



Devices for use with EUS

Prepared by: ASGE TECHNOLOGY COMMITTEE

Joo Ha Hwang, MD, PhD, FASGE, Harry R. Aslanian, MD, FASGE, Nirav Thosani, MD, Adam Goodman, MD, FASGE, Michael Manfredi, MD, Udayakumar Navaneethan, MD, Rahul Pannala, MD, MPH, Mansour A. Parsi, MD, FASGE, Zachary L. Smith, DO, Shelby A. Sullivan, MD, Subhas Banerjee, MD, FASGE, previous Committee Chair, John T. Maple, DO, FASGE, Chair

The American Society for Gastrointestinal Endoscopy (ASGE) Technology Committee provides reviews of existing, new, or emerging endoscopic technologies that have an impact on the practice of GI endoscopy. Evidence-based methodology is used, performing a MEDLINE literature search to identify pertinent clinical studies on the topic and a MAUDE (US Food and Drug Administration Center for Devices and Radiological Health) database search to identify the reported adverse events of a given technology. Both are supplemented by accessing the “related articles” feature of PubMed and by scrutinizing pertinent references cited by the identified studies. Controlled clinical trials are emphasized, but in many cases, data from randomized controlled trials are lacking. In such cases, large case series, preliminary clinical studies, and expert opinions are used. Technical data are gathered from traditional and Web-based publications, proprietary publications, and informal communications with pertinent vendors. Technology Status Evaluation Reports are drafted by 1 or 2 members of the ASGE Technology Committee, reviewed and edited by the Committee as a whole, and approved by the Governing Board of the ASGE. When financial guidance is indicated, the most recent coding data and list prices at the time of publication are provided.

For this review, the MEDLINE database was searched through February 2016 for articles related to endoscopy in patients by cross-referencing the key words “endoscopic ultrasound” or “EUS” with “fine needle aspiration,” “fine needle biopsy,” “cytology,” “histology,” “tissue acquisition,” “fine needle injection,” “neurolysis,” “endomicroscopy,” “stent,” “fiducial,” and “ablation.” Reference lists from relevant publications were also searched. Technology Status Evaluation Reports are scientific reviews provided solely for educational and informational purposes. Technology

Status Evaluation Reports are not rules and should not be construed as establishing a legal standard of care or as encouraging, advocating, requiring, or discouraging any particular treatment or payment for such treatment.

BACKGROUND

Since the publication of the last Technology Status Evaluation Report on devices for use with EUS in 2007,¹ several additional devices have been introduced. Initially, most EUS devices were needles, primarily for performing FNA. Newer EUS devices have expanded the capabilities of the endoscopist to include tissue acquisition for histologic evaluation, in vivo microscopy, fiducial placement, and EUS-based therapeutic interventions. This report will review the devices for use with EUS that are currently approved for marketing in the United States (Video 1, available online at www.VideoGIE.org).

TECHNICAL CONSIDERATIONS

The EUS devices presented in this report are all used with linear array echoendoscopes because image guidance is necessary to visualize the device as it is advanced to the target structures. The imaging plane of radial echoendoscopes is perpendicular to the axis of the endoscope; therefore, radial echoendoscopes cannot be used to guide the advancement of devices through the accessory channel.

EUS-FNA devices

A variety of single-use EUS-guided FNA (EUS-FNA) needle devices are available in 19G, 22G, and 25G configurations (Table 1). They are composed of a hollow needle with a solid removable stylet, a semirigid protective sheath, and a handle with a port for stylet insertion or withdrawal and attachment of a vacuum syringe. FNA needles and sheaths are composed of a variety of materials including aluminum, stainless steel, chromium-cobalt, and nitinol. All currently available needles are modified by laser etching, mechanical dimpling, or sandblasting of the leading tip (typically 1-2 cm) to enhance their echogenicity for ultrasound

TABLE 1. EUS devices

Device name	Manufacturer	Sheath diameter (mm or F)	Needle size (gauge)	Unique characteristics	List price (USD)
Fine-needle aspiration needles					
Beacon EUS delivery system with BNX FNA preloaded needle	Medtronic	2.5 mm	19, 22, 25	Needle is combined with a universal delivery sheath. The needle may be removed/exchanged while leaving the sheath in place. A safety sheath covers the needle tip when removed from the delivery sheath.	\$349 (22G, 25G) \$599 (19G)
BNX FNA needle (without sheath)	Medtronic		19, 22, 25	19G is a nitinol needle.	\$170 (22G, 25G) \$400 (19G)
Expect	Boston Scientific	1.52 mm (25G) 1.65 mm (22G) 1.83 mm (19G)	19, 22, 25	Cobalt-chromium needle, echogenic pattern to needle tip.	\$357
Expect Flex	Boston Scientific	1.73 mm	19	Nitinol needle has increased flexibility.	\$578
Expect Slimline	Boston Scientific	1.52 mm (25G) 1.65 mm (22G) 1.83 mm (19G)	19, 22, 25	Smaller-diameter handle for ergonomic purposes.	\$357
Expect Slimline Flex	Boston Scientific	1.73 mm	19	19G nitinol needle with smaller diameter handle.	\$578
ClearView	ConMed	1.8 mm (22G, 25G) 2.1 (19G)	19, 22, 25	Twist locks aid in 1-handed use, laser etching of needle tip over 2-cm length.	\$335
ClearView Sheath Stabilizer	ConMed	2.7 mm	22, 25	Larger-diameter sheath to increase needle stability.	\$335
ClearView Extended Bevel	ConMed	1.8 mm 2.7 mm (sheath stabilizer)	22	Extended stylet bevel to assist with puncture.	\$335
Echotip Ultra	Cook Medical	5.2F	19, 22, 25	Ergonomic handle, integrated sheath adjuster.	\$315
Echotip Ultra Coil Sheath	Cook Medical	5.2F	22	Coil sheath with increased flexibility.	\$315
Echotip Ultra HD access	Cook Medical	5.2F	19	Sharp stylet tip with smooth needle tip to prevent sheering during guidewire passage.	\$378
EZ Shot 2	Olympus	1.85 mm	19, 22, 25	Echogenic dimpled needle tip.	\$308
EZ Shot 2 Sideport	Olympus	1.85 mm	22	Sideport hole near needle tip to improve tissue acquisition.	\$364
EZ Shot 3 Plus with or without sideport	Olympus	2.2 mm (22G) 2.6 mm (19G)	19, 22	Nitinol, Menghini tip design.	\$615
EUS-FNB needles					
Beacon EUS Delivery System with SharkCore FNB preloaded needle	Medtronic	2.5 mm	19, 22, 25	Needle tip has parallel geometry with 2 cutting edges. Same delivery system as FNA needles.	\$464 (22G, 25G) \$750 (19G)
Echotip ProCore	Cook Medical	5.2F (22G, 25G) 7.95F (20G)	19, 20, 22, 25	Beveled core trap hole near needle tip. Needle dimpling to improve visualization.	\$410
Acquire	Boston	1.65 mm	22	Franseen design has 3 points to provide stability at the puncture site, with heels designed for tissue capture.	\$395

(continued on the next page)

TABLE 1. Continued

Device name	Manufacturer	Sheath diameter (mm or F)	Needle size (gauge)	Unique characteristics	List price (USD)
Miscellaneous EUS devices					
Echotip Ultra Celiac Plexus Neurolysis Needle	Cook Medical		20	Solid, sharp, conical tip with array of side holes for radial injection.	\$307
Echotip Ultra Fiducial Needle	Cook Medical		22	Preloaded with 4 gold fiducials.	\$550
Beacon EUS Fiducial Needle	Medtronic		22, 19	Preloaded with 2 gold fiducials.	
Moray microforceps	US Endoscopy	0.80 mm		Compatible with most 19G needles.	\$500
Habib EUS RFA probe	EMcision	1F		Compatible with 19G and some 22G needles.	\$1795
AXIOS System (10 mm × 10 mm) (15 mm × 10 mm)	Boston Scientific	10.8F		Delivery catheter is wire-guided with a hydrophilic coating. Stent lumen diameters are 10 mm (with 21-mm flange) and 15 mm diameter (with 24-mm flange).	\$4300
AXIOS Electrocautery Enhanced System (10 mm × 10 mm) (15 mm × 10 mm)	Boston Scientific	10.8F		Delivery system includes a monopolar electrode at the tip of the delivery catheter to enable electrocautery incision. Available stents are the same as the AXIOS system.	\$4390

visualization. Needles have adjustable spacers or sliders at the distal portion of the handle to allow modification of the length of sheath exiting the scope for use with different makes of linear echoendoscopes.

The FNA needles are preloaded with a blunt stylet, which may protrude beyond the tip of the needle by 1 to 2 mm in some needles. Stylets enhance the rigidity of the needle during advancement through tissue to the target structure and protect the endoscope channel. Many manufacturers suggest withdrawing the stylet by a few millimeters before needle advancement to fully expose the sharp bevel at the needle tip. No data exist to demonstrate superiority of one stylet tip over another. On some devices the stylet can be fixed in place within the needle by use of a Luer lock at the proximal end, whereas on other devices the stylet is loosely held in place by a notched cap.

The device handle consists of several rigid plastic interlocking cylinders and is affixed to the echoendoscope by use of the Luer lock at the accessory channel port to enhance device stability during use. The handle assembly allows for controlled and measured advancement of the needle from within the protective sheath into the organ or structure of interest. Handles typically have markings at 1-cm intervals to allow the depth of penetration of the needle to be monitored (although this distance can also be seen and measured endosonographically). Most needles can be advanced up to 9 cm. All devices come equipped with an adjustable “needle stopper” that limits advancement of the needle to a desired depth of insertion and prevents advancement completely during insertion and

removal of the entire device into the echoendoscope as a safety precaution. The needle is advanced out of the sheath and advanced into the target under direct ultrasound guidance. Once advanced into the target, the stylet is removed, and fluid, tissue, or both can be aspirated or therapeutic agents or contrast media can be injected.

The EUS-FNA needles come with 10- or 20-cc syringes with locking mechanisms to hold the withdrawn plunger at different levels and maintain various amounts of suction. A stopcock attached to the tip of the syringe assists in creating and holding the vacuum. Once the needle tip is in the target lesion and the stylet is removed, the suction syringe is locked onto the needle handle, and the stopcock is opened for suction to be transmitted to the needle tip. When sampling of the target lesion is completed, suction is terminated by closing the stopcock or removing the suction syringe to avoid aspirating luminal contents as the needle is withdrawn from the target back into the needle sheath. When aspirating a cystic lesion, vacuum suction is used to aspirate fluid and to obtain cells from the cyst wall. Standard Luer lock syringes can also be used to manually create suction.

The BNX needle (Medtronic, Sunnyvale, Calif) differs from other FNA devices in that the needle is advanced within a delivery sheath that is capable of accommodating different gauges of needles for use during the same procedure. After FNA of the target lesion has been performed, the needle is removed by pushing a release button, and the delivery sheath is left in place within the accessory channel of the endoscope. Upon withdrawal of the needle through

the handle, the needle tip is automatically covered with a safety sheath to prevent inadvertent needle tip injury to the endoscopy team. The same needle or a different needle of variable gauge can then be reinserted through the delivery sheath to perform additional needle passes.

Clinical results and comparative studies of FNA technique. EUS-FNA has high and well-established sensitivity and specificity for evaluation of solid pancreatic masses, with a diagnostic sensitivity of 0.87% (95% confidence interval [CI], 0.86-0.88) and specificity of 0.96% (95% CI, 0.95-0.97).²

Comparisons of different suction techniques.

There is variation in clinical practice on the use of the stylet and application of suction. The capillary technique uses slow stylet withdrawal while the needle is moving within the target lesion to generate a small amount of suction. Inconsistent diagnostic results for solid pancreatic masses have been reported with the use of suction, stylet withdrawal, and no suction. One trial comparing suction versus no suction found higher diagnostic accuracy with suction (82.4% vs 72.1%; $P = .005$).³ Another trial found greater sensitivity with the use of suction (0.86% vs 0.67%).⁴ In contrast, other studies identified increased sensitivity with slow stylet pull (capillary technique) with 25G needles,⁵ and another study identified no difference in outcomes between slow stylet pull and suction with 22G needles.^{4,5} When performing lymph node aspiration, the addition of suction was found to increase the blood in the sample with no benefit in diagnostic yield.⁶ A systematic review evaluating the role of suction in the performance of EUS-FNA recommended the use of suction for EUS-FNA of pancreatic masses but not for EUS-FNA of lymph nodes.⁷

Comparisons of different stylet techniques. The presence of the stylet within the needle at the time of the target puncture has not been found to affect the adequacy of the samples or the diagnostic yield of malignancy.⁷ Two prospective randomized trials evaluating EUS-FNA of solid lesions reported no difference in bloodiness (25.1% vs 24.4% and 17% vs 14%) or in diagnostic yield of malignancy (40% vs 34.2% and 23% vs 28%), with and without a stylet, respectively.^{8,9}

Comparisons of different needle gauges. Studies comparing needle sizes have indicated similar overall diagnostic yields.¹⁰ A comparison of 19G and 22G needles identified no difference in diagnostic yield for pancreatic and peripancreatic lesions.¹¹ No difference was found in the diagnostic yield between 22G and 25G needles in subepithelial lesions, although this may be influenced by the small study size (80% for 22G vs 60% for 25G).¹² However, 25G needles have been associated with a higher diagnostic yield for EUS-FNA of pancreatic masses. A meta-analysis evaluating 1292 patients undergoing EUS-FNA of pancreatic masses with a 22G needle (799 patients) versus a 25G needle (565 patients) found 25G needles to be more sensitive for the diagnosis of malignancy (pooled sensitivity 0.93 [95% CI, 0.91-0.96]) vs 22G needle (pooled sensitivity




Figure 1. ProCore (Cook Medical) needle tip with a core trap cutout. (Permission for use granted by Cook Medical Incorporated.)

0.85 [95% CI, 0.82-0.88]; $P = .0003$).¹³ A different meta-analysis found a trend toward greater sensitivity (0.91 [95% CI, 0.87-0.94] vs 0.78 [95% CI, 0.74-0.81]) and sample adequacy with 25G needles versus 22G needles.¹⁰

A single-center retrospective study evaluating FNA of pancreatic and nonpancreatic lesions using a 19G needle demonstrated a high diagnostic yield (>95%).¹⁴ However, difficulty in advancing 19G needles has been reported when the endoscope is highly torqued or angulated, as is often the case in the second portion of the duodenum while accessing the head/uncinate regions of the pancreas.¹¹ Nineteen-gauge needles made of nitinol (19G Flex, Boston Scientific, Marlborough, Mass) and the BNX 19G needle (Medtronic, Sunnyvale, Calif) are more flexible and may potentially be advantageous in these situations, but there are no published data to confirm this. For liver biopsies, EUS-FNA using 19G needles has a diagnostic yield of 91% to 98%, with a comparative study indicating yields comparable to percutaneous and transjugular approaches.¹⁵⁻¹⁷

EUS fine-needle biopsy devices

Core tissue sampling allows the ability to perform molecular studies and aids in the diagnostic evaluation of cases that benefit from tissue histologic examination, such as Hodgkin's lymphoma and autoimmune pancreatitis. Core tissue samples for histologic examination may be inconsistently obtained when FNA is performed with standard larger-bore FNA needles. The TruCut needle (Cook Medical, Winston-Salem, NC) was the first EUS needle introduced specifically to obtain core tissue samples. This device is no longer available, but 2 new fine-needle biopsy (FNB) devices have been designed with modifications of the distal portion or tip of the needle, to facilitate acquisition of core samples. The ProCore (Cook Medical) needle has a core trap cutout with a reverse bevel near the needle tip that facilitates additional tissue sampling (Fig. 1). ProCore needles are available in sizes of 25G, 22G, 20G, and 19G. The BNX SharkCore (Medtronic, Sunnyvale, Calif) has a parallel geometry with 2 cutting edges at the

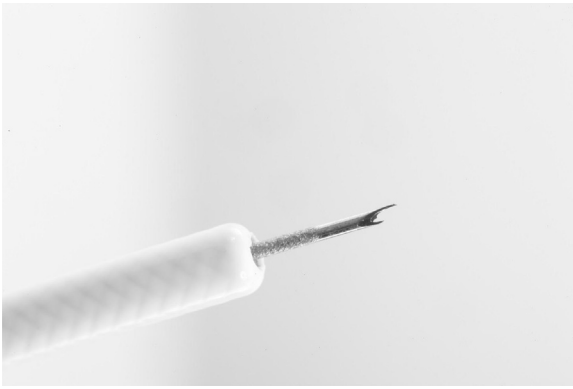

Figure 2. BNX SharkCore (Medtronic) needle tip. (Image provided by Medtronic.)

needle tip to facilitate tissue sampling (Fig. 2). It is available in 25G, 22G, and 19G diameters. The Boston Scientific Acquire needle is available in 22G diameter.

The 25G ProCore needle was found to have a diagnostic accuracy of 96% for solid pancreatic masses, and core samples were identified in 32% of patients.¹⁸ The 22G ProCore needle was found to provide diagnostic histologic examination in 88.5% of solid pancreas masses.¹⁹ A study of the 19G ProCore needle in 114 lesions indicated an overall 85% diagnostic accuracy, with histologic examination obtained in 89.5% of cases.²⁰

Comparative studies between FNA and FNB needles. A systematic review analysis of 10 studies comparing FNA with FNB sampling identified no difference in diagnostic yield in 6 studies and a superior yield with FNB in 4 studies.⁷ A meta-analysis comparing the ProCore FNB needle with standard FNA needles in 576 patients found no significant difference in diagnostic accuracy (85.8% vs 86.2%, odds ratio 0.88, $P = .53$) or rate of histologic core specimen acquisition (77.7% vs 76.5%, odds ratio 0.94, $P = .85$), respectively. The mean number of passes required for diagnosis, however, was significantly lower when using the ProCore needle (standardized mean difference, 1.2, $P < .001$).²¹ One study comparing the EchoTip Ultra (Cook Medical) 22G FNA needle (5 passes) with the EchoTip ProCore 22G FNB needle (2 passes) in the evaluation of the same solid pancreas masses in 32 patients found a significantly lower yield with the ProCore needle.²² In that study, the ProCore needle samples were processed as a histopathology sample, and tissue fragments were not identified in approximately one-fourth of patients. Additional data regarding the optimal processing of FNB samples are needed. A study comparing the 22G Expect FNA needle (Boston Scientific) with the 22G Cook ProCore needle found diagnostic sufficiency of 100% with FNA and 89.3% for FNB ($P = .24$). The 22G biopsy needle obtained a histologic specimen in 80% of cases, with a 3.6% technical failure rate.²³

In a series of 22 subepithelial lesions greater than 2 cm in size, 22G FNB needles were compared with 22G FNA needles. The FNB needles demonstrated greater diagnostic sufficiency (75% vs 20%), and more frequently produced




Figure 3. EchoTip Ultra High Definition Ultrasound Access Needle (Cook Medical). The needle has a sharp beveled stylet and a blunt needle tip after removal of the stylet. (Permission for use granted by Cook Medical Incorporated.)

histologic cores with 3 needle passes (92% vs 30%, $P = .006$).²⁴ A randomized crossover trial found no difference between FNA and FNB needles in the sampling of pancreas masses; however, in nonpancreatic lesions, the diagnostic yield of EUS-FNB was higher than that of EUS-FNA (88.2% vs 54.5%, $P = .006$). Crossover from FNA to FNB was found to be successful in 27 of 28 cases (96.5%, $P = .0003$).²⁵ A systematic review recommended considering EUS-FNB for tissue sampling of nonpancreatic mass lesions, when immunohistochemistry is required, and as a salvage technique after inadequate FNA samples.⁷

Access needle

EUS-guided access to extraluminal structures such as the bile duct, pancreatic duct, or pancreatic fluid collections has been reported.²⁶⁻³¹ A 19G needle has been specifically designed for this particular application (EchoTip Ultra High Definition Ultrasound Access Needle, Cook Medical), consisting of a sharply beveled stylet that is used for puncture and removed once access to the desired target has been obtained (Fig. 3). After removal of the beveled stylet, the remaining needle tip is blunt, and this may prevent trauma and reduce the incidence of guidewire shearing. The needle diameter allows passage of a 0.035 inch guidewire. Studies evaluating the safety and efficacy of EUS-guided access using this device compared with standard EUS-FNA needles have not been published to date.

Celiac plexus blockade and neurolysis needle

Celiac plexus blockade (CPB) is performed to provide temporary pain relief, usually via the injection of a local anesthetic agent combined with a steroid via an FNA needle. Celiac plexus neurolysis (CPN) involves the injection of a local anesthetic followed by injection of ethanol to permanently ablate nerve tissue.³² Most reports to date have described the performance of these injections through available standard EUS-FNA needles.³³⁻³⁵ A 20G needle




Figure 4. EchoTip Ultra Celiac Plexus Neurolysis Needle (Cook Medical). The needle has a sharp, conical tip with an array of side holes. (Permission for use granted by Cook Medical Incorporated.)

specifically designed for EUS-guided CPB and CPN (EchoTip Ultra Celiac Plexus Neurolysis Needle; Cook Medical) differs from other EUS needles in that it has a solid, sharp, conical tip and an array of side holes for radial delivery of the desired agent into the region of the celiac plexus, the perineural space, or both (Fig. 4). Studies evaluating the efficacy of CPN using this device compared with standard EUS-FNA needles have not been published.

Cytology brush

A cytology brush is available for dedicated use through echoendoscopes (EchoBrush; Cook Endoscopy) and comprises a disposable, modified EUS-styler with a 1 mm × 5 mm brush at its leading end that passes through the lumen of the Cook 19G FNA needle.

Several clinical studies have used this device to sample pancreatic cystic lesions.³⁶⁻⁴⁰ In a study of 37 patients with pancreatic cysts at least 20 mm in maximal dimension, standard FNA using a 19G FNA needle for aspiration of cyst contents was followed by EUS-guided brush cytology of the cyst interior using the EchoBrush.³⁸ The use of the cytology brush increased cytologic yield, with 3 cases (8%) of high-grade dysplasia identified only on brushing specimens. Another study compared the cytologic yield of the EchoBrush (47 patients) to EUS-FNA using a 22G EUS-FNA needle (80 patients) in pancreatic cysts of varying size.³⁷ The use of the EchoBrush resulted in a cytologically adequate sample in 85.1% of cases compared with 66.3% for the EUS-FNA group ($P = .023$).

Microforceps

A microforceps that can be advanced through the lumen of a 19G FNA needle is available (Moray microforceps; US Endoscopy, Mentor, Ohio). The Moray microforceps have a sheath diameter of 0.80 mm and an open jaw width of 4.3 mm (Fig. 5). A pilot study using another microforceps not marketed in the United States reported



Figure 5. Moray microforceps (US Endoscopy). (Image provided by US Endoscopy.)

the feasibility of obtaining tissue from solid pancreatic lesions for histologic evaluation.^{41,42} Seventeen patients underwent a median of 3 passes, with 67% tissue acquisition per pass and 100% per session. The diagnostic accuracy was 88% per pass and 94% per session. Studies evaluating the diagnostic yield of microforceps compared with other EUS-guided tissue sampling methods have not been published.

Needle-based confocal laser endomicroscopy probe

The AQ-Flex 19 (Mauna Kea Technologies, Paris, France) is a probe designed to be advanced through a 19G EUS-FNA needle to perform needle-based confocal laser endomicroscopy (nCLE) (Fig. 6). A laser scanning unit (Cellvizio, Mauna Kea Technologies) is required to perform nCLE, and 2.5 to 5 mL of 10% fluorescein is typically administered intravenously immediately before



Figure 6. AQ-Flex 19 (Mauna Kea Technologies) needle-based confocal laser endomicroscopy probe. (Image provided by Mauna Kea Technologies.)

imaging to provide vascular contrast. The depth of imaging is 40 to 70 μm , the maximal field of view is 325 μm , and resolution is 3.5 μm . The probe can be reused after high-level disinfection; software limits the use of each probe to a maximum of 10 examinations. Studies to date have largely evaluated nCLE performance in imaging the wall of pancreatic cystic lesions and are summarized in an ASGE Technology review of CLE.⁴³ A recent study of nCLE in 33 patients with pancreatic cysts reported sensitivity and specificity of 69% and 100% for serous cystadenoma, 91% and 95% for mucinous cysts, and 43% and 100% for pseudocysts.⁴⁴

Radiofrequency ablation catheter

A radiofrequency ablation (RFA) catheter designed to be passed through a 22G or 19G EUS-FNA needle has recently been approved for use by the US FDA for cauterization and coagulation of tissue under EUS guidance (Habib EUS-RFA probe; EMcision, London, United Kingdom). The RFA probe is a 1F (0.33 mm) diameter, monopolar wire with a 20-mm segment at the tip of the wire where current is conducted (Fig. 7). The RFA probe is compatible with any of the existing electrosurgical generators. A small multicenter pilot study evaluated this device in 8 patients with pancreatic neoplasms, including pancreatic cystic neoplasms (6 patients) and




Figure 7. Habib EUS-RFA probe (EMcision). (Image provided by EMcision.)

neuroendocrine tumors (2 patients).⁴⁵ This study demonstrated the feasibility of EUS-guided RFA; however, given the limited number of patients in this study, it is not possible to make any substantial conclusions regarding the efficacy or safety of the treatment.

Fiducials

EUS-guided fiducial placement is performed to assist image-guided radiation therapy (IGRT).⁴⁶ The use of fiducial markers placed within pancreatic tumors has been demonstrated to result in less positional variation compared with the use of bony anatomy for IGRT.⁴⁷ Currently, EUS-guided gold fiducial marker placement requires backloading of the fiducial into the tip of a 19G or 22G needle, followed by sealing of the needle tip with bone wax. This process is time-consuming, cumbersome, and carries the risk of needle-tip injury. Dedicated EUS needles that are preloaded with fiducials have recently been developed. The Echotip fiducial needle (Cook Medical) is a 22G needle that is preloaded with 4 gold fiducials (Fig. 8). In addition, Medtronic has developed 19G and 22G EUS fiducial needles that can be used with their BNX delivery system, with each needle containing 2 gold fiducials (Fig. 9).

Stents

Historically, EUS-guided drainage of intra-abdominal fluid collections has been performed primarily with the use of plastic and metal biliary stents designed for use with ERCP. The AXIOS Stent (Boston Scientific) is a lumen-apposing metal stent that is placed under EUS guidance (Fig. 10).⁴⁸ The stent is made of nitinol wire and is fully covered. It is available in diameters of 10 and 15 mm. The stent has 2 disk-shaped flanges, separated by 10 mm, designed to achieve tissue apposition and decrease the risk of migration. The 10.8F AXIOS stent delivery system has a hydrophilic coating and is advanced through the working channel of a therapeutic echoendoscope to the fluid collection over a previously placed guidewire after dilation of the transmural tract. Once the delivery system is advanced into



Figure 8. EchoTip fiducial needle (Cook Medical). (Permission for use granted by Cook Medical Incorporated.)



Figure 9. BNX fiducial delivery system (Medtronic) handle and fiducial. (Image provided by Medtronic.)

the fluid collection, the distal flange of the stent is deployed. The stent is then retracted so that the distal flange is pulled against the cyst wall. The proximal flange is then deployed within the lumen of the GI tract, and the delivery system is then withdrawn. Tract dilation and use of a guide-wire are not necessary with the AXIOS electrocautery enhanced system (Boston Scientific), which has a monopolar electrocautery element at the tip of the delivery system that can cut through the lumen wall.

The efficacy of the AXIOS stent has been evaluated in a multicenter study of 33 patients with pancreatic fluid collections. Successful placement of the AXIOS stent was possible in 30 (91%) of patients, with resolution of



Figure 10. AXIOS lumen-apposing metal stent (Boston Scientific). The stent has 2 flanges that are 10 mm apart. (Image provided by Boston Scientific.)

pancreatic fluid collections in 28 (84%) patients.⁴⁹ Stent migration was observed in a single patient. EUS-guided gallbladder drainage using the AXIOS stent has been reported in patients who were not surgical candidates.⁵⁰⁻⁵² In a multicenter, prospective trial of 30 patients, successful deployment of the stent into the gallbladder was possible in 90% of patients.⁵²

SAFETY

EUS-FNA devices

EUS-FNA has a low overall adverse event rate.⁷ Adverse events such as bleeding, bacteremia, and pancreatitis occur in less than 2% of all patients undergoing FNA.^{53,54} A systematic review assessing the morbidity and mortality associated with EUS-guided FNA demonstrated a 0.98% overall rate of EUS-FNA-specific morbidity.⁵⁴

Fine-needle biopsy devices

Studies evaluating the safety of FNB devices have shown no significant difference in rates of adverse events compared to FNA devices.^{23,24,55} In a comparison of 22G FNA and FNB devices used to sample solid pancreatic masses, the rate of adverse events was 1.7% and 5.2%, respectively ($P = 1.0$) with a case of mild pancreatitis in the FNA group and mild bleeding and a gastric wall hematoma at the puncture site in the FNB group.⁵⁵

Celiac plexus blockade and neurolysis

EUS-guided CPB and CPN have low reported rates of adverse events. A study of 189 EUS-CPB and 31 EUS-CPN procedures reported adverse event rates of 1.6% for EUS-CPB and 3.2% for EUS-CPN.⁵⁶ Commonly

TABLE 2. List of relevant endoscopic ultrasound Current Procedural Terminology codes

Colonoscopy
45391: Colonoscopy, flexible, proximal to splenic flexure; with endoscopic ultrasound examination
45392: Colonoscopy, flexible, proximal to splenic flexure; with transendoscopic ultrasound guided intramural or transmural fine needle aspiration/biopsy(s)
Sigmoidoscopy
45341: Sigmoidoscopy, flexible, with endoscopic ultrasound examination
45342: Sigmoidoscopy, flexible, with transendoscopic ultrasound guided intramural or transmural fine needle aspiration/biopsy(s)
Esophagoscopy
43231: Esophagoscopy, rigid or flexible, with endoscopic ultrasound examination
43232: Esophagoscopy, rigid or flexible, with transendoscopic ultrasound-guided intramural or transmural fine needle aspiration/biopsy(s)
Upper Gastrointestinal Endoscopy
43237: Esophagogastroduodenoscopy, flexible, transoral; EUS limited to esophagus, stomach OR duodenum
43238: Esophagogastroduodenoscopy, flexible, transoral; EUS with FNA limited to esophagus, stomach OR duodenum
43240: Esophagogastroduodenoscopy, flexible, transoral; transmural drainage, pseudocyst (Includes placement of drainage, stents, transmural needle aspiration and EUS during the same session)
43242: Esophagogastroduodenoscopy, flexible, transoral; EUS with FNA of esophagus, stomach AND duodenum
43253: Esophagogastroduodenoscopy, flexible, transoral; EUS-guided transmural injection (eg, celiac axis neurolysis, fiducial marker placement)
43259: Esophagogastroduodenoscopy, flexible, transoral; EUS of esophagus, stomach AND duodenum

reported adverse events included asymptomatic hypotension for EUS-CPN and post-procedural pain for EUS-CPB. Major adverse events reported for EUS-CPB include retroperitoneal abscess and empyema.⁵⁷ Major adverse events reported for EUS-CPN include retroperitoneal bleeding, ischemia, brain abscess, and paraplegia.⁵⁷ There are no studies that specifically evaluate the safety of the EUS-CPN needle. A randomized trial of 56 patients undergoing CPB for treatment of chronic pancreatitis compared EUS guidance with fluoroscopic guidance.⁵⁸ In that study, 2 patients had diarrhea after EUS-CPB, and 1 patient had postural hypotension after fluoroscopic-guided block. No serious adverse events were reported in either group.

Cytology brush

Adverse event rates of up to 19% have been reported with use of the EchoBrush in pancreatic cysts.³⁸ One study of 37 patients undergoing EUS-FNA with the EchoBrush reported major intracystic bleeding in 1 patient (2.7%) requiring blood transfusions and angiographic embolization, and acute pancreatitis in 1 patient (2.7%).³⁸ That study also reported 4 minor adverse events, including postprocedure abdominal pain without biochemical evidence of pancreatitis in 2 patients (5.4%) and self-limited intracystic bleeding in 2 patients (5.4%). Another study of 120 patients undergoing EUS-FNA with the EchoBrush reported 3 (2.5%) cases of self-limited intracystic bleeding and 1 perigastric abscess in an immunocompromised patient.³⁷

Needle-based confocal laser endomicroscopy probe

A multicenter pilot study examining the performance characteristics of nCLE to image pancreatic cysts in 66 patients reported an adverse event rate of 9%, which included

pancreatitis (2 patients), transient abdominal pain (1 patient), and self-limited intracystic bleeding (3 patients).⁵⁹

Stents

The safety of the AXIOS stent was evaluated in a multicenter study of 33 patients with pancreatic fluid collections. That study reported an overall adverse event rate of 15%, including abdominal pain (3%), back pain (3%), access-site infection (3%), stent migration (3%), and stent dislodgement (3%).⁴⁹

Other devices

Studies evaluating the safety of the new microforceps, RFA catheter, and EUS fiducial needles have yet to be reported.

FINANCIAL ISSUES

The use of EUS accessories adds cost, time, and risk to procedures. The specific costs of EUS accessories vary widely and are listed in [Table 1](#). The use of EUS accessories often requires modification in coding practices because additional codes are required, depending on the type of accessory used and the specific context of use. A full list of relevant Current Procedural Terminology codes can be found in [Table 2](#).

AREAS FOR FUTURE RESEARCH

Further studies are needed to evaluate the safety and efficacy of these new devices and interventions. In particular, the following issues related to existing devices require further study:

- Optimal tissue acquisition techniques for FNB
- Comparative studies evaluating the safety and diagnostic yield of microforceps and other EUS-guided tissue sampling methods

- Indications, safety, and diagnostic performance of nCLE
- Indications, safety, and efficacy of EUS-guided RFA
- Comparative studies evaluating the efficacy, safety, and cost-effectiveness of AXIOS stents compared with conventional plastic stents in the management of pancreatic fluid collections

SUMMARY

The development of dedicated EUS devices has expanded the diagnostic and therapeutic capabilities of EUS to include the ability to obtain tissue biopsy specimens for histologic evaluation, perform in vivo microscopy, place fiducials, and perform EUS-based therapeutic interventions. As experience and data accumulate for these devices, their role in clinical practice will be better defined. Until then, appropriate use of these devices should be based on the available data and clinical judgement.

DISCLOSURE

Dr Thosani and Dr Parsi are consultants for Boston Scientific. Dr Hwang is a consultant for Medtronic and US Endoscopy. Dr Sullivan is a consultant for USGI Medical, Obalon Therapeutics, Elira Therapeutics, and Enteromedics, is on the Advisory Board of Takeda Pharmaceuticals, and performs contracted research for USGI Medical, Obalon Therapeutics, GI Dynamics, Aspire Bariatrics, Baronova, and Paion. Dr Aslanian is a consultant for and receives honoraria from Boston Scientific and Olympus. All other authors disclosed no financial relationships relevant to this publication.

REFERENCES

1. ASGE Technology Committee; Adler DG, Conway JD, Coffie JM, et al. EUS accessories. *Gastrointest Endosc* 2007;66:1076-81.
2. Puli SR, Bechtold ML, Buxbaum JL, et al. How good is endoscopic ultrasound-guided fine-needle aspiration in diagnosing the correct etiology for a solid pancreatic mass? A meta-analysis and systematic review. *Pancreas* 2013;42:20-6.
3. Lee JK, Choi JH, Lee KH, et al. A prospective, comparative trial to optimize sampling techniques in EUS-guided FNA of solid pancreatic masses. *Gastrointest Endosc* 2013;77:745-51.
4. Puri R, Vilmann P, Saftoiu A, et al. Randomized controlled trial of endoscopic ultrasound-guided fine-needle sampling with or without suction for better cytological diagnosis. *Scand J Gastroenterol* 2009;44:499-504.
5. Nakai Y, Isayama H, Chang KJ, et al. Slow pull versus suction in endoscopic ultrasound-guided fine-needle aspiration of pancreatic solid masses. *Dig Dis Sci* 2014;59:1578-85.
6. Wallace MB, Kennedy T, Durkalski V, et al. Randomized controlled trial of EUS-guided fine needle aspiration techniques for the detection of malignant lymphadenopathy. *Gastrointest Endosc* 2001;54:441-7.
7. Wani S, Muthusamy VR, Komanduri S. EUS-guided tissue acquisition: an evidence-based approach (with videos). *Gastrointest Endosc* 2014;80:939-59.e7.
8. Rastogi A, Wani S, Gupta N, et al. A prospective, single-blind, randomized, controlled trial of EUS-guided FNA with and without a stylet. *Gastrointest Endosc* 2011;74:58-64.
9. Wani S, Gupta N, Gaddam S, et al. A comparative study of endoscopic ultrasound-guided fine needle aspiration with and without a stylet. *Dig Dis Sci* 2011;56:2409-14.
10. Affolter KE, Schmidt RL, Matynia AP, et al. Needle size has only a limited effect on outcomes in EUS-guided fine needle aspiration: a systematic review and meta-analysis. *Dig Dis Sci* 2013;58:1026-34.
11. Song TJ, Kim JH, Lee SS, et al. The prospective randomized, controlled trial of endoscopic ultrasound-guided fine-needle aspiration using 22G and 19G aspiration needles for solid pancreatic or peripancreatic masses. *Am J Gastroenterol* 2010;105:1739-45.
12. Imazu H, Uchiyama Y, Kakutani H, et al. A prospective comparison of EUS-guided FNA using 25-gauge and 22-gauge needles. *Gastroenterol Res Pract* 2009;2009:546390.
13. Madhoun MF, Wani SB, Rastogi A, et al. The diagnostic accuracy of 22-gauge and 25-gauge needles in endoscopic ultrasound-guided fine needle aspiration of solid pancreatic lesions: a meta-analysis. *Endoscopy* 2013;45:86-92.
14. Larghi A, Verna EC, Ricci R, et al. EUS-guided fine-needle tissue acquisition by using a 19-gauge needle in a selected patient population: a prospective study. *Gastrointest Endosc* 2011;74:504-10.
15. Stavropoulos SN, Im GY, Jlayer Z, et al. High yield of same-session EUS-guided liver biopsy by 19-gauge FNA needle in patients undergoing EUS to exclude biliary obstruction. *Gastrointest Endosc* 2012;75:310-8.
16. Diehl DL, Johal AS, Khara HS, et al. Endoscopic ultrasound-guided liver biopsy: a multicenter experience. *Endosc Int Open* 2015;3:E210-5.
17. Pineda JJ, Diehl DL, Miao CL, et al. EUS-guided liver biopsy provides diagnostic samples comparable with those via the percutaneous or transjugular route. *Gastrointest Endosc* 2016;83:360-5.
18. Iwashita T, Nakai Y, Samarasena JB, et al. High single-pass diagnostic yield of a new 25-gauge core biopsy needle for EUS-guided FNA biopsy in solid pancreatic lesions. *Gastrointest Endosc* 2013;77:909-15.
19. Larghi A, Iglesias-Garcia J, Poley JW, et al. Feasibility and yield of a novel 22-gauge histology EUS needle in patients with pancreatic masses: a multicenter prospective cohort study. *Surg Endosc* 2013;27:3733-8.
20. Iglesias-Garcia J, Poley JW, Larghi A, et al. Feasibility and yield of a new EUS histology needle: results from a multicenter, pooled, cohort study. *Gastrointest Endosc* 2011;73:1189-96.
21. Bang JY, Hawes R, Varadarajulu S. A meta-analysis comparing ProCore and standard fine-needle aspiration needles for endoscopic ultrasound-guided tissue acquisition. *Endoscopy* 2016;48:339-49.
22. Strand DS, Jeffus SK, Sauer BG, et al. EUS-guided 22-gauge fine-needle aspiration versus core biopsy needle in the evaluation of solid pancreatic neoplasms. *Diagn Cytopathol* 2014;42:751-8.
23. Bang JY, Hebert-Magee S, Trevino J, et al. Randomized trial comparing the 22-gauge aspiration and 22-gauge biopsy needles for EUS-guided sampling of solid pancreatic mass lesions. *Gastrointest Endosc* 2012;76:321-7.
24. Kim GH, Cho YK, Kim EY, et al. Comparison of 22-gauge aspiration needle with 22-gauge biopsy needle in endoscopic ultrasonography-guided subepithelial tumor sampling. *Scand J Gastroenterol* 2014;49:347-54.
25. Aadam AA, Wani S, Amick A, et al. A randomized controlled cross-over trial and cost analysis comparing endoscopic ultrasound fine needle aspiration and fine needle biopsy. *Endosc Int Open* 2016;4:E497-505.
26. Attam R, Arain M, Trikudanathan G, et al. EUS-guided pancreatic duct access and wire placement to facilitate dorsal duct cannulation after failed ERCP. *Gastrointest Endosc* 2015;81:1260.
27. Gupta K, Perez-Miranda M, Kahaleh M, et al. Endoscopic ultrasound-assisted bile duct access and drainage: multicenter, long-term analysis of approach, outcomes, and complications of a technique in evolution. *J Clin Gastroenterol* 2014;48:80-7.
28. Kahaleh M, Shami VM, Conaway MR, et al. Endoscopic ultrasound drainage of pancreatic pseudocyst: a prospective comparison with conventional endoscopic drainage. *Endoscopy* 2006;38:355-9.

29. Kawakubo K, Isayama H, Sasahira N, et al. Clinical utility of an endoscopic ultrasound-guided rendezvous technique via various approach routes. *Surg Endosc* 2013;27:3437-43.
30. ASGE Standards of Practice Committee; Muthusamy VR, Chandrasekhara V, Acosta RD, et al. The role of endoscopy in the diagnosis and treatment of inflammatory pancreatic fluid collections. *Gastrointest Endosc* 2016;84:1-9.
31. Khashab MA, Van der Merwe S, Kunda R, et al. Prospective international multicenter study on endoscopic ultrasound-guided biliary drainage for patients with malignant distal biliary obstruction after failed endoscopic retrograde cholangiopancreatography. *Endosc Int Open* 2016;4:E487-96.
32. LeBlanc JK, Al-Haddad M, McHenry L, et al. A prospective, randomized study of EUS-guided celiac plexus neurolysis for pancreatic cancer: one injection or two? *Gastrointest Endosc* 2011;74:1300-7.
33. Gress F, Schmitt C, Sherman S, et al. A prospective randomized comparison of endoscopic ultrasound- and computed tomography-guided celiac plexus block for managing chronic pancreatitis pain. *Am J Gastroenterol* 1999;94:900-5.
34. Wiersema MJ, Wiersema LM. Endosonography-guided celiac plexus neurolysis. *Gastrointest Endosc* 1996;44:656-62.
35. Kaufman M, Singh G, Das S, et al. Efficacy of endoscopic ultrasound-guided celiac plexus block and celiac plexus neurolysis for managing abdominal pain associated with chronic pancreatitis and pancreatic cancer. *J Clin Gastroenterol* 2010;44:127-34.
36. Al-Haddad M, Raimondo M, Woodward T, et al. Safety and efficacy of cytology brushings versus standard FNA in evaluating cystic lesions of the pancreas: a pilot study. *Gastrointest Endosc* 2007;65:894-8.
37. Lozano MD, Subtil JC, Miravalles TL, et al. EchoBrush may be superior to standard EUS-guided FNA in the evaluation of cystic lesions of the pancreas: preliminary experience. *Cancer Cytopathol* 2011;119:209-14.
38. Al-Haddad M, Gill KR, Raimondo M, et al. Safety and efficacy of cytology brushings versus standard fine-needle aspiration in evaluating cystic pancreatic lesions: a controlled study. *Endoscopy* 2010;42:127-32.
39. Bruno M, Bosco M, Carucci P, et al. Preliminary experience with a new cytology brush in EUS-guided FNA. *Gastrointest Endosc* 2009;70:1220-4.
40. Thomas T, Bebb J, Mannath J, et al. EUS-guided pancreatic cyst brushing: a comparative study in a tertiary referral centre. *JOP* 2010;11:163-9.
41. Nakai Y, Isayama H, Chang KJ, et al. A pilot study of EUS-guided through-the-needle forceps biopsy (with video). *Gastrointest Endosc* 2016;84:158-62.
42. Samarasena JB, Nakai Y, Shinoura S, et al. EUS-guided, through-the-needle forceps biopsy: a novel tissue acquisition technique. *Gastrointest Endosc* 2015;81:225-6.
43. ASGE Technology Committee; Chauhan SS, Abu Dayyeh BK, Bhat YM, et al. Confocal laser endomicroscopy. *Gastrointest Endosc* 2014;80:928-38.
44. Napoleon B, Lemaistre AI, Pujol B, et al. In vivo characterization of pancreatic cystic lesions by needle-based confocal laser endomicroscopy (nCLE): proposition of a comprehensive nCLE classification confirmed by an external retrospective evaluation. *Surg Endosc* 2016;30:2603-12.
45. Pai M, Habib N, Senturk H, et al. Endoscopic ultrasound guided radio-frequency ablation, for pancreatic cystic neoplasms and neuroendocrine tumors. *World J Gastrointest Surg* 2015;7:52-9.
46. DiMaio CJ, Nagula S, Goodman KA, et al. EUS-guided fiducial placement for image-guided radiation therapy in GI malignancies by using a 22-gauge needle (with videos). *Gastrointest Endosc* 2010;71:1204-10.
47. van der Horst A, Wognum S, Davila Fajardo R, et al. Interfractional position variation of pancreatic tumors quantified using intratumoral fiducial markers and daily cone beam computed tomography. *Int J Radiat Oncol Biol Phys* 2013;87:202-8.
48. Binmoeller KF, Shah J. A novel lumen-apposing stent for transluminal drainage of nonadherent extraintestinal fluid collections. *Endoscopy* 2011;43:337-42.
49. Shah RJ, Shah JN, Waxman I, et al. Safety and efficacy of endoscopic ultrasound-guided drainage of pancreatic fluid collections with lumen-apposing covered self-expanding metal stents. *Clin Gastroenterol Hepatol* 2015;13:747-52.
50. Irani S, Baron TH, Grimm IS, et al. EUS-guided gallbladder drainage with a lumen-apposing metal stent (with video). *Gastrointest Endosc* 2015;82:1110-5.
51. Teoh AY, Binmoeller KF, Lau JY. Single-step EUS-guided puncture and delivery of a lumen-apposing stent for gallbladder drainage using a novel cauterly-tipped stent delivery system. *Gastrointest Endosc* 2014;80:1171.
52. Walter D, Teoh AY, Itoi T, et al. EUS-guided gall bladder drainage with a lumen-apposing metal stent: a prospective long-term evaluation. *Gut* 2016;65:6-8.
53. ASGE Standards of Practice Committee; Early DS, Acosta RD, Chandrasekhara V, et al. Adverse events associated with EUS and EUS with FNA. *Gastrointest Endosc* 2013;77:839-43.
54. Wang KX, Ben QW, Jin ZD, et al. Assessment of morbidity and mortality associated with EUS-guided FNA: a systematic review. *Gastrointest Endosc* 2011;73:283-90.
55. Lee YN, Moon JH, Kim HK, et al. Core biopsy needle versus standard aspiration needle for endoscopic ultrasound-guided sampling of solid pancreatic masses: a randomized parallel-group study. *Endoscopy* 2014;46:1056-62.
56. O'Toole TM, Schmulewitz N. Complication rates of EUS-guided celiac plexus blockade and neurolysis: results of a large case series. *Endoscopy* 2009;41:593-7.
57. Alvarez-Sanchez MV, Jenssen C, Faiss S, et al. Interventional endoscopic ultrasonography: an overview of safety and complications. *Surg Endosc* 2014;28:712-34.
58. Santosh D, Lakhtakia S, Gupta R, et al. Clinical trial: a randomized trial comparing fluoroscopy guided percutaneous technique vs. endoscopic ultrasound guided technique of coeliac plexus block for treatment of pain in chronic pancreatitis. *Aliment Pharmacol Ther* 2009;29:979-84.
59. Konda VJ, Meining A, Jamil LH, et al. A pilot study of in vivo identification of pancreatic cystic neoplasms with needle-based confocal laser endomicroscopy under endosonographic guidance. *Endoscopy* 2013;45:1006-13.