

Combination therapy with plasma exchange and glucocorticoid may be effective for severe COVID-19 infection: A retrospective observational study

Yasushi Matsushita¹ | Makio Kusaoi¹ | Makoto Hiki^{2,3} | Goh Murayama¹ |
Yoshiyuki Abe¹ | Kazuhisa Nozawa¹ | Kazuhisa Takahashi⁴ | Ken Yamaji¹ |
Naoto Tamura¹ | Toshio Naito⁵

¹Department of Internal Medicine and Rheumatology, Faculty of Medicine, Juntendo University, Tokyo, Japan

²Department of Emergency Medicine, Faculty of Medicine, Juntendo University, Tokyo, Japan

³Department of Cardiovascular Medicine, Faculty of Medicine, Juntendo University, Tokyo, Japan

⁴Department of Respiratory Medicine, Faculty of Medicine, Juntendo University, Tokyo, Japan

⁵Department of General Medicine, Faculty of Medicine, Juntendo University, Tokyo, Japan

Correspondence

Makio Kusaoi, Department of Internal Medicine and Rheumatology, Faculty of Medicine, Juntendo University, 3-1-1 Hongo, Bunkyo-ku, Tokyo 113-8421, Japan.
Email: makio.k@juntendo.ac.jp

Funding information

Japanese rock band GLAY

[Correction added on 14 May 2021, after first online publication: the corresponding author's email address has been updated.]

Abstract

We retrospectively analyzed the characteristics and outcomes of five patients with COVID-19 who were received glucocorticoid (with or without pulse therapy) and therapeutic plasma exchange. The efficacy of the treatment was determined by whether the patient was able to be transferred from the COVID-19 exclusive ICU to the general ward. In comparing patients who received prednisolone pulse therapy (three cases) with those who did not (two cases), 2/3 (66%) and 0/2 (0%) patients could be discharged from the COVID-19 dedicated ICU, respectively. Among five patients who was performed plasma exchange, two elderly male patients who underwent plasma exchange as early as within 8 days of disease exacerbation survived and were able to be transferred to the general ward. This observational study indicates that plasma exchange in conjunction with methylprednisolone pulse therapy at the appropriate time may be an effective treatment for elderly patients with severe COVID-19.

KEYWORDS

COVID-19, glucocorticoid, methylprednisolone, plasma exchange, SARS-CoV-2

1 | INTRODUCTION

COVID-19 causes systemic symptoms, such as fever, cough, and general malaise. In severe cases, it causes acute respiratory distress syndrome (ARDS) resulting in

acute progressive hypoxemia and may take a fatal course. The pathogenesis of ARDS is considered to be caused by a cytokine storm that results from excessive activation of the immune system in response to a COVID-19 [1–3]. Although the optimal treatment regimen for COVID-19

has not been established, Horby et al. reported on the efficacy of short-term dexamethasone for moderate and severe cases of COVID-19 in a recovery trial [4]. This study found that mortality at 28 days was significantly lower in the dexamethasone group than in the standard care group. However, subgroup analysis showed that in severe cases of COVID-19 in patients over the age of 70, survival was low, and long-term prognosis was not shown. Plasma exchange (PE) removes high molecular weight inflammatory proteins and tissue-damaging factors such as neutrophil extracellular traps that dissolve in a patient's plasma [5]. It has also been reported that viral RNA is detected in the peripheral blood in severe COVID-19 cases and that PE can also be used to remove viral RNA directly [6]. We therefore decided to investigate whether combination therapy with a glucocorticoid (GC) and PE could be effective treatment in COVID-19 and tested it in several patients with severe COVID-19.

2 | PATIENTS AND METHODS

We retrospectively analyzed the characteristics and outcomes of COVID-19 patients who were received GC including pulse therapy and therapeutic PE, hospitalized at the Juntendo University Hospital, a 1051-bed, university-affiliated hospital in Tokyo, from April 13, 2020 to September 30, 2020. All patients were positive for the SARS-CoV-2 polymerase chain reaction (PCR) test and negative for other infections. The criteria for GC administration and PE were patients with ARDS ($\text{PaO}_2/\text{FiO}_2$ ratio of less than 200) and/or labored respiration and/or tracheal intubation. PE was performed using a membrane plasma separator (Plasmaflow OP-08W; Asahi Kasei Medical Co., Ltd.). Each PE session, we used fresh frozen plasma as the replacement fluid and 2500–3000 mL per time in all patients. We performed a lung protective strategy in all intubated patients and daily prone position ventilation, and continued anticoagulant therapy with heparin in all patients. We also performed a comprehensive screening of bacterial and fungal infections and used empirical antibiotics. The ethical review board of our hospital approved the use of PE for COVID-19 patients. The efficacy of PE and steroids, including pulse therapy, was assessed by the outcome of whether the patient could be transferred from the COVID-19 dedicated ICU. Written informed consent was obtained from all patients on the basis of the Declaration of Helsinki.

3 | RESULTS

Five patients received steroids and PE, including pulse therapy, during the eligible observation period. Four of the

five patients were male, and the median age was 76 years. All patients had some history of malignancy, hypertension, or renal failure. All patients received some GC and also PE, even if the timing was uneven. Three of the five patients received methylprednisolone (mPSL) pulse therapy. Two patients refused to be ventilated of their own volition, so even if they were hypoxemic, only three out of five patients were administered ventilatory management. The median number of PE performed was 6, and the median time from admission to PE was 11 days. As for apheresis besides PE, continuous hemodiafiltration (CHDF) was performed in three patients, and polymyxin B-immobilized fiber column direct hemoperfusion (PMX-DHP) was performed in two patients. The outcome of discharge from the dedicated ICU ward was achieved in two of five patients, both of whom received prednisolone pulse therapy. This means that two of the three patients who received prednisolone pulse therapy were discharged to the general ward, and the two patients without prednisolone pulse therapy did not achieve the outcome. In addition, the two patients who achieved the outcome started PE 6 and 7 days after admission, respectively, which was relatively early compared to the other patients. A brief summary of patient profiles and outcomes is shown in Table 1. The course of each case is described in detail as below.

3.1 | Case 1

Case 1 was a 66-year-old man who was receiving peritoneal dialysis because of an IgA nephropathy. His chief complaints were fever and dyspnea at rest. His chest CT scan showed diffuse ground glass opacities and consolidation on the pleural side of both lungs (Figure 1A). We performed tracheal intubation and administered mPSL (equivalent to 1 mg/kg) to improve his ARDS. In addition, we performed hemoadsorption using PMX-DHP. We also continued CHDF using an AN69ST cytokine-absorbing hemofilter. Because his oxygenation improved, we withdrew the mPSL after 10 days. His oxygenation, however, worsened again on the 14th day in hospital, and we restarted the GCs and performed PE starting on the 17th day in hospital. However, his oxygenation worsened day by day and he died on the 29th day in hospital (Figure 1B).

3.2 | Case 2

Case 2 was a 63-year-old woman with breast cancer who was treated with surgery and radiation therapy. She had a fever and cough, and her chest CT scan showed diffuse ground glass opacities (Figure 2A). She was admitted to our hospital on suspicion of radiation pneumonitis. After

TABLE 1 A brief summary of patient profiles and outcomes

	Case 1	Case 2	Case 3	Case 4	Case 5
Age (years)	66	63	84	76	86
Sex	M	F	M	M	M
Underlying health condition	IgA nephropathy on peritoneal dialysis	Breast cancer	Chronic renal failure on hemodialysis Liver cancer	Diabetes hypertension Prostate cancer	Cerebral infarction Subdural hematoma prostate cancer
Steroid pulse (mPSL 1000 mg/day)	No	No	Yes	Yes	Yes
Maximum daily steroids dose without pulse	mPSL 60 mg	mPSL 50 mg	PSL 60mg	PSL 50mg	PSL 60mg
Other medication	Nafamostat mesilate Hydroxychloroquine Gamma-globulin	Hydroxychloroquine	Remdesivir Favipiravir Ciclesonide	Remdesivir Favipiravir Ciclesonide Gamma-globulin	Favipiravir
Intubation	Yes	Yes	No	Yes	No
Time from onset to admission (days)	Probably 14	7	Probably 7	Probably 11	Probably 2
Time from admission to PE (days)	17	12	11	5	8
Total times of PE	6	3	5	6	7
Other therapeutic apheresis	CHDF PMX-DHP	CHDF PMX-DHP	CHDF		
Outcome (transferred from ICU)	No	No	No	Yes	Yes
Time from admission to outcome (days)	Died on the 29th days	Died on the 18th days	Died on the 38th days	62	40

Abbreviations: CHDF, continuous hemodiafiltration; mPSL, methylprednisolone; PE, plasma exchange; PMX-DHP, polymyxin B-immobilized fiber column direct hemoperfusion; PSL, prednisolone.

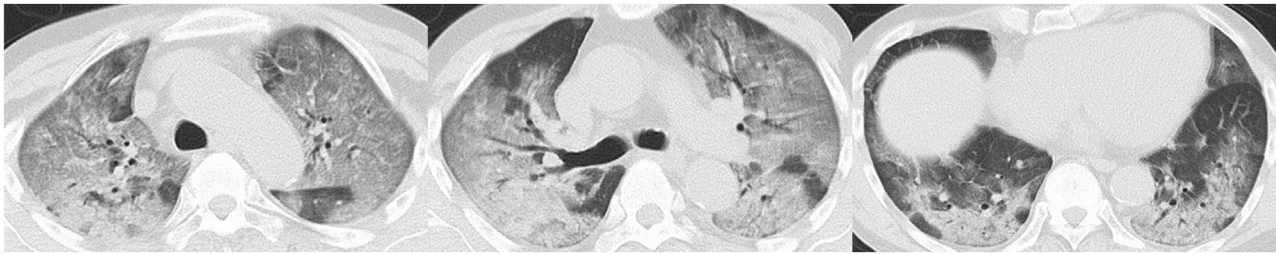admission, it was found that her SARS-CoV-2 PCR test was positive. Because her oxygenation worsened, we performed tracheal intubation and started her on a mPSL (equivalent to 1 mg/kg). We also performed PMX-DHP, and the mPSL was withdrawn on the sixth day in hospital. Her oxygenation worsened, so we continued CHDF using polymethylmethacrylate (PMMA)-based dialysis and performed PE starting on the 12th day in hospital. She died on the 18th day in hospital (Figure 2B).

3.3 | Case 3

Case 3 was an 84-year-old man receiving hemodialysis because of chronic renal failure. He also had a hepatocellular carcinoma and was undergoing radiofrequency

ablation treatment. Two days before admission, he was febrile and subsequently tested positive in a SARS-CoV-2 PCR test. On admission, his chest CT scan showed almost no abnormalities (Figure 3A). Although his oxygenation worsened, he decided of his own free will not to be intubated. We administered intravenous mPSL (1000 mg/day) pulse therapy for 3 days starting on his seventh day in hospital and performed PE twice. In addition, CHDF using PMMA-based dialysis was continued. His oxygenation improved temporarily, but subsequently worsened again. He received his second mPSL pulse therapy for 3 days starting on the 20th day in hospital and then a third mPSL pulse therapy for 3 days starting on the 30th day in hospital; he restarted PE every other day. However, all additional treatments were unsuccessful, and he died on the 38th day in hospital (Figure 3B,C).

(A)



(B)

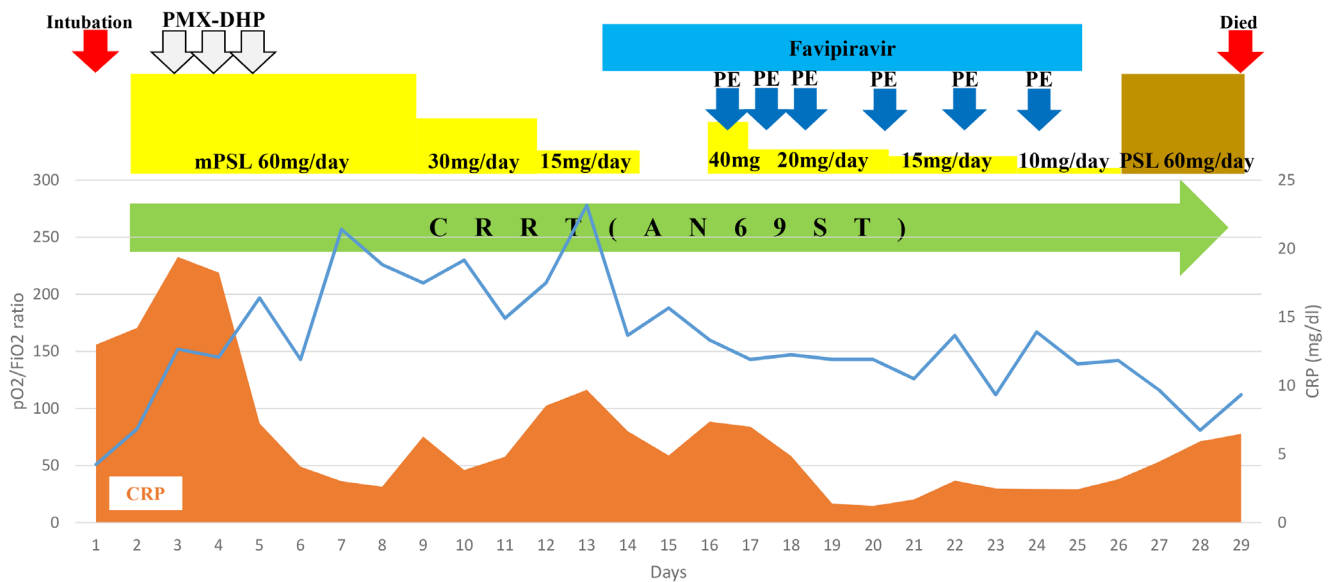


FIGURE 1 Course of hospitalization and chest CT findings in Case 1. (A) Chest CT scans at the time of admission showing diffuse ground glass opacities and consolidation on the pleural side of both lungs. (B) Clinical and treatment course. CRRT, continuous renal replacement therapy; mPSL, methylprednisolone; PE, plasma exchange; PMX-DXP, polymyxin B-immobilized fiber column direct hemoperfusion; pO₂/FiO₂ ratio, partial pressure arterial oxygen and fraction of inspired oxygen [Color figure can be viewed at wileyonlinelibrary.com]

3.4 | Case 4

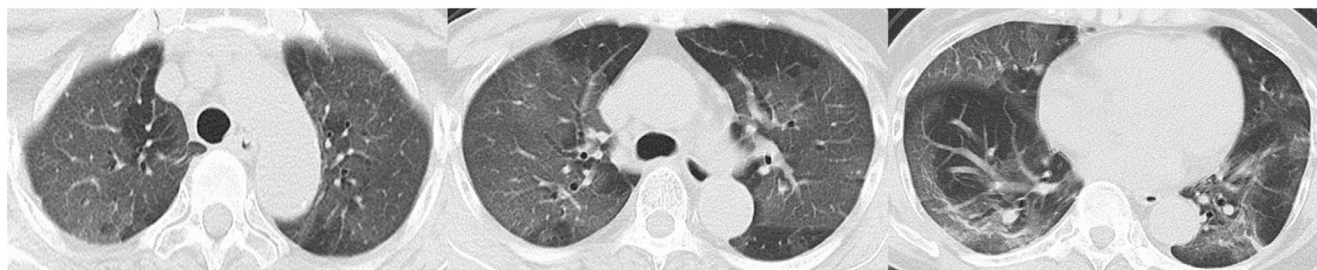Case 4 was a 76-year-old man with a history of diabetes, hypertension, and prostate cancer. His chief complaints were fever, cough, and dyspnea that began 5 days before being admitted. His chest CT scan showed diffuse ground glass opacities on the pleural side of both lungs (Figure 4A). After admission, he tested positive for SARS-CoV-2 PCR test. His oxygenation worsened, and we performed tracheal intubation. We performed PE on the fifth, sixth, seventh, and ninth days in hospital. He was then extubated on the 12th day in hospital. Because his oxygenation worsened again, we performed reintubation on the 19th day in hospital (Figure 4B) and performed PE twice, but his oxygenation did not improve (Figure 4C). We added mPSL pulse therapy (mPSL 1000 mg/day) for 3 days and continued GC treatment with prednisolone (PSL, equivalent to 1 mg/kg) after that. These GC treatments were extremely effective, with his respiratory condition improving

markedly, as shown on his chest CT scans (Figure 5A). We tapered his PSL and withdrew it on the 62nd day in hospital (total GC therapy duration was 37 days). Because he showed severe dysphagia and respiratory muscle weakness, he received a tracheostomy on the 62nd day in hospital and was subsequently transferred to a general ward (Figure 5B).

3.5 | Case 5

Case 5 was an 86-year-old man with a previous cerebral infarction and subdural hematoma, as well as an untreated prostate cancer. He had a fever and had a positive SARS-CoV-2 PCR test. On admission, his chest CT scan showed slightly ground glass opacities (Figure 6A). His oxygenation worsened (Figure 6B) but he decided of his own free will not to be intubated. We performed mPSL pulse therapy for 3 days starting on his fifth day in hospital, and we performed PE seven times. We started

(A)



(B)

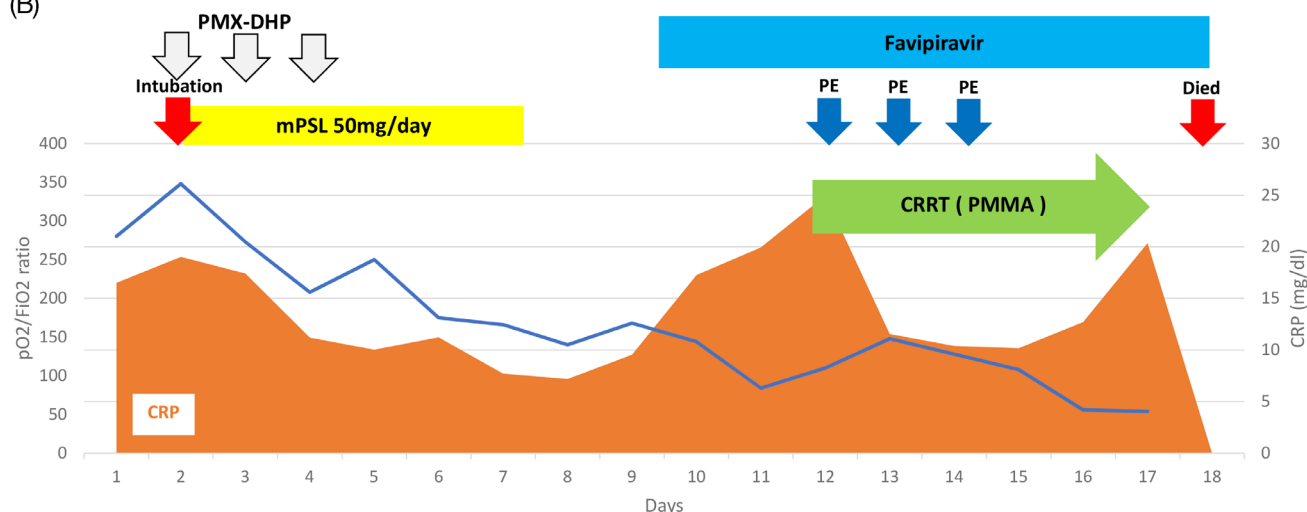


FIGURE 2 Course of hospitalization and chest CT findings in Case 2. (A) Chest CT scans at the time of admission showing diffuse ground glass opacities and consolidation on the pleural side of both lungs. (B) Clinical and treatment course. CRRT, continuous renal replacement therapy; mPSL, methylprednisolone; PE, plasma exchange; PMMA, polymethylmetacrylate; PMX-DXP, polymyxin B-immobilized fiber column direct hemoperfusion; pO₂/FiO₂ ratio, partial pressure arterial oxygen and fraction of inspired oxygen [Color figure can be viewed at wileyonlinelibrary.com]

treatment with daily PSL (equivalent to 1 mg/kg), which was gradually tapered to every 7 days. His oxygenation improved as well as his lungs, as shown on chest CT scans (Figure 6C), and he was discharged on the 46th day in hospital (Figures 6D).

4 | DISCUSSION

Although dexamethasone and remdesivir have been reported to be useful in the treatment of COVID-19 [4,7], it is still reported that even with multidisciplinary treatment, there is a high risk of the condition being fatal in men older than 65 years, and in patients with diabetes, hypertension, and heart disease [8]. So far, numerous reports on the efficacy of PE for severe COVID-19 have been published, including case reports and case series [9–13].

Liu et al. reported that PE was used in 9 of 23 patients admitted to the ICU and a decrease in blood cytokines after PE [14]. Gluck et al. performed five

sessions of PE over 8 days in 10 patients with increased oxygen demand [15]. Ventilated patients also reported an average 78% improvement in PaO₂/FiO₂ ratio, and significant decreases in blood levels of CRP and cytokines. These reports show that PE can remove high molecular weight inflammatory proteins and cytokines that dissolve in a patient's plasma. Although we did not evaluate major cytokines in this study, we found a decrease in CRP and an improvement in PaO₂/FiO₂ ratio after PE in all cases.

Dogan et al. reported that 6 of 53 patients admitted to the ICU with encephalitis symptoms were treated with PE with albumin replacement, and four of the six patients improved in consciousness, mostly after 1–3 sessions [9]. Faqih et al. reported a prospective study of 10 patients who deteriorated within 24 hours of ICU admission. Nine patients survived after 5–7 PEs [16]. Khamis et al., in a study of 31 patients with severe COVID-19, reported a higher extubation rate in 11 patients who underwent PE [17]. They also reported that 28-day mortality was significantly low (0% vs. 35%). Jaiswal et al. reported that

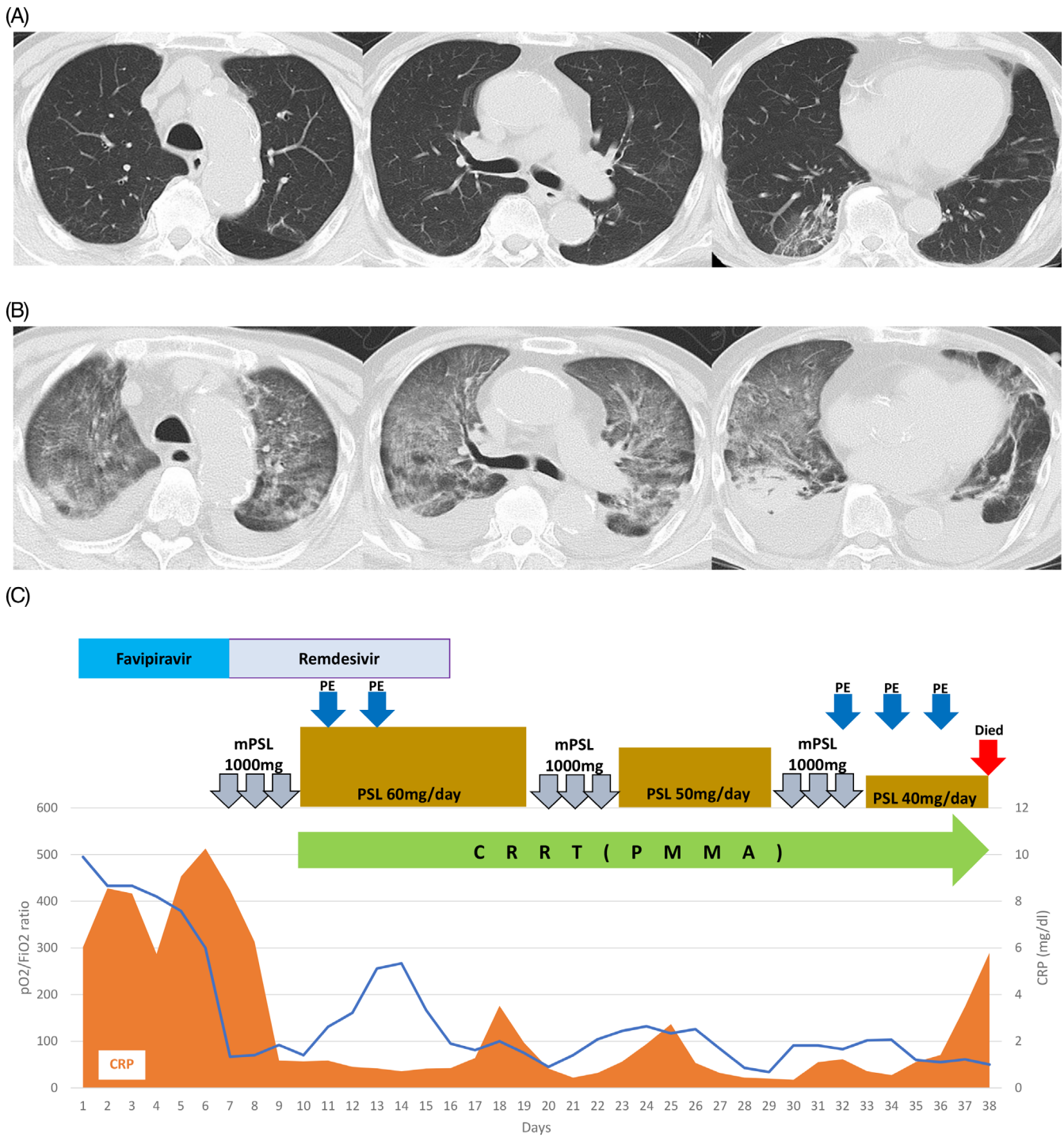
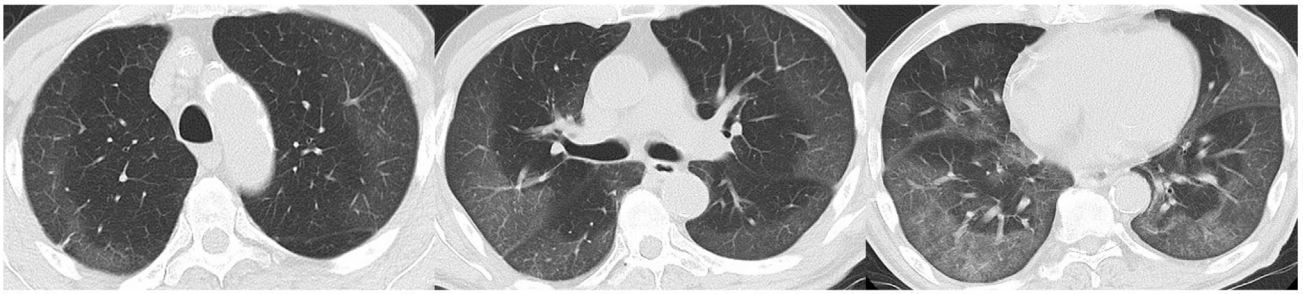


FIGURE 3 Course of hospitalization and chest CT findings in Case 3. (A) Chest CT scans at the time of admission showing few abnormalities. (B) Chest CT scans taken on the 34th day in hospital showing deterioration on both sides of the lung. (C) Clinical and treatment course. CRRT, continuous renal replacement therapy; mPSL, methylprednisolone; PE, plasma exchange; PMMA, polymethylmetacrylate; PMX-DXP, polymyxin B-immobilized fiber column direct hemoperfusion; pO₂/FiO₂ ratio, partial pressure arterial oxygen and fraction of inspired oxygen [Color figure can be viewed at wileyonlinelibrary.com]

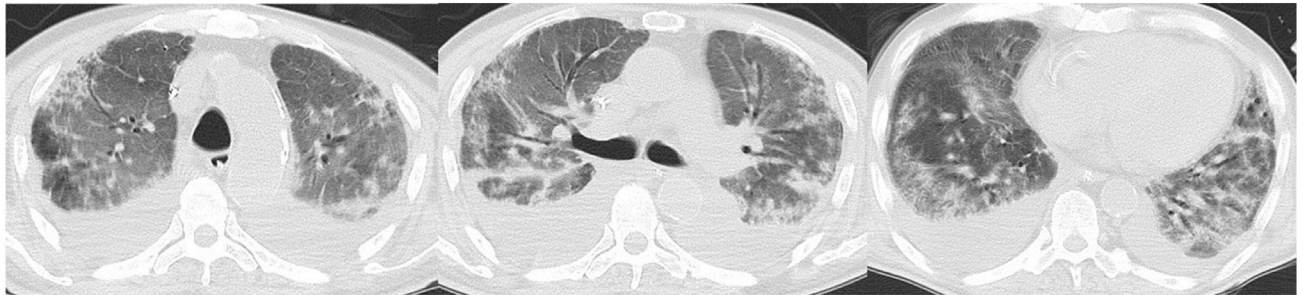14 intubated COVID-19 patients received only one session of PE followed by convalescent plasma [18]. Ten patients were released from the ventilator at a median of 5 days after treatment. 28-day mortality was 21.4% and 28.6%,

respectively. Kamran et al. retrospectively analyzed 280 COVID-19 patients [19]. Seventy-one patients underwent PE and 209 patients did not. Propensity score matching was used to analyze each of the 45 patients with

(A)



(B)



(C)

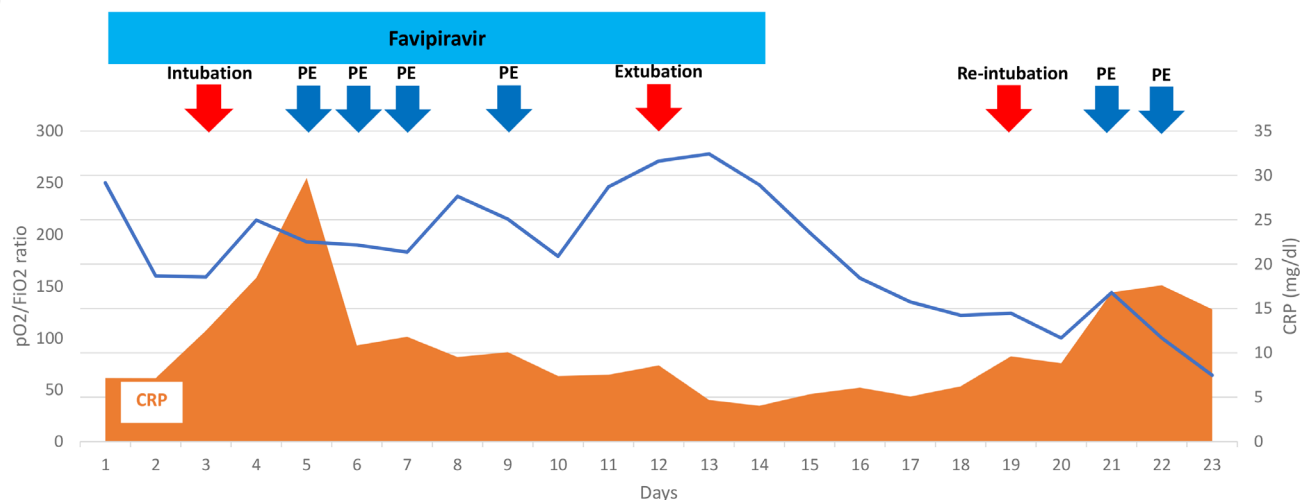


FIGURE 4 Course of hospitalization and chest CT findings in Case 4 (first half). (A) Chest CT scans at the time of admission showing diffuse ground glass opacities on the pleural side of both lungs. (B) Chest CT scans just before reintubation showing marked deterioration of both lungs. (C) Clinical and treatment course of the first half. PE, plasma exchange; pO₂/FiO₂ ratio, partial pressure arterial oxygen and fraction of inspired oxygen [Color figure can be viewed at wileyonlinelibrary.com]

a uniform patient background. The mortality rate was zero in the 43 patients who received PE within the first 12 days, whereas the mortality rate was 17.9% (five deaths) in the other 28 patients. These reports suggest that early PE may contribute to improved survival rate.

Gucyetmez et al. studied 73 patients with COVID-19 in five hospitals, divided into high d-dimer (≥ 2 mg/L) group (53 patients) and low d-dimer group (20 patients) [20]. The high d-dimer group was further divided into two groups: those who received PE (18 patients) and those who did not (35 patients). The median day for the

starting PE was three. Among the high d-dimer group, the mortality rate was 16.7% in the group receiving PE and 45.7% in the group not receiving PE, which was more pronounced after propensity score matching (8.3% and 58.3%, respectively). In COVID-19 patients, it has been known that abnormal blood coagulation occurs because of damage to vascular endothelial cells and an abnormal coagulation system, and prevention of thrombosis using anticoagulation therapy determines prognosis [21–23]. This report suggests that correcting the coagulation system to a normal state and removing substances that

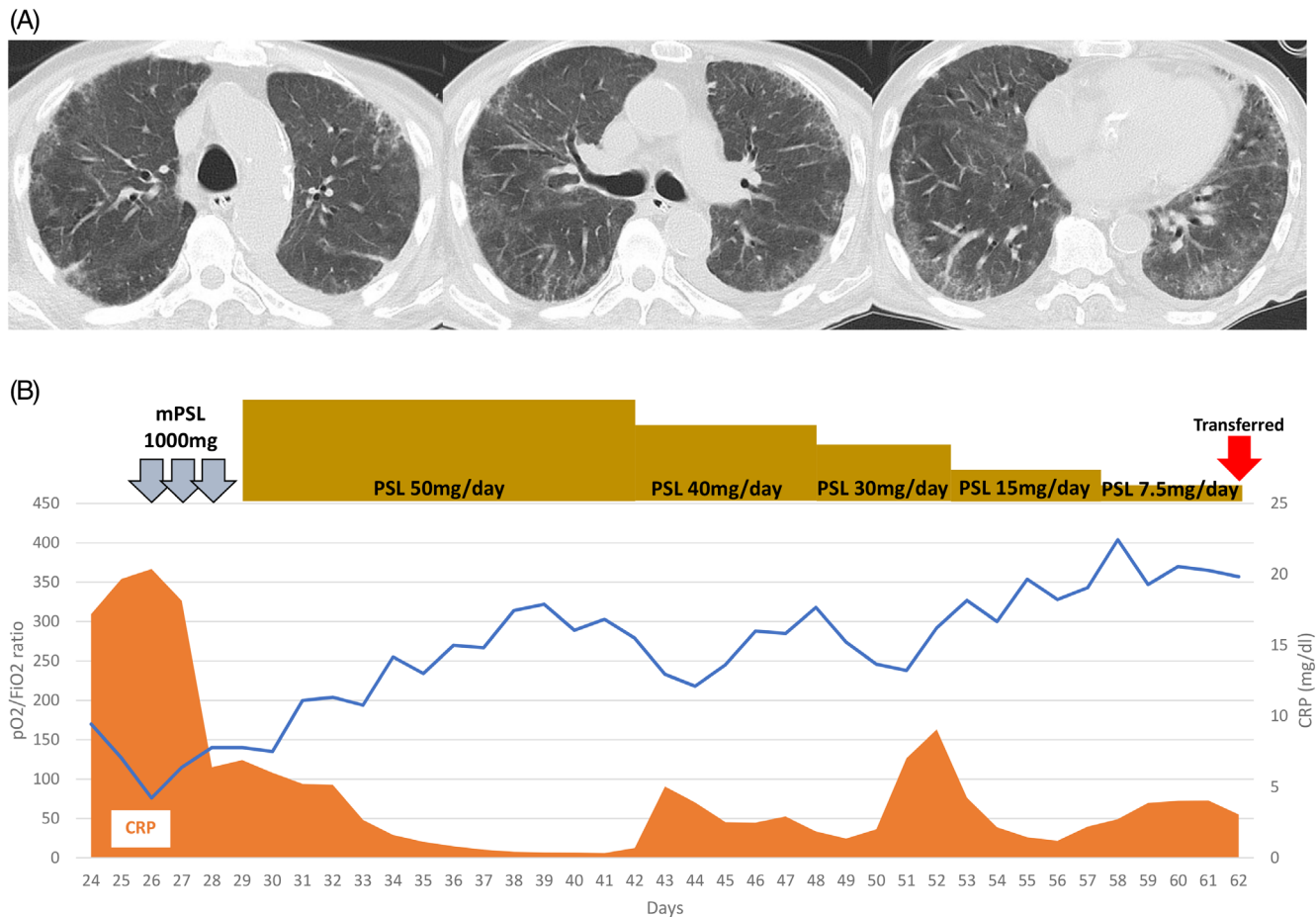


FIGURE 5 Course of hospitalization and chest CT findings in Case 4 (second half). (A) Chest CT scans on the 62nd day in hospital showing improvement in both lungs. (B) Clinical and treatment course of the second half. PE, plasma exchange; pO₂/FiO₂ ratio, partial pressure arterial oxygen and fraction of inspired oxygen [Color figure can be viewed at wileyonlinelibrary.com]

cause excessive inflammation by performing apheresis may be an effective treatment.

Thus, these reports show that the efficacy of PE in patients with severe COVID-19, and the efficacy seems to be higher when the treatment is administered early after an exacerbation. In addition, the possibility of directly removing SARS-CoV-2 from the bloodstream by apheresis has been speculated [24]. Further investigation is needed to determine why PE is shown to be effective in the treatment of severe COVID-19 and what characteristics of patients should be treated with PE. Furthermore, the results of a prospective randomized controlled trial, which is currently underway to provide evidence for the efficacy of PE, are also awaited [25–30].

The efficacy of continuous renal replacement therapy in patients with acute kidney injury and hypercytokinemia has also been reported [31]; however, results have been inconsistent. Similarly, in our observation, the efficacy of CHDF and PMX-DHP has not been clearly demonstrated. In Case 1 and 3, CHDF was performed during hospitalization because of chronic renal failure,

and in Case 2, blood purification with PMMA membrane was performed to adsorb cytokines as part of multidisciplinary treatment, but the improvement in oxygen demand was not clear. We also performed one to three sessions of PMX-DHP as part of our multidisciplinary treatment. There are some reports that PMX-DHP was effective in treating severe COVID-19 [32–34], but further investigation is needed. In this observation, two patients who were able to be transferred from the COVID-19 ICU to the general ward both showed a rapidly increasing oxygen demand and exacerbation on chest CT within a few days after admission. However, early treatment (within 8 days after admission) with multidisciplinary therapy combining steroid pulse therapy and PE improved the condition and reduced the oxygen demand.

The use of GCs against ARDS in COVID-19 has been controversial, and the World Health Organization did not initially recommend its use. In contrast, some studies suggested that GCs were effective [35], and COVID-19's Surviving Sepsis Campaign Guidelines somewhat recommended it for severe cases [36]. Currently, the

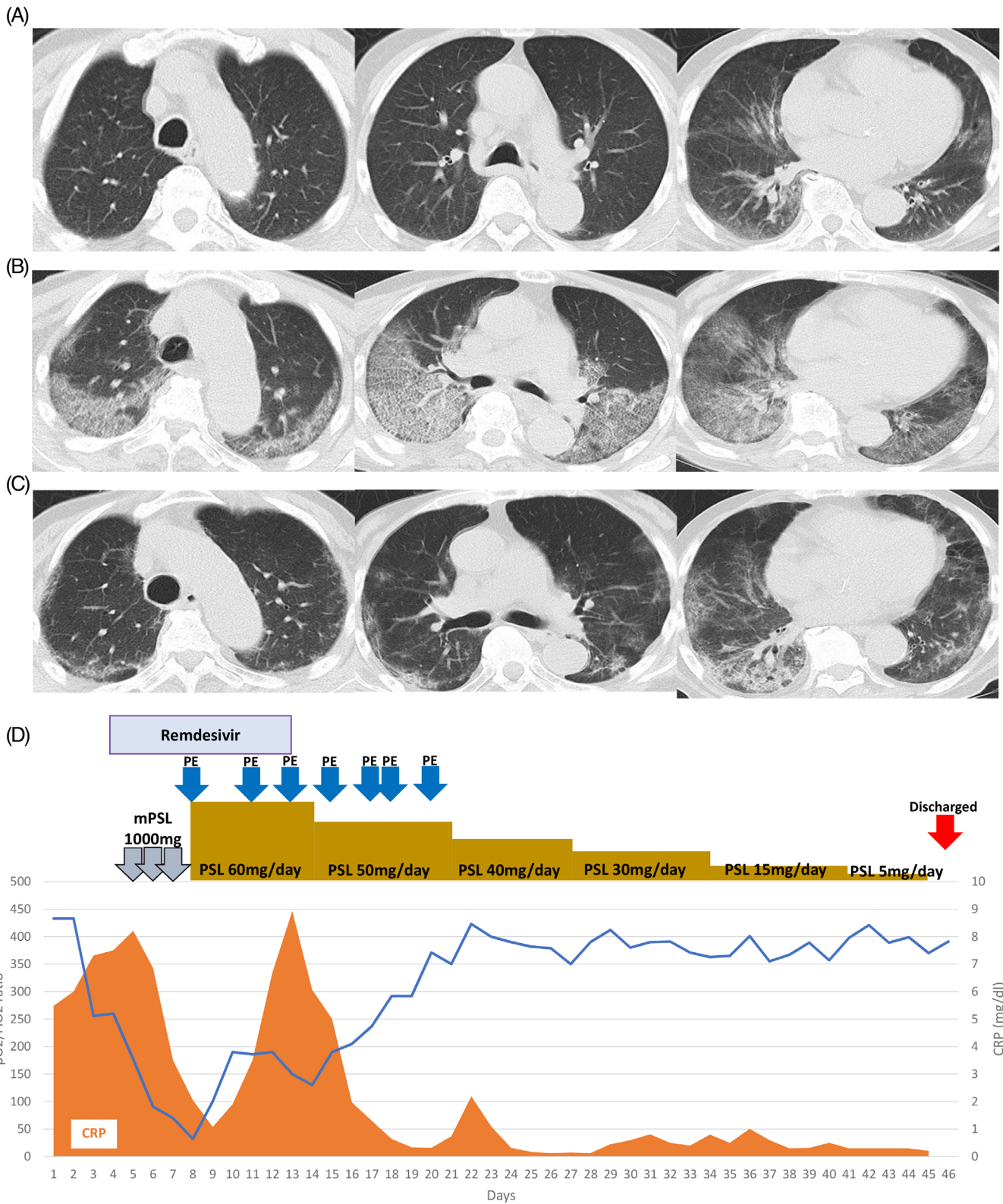


FIGURE 6 Course of hospitalization and chest CT findings in Case 5. (A) Chest CT scans at the time of admission showing slight ground glass opacities in both lungs. (B) Chest CT scans taken on the seventh day in hospital showing deterioration on both sides of the lung. (C) Chest CT scans taken on the 35th day in hospital showing improvement. (D) Clinical and treatment course. mPSL, methylprednisolone; PE, plasma exchange; pO₂/FiO₂ ratio, partial pressure arterial oxygen and fraction of inspired oxygen [Color figure can be viewed at wileyonlinelibrary.com]

effectiveness of GCs has been demonstrated [4], and it has become the standard treatment worldwide. As of December 2020, however, there are no randomized controlled trials comparing GC types, doses, and durations. In this study, all survivors were over 70 years old, which was older than patients in the recovery trial [4]. Our retrospective, single-center, small case study suggests that the combination of GC including steroid pulse therapy and membrane-based PE administered at an early and appropriate time may be effective even in severe cases in elderly COVID-19 patients who have a history of hypertension, diabetes, and cerebrovascular disease.

ACKNOWLEDGMENTS

We thank COVID team, Juntendo University Hospital. We are grateful to the Japanese rock band GLAY who donated funds to this research. We also thank Mark Abramovitz, Ph.D., from Edanz Group (<https://en-author-services.edanz.com/ac>) for editing a draft of this manuscript.

CONFLICT OF INTEREST

The authors declare no potential conflict of interest.

REFERENCES

1. Wu Z, McGoogan JM. Characteristics of and important lessons from the coronavirus disease 2019 (COVID-19) outbreak in China: summary of a report of 72 314 cases from the Chinese Center for Disease Control and Prevention. *JAMA*. 2020;323(13):1239–42.
2. Huang C, Wang Y, Li X, Ren L, Zhao J, Hu Y, et al. Clinical features of patients infected with 2019 novel coronavirus in Wuhan, China. *Lancet*. 2020;395(10223):497–506.
3. Chen N, Zhou M, Dong X, Qu J, Gong F, Han Y, et al. Epidemiological and clinical characteristics of 99 cases of 2019 novel coronavirus pneumonia in Wuhan, China: a descriptive study. *Lancet*. 2020;395(10223):507–13.
4. Horby P, Lim WS, Emberson JR, Mafham M, Bell JL, Linsell L, et al. Dexamethasone in hospitalized patients with Covid-19 - preliminary report. *N Engl J Med*. 2020;384(8):693–704.
5. Barnes BJ, Adrover JM, Baxter-Stoltzfus A, Borczuk A, Cools-Lartigue J, Crawford JM, et al. Targeting potential drivers of COVID-19: neutrophil extracellular traps. *J Exp Med*. 2020;217(6):e20200652.
6. Liu X, Zhang Y, Xu X, du W, Su K, Zhu C, et al. Evaluation of plasma exchange and continuous veno-venous hemofiltration for the treatment of severe avian influenza A (H7N9): a cohort study. *Ther Apher Dial*. 2015;19(2):178–84.
7. Beigel JH, Tomashek KM, Dodd LE, Mehta AK, Zingman BS, Kalil AC, et al. Remdesivir for the treatment of Covid-19 - final report. *N Engl J Med*. 2020;383(19):1813–26.
8. Zheng Z, Peng F, Xu B, Zhao J, Liu H, Peng J, et al. Risk factors of critical & mortal COVID-19 cases: a systematic literature review and meta-analysis. *J Infect*. 2020;81(2):e16–25.
9. Dogan L, Kaya D, Sarikaya T, Zengin R, Dincer A, Akinci IO, et al. Plasmapheresis treatment in COVID-19-related autoimmune meningoencephalitis: case series. *Brain Behav Immun*. 2020;87:155–8.
10. Zhang L, Zhai H, Ma S, Chen J, Gao Y. Efficacy of therapeutic plasma exchange in severe COVID-19 patients. *Br J Haematol*. 2020;190(4):e181–3.
11. Morath C, Weigand MA, Zeier M, Speer C, Tiwari-Heckler S, Merle U. Plasma exchange in critically ill COVID-19 patients. *Crit Care*. 2020;24(1):481.
12. Truong AD, Auld SC, Barker NA, et al. Therapeutic plasma exchange for COVID-19-associated hyperviscosity. *Transfusion*. 2020;61(4):1029–1034. <https://doi.org/10.1111/trf.16218>.
13. Arulkumaran N, Thomas M, Brealey D, et al. Plasma exchange for COVID-19 thrombo-inflammatory disease. *EJHaem*. 2020;10:1002. <https://doi.org/10.1002/jha2.140>.
14. Liu J, Dong YQ, Yin J, He G, Wu X, Li J, et al. Critically ill patients with COVID-19 with ECMO and artificial liver plasma exchange: a retrospective study. *Medicine*. 2020;99(26):e21012.
15. Gluck WL, Callahan SP, Brevetta RA, Stenbit AE, Smith WM, Martin JC, et al. Efficacy of therapeutic plasma exchange in the treatment of penn class 3 and 4 cytokine release syndrome complicating COVID-19. *Respir Med*. 2020;175:106188.
16. Faqih F, Alharthy A, Alodat M, Kutsogiannis DJ, Brindley PG, Karakitsos D. Therapeutic plasma exchange in adult critically ill patients with life-threatening SARS-CoV-2 disease: a pilot study. *J Crit Care*. 2020;60:328–33.
17. Khamis F, Al-Zakwani I, Hashmi SA, et al. Therapeutic plasma exchange in adults with severe COVID-19 infection. *Int J Infect Dis*. 2020;99:214–8.
18. Jaiswal V, Nasa P, Raouf M, Gupta M, Dewedar H, Mohammad H, et al. Therapeutic plasma exchange followed by convalescent plasma transfusion in critical COVID-19—an exploratory study. *Int J Infect Dis*. 2021;102:332–4.
19. Kamran SM, Mirza ZEH, Naseem A, Liaqat J, Fazal I, Alamgir W, et al. Therapeutic plasma exchange for coronavirus disease-2019 triggered cytokine release syndrome; a retrospective propensity matched control study. *PLoS One*. 2021;16(1):e0244853.
20. Gucyetmez B, Atalan HK, Sertdemir I, et al. Therapeutic plasma exchange in patients with COVID-19 pneumonia in intensive care unit: a retrospective study. *Crit Care*. 2020;24(1):492.
21. Klok FA, Kruip MJHA, van der Meer NJM, Arbous MS, Gommers DAMPJ, Kant KM, et al. Incidence of thrombotic complications in critically ill ICU patients with COVID-19. *Thromb Res*. 2020;191:145–7.
22. Klok FA, Kruip MJHA, van der Meer NJM, Arbous MS, Gommers D, Kant KM, et al. Confirmation of the high cumulative incidence of thrombotic complications in critically ill ICU patients with COVID-19: an updated analysis. *Thromb Res*. 2020;191:148–50.
23. Llitjos JF, Leclerc M, Chochois C, Monsallier JM, Ramakers M, Auvray M, et al. High incidence of venous thromboembolic events in anticoagulated severe COVID-19 patients. *J Thromb Haemost*. 2020;18(7):1743–6.
24. Turgutkaya A, Yavaşoğlu İ, Bolaman Z. Application of plasmapheresis for Covid-19 patients. *Ther Apher Dial*. 2020;25(2):248–249. <https://doi.org/10.1111/1744-9987.13536>.
25. Daoud AM, Soliman KM, Ali HK. Potential limitations of plasmapheresis in treatment of COVID-19 patients: how to overcome them? *Ther Apher Dial*. 2020; [Online ahead of print].

26. ClinicalTrials.gov. Therapeutic plasma exchange as an adjunctive strategy to treat coagulopathy and inflammation in severe Covid-19 (PEXCoV). <https://www.clinicaltrials.gov/ct2/show/NCT04613986>. Accessed 17 Jan 2021.
27. ClinicalTrials.gov. Therapeutic plasma exchange for COVID-19-associated hyperviscosity. <https://www.clinicaltrials.gov/ct2/show/NCT04441996>. Accessed 17 Jan 2021.
28. ClinicalTrials.gov. Plasma exchange in patients with COVID-19 disease and invasive mechanical ventilation: a randomized controlled trial (REP-COVID). <https://www.clinicaltrials.gov/ct2/show/NCT04374539>. Accessed 17 Jan 2021.
29. ClinicalTrials.gov. Randomised study of plasma exchange in severe COVID-19 (COVIPLEX). <https://www.clinicaltrials.gov/ct2/show/NCT04623255>. Accessed 17 Jan 2021.
30. ClinicalTrials.gov. RescuE pLAsma eXchange in severe COVID-19 (RELAX). <https://www.clinicaltrials.gov/ct2/show/NCT04685655>. Accessed 17 Jan 2021.
31. Shareef KA, Bakouri M. Cytokine blood filtration responses in COVID-19. *Blood Purif.* 2020;50(2):141–149.
32. Kusaba Y, Izumi S, Takasaki J, Suzuki M, Katagiri D, Katsuno T, et al. Successful recovery from COVID-19-associated acute respiratory failure with polymyxin B-immobilized fiber column-direct hemoperfusion. *Intern Med.* 2020;59(19):2405–8.
33. Ishiwari M, Togashi Y, Takoi H, Kikuchi R, Kono Y, Abe S. Polymyxin B haemoperfusion treatment for respiratory failure and hyperferritinaemia due to COVID-19. *Respirol Case Rep.* 2020;8(9):e00679.
34. Rosa SD, Cutuli SL, Ferrer R, et al. Polymyxin B hemoperfusion in COVID-19 patients with endotoxic shock: case series from EUPHAS II registry. *Artif Organs.* 2020. <https://doi.org/10.1111/aor.13900> [Online ahead of print].
35. Wu C, Chen X, Cai Y, Xia J', Zhou X, Xu S, et al. Risk factors associated with acute respiratory distress syndrome and death in patients with coronavirus disease 2019 pneumonia in Wuhan, China. *JAMA Intern Med.* 2020;180(7):934–43.
36. Alhazzani W, Møller MH, Arabi YM, Loeb M, Gong MN, Fan E, et al. Surviving sepsis campaign: guidelines on the management of critically ill adults with coronavirus disease 2019 (COVID-19). *Crit Care Med.* 2020;48(6):e440–69.

How to cite this article: Matsushita Y, Kusaoi M, Hiki M, et al. Combination therapy with plasma exchange and glucocorticoid may be effective for severe COVID-19 infection: A retrospective observational study. *Ther Apher Dial.* 2021;25: 390–400. <https://doi.org/10.1111/1744-9987.13656>