

## **Ocular MRI Findings in Patients with Severe COVID-19: A Retrospective Multicenter Observational Study**

**Manuscript type:** Original Research

Augustin Lecler, MD, PhD<sup>1</sup>, François Cotton, MD, PhD<sup>2</sup>, François Lersy, MD<sup>3</sup>, Stéphane Kremer, MD, PhD<sup>3</sup>, Françoise Héran, MD<sup>1</sup> on behalf of the SFNR's COVID Study Group.

1. Department of Neuroradiology, Rothschild Foundation Hospital, Paris, France
2. Department of Neuroradiology, CHU Lyon, Lyon, France
3. Department of Neuroradiology, CHU Strasbourg, Strasbourg, France

### **Corresponding author:**

Augustin Lecler, MD, PhD

Department of Neuroradiology, Rothschild Foundation Hospital

25 rue Manin, 75019 Paris, France

E-mail: [alecler@for.paris](mailto:alecler@for.paris)

Financial Support:

None

Presentation to a RSNA meeting:

No

## **Keywords**

- MRI
- Orbit
- COVID-19
- SARS-CoV-2

## **Abbreviations and Acronyms:**

- MRI: Magnetic Resonance Imaging
- SARS-CoV-2: Severe Acute Respiratory Syndrome CoronaVirus 2
- OCT: Optical Coherence Tomography
- FLAIR: Fluid-attenuated inversion recovery
- RT-PCR: Reverse transcriptase-polymerase chain reaction

See also the editorial by Kirsch.

## **ABSTRACT**

COVID-19 may affect various organs. This paper reports 9 patients (1/9 [11%] woman and 8/9 [89%] men, mean age  $56 \pm 13$  years) with globe MRI abnormalities obtained from a multicenter cohort of 129 patients presenting with severe COVID-19 from March 4th to May 1st, 2020. 9/129 (7%) patients had one or several FLAIR-WI hyperintense nodules of the posterior pole of the globe. All patients had nodules in the macular region, 8/9 (89%) had bilateral nodules, 2/9 (22%) had nodules outside the macular region. Screening of these patients might improve the management of potentially severe ophthalmological manifestations of the virus.

## **INTRODUCTION**

COVID-19 is a pandemic infection caused by severe acute respiratory syndrome coronavirus 2 (SARS-CoV-2), negatively affecting various organs such as the central nervous system(1,2).

COVID-19 has been reported to be associated with ophthalmological abnormalities, such as conjunctivitis, chemosis, retinopathy or optic neuritis(3–7). MRI orbital abnormalities have been reported but no MRI studies have been published about globe abnormalities to the best of our knowledge(8–10).

This paper reports a series of patients with severe COVID-19 presenting with abnormal MRI findings of the globe.

## **MATERIAL AND METHODS**

### **Study design and population**

This retrospective observational multicenter study was initiated by the French Society of Neuroradiology (SFNR). It included clinical and imaging data of consecutive patients presenting with severe COVID-19 who underwent brain MRI from 16 hospitals including 11 university hospitals and 5 general hospitals from March 4<sup>th</sup> to May 1<sup>st</sup> 2020. The study was approved by the ethical committee of Strasbourg University Hospital (CE-2020-37)

### **Clinical, ophthalmological, virological and imaging data**

Clinical and ophthalmological data were extracted from the patients' electronic medical records. Virological assessment was made with quantitative real-time RT-PCR tests for SARS-CoV-2 nucleic acid performed on nasopharyngeal or lower respiratory tract swabs and cerebrospinal fluid. Imaging studies were conducted either on 1.5- or 3-Tesla MRI.

### **MRI Analysis**

MRI examinations were anonymized and analyzed by two neuroradiologists with 9 years ("blinded") and 30 years ("blinded") of experience in ophthalmological imaging.

## **RESULTS**

### **Study Population**

A total of 129 patients (43/129 [33%] women and 86/129 [67%] men, mean age  $63 \pm 14$  years) was included for analysis from March 4<sup>th</sup> to May 1<sup>st</sup> 2020 (Figure 1). Among them, 9/129 (7%) patients (1/9 [11%] woman and 8/9 [89%] men, mean age  $56 \pm 13$  years) had abnormal MRI findings of the globe consisting in the presence of one or several nodules of the posterior pole of the globe. 2/9 (22%) patients had diabetes, 6/9 (67%) were obese, 2/9 (22%) had hypertension and none of them had asthma.

8/9 (89%) patients were hospitalized in intensive care unit (ICU) with severe COVID. All ICU patients presented with acute respiratory distress syndrome, with a median Simplified Acute Physiology Score (SAPS II) of 45 (IQR 18.5). All ICU patients were intubated on high-flow supplementary oxygen, curarized and sedated. 7/9 (78%) patients were placed in the prone position. 1/9 (11%) was placed on extracorporeal membrane oxygenation. 3/9 (33%) patients were put on dialysis. Median duration of hospitalization in ICU was of 17 (IQR 7] days.

6/9 (67%) patients underwent brain MRI due to delayed awakening despite discontinuation of sedation, 2/9 (22%) due to persisting agitation and confusion after awakening and 1/9 (11%) for agitation and hallucinations.

### **MRI findings**

The nodules of the posterior pole of the globe were all hyperintense on FLAIR-WI, isointense on T1-WI and showed no enhancement after gadolinium injection. No abnormal susceptibility was seen on susceptibility-weighted images. All 9/9 (100%) patients had nodules in the macular region, 8/9 (89%) had bilateral nodules, 2/9 (22%) had nodules outside the macular region (figure 2).

2/9 (22%) patients had diffuse extensive white matter hyperintense lesions on FLAIR-WI, with restricted diffusion, without post-contrast enhancement and disseminated multiple microhemorrhages on SWI. 2/9 (22%) had diffuse non-confluent multifocal white matter hyperintense lesions on FLAIR-WI without restricted diffusion nor post-contrast enhancement. 1/9 (11%) had multiple infarcts in the anterior cerebral artery territory. 1/9 (11%) had a frontal hematoma. 1/9 (11%) had multiple microhemorrhages of the splenium of the corpus callosum. 1/9 (11%) had leptomeningeal enhancement without parenchymal abnormalities. Brain MRI was unremarkable for 1/9 (11%) patient. 5/9 (56%) patients had bilateral fluid filling of the mastoid cells. No patient had optic nerve, optic chiasm or optic tract abnormalities.

#### **Correlations between MRI and ophthalmological findings**

3/9 (33%) patients had a fundoscopy showing no abnormality of the posterior pole. 1/9 (11%) had an OCT showing no abnormality. 1/9 (11%) had an occlusion of a central retinal artery branch on fluorescein angiography. 1/9 (11%) presented with keratitis of the left eye.

## DISCUSSION

This paper reports a series of patients with severe COVID-19 presenting with abnormal MRI findings of the globe. This study showed that 7% of patients with severe COVID-19 presented with one or several nodules of the posterior pole of the globe. This rate is in line with the prevalence of 5.5% of ocular manifestations among COVID-19 patients reported in a recent meta-analysis(3). Patients affected by severe COVID-19 were reported to be more at-risk to develop ocular manifestations (4,11,12).

Nodules were mostly bilateral and were located in the macular region in all cases, in association with extra-macular nodules in 22% of the cases. These nodules were not visible in the 3 patients who underwent ophthalmological examination. This might be due to a lack of sensitivity of the clinical examination, which was difficult to perform in patients with severe COVID-19 or to the delay between the completion of the MRI examination and the ophthalmological examination.

No retinal involvement could be detected on fundoscopy in a single retrospective series of severe COVID-19 patients(13). However, viral RNA of SARS-CoV-2 has been reported to be detectable in the retina of deceased COVID-19 patients. Moreover, three recent reports showed that retinal findings, such as hemorrhages, cotton wool spots, dilated veins, or tortuous vessels, could be possibly associated with COVID-19 infection in humans(14–16).

Two studies displayed findings from the OCT, which is a more sensitive tool than fundoscopy(14,15). They reported hyper-reflective lesions at the level of ganglion cell and inner plexiform layers on OCT, as well as the presence of cotton wool exudates which are markers of vascular disease severity. Interestingly, these abnormalities were more prominent at the papillomacular bundle in both eyes, which was also the preferential location for the nodules visible on MRI in our study. Only one of our patients with a macular nodule underwent OCT, showing no abnormal findings.



Although the nature of these nodules remains unknown, several hypotheses might be considered since human and animal coronaviruses were reported to cause inflammation of varying ocular segments, causing retinitis, choroiditis, retinal detachment or optic neuritis in the literature(17,18). A wide variety of mechanisms have been described, such as direct infiltration of the retina and retina pigment epithelium by the virus, vasculitis, or autoimmune process, the latter mechanism being more frequent to explain retinal damages(17). The onset of an ocular microangiopathic syndrome is highly prevalent after viral infections. SARS-Cov-2 is known to target the angiotensin-converting enzyme-related carboxypeptidase (ACE2) receptor, which is largely expressed in the retina and the choroid. ACE2 is the primary enzyme of the vasoprotective axis of the renin–angiotensin system in the retina(19). Its downregulation might induce the development of retinal ischemia(15). Another possible hypothesis is a Valsalva retinopathy secondary to orbital proptosis which can occur when the ocular venous system is affected by the increased central venous pressure, leading to an inadequate ocular venous drainage. This situation can occur in patients hospitalized in intensive care units, especially those in the prone position or intubated, which was the case for almost all our patients with severe COVID-19(20,21).

In clinical practice, our study suggests that a dedicated exploration of the globes with high resolution 3D T2-WI and post-contrast fat-suppressed T1-WI MRI, as well as fundoscopy and OCT, should be considered in all patients presenting with severe COVID-19 to detect posterior pole nodules. Severe eye problems might largely go unnoticed as these patients are often treated in intensive care units for much more severe, life-threatening conditions. Our data support the need for a screening and follow-up of these patients to provide appropriate treatment and improve the management of potentially severe ophthalmological manifestations.

Our study suffers from several limitations. Firstly, it is a retrospective study with a limited number of patients and no control group. Secondly, we analyzed ocular abnormalities on brain MRI performed in patients with severe COVID infections. Dedicated ocular MRI sequences, especially high-resolution MRI sequences, were not available, preventing a precise description and understanding of ocular abnormalities. Thirdly, ophthalmological data were missing for the majority of our patients, because no systematic ophthalmological examination was performed in our patients with severe COVID-19 hospitalized in intensive care unit, thus clinical-radiological correlations were limited. Fourthly, no ocular or conjunctival sampling for detection of SARS-CoV-2 was available, thus it is impossible to assess the direct causality of the virus in our findings. We do not know whether a high viral load was linked to more severe ophthalmological findings. Fifthly, pathologic material was lacking. Finally, we lacked follow-up data to assess whether the MRI abnormalities were transient or not and their consequences on visual acuity.

## **CONCLUSION**

This paper reports a series of patients with severe COVID-19 presenting with abnormal MRI findings of the globe. Screening of these patients might be suitable to provide appropriate treatment and improve the management of potentially severe ophthalmological manifestations.

## **ACKNOWLEDGEMENT**

Laura McMaster provided professional English-language medical editing of this article.

in press

## SFNR's COVID Study Group

<b>Center</b>	<b>Name</b>	<b>Surname</b>	<b>Email</b>
CHU de Strasbourg	Helms	Julie	<a href="mailto:julie.helms@chru-strasbourg.fr">julie.helms@chru-strasbourg.fr</a>
	Meziani	Ferhat	<a href="mailto:ferhat.meziani@chru-strasbourg.fr">ferhat.meziani@chru-strasbourg.fr</a>
	Collange	Olivier	<a href="mailto:olivier.collange@chru-strasbourg.fr">olivier.collange@chru-strasbourg.fr</a>
	Mertes	Paul Michel	<a href="mailto:paul-michel.mertes@chru-strasbourg.fr">paul-michel.mertes@chru-strasbourg.fr</a>
	Fafi-Kremer	Samira	<a href="mailto:samira.fafi-kremer@unistra.fr">samira.fafi-kremer@unistra.fr</a>
	Lefebvre	Nicolas	<a href="mailto:nicolas.lefebvre@chru-strasbourg.fr">nicolas.lefebvre@chru-strasbourg.fr</a>
	Hansmann	Yves	<a href="mailto:yves.hansmann@chru-strasbourg.fr">yves.hansmann@chru-strasbourg.fr</a>
	Pottecher	Julien	<a href="mailto:julien.pottecher@chru-strasbourg.fr">julien.pottecher@chru-strasbourg.fr</a>
	Schenck	Maleka	<a href="mailto:maleka.schenck@chru-strasbourg.fr">maleka.schenck@chru-strasbourg.fr</a>
	Francis Schneider	Francis	<a href="mailto:francis.schneider@chru-strasbourg.fr">francis.schneider@chru-strasbourg.fr</a>
CHU de Toulouse	Bonneville	Fabrice	<a href="mailto:bonneville.f@chu-toulouse.fr">bonneville.f@chu-toulouse.fr</a>
	Adam	Gilles	<a href="mailto:adam.g@chu-toulouse.fr">adam.g@chu-toulouse.fr</a>
	Martin-Blondel	Guillaume	<a href="mailto:martin-blondel.g@chu-toulouse.fr">martin-blondel.g@chu-toulouse.fr</a>
	Pariente	Jérémie	<a href="mailto:pariente.j@chu-toulouse.fr">pariente.j@chu-toulouse.fr</a>
	Geeraerts	Thomas	<a href="mailto:geeraerts.t@chu-toulouse.fr">geeraerts.t@chu-toulouse.fr</a>
CHU de Rennes	Ferré	Jean-Christophe	<a href="mailto:jean-christophe.ferre@chu-rennes.fr">jean-christophe.ferre@chu-rennes.fr</a>
	Maamar	Adel	<a href="mailto:Adel.MAAMAR@chu-rennes.fr">Adel.MAAMAR@chu-rennes.fr</a>
	Carsin-Nicol	Béatrice	<a href="mailto:beatrice.carsin-nicol@chu-rennes.fr">beatrice.carsin-nicol@chu-rennes.fr</a>
CH Louis Pasteur Colmar	Oesterlé	Hélène	<a href="mailto:helene.oesterle@ch-colmar.fr">helene.oesterle@ch-colmar.fr</a>
	Bolognini	Federico	<a href="mailto:federico.bolognini@ch-colmar.fr">federico.bolognini@ch-colmar.fr</a>
	Messie	Julien	<a href="mailto:julien.messie@ch-colmar.fr">julien.messie@ch-colmar.fr</a>
CH Sainte Anne Paris	Hmeydia	Ghazi	<a href="mailto:g.hmeydia@ghu-paris.fr">g.hmeydia@ghu-paris.fr</a>
	Benzakoun	Joseph	<a href="mailto:j.benzakoun@ghu-paris.fr">j.benzakoun@ghu-paris.fr</a>
	Oppenheim	Catherine	<a href="mailto:c.oppenheim@ghu-paris.fr">c.oppenheim@ghu-paris.fr</a>
CHU d'Amiens	Constans	Jean-Marc	<a href="mailto:constans.jean-marc@chu-amiens.fr">constans.jean-marc@chu-amiens.fr</a>
	Metanbou	Serge	<a href="mailto:Metanbou.Serge@chu-amiens.fr">Metanbou.Serge@chu-amiens.fr</a>
	Heintz	Adrien	<a href="mailto:heintz.adrien@gmail.com">heintz.adrien@gmail.com</a>
CHU Henri-Mondor Créteil	Bapst	Blanche	<a href="mailto:blanchebapst@hotmail.com">blanchebapst@hotmail.com</a>
	Megdiche	Imen	<a href="mailto:imen.megdiche@aphp.fr">imen.megdiche@aphp.fr</a>
CHU Bichat Paris	Marie- Cécile Feugeas	Marie- Cécile	<a href="mailto:marie-cecile.henry-feugeas@aphp.fr">marie-cecile.henry-feugeas@aphp.fr</a>
	Henri Feugeas	Henri Feugeas	<a href="mailto:feugeas@aphp.fr">feugeas@aphp.fr</a>
	Khalil	Antoine	<a href="mailto:antoine.khalil@aphp.fr">antoine.khalil@aphp.fr</a>
CHIC Unisanté Forbach	Gaudemer	Augustin	<a href="mailto:augustingaudemer@gmail.com">augustingaudemer@gmail.com</a>
	Jager	Lavinia	<a href="mailto:lavinia.gabriela.jager@unisanté.fr">lavinia.gabriela.jager@unisanté.fr</a>
	Nesser	Patrick	<a href="mailto:patrick.nesser@sante-lorraine.fr">patrick.nesser@sante-lorraine.fr</a>
Talla Mba	Yannick	<a href="mailto:yannick.tallamba@sante-lorraine.fr">yannick.tallamba@sante-lorraine.fr</a>	

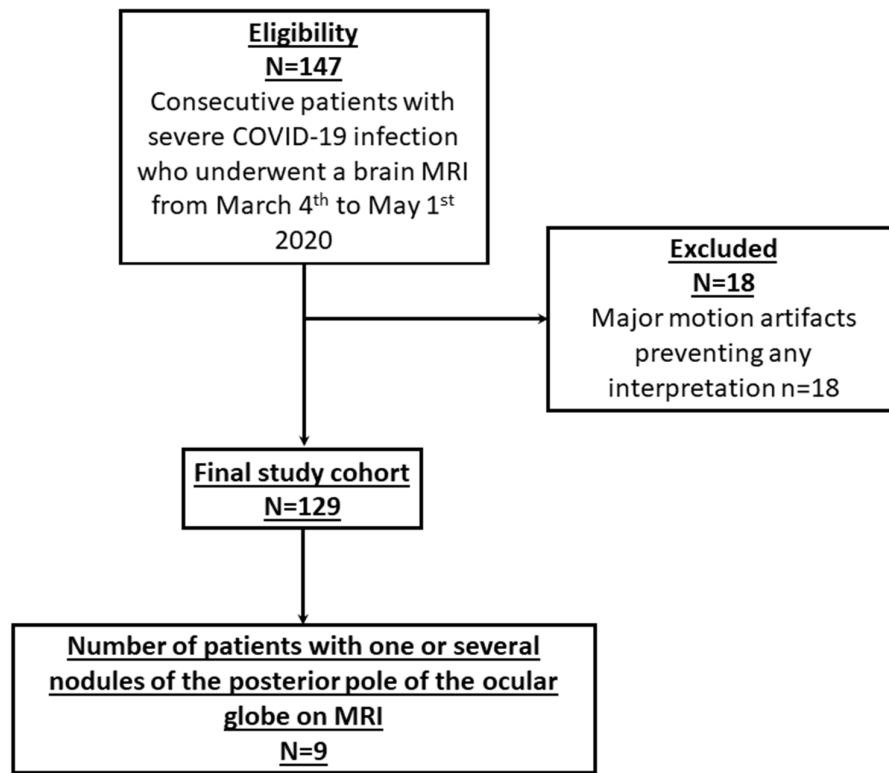
CHR Mulhouse	Hemmert	Céline	<a href="mailto:hemmertceline@aol.com">hemmertceline@aol.com</a>
	Feuerstein	Philippe	<a href="mailto:Philippe.feuerstein@ghrmsa.fr">Philippe.feuerstein@ghrmsa.fr</a>
	Sebag	Nathan	<a href="mailto:Nathan.Sebag@ghrmsa.fr">Nathan.Sebag@ghrmsa.fr</a>
CH Haguenau	Carre	Sophie	<a href="mailto:sophie.carre@ch-haguenau.fr">sophie.carre@ch-haguenau.fr</a>
	Alleg	Manel	<a href="mailto:manel.alleg@ch-haguenau.fr">manel.alleg@ch-haguenau.fr</a>
	Lecocq	Claire	<a href="mailto:claire.lecocq@ch-haguenau.fr">claire.lecocq@ch-haguenau.fr</a>
CHU Nancy	Schmitt	Emmanuel	<a href="mailto:e.schmitt@chru-nancy.fr">e.schmitt@chru-nancy.fr</a>
	Anxionnat	René	<a href="mailto:r.anxionnat@chu-nancy.fr">r.anxionnat@chu-nancy.fr</a>
	Zhu	François	<a href="mailto:f.zhu@chru-nancy.fr">f.zhu@chru-nancy.fr</a>
CHU de Dijon	Comby	Pierre-Olivier	<a href="mailto:pierre-olivier.comby@chu-dijon.fr">pierre-olivier.comby@chu-dijon.fr</a>
	Ricolfi	Frederic	<a href="mailto:frederic.ricolfi@chu-dijon.fr">frederic.ricolfi@chu-dijon.fr</a>
	Thouant	Pierre	<a href="mailto:pierre.thouant@chu-dijon.fr">pierre.thouant@chu-dijon.fr</a>
CHU de Grenoble	Grand	Sylvie	<a href="mailto:SGrand@chu-grenoble.fr">SGrand@chu-grenoble.fr</a>
	Krainik	Alexandre	<a href="mailto:AKrainik@chu-grenoble.fr">AKrainik@chu-grenoble.fr</a>
Hôpital privé Antony	Forestier	Géraud	<a href="mailto:geraudforestier@gmail.com">geraudforestier@gmail.com</a>
	de Beaurepaire	Isaure	<a href="mailto:isaure.debeaurepaire@orange.fr">isaure.debeaurepaire@orange.fr</a>
	Bornet	Grégoire	<a href="mailto:gregoirebornet@yahoo.fr">gregoirebornet@yahoo.fr</a>
CHU de Lyon	Lacalm	Audrey	<a href="mailto:audrey.lacalm@gmail.com">audrey.lacalm@gmail.com</a>
	Pique	Julie	<a href="mailto:julie.pique@chu-lyon.fr">julie.pique@chu-lyon.fr</a>
CHU Saint-Etienne	Boutet	Claire	<a href="mailto:claire.boutet@chu-st-etienne.fr">claire.boutet@chu-st-etienne.fr</a>
	Fabre	Xavier	<a href="mailto:xavier.fabre@ch-roanne.fr">xavier.fabre@ch-roanne.fr</a>
Bureau SFNR	Desal	Hubert	<a href="mailto:hubert.desal@chu-nantes.fr">hubert.desal@chu-nantes.fr</a>
	Berge	Jérôme	<a href="mailto:jerome.berge@chu-bordeaux.fr">jerome.berge@chu-bordeaux.fr</a>
	Boulouis	Grégoire	<a href="mailto:gregoireboulouis@gmail.com">gregoireboulouis@gmail.com</a>
	Kazemi	Apolline	<a href="mailto:apolline.kazemi@gmail.com">apolline.kazemi@gmail.com</a>
	Pyatigorskaya	Nadya	<a href="mailto:nadya.pyatigorskaya@psl.aphp.fr">nadya.pyatigorskaya@psl.aphp.fr</a>
	Lecler	Augustin	<a href="mailto:augustinlecler@gmail.com">augustinlecler@gmail.com</a>
	Saleme	Suzana	<a href="mailto:s.saleme@mac.com">s.saleme@mac.com</a>
	Edjlali-Goujon	Myriam	<a href="mailto:myriam.edjlali@gmail.com">myriam.edjlali@gmail.com</a>
	Kerleroux	Basile	<a href="mailto:basile.kerleroux@gmail.com">basile.kerleroux@gmail.com</a>
	Brisset	Jean-Christophe	<a href="mailto:brissetli@gmail.com">brissetli@gmail.com</a>
UCIEC	Zorn	Pierre-Emmanuel	<a href="mailto:pierreemmanuel.zorn@chru-strasbourg.fr">pierreemmanuel.zorn@chru-strasbourg.fr</a>
	Matthieu	Muriel	<a href="mailto:muriel.matthieu@chru-strasbourg.fr">muriel.matthieu@chru-strasbourg.fr</a>
Fondation Rothschild	Chenaf	Samir	<a href="mailto:samir.chenaf@chru-strasbourg.fr">samir.chenaf@chru-strasbourg.fr</a>
	Savatovsky	Julien	<a href="mailto:jsavatovsky@gmail.com">jsavatovsky@gmail.com</a>
	Duron	Loïc	<a href="mailto:loic.cmprepa@gmail.com">loic.cmprepa@gmail.com</a>

## REFERENCES

1. Kremer S, Lersy F, Anheim M, et al. Neurologic and neuroimaging findings in COVID-19 patients: A retrospective multicenter study. *Neurology*. 2020; doi: 10.1212/WNL.0000000000010112.
2. Kremer S, Lersy F, de Sèze J, et al. Brain MRI Findings in Severe COVID-19: A Retrospective Observational Study. *Radiology*. 2020;202222. doi: 10.1148/radiol.2020202222.
3. Ulhaq ZS, Soraya GV. The prevalence of ophthalmic manifestations in COVID-19 and the diagnostic value of ocular tissue/fluid. *Graefes Arch Clin Exp Ophthalmol*. 2020;258(6):1351–1352. doi: 10.1007/s00417-020-04695-8.
4. Wu P, Duan F, Luo C, et al. Characteristics of Ocular Findings of Patients With Coronavirus Disease 2019 (COVID-19) in Hubei Province, China. *JAMA Ophthalmol*. 2020;138(5):575–578. doi: 10.1001/jamaophthalmol.2020.1291.
5. Chen L, Deng C, Chen X, et al. Ocular manifestations and clinical characteristics of 534 cases of COVID-19 in China: A cross-sectional study. *medRxiv*. Cold Spring Harbor Laboratory Press; 2020;2020.03.12.20034678. doi: 10.1101/2020.03.12.20034678.
6. Ling XC, Kang EY-C, Lin J-Y, et al. Ocular manifestation, comorbidities, and detection of severe acute respiratory syndrome-coronavirus 2 from conjunctiva in coronavirus disease 2019: A systematic review and meta-analysis. *Taiwan J Ophthalmol*. 2020;10(3):153–166. doi: 10.4103/tjo.tjo\_53\_20.
7. Cavalleri M, Brambati M, Starace V, et al. Ocular Features and Associated Systemic Findings in SARS-CoV-2 Infection. *Ocul Immunol Inflamm*. 2020;28(6):916–921. doi: 10.1080/09273948.2020.1781198.
8. Moonis G, Filippi CG, Kirsch CFE, et al. The Spectrum of Neuroimaging findings on CT and MRI in Adults with Coronavirus Disease (COVID-19). *AJR Am J Roentgenol*. 2020; doi: 10.2214/AJR.20.24839.
9. Mehta S, Pandey A. Rhino-Orbital Mucormycosis Associated With COVID-19. *Cureus*. 2020;12(9):e10726. doi: 10.7759/cureus.10726.
10. Turbin RE, Wawrzusin PJ, Sakla NM, et al. Orbital cellulitis, sinusitis and intracranial abnormalities in two adolescents with COVID-19. *Orbit Amst Neth*. 2020;39(4):305–310. doi: 10.1080/01676830.2020.1768560.
11. Abrishami M, Tohidinezhad F, Daneshvar R, et al. Ocular Manifestations of Hospitalized Patients with COVID-19 in Northeast of Iran. *Ocul Immunol Inflamm*. 2020;28(5):739–744. doi: 10.1080/09273948.2020.1773868.
12. Loffredo L, Pacella F, Pacella E, Tiscione G, Oliva A, Violi F. Conjunctivitis and COVID-19: A meta-analysis. *J Med Virol*. 2020; doi: 10.1002/jmv.25938.
13. Pirraglia MP, Ceccarelli G, Cerini A, et al. Retinal involvement and ocular findings in COVID-19 pneumonia patients. *Sci Rep*. 2020;10. doi: 10.1038/s41598-020-74446-6.
14. Marinho PM, Marcos AAA, Romano AC, Nascimento H, Belfort R. Retinal findings in patients with COVID-19. *Lancet Lond Engl*. 2020;395(10237):1610. doi: 10.1016/S0140-6736(20)31014-X.
15. Landecho MF, Yuste JR, Gándara E, et al. COVID-19 retinal microangiopathy as an in vivo biomarker of systemic vascular disease? *J Intern Med*. 2020; doi: 10.1111/joim.13156.
16. Invernizzi A, Torre A, Parrulli S, et al. Retinal findings in patients with COVID-19: Results from the SERPICO-19 study. *EClinicalMedicine*. 2020; doi: 10.1016/j.eclinm.2020.100550.
17. Seah I, Agrawal R. Can the Coronavirus Disease 2019 (COVID-19) Affect the Eyes? A Review of Coronaviruses and Ocular Implications in Humans and Animals. *Ocul Immunol Inflamm*. 2020;1–5. doi: 10.1080/09273948.2020.1738501.

18. Abdul-Kadir M-A, Lim LT. Human coronaviruses: ophthalmic manifestations. *BMJ Open Ophthalmol.* 2020;5(1):e000630. doi: 10.1136/bmjophth-2020-000630.
19. Zhou L, Xu Z, Castiglione GM, Soiberman US, Eberhart CG, Duh EJ. ACE2 and TMPRSS2 are expressed on the human ocular surface, suggesting susceptibility to SARS-CoV-2 infection. *Ocul Surf.* 2020;18(4):537–544. doi: 10.1016/j.jtos.2020.06.007.
20. Sanghi P, Malik M, Hossain IT, Manzouri B. Ocular Complications in the Prone Position in the Critical Care Setting: The COVID-19 Pandemic. *J Intensive Care Med.* 2020;885066620959031. doi: 10.1177/0885066620959031.
21. Stevens DV, Tran AQ, Kim E. Complications of Orbital Emphysema in a COVID-19 Patient. *Ophthalmology.* 2020;127(7):990. doi: 10.1016/j.ophtha.2020.05.011.

## FIGURES

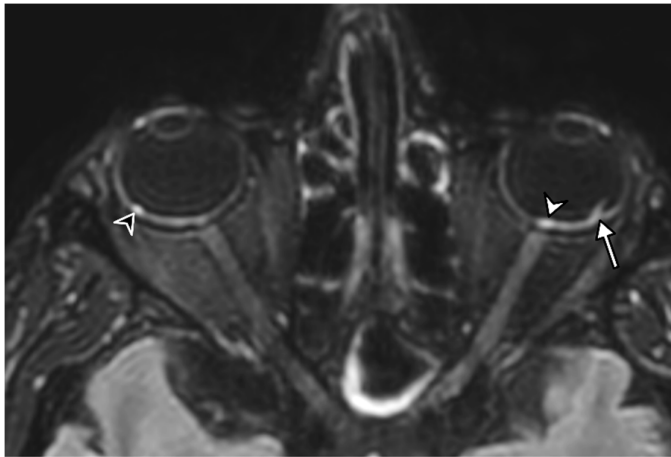


**Figure 1**

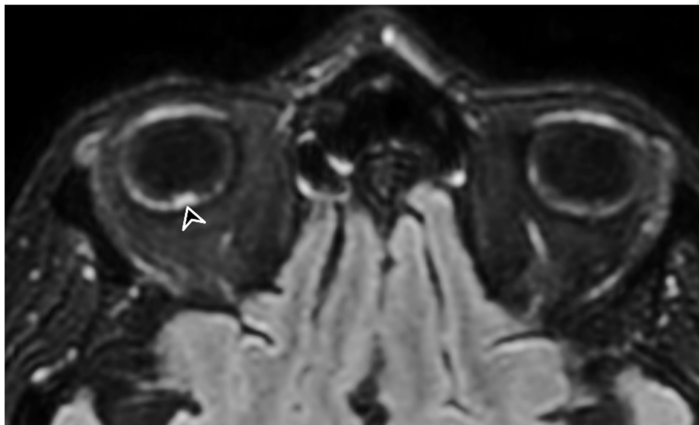
Flow chart. MRI=Magnetic Resonance Imaging.



**Figure 2**



**A**



**B**

56-year-old man presenting with severe COVID-19. Diagnosis of SARS-CoV-2 infection was based on a positive quantitative real-time RT-PCR test for SARS-CoV-2 nucleic acid performed on nasopharyngeal and lower respiratory tract swabs. The patient had been hospitalized in intensive care unit for 20 days when an MRI was performed due to delayed awakening despite discontinuation of sedation. He presented with acute respiratory distress syndrome, with a median Simplified Acute Physiology Score (SAPS II) of 45. He was intubated on high-flow supplementary oxygen and placed in the prone position. *A, B*, 3D FLAIR-weighted MRI reformatted in the axial plane showing several hyperintense nodules of the posterior pole of the globe located in the macular region (white arrowhead) and the extramacular region (black arrowheads). Note the presence of a focal temporal retinal detachment of the left eye (arrow).