

Functional medicine

Tendon incontinence repair - First experience with an autologous semitendinosus tendon transplant for urinary stress incontinence treatment

Amadeus Hornemann^{a,b,c,*}, Benjamin Hoch^a, Wolfgang Franz^b, Marc Sütterlin^a^a Department of Obstetrics and Gynecology, University Medical Center Mannheim, Heidelberg University, Mannheim, Germany^b Ethianum Clinic for Plastic, Aesthetic and Reconstructive Surgery, Spine, Orthopedic, Gynecology and Hand Surgery, Heidelberg, Germany^c Department of Minimally-Invasive Gynecological Surgery, Krankenhaus Sachsenhausen, Frankfurt am Main, Germany

ARTICLE INFO

Keywords:

Mesh
Semitendinosus tendon autograft
Tendon transplantation
Tendon incontinence repair
TVT

ABSTRACT

In a 40-year-old caucasian patient with stress incontinence was a TVT operation performed with an autologous semitendinosus tendon transplant. The operation was done with spinal anesthesia. The tendon of the right musculus semitendinosus was stripped from the popliteal fossa and used instead of a synthetic tape as mid-urethral sling, as it is done in a classical retropubic TVT procedure. The operation was performed successfully. On the first day after the operation the transurethral catheter was removed, continence was reached, and no urinary retention was seen. Mobility and power of the affected leg did not change.

Introduction

Urinary stress incontinence is an underestimated problem with high prevalence. Lifetime risk of stress urinary incontinence surgery in women is estimated to be 14%. Treatment options include, among others, physiotherapy, electric nerve stimulation, and operative approaches. The surgical procedures are more likely to cure stress incontinence than nonsurgical methods.

In July 2018, vaginal meshes were banned in the UK due to a large discussion about side effects.¹ Since then, even the TVT (tension free vaginal tape) meshes for incontinence operations are on hold. Other countries, such as Australia and New Zealand, acted similarly.

As orthopedic surgeons have reported excellent experience with the 20–30cm long and 1–1.5cm broad semitendinosus tendon for anterior cruciate ligament reconstruction², we initiated a feasibility study using this tendon to perform a TVT operation without a synthetic mesh. We already used this tendon successfully for cervicosacropexy³ and pecto-⁴ in women with prolapse.

Case presentation

After obtaining ethical approval, a 40-year-old patient with stress incontinence was offered this tendon transplantation approach and informed consent was obtained. The operation was done with spinal anesthesia. The tendon of the right musculus semitendinosus was

stripped from the popliteal fossa, and used instead of a synthetic tape as a midurethral sling as it is done in a classical retropubic TVT procedure (Fig. 1).

The operation was performed successfully without complications in 90 minutes. On the first day after the operation the transurethral catheter was removed, continence was reached, and no urinary retention was seen. Mobility and power of the affected leg did not change.

10 weeks later the first control examination was done. There were no complaints (leg, vagina, bladder) and continence was reported. Ultrasound examination showed 90ml residual urine. 15 days later, the patient returned because she was not able to urinate (acute urinary retention). As she was not able to urinate at all, the bladder was emptied with a catheter, but afterwards the problem persisted. Therefore, the decision to incise the tendon through the vagina was made. This procedure was done the next day in local anesthesia. A histologic sample showed slightly altered tendon tissue without necrosis. Directly after the procedure, the patient was able to urinate, and there was no further urinary retention. After another 12 weeks, the patient was continent, and no urinary retention was seen. The patient is still highly-satisfied and confirmed that she would recommend this operation to other affected women without restriction. Despite the patient's voiding problem after 10 weeks, which might be caused by tendon shrinkage, we are convinced that further research to investigate the potential of tendon transplants as substitutes for artificial suburethral bands is indicated.

* Corresponding author. Krankenhaus Sachsenhausen, Department of Obstetrics and Gynecology, Schulstr. 31, 60594, Frankfurt am Main, Germany.

E-mail address: amadeus.hornemann@ethianum.de (A. Hornemann).

<https://doi.org/10.1016/j.eucr.2020.101257>

Received 6 May 2020; Accepted 17 May 2020

Available online 21 May 2020

2214-4420/© 2020 The Authors.

Published by Elsevier Inc.

This is an open access article under the CC BY-NC-ND license

(<http://creativecommons.org/licenses/by-nc-nd/4.0/>).

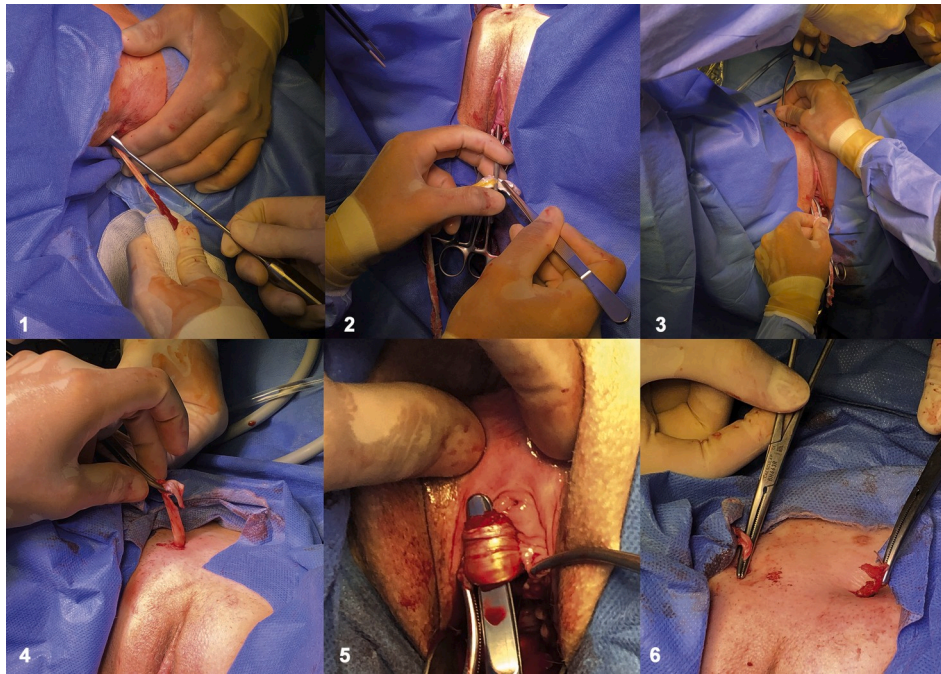


Fig. 1. (from left to right): removing the tendon from the right popliteal fossa¹; suburethral placement as it is done with a synthetic TVT mesh (2–6).

Discussion

Synthetic vaginal meshes are under discussion because of possible complications.¹ Up to 80% of them are bacterial contaminated while being implanted⁵, which can lead to serious infections. Previous approaches to other groups with autologous material as fascia lata or musculus rectus abdominus already showed a good mesh alternative, but harvesting of the tissue was much too invasive to be introduced into clinical routine. As removing the semitendinosus tendon is easy to learn, quite fast, and can be performed without much morbidity² it seems to be a better alternative to the autologous material used in the past. With the voiding problem and possible tendon shrinkage in the presented patient in mind, the tendon will not be placed as tightly in the next patient.

Conclusion

Our new approach demonstrates the feasibility of using a semitendinosus tendon instead of a synthetic mesh for a TVT operation. The preliminary result appears to be promising. In our opinion, further research in vaginal incontinence operations with autologous tendon transplants is warranted.

Author Disclosure Statement

Amadeus Hornemann, Benjamin Hoch and Marc Sütterlin have no conflict of interest

Wolfgang Franz receives royalties from Arthrex for a tendon harvesting tool.

References

1. Wise J. Surgical mesh for stress urinary incontinence to be halted immediately in England. *BMJ*. 2018;362. k3035.
2. Franz W, Baumann A. Minimally invasive semitendinosus tendon harvesting from the popliteal fossa versus conventional hamstring tendon harvesting for ACL reconstruction: a prospective, randomised controlled trial in 100 patients. *Knee*. 2016; 23(1):106–110.
3. Hornemann A, Hoch B, Germann G, Franz W, Suetterlin M. Hamstring autograft as a mesh-alternative for pelvic organ prolapse. *J Minim Invasive Gynecol*. 2020;27(1):17–18.
4. Hornemann A, Hoch B, Hofmann J, Franz W, Sutterlin M. Tendon Descensus Repair (TENDER) - a prospective clinical feasibility study of tendon transplantation for pelvic organ prolapse repair. *Eur J Obstet Gynecol Reprod Biol*. 2020;249:37–41.
5. Rovner E, de Tayrac R, Kirschner-Hermanns R, Veit-Rubin N, Anding R. Is polypropylene mesh material fundamentally safe for use as a reconstructive material in vaginal surgery: ICI-rs 2019? *NeuroUrol Urodyn*. 2020.