

CASE REPORT

Disseminated hematogenous tuberculosis in puerperium—case report

Orivaldo Alves Barbosa^{1,*}, Felipe Morais Teles¹, Allan Carlos Costa Maia², Gabriel Melo Ferraz Pessoa², Isabele Moreno de Alencar², Emília Tomé de Sousa³ and Sâmia Duarte Jorge Bezerra Simão⁴

¹Internal Medicine, Hospital Cesar Cals, Fortaleza, Brazil, ²Christus University Center, Unichristus, Fortaleza, Brazil, ³Pathology, Necropsy Verification Service, Fortaleza, Brazil, ⁴Obstetrics Department, Hospital Cesar Cals, Fortaleza, Brazil

*Correspondence address: General Hospital Dr. César Cals, Professor of the Medicine Christus University Center (UNICHRISTUS). Fax: 5585 31015333; E-mail: orivaldo.alves.barbosa@gmail.com

Abstract

Although tuberculosis (TB) is relatively common in pregnancy and puerperium, its disseminated form is a rare event, with potential lethal maternal and fetal outcomes. Due to the infrequency and lack of knowledge of most physicians about the various manifestations of the disease, the diagnosis is often overlooked, and treatment postponed, resulting in a high death rate. We report a fatal case of disseminated tuberculosis in the puerperium, with lung, brain, liver and uterine involvement. After, we briefly review the clinical manifestations of TB in the gestational period.

INTRODUCTION

Tuberculosis (TB) is a major cause of death worldwide, with an estimated 1.3 million deaths in 2017 [1]. In Brazil, there were 86. Eight hundred fifty-eight cases reported in 2017, one-third of them in females. In tuberculosis-endemic areas, such as sub-Saharan Africa and India, the most considerable burden of tuberculosis in women is during the childbearing years (15–49 years) [2]. It was estimated that more than 200 000 cases of active tuberculosis occurred among pregnant women globally in 2011; globally, it is estimated that as many as 216 500 pregnant women have active TB [3] with potentially deleterious effects on maternal and fetal outcomes [4].

Although TB is prevalent in pregnancy and puerperium, its progressive disseminated hematogenous form is rare and hardly considered in the differential diagnosis of acute febrile conditions during this period [5].

We report a case of maternal death due to disseminated TB after an abortion with cerebral, pulmonary, hepatic and uterine involvement. We will briefly review the literature on the subject.

CASE REPORT

A 22-year-old woman, with first-time pregnancy, 22 weeks pregnant, was admitted to the obstetrics service of a hospital for decreased fetal movement and transvaginal bleeding. The patient was in her usual state of health 2 weeks before hospital admission, when intermittent vaginal spotting began. Over the course of days, she noted reduced fetal mobility and was referred to a tertiary hospital. The patient had never smoked and did not drink alcohol or use illicit drugs. Her family history was unremarkable.

†The authors have nothing to disclose.

Received: May 7, 2019. Revised: June 23, 2019. Accepted: October 6, 2019

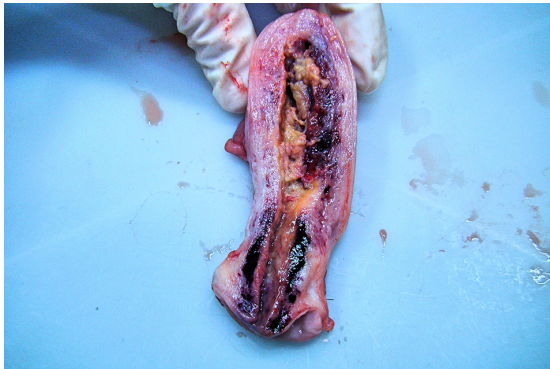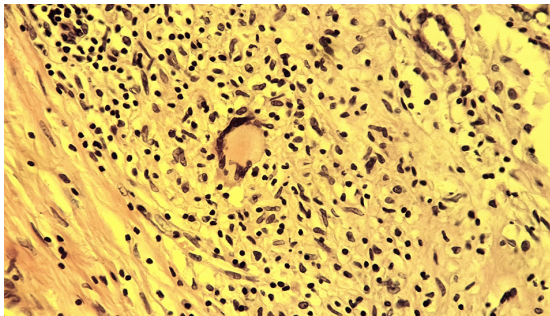
© The Author(s) 2019. Published by Oxford University Press.

This is an Open Access article distributed under the terms of the Creative Commons Attribution Non-Commercial License (<http://creativecommons.org/licenses/by-nc/4.0/>), which permits non-commercial re-use, distribution, and reproduction in any medium, provided the original work is properly cited.

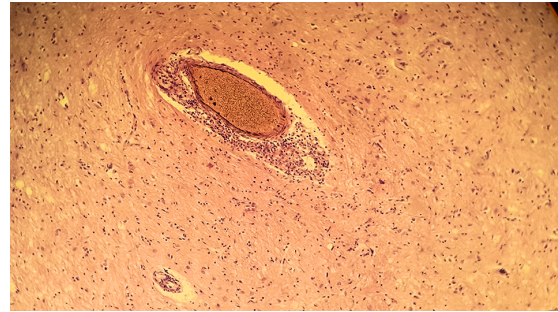
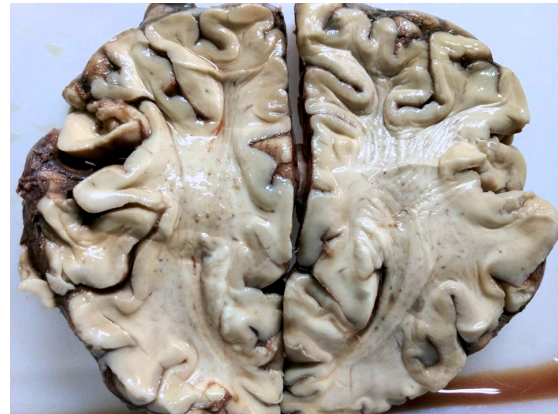For commercial re-use, please contact journals.permissions@oup.com

Table 1: Laboratory data

Test (on ICU admission)	Patient	Reference value
Total protein (CSF)	49 mg/dl	<45 mg/dl
Glucose CSF	56 mg/dl	>60
Adenosine deaminase CSF	4.6 U/l	<8 u/l
Cellular count CSF	5 cells (lymphocytes)	<4 cells/mm ³
VDRL (CSF)	Negative	Negative
VDRL (serum)	Positive at 1:64	Negative
C-reactive protein (serum)	31 mg/dl	<6 mg/dl
Hemoglobin	7.2 g/dl	11.5 to 15.7 g dl
Leucocyte count	7710 mm ³	4000 to 11 000 mm ³
Platelet count	217.000 mm ³	150 000 to 450 000 mm ³
Anti-HIV 1 and 2	Negative	Negative
Sodium	134 meq/l	135–145 meq/l
Potassium	3.7 meq/l	3.5–5.5 meq/l
Creatinine	0.6 mg/dl	<1.4 0.6 mg/dl

**Figure 1:** Macroscopic section of uterus showing increased size with evidence of necrosis.**Figure 2:** Microscopic section of uterus: central caseation surrounded by epithelioid macrophages and Langhans' giant cells along with lymphocytes.

On admission, fetal heart rate was 130 beats per minute, and uterine dynamics and fetal movements were absent, with the presence of bloody secretion on speculum examination. Ultrasonography showed an absence of amniotic fluid. A prophylactic antibiotic was initiated with ampicillin and azithromycin and treatment for syphilis with benzathine penicillin (Positive Venereal Disease Research Laboratory—VDRL); other laboratory test results are shown in [Table 1](#). The patient had two negative HIV tests. After 3 days, she developed fever and abdominal

**Figure 3:** Histology of brain. (a) There is an exudate of macrophages, lymphocytes and plasma cells. (b) Meningeal artery surrounded by lymphocytes, macrophages and an occasional multinucleated giant cell and endarteritis.**Figure 4:** Brain autopsy, showing diffuse edema and congestion.

pain, leukocytosis and C-reactive protein elevation. Due to the suspicion of chorioamnionitis, the decision made was to terminate the pregnancy by misoprostol induction. After 2 days, the patient reported mild headache, neck stiffness and fever, with suspected retained products of conception. The uterine evacuation was accomplished with sharp curettage; intravenous piperacillin–tazobactam and vancomycin were initiated. Head computer tomography showed signs of diffuse cerebral edema and hydrocephalus and cerebrospinal fluid analysis ([Table 1](#)) and showed protein elevation (49 mg/dl) with mild lymphocytic pleocytosis (five cells/mm³). Cryptococcal antigen was negative. Meropenem and empirical treatment for tuberculosis with pyrazinamide, isoniazid, rifampin and ethambutol was initiated. Due to sensory deterioration, endotracheal intubation and mechanical ventilation were performed. Neurosurgery was consulted, and external ventricular drainage with monitoring of intracranial pressure was placed. An electroencephalogram was performed, which evidenced slow waves and reduced brain electrical activity.

Despite clinical measures, the patient developed refractory intracranial hypertension and encephalic death after 48 h. The relatives consented to perform an autopsy to help determine the cause of death.

The anteroposterior section of the postpartum uterus revealed an enlarged and necrotic organ ([Fig. 1](#)), with the presence of caseous necrosis ([Fig. 2](#)—white arrow) with a giant cell. The brain was grossly edematous with evidence of lymphocytic inflammatory infiltrate in parenchyma and meninges. There was evidence of endarteritis ([Figs 3 and 4](#)).

The lungs were enlarged, with inflammatory lymphocytic infiltrate and the presence of multinucleated giant cells and caseous necrosis.

The livers also presented edema and evidence of inflammation with giant cells.

The final postmortem diagnosis was disseminated tuberculosis.

DISCUSSION

Tuberculosis is a common cause of maternal and fetal morbidity. However, the vast majority of cases are of pulmonary tuberculosis, with the exception of the HIV-infected population, who has a higher incidence of extra-pulmonary forms. Our presented patient had disseminated hematogenous tuberculosis, including the presence of endometrial spread, which may have contributed to miscarriage, similar to what is reported in other studies [6]. Given the previous normal immune status, this presentation is exceedingly rare.

Progressive hematogenous TB, or acute miliary, presents a wide range of clinical manifestations. Pleural effusion, peritonitis or meningitis occurs in two-thirds of patients [5]. Most patients present with unspecific symptoms, such as fever, weight loss, malaise and headache; less frequently, patients present with acute respiratory failure, cholangitis (fever, liver function test abnormalities suggestive of obstructive disease) and hypotension (due to sepsis, Addison disease or obstructive shock in pericardial TB). Uterine TB most often presents as infertility, but several cases of abortion due to TB have been reported [6].

Treatment should be initiated based on strong clinical suspicion because mortality from miliary tuberculosis is high with delayed treatment [5].

In a recent study in South Africa, more than two-thirds of pregnant women on antituberculosis treatment were HIV-infected. In HIV-uninfected cases (total 20 patients), pulmonary TB was responsible for 90% of cases; the remaining two cases were pleural. No cases of miliary or disseminated TB were reported, and no fatal incidents in the non-HIV population were reported. Only HIV-infected women had severe extra-pulmonary manifestation, including eight cases of meningeal TB and cases of abdominal, pericardial, spinal and pleural TB. No reports were made of uterine TB resulting in miscarriage [7].

Tuberculosis is an infection that requires a cellular immune response for control. Pregnancy suppresses the T-helper 1 (Th1) response, which may increase susceptibility to reactivation of tuberculosis. After delivery, Th1 suppression reverses and symptoms are exacerbated [8].

In our case, we suspect that the process of pregnancy immunoregulation induced the spread of a latent focus of tuberculosis. In the puerperium, the reconstitution of cellular immune response with pro-inflammatory profile, similar to immune reconstitution inflammatory syndrome (IRIS) in AIDS patients after initiation of antiretroviral therapy, may have caused the patient's death due to cerebral edema and herniation.

CONCLUSION

Physicians should be aware of the unpredictable symptomatology of tuberculosis during pregnancy. The multidisciplinary team that cares for women in high prevalence regions should have a low threshold for initiation of empirical treatment in

suspected cases. Our case highlights the importance of always considering TB in the differential diagnosis of fever in the pregnancy and puerperium, especially critically ill patients in endemic areas.

ACKNOWLEDGEMENTS

None.

CONFLICT OF INTEREST STATEMENT

None declared.

FUNDING

No funding source.

ETHICAL APPROVAL

The data were collected from the medical records and the interview with the patient. The project was submitted to the Research Ethics Committee, being approved for publication, following the norms of resolution 510/2016 of the National Health Council.

CONSENT

The Patient Family authorized the publication of his case, knowing that it is free of charge and that their identity will be preserved.

REFERENCES

1. World Health Organization. *Global Tuberculosis Control: Epidemiology, Strategy, Financing*. WHO Report. Switzerland: World Health Organization, Geneva, 2018.
2. Marais BJ, Gupta A, Starke JR, El Sony A. Tuberculosis in women and children. *Lancet* 2010;**375**:2057–9.
3. El-Messidi A, Czuzoj-Shulman N, Spence AR, Abenhaim HA. Medical and obstetric outcomes among pregnant women with tuberculosis: a population-based study of 7.8 million births. *Am J Obstet Gynecol* 2016;**215**:797.e1.
4. Sobhy S, Babiker ZOE, Zamora J, Khan KS, Kunst H. Maternal and perinatal mortality and morbidity associated with tuberculosis during pregnancy and the postpartum period: a systematic review and meta-analysis. *BJOG* 2017;**124**:727–33.
5. Fitzgerald DW, Sterling TR, Haas DW. *Mycobacterium tuberculosis*. In: Bennett JE, Dolin R, Blaser MJ, editors. *Mandell, Douglas, and Bennett's Principles and Practice of Infectious Diseases*. Philadelphia: Elsevier, 2015, 2787–818.
6. Cantres-Fonseca OJ, Montalvo F, Campos-Santiago Z, Rodríguez-Cintrón W. Miscarriage as initial presentation of tuberculosis. *Infect Dis Clin Pract* 2013;**21**:e27–9. doi: [10.1097/IPC.0b013e31827cad21](https://doi.org/10.1097/IPC.0b013e31827cad21).
7. Bekker A, Schaaf HS, Draper HR, Kriel M, Hesselting AC. Tuberculosis disease during pregnancy and treatment outcomes in HIV infected and uninfected women at a referral hospital in Cape Town. *PLoS ONE* 2016;**11**:e0164249. doi: [10.1371/journal.pone.0164249](https://doi.org/10.1371/journal.pone.0164249).
8. Kourtis AP, Read JS, Jamieson DJ. Pregnancy and infection. *N Engl J Med* 2014;**370**:2211–8. doi: [10.1056/NEJMra1213566](https://doi.org/10.1056/NEJMra1213566).