

Biallelic Pathogenic Variants in *TNNT3* Associated With Congenital Myopathy

Daniel G. Calame, MD, PhD, Jawid Fatih, BS, Isabella Herman, MD, PhD, Zeynep Coban Akdemir, PhD, Haowei Du, MS, Shalini N. Jhangiani, BS, Richard A. Gibbs, PhD, Dana Marafi, MD, MSc, Davut Pehlivan, MD, Jennifer E. Posey, MD, PhD, Timothy Lotze, MD, Pedro Mancias, MD, Meenakshi Bidwai Bhattacharjee, MD, and James R. Lupski, MD, PhD, DSc (hon)

Correspondence
Dr. Lupski
jlupski@bcm.tmc.edu

Neurol Genet 2021;7:e589. doi:10.1212/NXG.000000000000589

Abstract

Objective

Pathogenic variants in *TNNT3*, the gene encoding fast skeletal muscle troponin T, were first described in autosomal dominant distal arthrogryposis type 2B2. Recently, a homozygous splice site variant, c.681+1G>A, was identified in a patient with nemaline myopathy and distal arthrogryposis. Here, we describe the second individual with congenital myopathy associated with biallelic *TNNT3* variants.

Methods

Clinical exome sequencing data from a patient with molecularly undiagnosed congenital myopathy underwent research reanalysis. Clinical and histopathologic data were collected and compared with the single reported patient with *TNNT3*-related congenital myopathy.

Results

A homozygous *TNNT3* variant, c.481-1G>A, was identified. This variant alters a consensus splice acceptor and is predicted to affect splicing by multiple *in silico* prediction tools. Both the patient reported here and the previously published patient exhibited limb, bulbar, and respiratory muscle weakness from birth, which improved over time. Other shared features include history of polyhydramnios, hypotonia, scoliosis, and high-arched palate. Distal arthrogryposis and nemaline rods, findings reported in the first patient with *TNNT3*-related congenital myopathy, were not observed in the patient reported here.

Conclusions

This report provides further evidence for the association of biallelic *TNNT3* variants with severe recessive congenital myopathy with or without nemaline rods and distal arthrogryposis. *TNNT3* sequencing and copy number analysis should be incorporated into the workup of congenital myopathies.

From the Division of Neurology and Developmental Neuroscience (D.G.C., I.H., D.P., T.L.), Department of Pediatrics, Baylor College of Medicine, Houston, TX; Texas Children's Hospital (D.G.C., I.H., D.P., J.R.L.), Houston, TX; Department of Molecular and Human Genetics (D.G.C., J.F., I.H., Z.C.A., H.D., R.A.G., D.M., D.P., J.E.P., J.R.L.), Baylor College of Medicine, Houston, TX; Human Genome Sequencing Center (S.N.J., R.A.G., J.R.L.), Baylor College of Medicine, Houston, TX; Department of Pediatrics (D.M.), Faculty of Medicine, Kuwait University, Safat, Kuwait; Division of Child and Adolescent Neurology (P.M.), Department of Pediatrics, University of Texas Health Science Center, Houston, TX; Pathology and Laboratory Medicine (M.B.B.), University of Texas Health Science Center at Houston-McGovern Medical School, Houston, TX; and Department of Pediatrics (J.R.L.), Baylor College of Medicine, Houston, TX.

Go to [Neurology.org/NG](https://www.neurology.org/NG) for full disclosures. Funding information is provided at the end of the article.

The Article Processing Charge was funded by the NIH.

This is an open access article distributed under the terms of the Creative Commons Attribution-NonCommercial-NoDerivatives License 4.0 (CC BY-NC-ND), which permits downloading and sharing the work provided it is properly cited. The work cannot be changed in any way or used commercially without permission from the journal.

Glossary

AOH = absence of heterozygosity; ES = exome sequencing; GoF = gain of function; LoF = loss of function.

Pathogenic heterozygous variation in *TNNT3*, the gene encoding fast skeletal muscle troponin T, was first identified in families with autosomal dominant distal arthrogryposis type 2B2 (DA2B2, MIM #618435).¹⁻³ Clinical features of DA2B2 include distal arthrogryposis and triangular facies. As a component of the troponin complex, troponin T plays an integral role in skeletal muscle contraction.⁴ There are 3 paralogs encoding troponin T with tissue-specific expression patterns: *TNNT1* (slow skeletal), *TNNT2* (cardiac), and *TNNT3* (fast skeletal).⁴ To date, all DA2B2-associated *TNNT3* variants involve a single arginine residue, p.Arg63 (p.Arg63Ser, p.Arg63Cys, and p.Arg63His).¹⁻³ The *TNNT3* variant p.Arg63His increased contractile force in rabbit psoas muscle fibers, suggesting that DA2B2 results from a gain-of-function (GoF) mechanism.⁵ More recently, a neonate with nemaline myopathy, distal arthrogryposis, and a homozygous *TNNT3* splice variant, c.681+1G>A, was reported.⁶ Here, we describe the second patient with biallelic variation at the locus; a novel homozygous *TNNT3* canonical splice site variant associated with congenital myopathy.

Methods

The patient was identified by local collaborators and was recruited through the Baylor-Hopkins Center for Mendelian Genomics initiative as part of an adult and pediatric neuromuscular disease cohort.

Standard Protocol Approvals, Registrations, and Patient Consents

Written informed consent including consent to publish photographs was obtained under Baylor College of Medicine Institutional Review Board Protocol H-29697.

Clinical exome sequencing (ES) was performed by Baylor Genetics (Houston, TX). The resulting FASTQ file was transferred to the Baylor-Hopkins Center for Mendelian Genomics for reanalysis through our in-house pipeline as previously described.⁷⁻⁹ Absence of heterozygosity (AOH) was determined via BafCalculator and based on calculated B-allele frequency from unphased exome data as described.⁸ As the AOH region size cutoff for BafCalculator is >1.5 Mb, BAM files were manually inspected using Integrative Genomics Viewer (software.broadinstitute.org/software/igv/) for evidence of smaller AOH regions.

Data Availability

Anonymized data not published within this article will be made available by request from any qualified investigator.

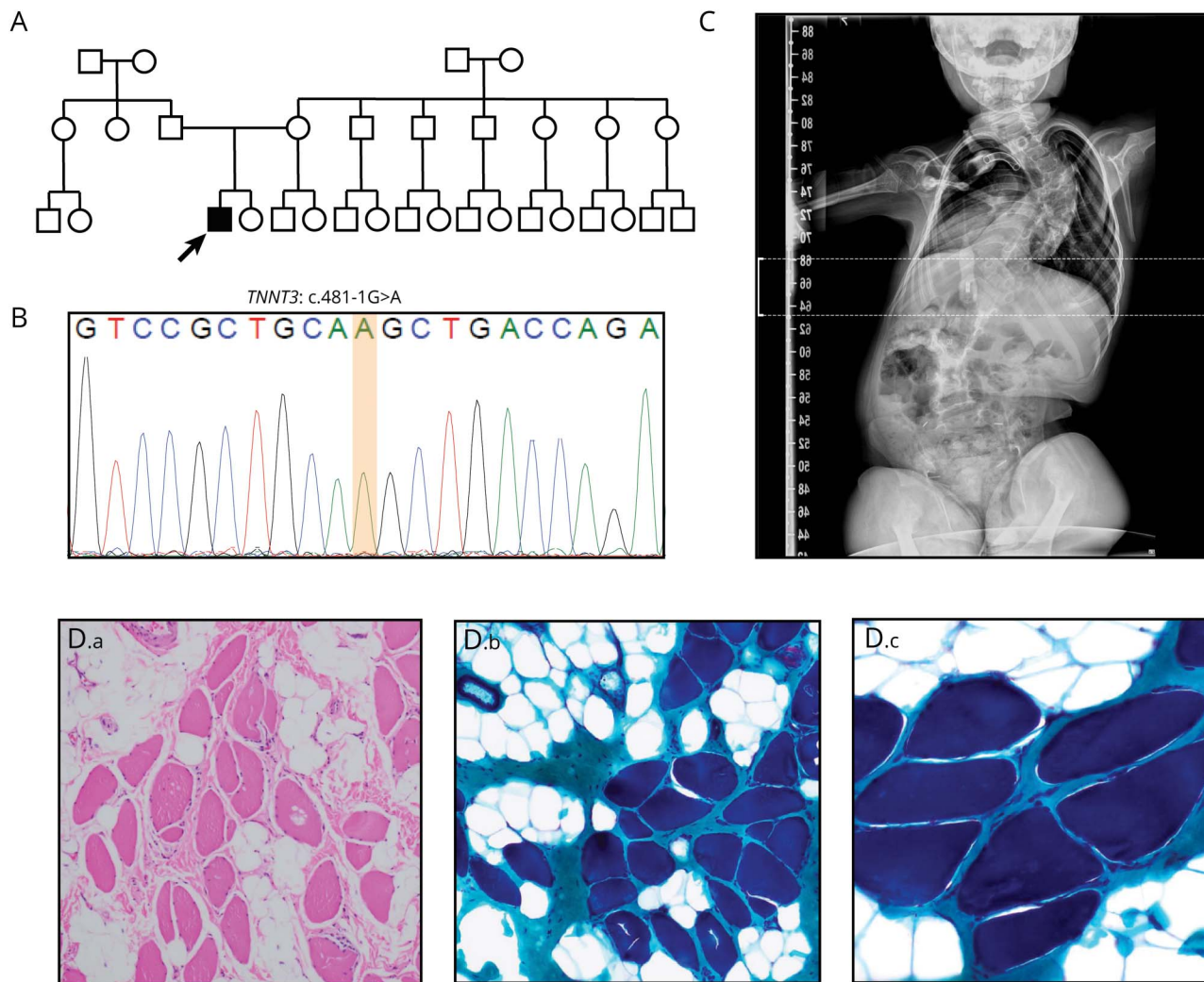
Results

The male proband was born full term to unrelated Latino parents (figure 1, A and B). Prenatal complications included

decreased fetal movement and polyhydramnios. Birth was complicated by respiratory failure requiring noninvasive ventilatory support. The patient ultimately required tracheostomy for persistent respiratory failure and gastrostomy placement for dysphagia before hospital discharge at age 3 months. He also had excessive drooling, which required treatment with glycopyrrolate. Although developmentally delayed, the patient was able to sit independently at age 1 year and by age 3 years could stand with support. Examination at 3 years demonstrated limb, truncal, and neck flexion weakness, myopathic facies, axial and appendicular hypotonia, absent reflexes, ligamentous laxity, scoliosis, pectus carinatum, high-arched palate, and bitemporal narrowing (figure 1C). He exhibited antigravity or greater strength in all muscle groups examined without any difference between proximal or distal muscle groups. Echocardiogram and ECG were normal. He required continuous positive airway pressure at night but no respiratory support during the day. Biopsy of the right quadriceps was performed at age 4 years (figure 1D). Marked fiber size variability was observed. Poor fiber type differentiation was appreciated with the myosin ATPase reaction (data not shown). No necrotic, degenerating, or regenerating fibers were appreciated. There was significant fatty infiltration, increase in perimysial and endomysial connective tissue, and thickening of fibrous septa. Scattered fibers with increased internal nuclei were detected (data not shown). No central cores or nemaline rods were detected. At 4 years, he was accidentally disconnected from his trach collar and had catastrophic hypoxic-ischemic brain injury.

Research reanalysis of ES data identified a homozygous splice variant in *TNNT3* (NM_006757.4):c.481-1G>A at position GRCh37/hg19: chr11:1955775 (figure 1B and table 1). The variant was absent in our internal database of >14,000 exomes and has a gnomAD minor allele frequency of 1.655×10^{-5} (4 heterozygotes). Three of the 4 heterozygotes in gnomAD are Latino, and the remaining heterozygote is categorized as “Other”. Consistent with the lack of known parental consanguinity, B-allelic frequency analysis detected a total autosomal AOH size of 60.3 Mb. Manual inspection of the patient’s BAM file revealed a 565.2 Kb AOH block surrounding the variant (figure S1, links.lww.com/NXG/A413). Taken together with population data, these AOH data from ES suggest that *TNNT3*:c.481-1G>A may represent a Clan Genomics derived founder mutation in the Latino population.^{10,11} The nucleotide is well conserved (figure 2B), and the variant is predicted damaging by multiple variant annotation tools (MutationTaster: Disease causing; CADD score: 33) and splicing predictors (table 1).

Figure 1 Homozygous Splice Site *TNNT3* Variants Cause a Severe Congenital Myopathy



(A) Family pedigree. The proband is the only affected child of 2 unrelated parents of Latin American descent (father's origin: Mexico; mother's origin: Argentina). Exome sequencing identified a homozygous *TNNT3* c.481-1G>A variant in the proband. His parents were not available for testing. (B) Sanger sequencing confirming the genotype determined by exome sequencing in the proband. (C) X-ray showing severe neuromuscular scoliosis. (D) Muscle histology of the proband at age 4 years. H&E staining (D.a) demonstrates fiber size variability, fatty infiltration, and increased perimysial and endomysial connective tissue. Gomori trichrome staining (D.b, D.c) failed to identify nemaline rods. (D.a, D.b) 100× magnification, (D.c) 200× magnification.

Discussion

Although *TNNT3* was first associated with autosomal dominant DA2B2 (MIM #618435),¹⁻³ the severe phenotype of *Tnnt3*^{-/-} mice suggests that human biallelic loss of function (LoF) might cause a more severe neuromuscular disease than previously recognized.¹² Although crosses of wild-type and *Tnnt3*^{+/-} mice produced offspring with a normal mendelian distribution, no adult *Tnnt3*^{-/-} mice resulted from *Tnnt3*^{+/-} x *Tnnt3*^{+/-} crosses.¹² However, *Tnnt3*^{-/-} embryos were detected at embryonic day 18.5, and dead *Tnnt3*^{-/-} pups were found shortly after birth. As troponin T3 is robustly expressed in the diaphragm and *Tnnt3*^{-/-} pups had no heart or lung abnormalities, perinatal mortality was attributed to respiratory failure. These observations are consistent with troponin T3's known role as a critical component of the type 2 fiber troponin complex required for muscle contraction.⁴

This report details the second patient with congenital myopathy associated with biallelic *TNNT3* variants and the fifth pathogenic *TNNT3* variant (figure 2A). Both patients with congenital myopathy had homozygous variants involving consensus splice sites (Sandaradura et al,⁶ c.681+1G>A; this report, c.481-1G>A; figure 2B). c.681+1G>A is predicted to cause loss of a canonical splice donor site by multiple *in silico* algorithms (e.g., SpliceAI, MMSp, Human Splice Finder, table 1). cDNA from the first patient's muscle biopsy showed exon 14 skipping and increased intron 14 retention, which are predicted to cause either premature truncation or exonization.⁶ Western blot demonstrated severe reduction in troponin T3 protein with no truncated or elongated protein products.⁶ Thus, any abnormal splicing products not subject to nonsense mediated decay were likely unstable and degraded. The variant reported here, c.481-1G>A, is predicted to cause acceptor loss by SpliceAI, MMSp and

Table 1 Summary of *TNNT3* Pathogenic Alleles

Report	Position (hg19)	Nucleotide (NM_006757.4)	Protein	gnomAD allele count	SpliceAI	MMSp	HSF	CADD (v1.6)	verPhyloP
Sung et al, 2003	Chr11: 1954967: G>A	c.188G>A	p.Arg63His	0 Htz=0 Hmz	0	0	No impact	26.8	5.330
Zhao et al, 2011	Chr11: 1954966:C>T	c.187C>T	p.Arg63Cys	0 Htz=0 Hmz	0	0	Alteration of ESE/ESS motif; new cryptic Don.	25.6	1.014
Beck et al, 2013	Chr11: 1954966:C>A	c.187C>A	p.Arg63Ser	0 Htz=0 Hmz	0	0	No impact	24.2	1.014
Sandaradura et al, 2018	Chr11: 1956150: G>A	c.681+1G>A	—	2 Htz=0 Hmz	Don. Gain 0.01 Don. Loss 0.98	-4.840 (Don.)	Broken WT Don.	32	5.352
This report	Chr11: 1955775: G>A	c.481-1G>A	—	4 Htz=0 Hmz	Acc. Gain 0.72 Acc. Loss 0.99	-2.586 (Acc.)	Broken WT Acc.; new Acc.	33	5.405

Abbreviations: Acc. = acceptor; CADD = Combined Annotation Dependent Depletion; Don. = donor; ESE = exonic splicing enhancer; ESS = exonic splicing silencer; Hmz = homozygote; HSF = human splice finder; Htz = heterozygote; WT = wild type.

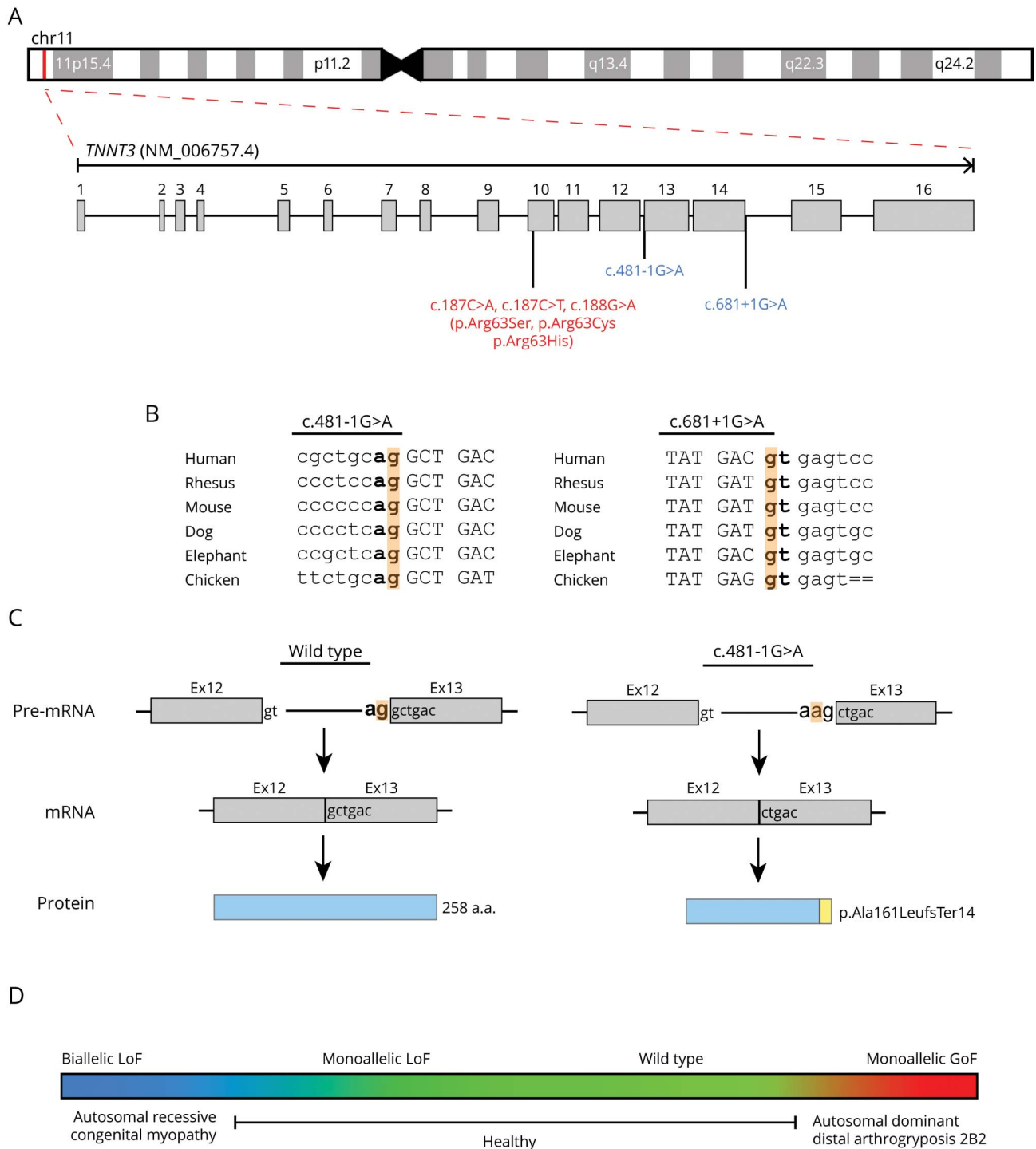
Human Splice Finder and acceptor gain by SpliceAI and Human Splice Finder (table 1). Therefore, this substitution should shift the splice acceptor site +1 bp in the 3' direction, resulting in a -1 frameshift and a prematurely truncated protein product, p.Ala161LeufsTer14 (figure 2C). As the resulting premature termination codon falls within the 13th of 16 exons, the mutant mRNA should be subject to nonsense-mediated decay.¹³ c.481-1G>A is therefore likely to represent a LoF allele, but this cannot be definitively established without additional studies examining its impact on *TNNT3* expression and function. Another possibility would be that c.481-1G>A could cause GoF. For example, a recurrent de novo dominantly acting splice gain variant in *COL6A1* was recently identified in patients with collagen VI-related dystrophy. The variant, *COL6A1*(NM_001848.3): c.930+189C>T, recurs due to a CpG dinucleotide and results in the inclusion of an additional 24 amino acids within a G-X-Y repeat region. Disruption of such G-X-Y repeat regions is a well-known mechanism of dominant negative disease in collagen disorders. If *TNNT3*:c.481-1G>A does cause GoF, it must influence *TNNT3* function in a manner distinct from the known *TNNT3* GoF variant c.188G>A (p.Arg63His), as neither of the patient's parents had DA2B2.

Shared clinical features between the 2 patients include bulbar, respiratory, and limb weakness, history of polyhydramnios, scoliosis, and high-arched palate (table 2). Both required gastrotomy due to bulbar weakness. The patient reported here has a persistent requirement for ventilatory support at night, whereas the patient described by Sandaradura et al⁶ required lifelong noninvasive ventilation. In contrast, Sandaradura et al's⁶ patient exhibited distal arthrogryposis and nemaline rods, whereas our patient did not. Arthrogryposis results from fetal akinesia and

can be a variable finding in many congenital neuromuscular disorders.¹⁴ Similarly, nemaline rods are not always present in nemaline myopathy or may only manifest with age.¹⁵ Neither patient has the triangular facies seen in DA2B2.¹⁻³

TNNT1, the *TNNT3* paralog encoding slow skeletal muscle troponin T, is responsible for nemaline myopathy 5, Amish type (NEM5; MIM #605355).¹⁶⁻¹⁸ First described in consanguineous Amish families in which a homozygous nonsense variant in exon 11 of *TNNT1* segregated with disease, NEM5 has subsequently been reported in multiple ethnic groups (Dutch, Hispanic, Palestinians, Ashkenazi, and French) due to other biallelic *TNNT1* variants (e.g., exonic deletions, other nonsense variants, and splice variants).¹⁵ NEM5 has neonatal onset and a progressive, fatal course with muscle weakness and atrophy, contractures, and chest wall rigidity causing pectus carinatum. In a large cohort of children with NEM5 of Amish ancestry, median survival was 18 months.¹⁷ In contrast, both patients with *TNNT3*-related congenital myopathy exhibited gradual improvement in limb strength.⁶ These observations suggest differential capacity for postnatal adaptation to *TNNT1* vs *TNNT3* deficiency in humans. As both patients with *TNNT3*-related congenital myopathy had improving limb strength but persistent respiratory weakness and respiratory-related complications (i.e., mortality or hypoxic-ischemic brain injury), there may also be differential capacity for postnatal adaptation to *TNNT3* deficiency between muscle groups. The comparison between NEM5 and *TNNT3*-related congenital myopathy may also suggest the existence of milder *TNNT3*-related myopathies. An example of this is the recent identification of a homozygous *TNNT1* missense variant, which segregated with slowly progressive limb-girdle muscle

Figure 2 *TNNT3* Variant Details and Model of *TNNT3*-Related Disease



(A) Exon structure of *TNNT3* (NM_006757.4). *TNNT3* is located on chromosome 11p15.5. Variants linked to autosomal recessive congenital myopathy are indicated in red, whereas variants associated with autosomal dominant DA2B2 are in blue. (B) Location and conservation of *TNNT3* splice variants c.481-1G>A and c.681+1G>A. Intronic sequences are indicated in lowercase. Exonic sequences are indicated in upper case. Consensus splice sites are indicated in bold. The variant location is highlighted in orange. (C) Predicted impact of c.481-1G>A on splicing and final protein product. Consensus splice sites are indicated in bold. The variant location is highlighted in orange. Normal splicing and translation of wild-type *TNNT3* mRNA (NM_006757.4) results in a 258 amino acid protein. The c.481-1G>A substitution is predicted to cause loss of the consensus splice acceptor and result in the creation of a new splice acceptor shifted +1 bp in the 3' direction. This new splice acceptor should result in a -1 frameshift and therefore is predicted to cause a prematurely truncated protein, p.Ala161LeufsTer14. (D) *TNNT3* disease model. Genotype is indicated above the colored box, and phenotype is displayed below. Monoallelic LoF *TNNT3* variants are tolerated (green), whereas biallelic LoF *TNNT3* variants (blue) cause severe congenital myopathy with respiratory and bulbar muscle weakness and scoliosis. In contrast, gain-of-function missense variants increasing contractility (red) result in autosomal dominant DA2B2.

Table 2 Clinical Features of Patients With *TNNT3* Pathogenic Variants

	This report	Sandaradura et al, 2018	DA2B2
Distal arthrogryposis	–	+	+
Triangular facies	–	–	+
High-arched palate	+	+	–
Hypotonia	+	+	–
Limb weakness	+	+	–
Facial weakness	+	+	–
Bulbar weakness	+	+	–
Respiratory weakness	+	+	–
Absent reflexes	+	+	–
Scoliosis	+	+	–
Nemaline rods	–	+	–

weakness, spine rigidity, contractures, and restrictive lung disease in a French-Canadian family.¹⁹

In conclusion, this report describes the second patient with biallelic *TNNT3* variants and severe congenital myopathy associated with respiratory and bulbar muscle weakness and scoliosis. Although this does not definitively establish *TNNT3* as a cause of congenital myopathy, these 2 case reports combined with animal model data provide compelling evidence for the existence of *TNNT3*-related congenital myopathy. *TNNT3* sequencing and copy number analysis should therefore be incorporated into the workup of congenital myopathies. Moreover, all patients with congenital myopathy with unsolved clinical exomes should undergo reanalyses of extant ES data and consider WGS studies and perhaps RNA-seq on muscle biopsy.²⁰⁻²²

Study Funding

This study was supported in part by the US National Human Genome Research Institute (NHGRI) and National Heart Lung and Blood Institute (NHLBI) to the Baylor-Hopkins Center for Mendelian Genomics (BHCMG, UM1 HG006542, J.R.L.) and NHGRI grant to Baylor College of Medicine Human Genome Sequencing Center (U54HG003273 to R.A.G.), US National Institute of Neurological Disorders and Stroke (NINDS) (R35NS105078 to J.R.L.), and Muscular Dystrophy Association (MDA) (512848 to J.R.L.). D.M. is supported by a Medical Genetics Research Fellowship Program through the United States National Institutes of Health (T32 GM007526-42). D.P. is supported by a Clinical Research Training Scholarship in Neuromuscular Disease partnered by the American Academy of Neurology (AAN), American Brain Foundation (ABF), and Muscle Study Group (MSG) and International

Rett Syndrome Foundation (IRSF grant #3701-1). J.E.P. was supported by NHGRI K08 HG008986.

Disclosure

J.R. Lupski has stock ownership in 23andMe; is a paid consultant for Regeneron Genetics Center; and is a coinventor on multiple United States and European patents related to molecular diagnostics for inherited neuropathies, eye diseases, and bacterial genomic fingerprinting. The Department of Molecular and Human Genetics at Baylor College of Medicine receives revenue from clinical genetic testing conducted at Baylor Genetics (BG) Laboratories. The other authors report no disclosures relevant to the manuscript. Go to Neurology.org/NG for full disclosures.

Publication History

Received by *Neurology: Genetics* December 14, 2020. Accepted in final form March 11, 2021.

Appendix Authors

Name	Location	Contribution
Daniel G. Calame, MD, PhD	Division of Neurology and Developmental Neuroscience, Department of Pediatrics, Baylor College of Medicine, Houston, TX	Drafting/revision of the manuscript for content, including medical writing for content; major role in the acquisition of data; study concept or design; and analysis or interpretation of data
Jawid Fatih, BS	Department of Molecular and Human Genetics, Baylor College of Medicine, Houston, TX	Major role in the acquisition of data
Isabella Herman, MD, PhD	Department of Molecular and Human Genetics, Baylor College of Medicine, Houston, TX	Conducted the genetic analyses and reviewed the manuscript and provided critical revisions
Zeynep Coban Akdemir, PhD	Department of Molecular and Human Genetics, Baylor College of Medicine, Houston, TX	Supervised the genetic analyses and reviewed the manuscript and provided critical revisions
Haowei Du, MS	Department of Molecular and Human Genetics, Baylor College of Medicine, Houston, TX	Conceptualized the study and reviewed the manuscript and provided critical revisions
Shalini N. Jhangiani, BS	Department of Molecular and Human Genetics, Baylor College of Medicine, Houston, TX	Conceptualized the study and reviewed the manuscript and provided critical revisions
Richard A. Gibbs, PhD	Department of Molecular and Human Genetics, Baylor College of Medicine, Houston, TX	Analysis or interpretation of data
Dana Marafi, MD, MSc	Department of Pediatrics (D.M.), Faculty of Medicine, Kuwait University, Safat, Kuwait	Drafting/revision of the manuscript for content, including medical writing for content, and analysis or interpretation of data
Davut Pehlivan, MD	Department of Molecular and Human Genetics, Baylor College of Medicine, Houston, TX	Drafting/revision of the manuscript for content, including medical writing for content, and analysis or interpretation of data

Appendix (continued)

Name	Location	Contribution
Jennifer E. Posey, MD, PhD	Department of Molecular and Human Genetics, Baylor College of Medicine, Houston, TX	Drafting/revision of the manuscript for content, including medical writing for content, and analysis or interpretation of data
Timothy Lotze, MD	Department of Molecular and Human Genetics, Baylor College of Medicine, Houston, TX	Drafting/revision of the manuscript for content, including medical writing for content
Pedro Mancias, MD	Department of Molecular and Human Genetics, Baylor College of Medicine, Houston, TX	Drafting/revision of the manuscript for content, including medical writing for content
Meenakshi Bidwai Bhattacharjee, MD	Pathology and Laboratory Medicine, University of Texas Health Science Center at Houston-McGovern Medical School, Houston, TX	Drafting/revision of the manuscript for content, including medical writing for content, and major role in the acquisition of data
James R. Lupski, MD, PhD, DSc (hon)	Department of Pediatrics, Baylor College of Medicine, Houston, TX	Drafting/revision of the manuscript for content, including medical writing for content; major role in the acquisition of data; study concept or design; and analysis or interpretation of data

References

- Sung SS, Brassington AM, Krakowiak PA, Carey JC, Jorde LB, Bamshad M. Mutations in *TNNT3* cause multiple congenital contractures: a second locus for distal arthrogryposis type 2B. *Am J Hum Genet.* 2003;73(1):212–214.
- Zhao N, Jiang M, Han W, et al. A novel mutation in *TNNT3* associated with Sheldon-Hall syndrome in a Chinese family with vertical talus. *Eur J Med Genet.* 2011;54(3):351–353.
- Beck AE, McMillin MJ, Gildersleeve HI, et al. Spectrum of mutations that cause distal arthrogryposis types 1 and 2B. *Am J Med Genet A.* 2013;161A(3):550–555.
- Wei B, Jin JP. Troponin T isoforms and posttranscriptional modifications: evolution, regulation and function. *Arch Biochem Biophys.* 2011;505(2):144–154.
- Robinson P, Lipscomb S, Preston LC, et al. Mutations in fast skeletal troponin I, troponin T, and beta-tropomyosin that cause distal arthrogryposis all increase contractile function. *FASEB J.* 2007;21(3):896–905.
- Sandaradura SA, Bournazos A, Mallawaarachchi A, et al. Nemaline myopathy and distal arthrogryposis associated with an autosomal recessive *TNNT3* splice variant. *Hum Mutat.* 2018;39(3):383–388.
- Karaca E, Harel T, Pehlivan D, et al. Genes that affect brain structure and function identified by rare variant analyses of mendelian neurologic disease. *Neuron.* 2015;88(3):499–513.
- Eldomery MK, Coban-Akdemir Z, Harel T, et al. Lessons learned from additional research analyses of unsolved clinical exome cases. *Genome Med.* 2017;9(1):26.
- Karaca E, Posey JE, Coban Akdemir Z, et al. Phenotypic expansion illuminates multilocus pathogenic variation. *Genet Med.* 2018;20(12):1528–1537.
- Lupski JR, Belmont JW, Boerwinkle E, Gibbs RA. Clan genomics and the complex architecture of human disease. *Cell.* 2011;147(1):32–43.
- Gonzaga-Jauregui C, Yesil G, Nistala H, et al. Functional biology of the Steel syndrome founder allele and evidence for clan genomics derivation of *COL27A1* pathogenic alleles worldwide. *Eur J Hum Genet.* 2020;28(9):1243–1264.
- Ju Y, Li J, Xie C, et al. Troponin T3 expression in skeletal and smooth muscle is required for growth and postnatal survival: characterization of *Tnnt3(tm2a(KOMP) Wtsi)* mice. *Genesis.* 2013;51(9):667–675.
- Coban-Akdemir Z, White JJ, Song X, et al. Identifying genes whose mutant transcripts cause dominant disease traits by potential gain-of-function alleles. *Am J Hum Genet.* 2018;103(2):171–187.
- Pehlivan D, Bayram Y, Gunes N, et al. The genomics of arthrogryposis, a complex trait: candidate genes and further evidence for oligogenic inheritance. *Am J Hum Genet.* 2019;105(1):132–150.
- Sewry CA, Laitila JM, Wallgren-Pettersson C. Nemaline myopathies: a current view. *J Muscle Res Cell Motil.* 2019;40(2):111–126.
- Johnston JJ, Kelley RI, Crawford TO, et al. A novel nemaline myopathy in the Amish caused by a mutation in troponin T1. *Am J Hum Genet.* 2000;67(4):814–821.
- Fox MD, Carson VJ, Feng HZ, et al. *TNNT1* nemaline myopathy: natural history and therapeutic frontier. *Hum Mol Genet.* 2018;27(18):3272–3282.
- Géraud J, Dieterich K, Rendu J, et al. Clinical phenotype and loss of the slow skeletal muscle troponin T in three new patients with recessive *TNNT1* nemaline myopathy. *J Med Genet.* 2020. doi:10.1136/jmedgenet-2019-106714.
- Pellerin D, Aykanat A, Ellezam B, et al. Novel recessive *TNNT1* congenital core-rod myopathy in French Canadians. *Ann Neurol.* 2020;87(4):568–583.
- Cummings BB, Marshall JL, Tukiainen T, et al. Improving genetic diagnosis in Mendelian disease with transcriptome sequencing. *Sci Transl Med.* 2017;9(386):eaal5209.
- Gonorazky HD, Naumenko S, Ramani AK, et al. Expanding the boundaries of RNA sequencing as a diagnostic tool for rare mendelian disease. *Am J Hum Genet.* 2019;104(5):1007.
- Murdock DR, Dai H, Burrage LC, et al. Transcriptome-directed analysis for Mendelian disease diagnosis overcomes limitations of conventional genomic testing. *J Clin Invest.* 2020;131:e141500.