

# Acute major gastrointestinal bleeding caused by hookworm infection in a patient on warfarin therapy

## A case report

Yu Meng, PhD<sup>a</sup>, FangGen Lu, MD<sup>a</sup>, Lin Shi, MA<sup>a</sup>, MeiChu Cheng, MD<sup>b</sup>, Jie Zhang, MD<sup>a,\*</sup>

### Abstract

**Rationale:** The use of anticoagulants is a contributor to gastrointestinal (GI) bleeding. Most bleeding patients on anticoagulant therapy such as warfarin commonly have basic lesions existing in their GI mucosa.

**Patient concerns:** We report a case of major GI bleeding following the use of anticoagulants in a patient with hookworm infection.

**Diagnoses:** The patient was diagnosed with nephrotic syndrome with pulmonary embolism.

**Interventions:** He was treated with anticoagulants and suffered from acute major GI bleeding during the treatment. Capsule endoscopy revealed many hookworms in the lumen of jejunum where fresh blood was seen coming from the mucosa.

**Outcomes:** The patient was successfully rescued and cured with albendazole.

**Lessons:** Latent hookworm infection can be a cause of massive small-bowel hemorrhage in patients on anticoagulant therapy and anthelmintic treatment is the key to stop bleeding.

**Abbreviations:** APTT = activated partial thromboplastin, CTA = computed tomography angiography, GI = gastrointestinal, Hb = hemoglobin, INR = international normalized ratio, PT = prothrombin time.

**Keywords:** anticoagulants, capsule endoscopy, hookworm infection, major gastrointestinal bleeding, mucosal injury

## 1. Introduction

Anticoagulants are commonly used for the prophylaxis and treatment of intravascular thrombosis or thromboembolic diseases. The use of anticoagulants is a contributor to gastrointestinal (GI) bleeding.<sup>[1,2]</sup> The incidence of major GI bleeding as a serious complication of anticoagulant therapy is approximately 1–4% per year and the case fatality rate is up to 10%<sup>[3,4]</sup>. In anticoagulated patients with upper GI bleeding, gastroduodenal ulcers and erosions account for more than 50% of lesions;<sup>[5–8]</sup> erosive esophagitis is also an important cause<sup>[7]</sup>. Of patients presenting with GI bleeding (unspecified as lower or upper) on anticoagulant therapy, 25% to 33% were thought to have colonic polyps, diverticulae, and angiodysplasia being the most common<sup>[9,10]</sup>. Most bleeding patients commonly have basic lesions existing in their GI mucosa. But in 17% to 29% of patients with GI bleeding

on antiplatelets or anticoagulants, no mucosal abnormality is found on endoscopic investigation.<sup>[5,7]</sup> Here we report a case of hookworm infection resulting in acute massive hemorrhage in the small bowel of a patient on anticoagulant therapy.

## 2. Methods

The study was approved by the Research Ethics Committee of the 2nd Xiangya Hospital of Central South University. Informed consent was obtained from the patient for the publication of the report.

## 3. Case report

A 46-year-old male of the Han nationality was admitted to our Department of Nephrology with the complaint of proteinuria for 2 months, and chest pain and shortness of breath for 15 days. His illness started with left lower back pain and edema of lower limbs; urinalysis revealed urine protein to be positive. He had no history of gastrointestinal disease, malignancy, surgery or trauma, with no positive family history. On physical examination, mild pallor was present and blood pressure was 160/90 mm Hg. Chest auscultation showcased bilateral scattered fine rales. No other abnormal signs and symptoms were found or reported. Serological and laboratory findings showed a red blood cell count of  $3.82 \times 10^{12}/L$  ( $4.3\text{--}5.8 \times 10^{12}/L$ ), a hemoglobin (Hb) concentration of 111 g/L ( $130\text{--}175\text{ g/L}$ ), a platelet count of  $408 \times 10^9/L$  ( $125\text{--}350 \times 10^9/L$ ), an eosinophil count of  $0.44 \times 10^9/L$  ( $0.02\text{--}0.52 \times 10^9/L$ ), eosinophils percentage of 6.20% ( $0.4\text{--}8.0\%$ ), an albumin concentration of 14.9 g/L ( $40\text{--}55\text{ g/L}$ ), normal renal function, a triglyceride concentration of 3.83 mmol/L ( $<1.71\text{ mmol/L}$ ), a cholesterol concentration of 7.22 mmol/L ( $2.9\text{--}5.2\text{ mmol/L}$ ), a prothrombin time (PT) of 13.5 seconds ( $10\text{--}14\text{ seconds}$ ), international normalized ratio (INR) of 1.05

Editor: Ewa Janczewska.

The authors have no conflicts of interest to disclose.

<sup>a</sup> Department of Gastroenterology, <sup>b</sup> Department of Nephrology, 2nd Xiangya Hospital of Central South University, Changsha, Hunan Province, China.

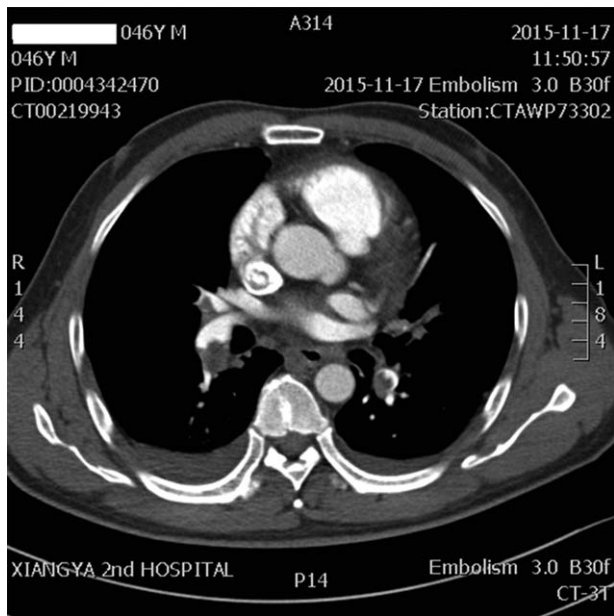
\* Correspondence: Jie Zhang, Department of Gastroenterology, 2nd Xiangya Hospital of Central South University, 139 Middle Renmin Road, Furong, Changsha 410011, Hunan Province, China (e-mail: jiezhang@csu.edu.cn).

Copyright © 2018 the Author(s). Published by Wolters Kluwer Health, Inc. This is an open access article distributed under the terms of the Creative Commons Attribution-Non Commercial License 4.0 (CCBY-NC), where it is permissible to download, share, remix, transform, and buildup the work provided it is properly cited. The work cannot be used commercially without permission from the journal.

Medicine (2018) 97:11(e9975)

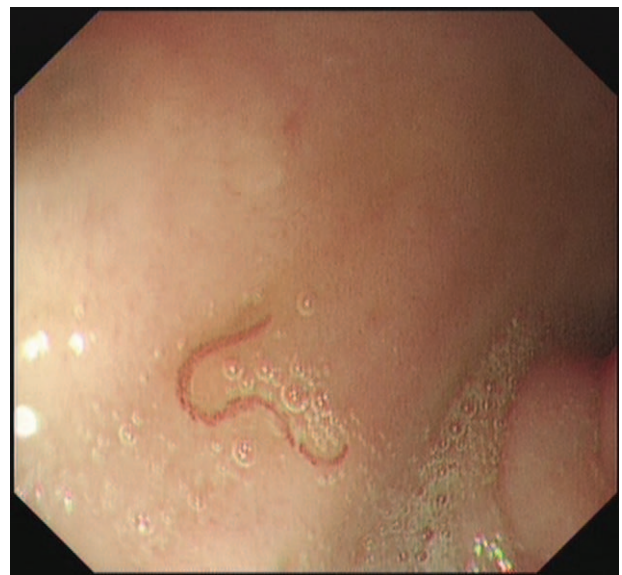Received: 26 April 2017 / Received in final form: 31 December 2017 / Accepted: 31 January 2018

<http://dx.doi.org/10.1097/MD.00000000000009975>



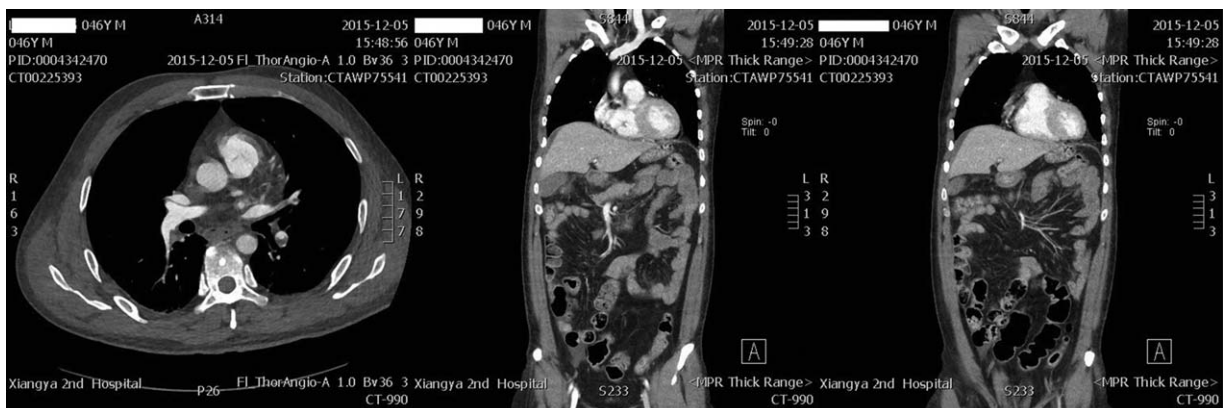**Figure 1.** Pulmonary CTA shows multiple embolism in left and right pulmonary artery. CTA=computed tomography angiography.

(0.85–1.20), activated partial thromboplastin (APTT) of 48.90 seconds (28–45 seconds), occult blood in stool, no ova in stool under microscope and quantity of protein in 24-hour urine to be 7588 mg/day (0–150 mg/day). Pulmonary computed tomography angiography (CTA) showed multiple embolism in bilateral pulmonary artery, pulmonary infarction and pulmonary infection (see Fig. 1). He was diagnosed with nephrotic syndrome, multiple pulmonary embolism with pulmonary infarction. On the day of admission, the patient was treated with methylprednisolone and tacrolimus. On the 4th day, he was given low-molecular-weight heparin 5000 IU twice daily. On the 6th day, he was given warfarin 2.5 mg once daily. On the 11th day, coagulation function was monitored and showed PT to be 14.5 seconds, INR of 1.11, APTT to be 44.60 seconds. The symptoms of shortness of breath and chest pain were relieved. On the morning of the 14th day, the patient suddenly defecated black-colored stool weighing about 400 g, with dizziness and cold sweats. Low-molecular-weight heparin and warfarin were discontinued immediately.

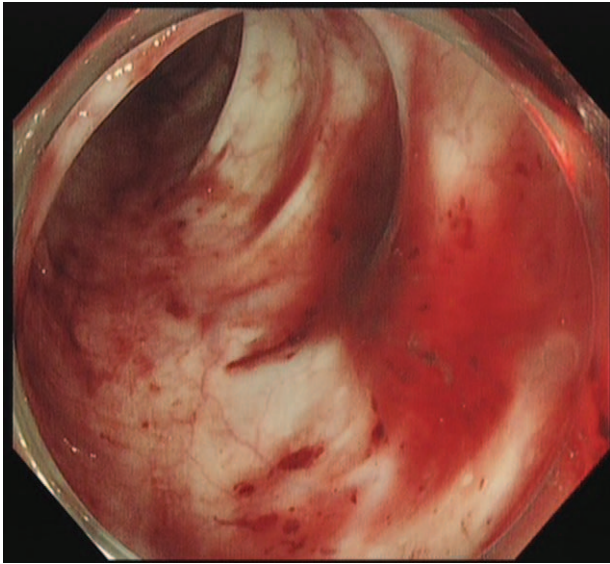


**Figure 3.** Gastroscopy image shows a hookworm moving on the patient's duodenal mucosa.

Peripheral blood cell count and coagulation function were monitored at once and revealed Hb to be 79 g/L, PT of 14.60 seconds, APTT of 31.30 seconds, and INR of 1.28. Fecal occult blood test was positive. Microscopic examination of stool revealed red blood cells in the entire field of view and no eggs. The patient was immediately made Non Per Os (NPO) and given a proton pump inhibitor, somatostatin, hemostasis, and transfusion, but the bleeding did not stop. He was rescued several times due to drop of blood pressure. On the 17th day, hemorrhage continued. PT ranged from 14.6 to 25 seconds and INR ranged from 1.0 to 2.24. The lowest level of Hb monitored was 41 g/L. He was given emergency treatment once again including transfusion. On the 19th day, CTA was performed and showed that the pulmonary embolism had improved—there were no signs of embolism in celiac artery, superior and inferior mesenteric arteries, but multiple low density images, what was considered to be thrombi remained in the inferior vena cava, left common iliac artery and bilateral internal iliac vein (see Fig. 2). Gastroscopy was performed and revealed 2 hookworms in the duodenal bulb, but no mucosal abnormalities were found (see Fig. 3).



**Figure 2.** (A) Pulmonary CTA shows improvement of the pulmonary embolism. (B) Abdominal CTA shows no signs of embolism in the superior mesenteric artery. (C) Abdominal CTA shows no signs of embolism in the celiac artery. CTA=computed tomography angiography.



**Figure 4.** Colonoscopy shows normal mucosa and bloody fluid in the colonic lumen.

Colonoscopy was performed and showed a large amount of bloody fluid in the intestinal lumen and no mucosal abnormality (see Fig. 4). On the 30th day, capsule endoscopy was performed and revealed many hookworms in the lumen of the jejunum where active bleeding and fresh blood clots were seen (see Fig. 5). The patient was given albendazole 400 mg twice daily for 3 days. Five days later, the color of his stool turned normal. Nine days later, the level of Hb was 66 g/L; no occult blood was detected in stool and coagulation function showed INR of 2.1. Eleven days later, the patient was discharged and given warfarin 2.5 mg once daily again. After the 6-month follow-up visit, the concentration of Hb increased to 110 g/L; no occult blood and no eggs were detected in his stool. Ten months later, anticardiolipin antibodies were detected and the results were negative. The activities of antithrombin III, protein C and protein S were normal.

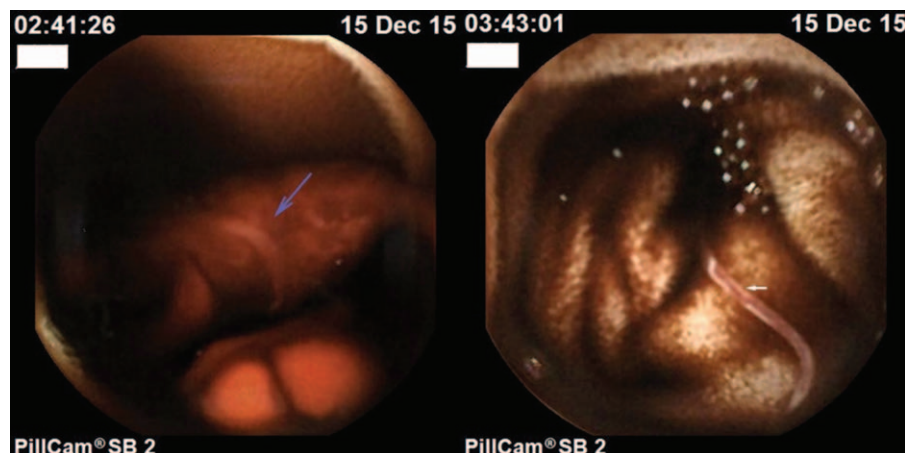
#### 4. Discussion

Hookworm infection is one of the most common chronic infections worldwide, especially in poor, rural areas in the tropics and subtropics. Hookworms parasitize small bowels of humans and release anticoagulative substances to facilitate sucking blood.<sup>[11,12]</sup> A hookworm can cause a small amount of blood loss per day.<sup>[13]</sup> When a large number of hookworms infest the intestines, patients generally present with severe anemia because of chronic blood loss. Interestingly, the patient had no GI bleeding symptoms prior to admission and presented with mild anemia on admission; furthermore, his fecal occult blood test was negative. The reasons may be as follows: blood of the patient was in a hypercoagulable state due to nephrotic syndrome, thus his blood was less able to be sucked by the worms and exude from mucosal injuries, and injuries of vascular wall were able to be blocked quickly.

However, sudden massive GI hemorrhage occurred during the period of anticoagulant therapy. After performance of gastroscopy and colonoscopy with no abnormal findings, massive small bowel bleeding was suspected. Capsule endoscopy was performed and revealed a large number of hookworms in the small bowel. After anthelmintic treatment, bleeding stopped very soon. Thus latent hookworm infection was considered to be the cause of massive GI bleeding during anticoagulant therapy. We inferred that remission of hypercoagulability due to anticoagulant therapy were conducive for hookworms to be better able to suck blood and could trigger major bleeding from the mucosal and vascular injuries.

It is worth mentioning that there is currently no consensus on the place of capsule endoscopy in patients with severe overt suspected small bowel bleeding. A study has suggested that capsule endoscopy may be a promising diagnostic means in the emergency situation.<sup>[14]</sup> Moreover, hookworms in the lumen of small bowel cannot be detected by red-cell scintigraphy and angiography which have been recommended as the first-line procedure for patients with massive suspected small bowel hemorrhage.<sup>[15]</sup> By contrast, capsule endoscopy may be an effective tool to diagnose hookworm infection in small intestine.

In conclusion, latent hookworm infection can also act as a cause of acute major GI bleeding in patients on warfarin therapy and anthelmintic treatment is the key to stop bleeding.



**Figure 5.** Capsule endoscopy shows many hookworms in the middle and distal jejunum and one end of some worms inserted into the intestinal mucosa.

## References

- [1] Johnsen SP, Sorensen HT, Mellemkjoer L, et al. Hospitalisation for upper gastrointestinal bleeding associated with use of oral anticoagulants. *Thromb Haemost* 2001;86:563–8.
- [2] Wolf AT, Wasan SK, Saltzman JR. Impact of anticoagulation on rebleeding following endoscopic therapy for nonvariceal upper gastrointestinal hemorrhage. *Am J Gastroenterol* 2007;102:290–6.
- [3] Guerrouij M, Uppal CS, Alklabi A, et al. The clinical impact of bleeding during oral anticoagulant therapy: assessment of morbidity, mortality and post-bleed anticoagulant management. *J Thromb Thrombolysis* 2011;31:419–23.
- [4] Ansell J, Hirsh J, Hylek E, et al. American College of Chest Physicians. Pharmacology and management of the vitamin K antagonists: American College of Chest Physicians Evidence-Based Clinical Practice Guidelines (8th-edition). *Chest* 2008;133:160s–98s.
- [5] Choudari CP, Rajgopal C, Palmer KR. Acute gastrointestinal haemorrhage in anticoagulated patients: diagnoses and response to endoscopic treatment. *Gut* 1994;35:464–6.
- [6] Tabibian N. Acute gastrointestinal bleeding in anticoagulated patients: a prospective evaluation. *Am J Gastroenterol* 1989;84:10–2.
- [7] Taha AS, Angerson WJ, Knill-Jones RP, et al. Upper gastrointestinal mucosal abnormalities and blood loss complicating low-dose aspirin and antithrombotic therapy. *Aliment Pharmacol Ther* 2006;23:489–95.
- [8] Thomopoulos KC, Mimidis KP, Theocharis GJ, et al. Acute upper gastrointestinal bleeding in patients on long-term oral anticoagulation therapy: endoscopic findings, clinical management and outcome. *World J Gastroenterol* 2005;11:1365–8.
- [9] Rubin TA, Murdoch M, Nelson DB. Acute GI bleeding in the setting of supratherapeutic international normalized ratio in patients taking warfarin: endoscopic diagnosis, clinical management, and outcomes. *Gastrointest Endosc* 2003;58:369–73.
- [10] Wilcox CM, Truss CD. Gastrointestinal bleeding in patients receiving long-term anticoagulant therapy. *Am J Med* 1988;84:683–90.
- [11] Ledizet M, Harrison LM, Koskia RA, et al. Discovery and pre-clinical development of antithrombotics from hematophagous invertebrates. *Curr Med Chem Cardiovasc Hematol Agents* 2005;3:1–0.
- [12] Stassens P, Bergum PW, Gansemans Y, et al. Anticoagulant repertoire of the hookworm *Ancylostoma caninum*. *Proc Natl Acad Sci USA* 1996;93:2149–54.
- [13] Roche M, Layrisse M. The nature and causes of “hookworm anemia”. *Am J Trop Med Hyg* 1966;15:1029.
- [14] Leclaire S, Iwanicki-Caron I, Di-Fiore A, et al. Yield and impact of emergency capsule enteroscopy in severe obscure-overt gastrointestinal bleeding. *Endoscopy* 2012;44:337–42.
- [15] Gerson LB, Fidler JL, Cave DR, et al. ACG Clinical Guideline: diagnosis and management of small bowel bleeding. *Am J Gastroenterol* 2015;110:1265–87.