

Double plastic stent implantation for recurrent acute pancreatitis with incomplete pancreas divisum: a case report and literature review

Journal of International Medical Research

49(11) 1–6

© The Author(s) 2021

Article reuse guidelines:

sagepub.com/journals-permissions

DOI: 10.1177/03000605211060142

journals.sagepub.com/home/imr

Kunyi Liu*, Xuechen Liu*, Chengyi Shi,
Siqi Liu, Hongwei Du, Yan Li, Na Wang ,
Zhijie Feng and Huiqing Jiang

Abstract

Pancreas divisum (PD) is a common pancreatic malformation caused by the failure of fusion between ventral and dorsal pancreatic ducts. There is a small branch of communication between the two systems in incomplete PD, and this variation has an incidence of 15%. A 43-year-old female patient presented to our department with recurrent abdominal pain. Magnetic resonance cholangiopancreatography (MRCP) showed that the ventral pancreatic duct was curved, with a local pouchlike dilatation. Endoscopic ultrasonography supported the diagnosis of incomplete PD and showed a thin branch of communication between ventral and dorsal pancreatic ducts. Endoscopic retrograde cholangiopancreatography (ERCP) and papillotomy of the minor papilla with double plastic stent implantation were performed. One pancreatic plastic stent was inserted across the minor and major papilla over the guide wire, creating a U-shape. The other wire-guided plastic stent was inserted through the minor papilla into the dorsal pancreatic duct. The pancreatic fluid drained smoothly after stent placement. During the 6-month follow-up, the patient remained well, without recurrence of pancreatitis.

*These authors contributed equally to this work.

Corresponding author:

Na Wang, Department of Gastroenterology, The Second Hospital of Hebei Medical University, Hebei Key Laboratory of Gastroenterology, Hebei Institute of Gastroenterology, 215 Heping West Road, Shijiazhuang, Hebei 050000, China.

Email: wangna1975@126.com

Department of Gastroenterology, Hebei Key Laboratory of Gastroenterology, Hebei Institute of Gastroenterology, The Second Hospital of Hebei Medical University, Shijiazhuang, Hebei Province, China



Creative Commons Non Commercial CC BY-NC: This article is distributed under the terms of the Creative Commons Attribution-NonCommercial 4.0 License (<https://creativecommons.org/licenses/by-nc/4.0/>) which permits non-commercial use, reproduction and distribution of the work without further permission provided the original work is attributed as specified on the SAGE and Open Access pages (<https://us.sagepub.com/en-us/nam/open-access-at-sage>).

Keywords

Incomplete pancreatic divisum, recurrent acute pancreatitis, endoscopic retrograde cholangiopancreatography, endoscopic sphincterotomy, magnetic resonance cholangiopancreatography, stent implantation

Date received: 31 May 2021; accepted: 28 October 2021

Introduction

Pancreas divisum (PD) is a pancreatic malformation caused by the failure of fusion between ventral and dorsal pancreatic ducts.¹ For incomplete PD, there is a small branch of communication between the two systems, with an incidence of 15%.² Only 5% of patients with PD develop symptomatic disease,³ presenting as recurrent acute pancreatitis (RAP), chronic pancreatitis, and chronic abdominal pain.⁴ Currently, endoscopic retrograde cholangiopancreatography (ERCP), including endoscopic sphincterotomy (EST), is recommended for the treatment of incomplete PD.⁵ However, double plastic stent implantation, which combines a U-shaped stent with a dorsal pancreatic duct stent, has not been reported. We encountered a patient with incomplete PD presenting with RAP, and this article describes the ERCP procedure with double plastic stent implantation. This case report will add valuable knowledge to clinical practice.

Case presentation

A 43-year-old woman with RAP presented to our department with abdominal pain that persisted despite medical treatment. She was diagnosed as having acute pancreatitis 4 years earlier because of abdominal pain. The symptoms had worsened in the past 6 months, occurring every 2 to 3 weeks, without a definitive etiology, and symptoms improved after conservative

treatment. Serological laboratory testing showed increased blood amylase and lipase concentrations, and abdominal computed tomography revealed acute pancreatitis. Magnetic resonance cholangiopancreatography (MRCP) showed that the ventral pancreatic duct was curved, with a local pouchlike dilatation (Figure 1). Endoscopic ultrasonography supported the diagnosis of incomplete PD and showed a thin branch of communication between ventral and dorsal pancreatic ducts (Figure 2). These examinations ruled out the possibility of intraductal papillary mucinous neoplasms and pancreatic tumor.

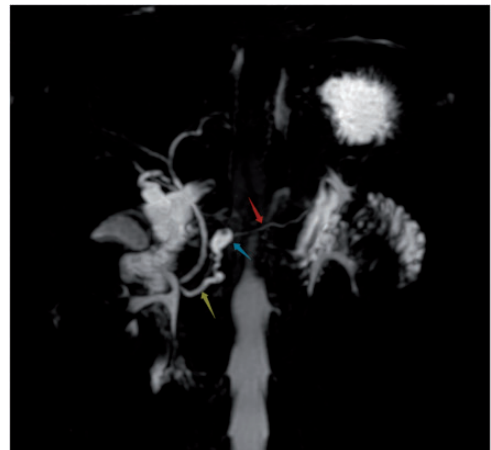


Figure 1. Magnetic resonance cholangiopancreatography of a 43-year-old woman with recurrent acute pancreatitis showing the curved ventral pancreatic duct (yellow arrow) with a local pouchlike dilatation (blue arrow). The dorsal pancreatic duct (red arrow) is also seen.

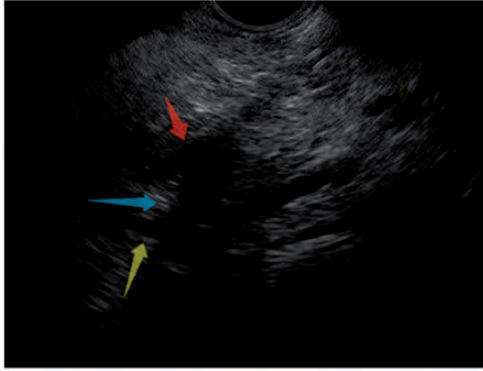

Figure 2. Endoscopic ultrasonography showing a thin branch (blue arrow) of communication between the ventral pancreatic duct (yellow arrow) and the dorsal pancreatic duct (red arrow).

With the patient's medical history, serological indicators, and imaging results, we diagnosed RAP and incomplete PD. ERCP was performed, with papillotomy of the minor papilla and double plastic stent implantation. After cannulating the pancreatic duct through the major papilla (Figure 3a), we injected radiopaque contrast material. Pancreatography showed that the ventral pancreatic duct was short and tortuous, and that it communicated with the dorsal pancreatic duct via a thin duct (Figure 3b). Fortunately, the guide wire (Terumo, Tokyo, Japan) exited the minor papilla (Figure 3c). Minor papilla sphincterotomy was then performed with

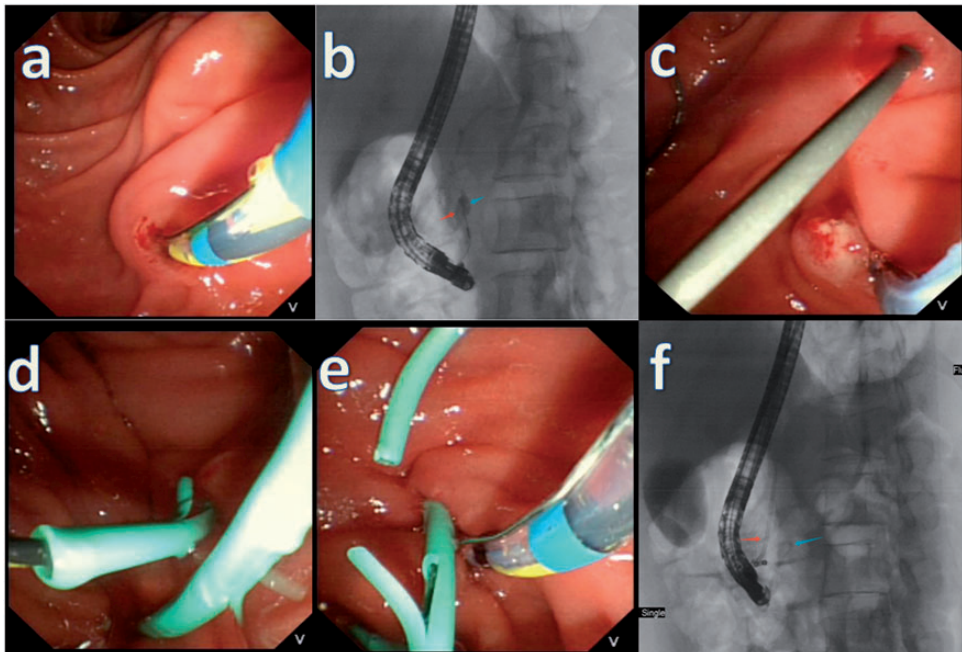


Figure 3. Endoscopic retrograde cholangiopancreatography showing (a) cannulation of the pancreatic duct through the major papilla; (b) a short and tortuous ventral pancreatic duct (blue arrow) and communication with the dorsal pancreatic duct via a thin duct (red arrow); (c) the guide wire exiting the minor papilla; (d) inserting a pancreatic plastic stent across the major and minor papilla over the guide wire, creating a U-shape; (e) dorsal pancreatic duct cannulation via the minor papilla with the intention of inserting a second stent; (f) U-shaped stent (blue arrow) implantation combined with dorsal pancreatic duct stent implantation (red arrow).

a sphincterotome, and a pancreatic plastic stent (9 cm, 5 F; Cook Medical, Winston-Salem, NC, USA) was inserted across the major and minor papillae over the guide wire, creating a U-shape (Figure 3d). The U-shaped stent served only as support for the pancreatic ducts and did not provide adequate drainage. For better drainage, stenting was followed by dorsal pancreatic duct cannulation via the minor papilla, with the intent of inserting a second stent (Figure 3e). After repeated pancreatic duct dilation failed with a dilation catheter, pancreatic duct dilation was performed successfully when an 8.5-F Soehendra stent retriever (Cook Medical) was rotated inward. Next, another wire-guided (Jagwire; Boston Scientific, Natick, MA, USA) pancreatic plastic stent (9 cm, 7 F; Cook Medical) was inserted through the minor papilla into the dorsal pancreatic duct (Figure 3f). The pancreatic fluid then drained smoothly. Postoperatively, the patient was treated medically with anti-cholinergic medications and pancreatic enzyme supplementation, and she improved symptomatically. During the 6-month follow-up, she remained well without recurrence of pancreatitis and abdominal pain. This report conforms to the CARE guidelines.⁶

Discussion

PD leads to the main dorsal pancreatic duct draining through the minor papilla and the small ventral pancreatic duct draining through the major papilla.¹ MRCP is a non-invasive imaging modality that is considered the first choice in the diagnosis of PD.⁷ Secretin-enhanced MRCP has been suggested to enhance the detection of pancreatic malformations, including incomplete PD, with a sensitivity of 85% and specificity of 97%.⁸ ERCP is considered the gold-standard for the diagnosis of PD; however, ERCP is an invasive procedure

involving radiation exposure and leads to a 10% to 15% complication rate, with an incidence of post-ERCP pancreatitis of up to 10%.⁹⁻¹² ERCP is used only for the diagnosis of uncertain cases and the treatment of symptomatic cases.⁴ Asymptomatic patients with PD do not require further diagnostic evaluation or treatment. In symptomatic patients with PD, conservative treatment, such as with anti-infection and anti-cholinergic medications, and pancreatic enzyme supplementation, should be considered. Therapeutic intervention is reserved for patients with recurrent attacks of acute pancreatitis or with clear imaging changes.¹³

ERCP, with EST, with or without plastic stent implantation, is the first-choice therapeutic intervention in patients with symptomatic PD.^{5,14-16} Plastic stent implantation in the pancreatic duct can prevent postoperative restenosis; however these stents should be replaced periodically.² Zeng et al.¹⁷ described placing a U-shaped plastic stent in four patients with RAP and incomplete PD, with no complications related to the ERCP. Six months later, ERCP was performed again to remove the stent, and no patients experienced recurrence of pancreatitis and abdominal pain. Michailidis et al.¹⁸ confirmed that the efficacy of ERCP in PD is 67.5%. Our patient with incomplete PD presenting with RAP underwent ERCP with papillotomy of the minor papilla with double plastic stent implantation. A U-shaped stent was combined with a dorsal pancreatic duct stent. The difference between previous cases and our case is that, in our case, pancreatic duct dilation was performed with the Soehendra stent retriever rather than with a standard dilation catheter, which ensured a successful operation. The etiology in patients with PD presenting with RAP is poor drainage of pancreatic fluid because of stenosis of the minor papilla. Therapy with ERCP aims to enlarge the

minor papilla and adequately drain the pancreatic fluid. Owing to proximal stenosis of the dorsal pancreatic duct, which was found during pancreatography through the minor papilla in our patient, only a U-shaped stent was sufficient to provide smooth drainage. The U-shaped stent served only as support for the pancreatic ducts. The dorsal pancreatic duct drains most of the pancreatic juice; therefore, stent placement in the dorsal pancreatic duct was necessary. To obtain long-term drainage, combining U-shaped stent implantation with dorsal pancreatic duct stent implantation can prevent postoperative stenosis and reduce the time between stent replacements.

To date, there are no reports of double plastic stent implantation in PD. This procedure is difficult to perform and requires time. Additionally, surgeons must have extensive experience performing endoscopic procedures. Surgery should be considered in cases of failure of endoscopic treatment in symptomatic patients or in cases of chronic pancreatitis and local complications, such as common bile duct stenosis or main pancreatic duct stenosis.^{19,20} Life-long follow-up of patients with incomplete PD is mandatory.

Conclusion

Incomplete PD is a rare pancreatic malformation, and only a small number of patients develop symptoms. ERCP with EST is the first-line treatment for symptomatic patients with incomplete PD. The symptoms in our patient, who underwent ERCP with papillotomy of the minor papilla and double plastic stent implantation to improve pancreatic fluid drainage, improved significantly, and she remained well without recurrence of pancreatitis during the follow-up period. This procedure should be widely promoted and applied in clinical practice.

Author contributions

Na Wang and Xuechen Liu were the main authors responsible for the patient's diagnosis and treatment. Kunyi Liu drafted the manuscript. Na Wang was responsible for revising the manuscript and submitting the revisions. Chengyi Shi and Siqi Liu assisted in the collection of the clinical data. Hongwei Du and Yan Li assisted with the therapeutic procedures. Zhijie Feng and Huiqing Jiang participated in the multidisciplinary treatment of the patient and made suggestions regarding the references.

Ethics statement

The patient provided written informed consent for the treatment. Ethical approval of this study by our institution was not required because the manuscript is a case report. The patient provided consent to use her data for scientific research.


Declaration of conflicting interest

The authors declare that there is no conflict of interest.

Funding

The authors disclosed receipt of the following financial support for the research, authorship, and publication of this article: This study was supported by the Chinese Foundation for Hepatitis Prevention and Control – TianQing Liver Disease Research Fund Subject, China (TQGB20200050).

ORCID iD

Na Wang  <https://orcid.org/0000-0001-5316-527X>

References

1. Taj MA, Qureshi S, Ghazanfar S, et al. Pancreas divisum. *J Coll Physicians Surg Pak* 2016; 26: 96–99.
2. Gutta A, Fogel E and Sherman S. Identification and management of pancreas divisum. *Expert Rev Gastroenterol Hepatol* 2019; 13: 1089–1105.
3. Dimitriou I, Katsourakis A, Nikolaidou E, et al. The main anatomical variations of the pancreatic duct system: review of the

- literature and its importance in surgical practice. *J Clin Med Res* 2018; 10: 370–375.
4. Ferri V, Vicente E, Quijano Y, et al. Diagnosis and treatment of pancreas divisum: a literature review. *Hepatobiliary Pancreat Dis Int* 2019; 18: 332–336.
 5. Fukumori D, Ogata K, Ryu S, et al. An endoscopic sphincterotomy of the minor papilla in the management of symptomatic pancreas divisum. *Hepatogastroenterology* 2007; 54: 561–563.
 6. Gagnier JJ, Kienle G, Altman DG, et al. The CARE guidelines: consensus-based clinical case reporting guideline development. *Headache* 2013; 53: 1541–1547.
 7. Matos C, Metens T, Devière J, et al. Pancreas divisum: evaluation with secretin-enhanced magnetic resonance cholangiopancreatography. *Gastrointest Endosc* 2001; 53: 728–733.
 8. Rustagi T and Njei B. Magnetic resonance cholangiopancreatography in the diagnosis of pancreas divisum: a systematic review and meta-analysis. *Pancreas* 2014; 43: 823–828.
 9. Quest L and Lombard M. Pancreas divisum: opinio divisa. *Gut* 2000; 47: 317–319.
 10. Rustagi T and Golioto M. Diagnosis and therapy of pancreas divisum by ERCP: a single center experience. *J Dig Dis* 2013; 14: 93–99.
 11. Andriulli A, Loperfido S, Napolitano G, et al. Incidence rates of post-ERCP complications: a systematic survey of prospective studies. *Am J Gastroenterol* 2007; 102: 1781–1788.
 12. Lans JJ, Geenen JE, Johanson JF, et al. Endoscopic therapy in patients with pancreas divisum and acute pancreatitis: a prospective, randomized, controlled clinical trial. *Gastrointest Endosc* 1992; 38: 430–434.
 13. Mariani A, Di Leo M, Petrone MC, et al. Outcome of endotherapy for pancreas divisum in patients with acute recurrent pancreatitis. *World J Gastroenterol* 2014; 20: 17468–17475.
 14. Lutzak GD, Gluck M, Ross AS, et al. Endoscopic minor papilla sphincterotomy in patients with santoriniceles reduces pain and improves quality of life. *Dig Dis Sci* 2013; 58: 2075–2081.
 15. Yamamoto N, Isayama H, Sasahira N, et al. Endoscopic minor papilla balloon dilation for the treatment of symptomatic pancreas divisum. *Pancreas* 2014; 43: 927–930.
 16. Gerke H, Byrne MF, Stiffler HL, et al. Outcome of endoscopic minor papillotomy in patients with symptomatic pancreas divisum. *JOP* 2004; 5: 122–131.
 17. Zeng QS, Wu CC, Liu W, et al. Endoscopic placement of a U-shaped plastic stent in patients with recurrent acute pancreatitis and incomplete pancreas divisum. *Am J Gastroenterol* 2017; 112: 1777.
 18. Michailidis L, Aslam B, Grigorian A, et al. The efficacy of endoscopic therapy for pancreas divisum: a meta-analysis. *Ann Gastroenterol* 2017; 30: 550–558.
 19. Schlosser W, Rau BM, Poch B, et al. Surgical treatment of pancreas divisum causing chronic pancreatitis: the outcome benefits of duodenum-preserving pancreatic head resection. *J Gastrointest Surg* 2005; 9: 710–715.
 20. Liao Z, Gao R, Wang W, et al. A systematic review on endoscopic detection rate, endotherapy, and surgery for pancreas divisum. *Endoscopy* 2009; 41: 439–444.