



# Development of High-Intensity Focused Ultrasound Therapy for Inferior Turbinate Hypertrophy

Joon Kon Kim<sup>1,\*</sup> · Sung-Woo Cho<sup>1,\*</sup> · Hyojin Kim<sup>2</sup> · Sung Chan Jo<sup>3</sup> · Hyung Gu Kim<sup>4</sup> · Tae-Bin Won<sup>1</sup> · Jeong-Whun Kim<sup>1</sup> · Jae Hyun Lim<sup>5</sup> · Chae-Seo Rhee<sup>1,6</sup>

Departments of<sup>1</sup>Otorhinolaryngology-Head and Neck Surgery and<sup>2</sup>Pathology, Seoul National University Bundang Hospital, Seongnam;  
<sup>3</sup>KORUST Company Limited, Anyang; <sup>4</sup>Department of Otorhinolaryngology-Head and Neck Surgery, Hanyang National University Guri Hospital, Guri; <sup>5</sup>Department of Otorhinolaryngology-Head and Neck Surgery, National Police Hospital, Seoul; <sup>6</sup>Department of Otorhinolaryngology-Head and Neck Surgery, Seoul National University Hospital, Seoul, Korea

**Objectives.** Inferior turbinate (IT) hypertrophy is the main cause of chronic nasal obstruction. We developed a high-intensity focused ultrasound (HIFU) ablation device to treat patients with IT hypertrophy.

**Methods.** First, computed tomography images of patients with no evidence of sinonasal disease were evaluated to measure and compare the IT, medial mucosal thickness (MT), and space between the nasal septum and IT according to clinical characteristics such as septal deviation. A HIFU prototype was developed based on the above human anatomical studies. The experimental study was performed in five pigs; the nasal volume and histological changes at 1 and 4 weeks postoperatively were evaluated to compare the efficacy of HIFU turbinoplasty with that of radiofrequency turbinoplasty and a control group.

**Results.** The mean medial MT of the anterior, middle, and posterior portions of the IT were  $4.66 \pm 1.14$ ,  $4.23 \pm 0.97$ , and  $6.17 \pm 1.29$  mm, respectively. The mean medial space was  $2.65 \pm 0.79$  mm. The diameter and focal depth of the prototype were 4 mm and 3 mm, respectively. HIFU showed no postoperative complications, including bleeding or scar formation. After HIFU treatment, the nasal volume increased by  $196.62 \text{ mm}^3$  (7.8%) and  $193.74 \text{ mm}^3$  (8.3%) at 1 week and 4 weeks, compared with the increase of  $87.20 \text{ mm}^3$  (3.1%) and  $213.81 \text{ mm}^3$  (9.0%), respectively, after radiofrequency therapy. A qualitative histological analysis after radiofrequency turbinoplasty showed epithelial layer disruption at 1 week and increased fibrosis, along with decreased glandular structure, at 4 weeks. The HIFU group had an intact epithelial layer at 1 week postoperatively. However, significant differences were observed at 4 weeks, including increased fibrosis and decreased glandular structure.

**Conclusion.** The efficacy and safety of HIFU turbinoplasty were demonstrated in an animal study. Our results warrant further human clinical trials.

**Keywords.** High-Intensity Focused Ultrasound Ablation; Turbinates; Postoperative Complications; Radiofrequency Therapy

## INTRODUCTION

Turbinate hypertrophy is one of the most common causes of chronic nasal obstruction. A recent study showed that 10%–20% of the global population suffers from nasal obstruction due to allergic rhinitis, which causes a significant deterioration in the quality of life [1]. The common causes of turbinate hypertrophy include allergic rhinitis, vasomotor rhinitis, and chronic hypertrophic rhinitis. Although transient symptom relief can be

• Received November 29, 2020

Revised March 1, 2021

Accepted March 9, 2021

• Corresponding author: Chae-Seo Rhee

Department of Otorhinolaryngology-Head and Neck Surgery, Seoul National University Hospital, 101 Daehak-ro, Jongno-gu, Seoul 03080, Korea

Tel: +82-2-2072-3991, Fax: +82-2-745-2387

E-mail: csrhee@snu.ac.kr

\*These authors contributed equally to this article.

Copyright © 2022 by Korean Society of Otorhinolaryngology-Head and Neck Surgery.

This is an open-access article distributed under the terms of the Creative Commons Attribution Non-Commercial License (<https://creativecommons.org/licenses/by-nc/4.0>) which permits unrestricted non-commercial use, distribution, and reproduction in any medium, provided the original work is properly cited.

achieved through medical treatment with agents such as antihistamines, oral vasoconstrictors, or intranasal corticosteroids, a significant proportion of patients require surgical volume reduction [2].

Techniques for reducing turbinate hypertrophy include microdebrider-assisted turbinoplasty, radiofrequency turbinoplasty, and turbinate resection. Most of these techniques are effective; however, the outcomes differ depending on the degree of technical invasiveness [3]. Turbinoplasty is usually performed as an adjunctive procedure during septoplasty, which is generally performed inside an operating theater. Under those circumstances, techniques providing better outcomes may be preferred, as bleeding can be easily controlled. However, office-based turbinoplasty is becoming more common, leading to an unmet need for minimally invasive turbinoplasty.

In recent years, high-intensity focused ultrasound (HIFU) has been used for the treatment of benign lesions in obstetrics, gynecology, and urology. HIFU is a noninvasive treatment that effectively coagulates and necrotizes target tissues (mainly solid tumors) that are located deep within the body without damaging the surrounding tissue [4]. It is applied at a frequency of 0.8–3.0 MHz depending on the type of instrument used [5]. Ultrasonic waves within this range can reach the tissue and rapidly increase the target focal temperature to 80°C or higher, leading to coagulation and necrosis. Furthermore, the ultrasonic waves also cause vibration in the target tissue, resulting in compression and thinning of molecular structures [6]. High-energy HIFU can be amplified and targeted to a very small focal area without damaging the surrounding tissue. Unlike traditional surgery for tissue removal, HIFU does not physically penetrate the surface tissue. In light of the low likelihood of epithelial injury, minimal bleeding and rapid wound healing are expected. As the factors influencing hypertrophy include thickened mucosa with enlarged venous sinusoids [7], we hypothesized that tissue reduction or ablation with HIFU, which involves a minimal injury, may be a good treatment option for refractory chronic rhinitis. Therefore, the goal of this study was to design and develop an optimal HIFU device for the treatment of turbinate hypertrophy.

This study aimed to confirm that HIFU leads to an appropriate response when used for the treatment of turbinate hypertro-

phy causing nasal obstruction in patients with chronic rhinitis. Thus, the present study describes the development of a HIFU device for turbinoplasty. The diameter and focal depth were determined, and an efficacy study was then conducted in an animal model.

## MATERIALS AND METHODS

### Human anatomical analysis

A retrospective review of prospectively collected data was performed. This study was approved by the Institutional Review Board of Seoul National University Bundang Hospital (IRB No. B-2012-652-101) and the requirement for informed consent was waived. Patients age >18 years who underwent non-contrast computed tomography (CT) examination from 2016 to 2017 at our hospital, without any evidence of sinonasal disease, were evaluated. The CT scans were performed with a single-source multi-detector CT system with 256 channels (iCT; Philips, Amsterdam, the Netherlands). The scanning parameters were as follows: tube voltage, 120 kVP; tube current, 200 mAs; scan mode, axial scan mode pitch, 0.39; detector collimation, 64×0.625 mm; gantry rotation time, 0.5 seconds; and slice thickness, 0.9 mm. The acquired raw data were then reconstructed using images with 2-mm section thickness. The CT images of all patients were reviewed using a picture archiving and communication system (INFINITT Healthcare, Seoul, Korea). Medial mucosal thickness (MT) of the inferior turbinate (IT) and the space between the nasal septum and the IT (medial space [MS]) were measured in both nasal cavities (Fig. 1). The MT was measured at three points: anterior—starting point of the IT bone; posterior—ending point of the IT bone; and middle—halfway between the anterior and posterior points. Further analysis was performed according to the presence of septal deviation. Septal deviation was defined as a greater than 5° angle of the nasal septum based on a straight line from the crista galli to the anterior nasal spine [8]. All data were presented as mean ± standard deviation. The analysis of variance test with Tukey test for post-hoc analysis was used to identify potential significance between the values of no septal deviation, narrow side of septal deviation and wide side

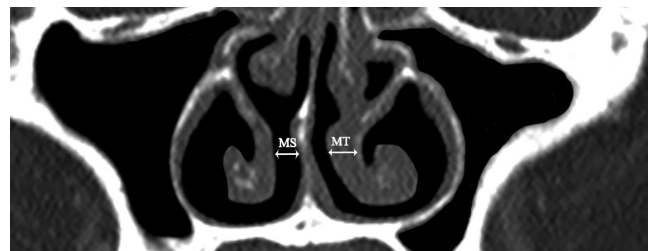


Fig. 1. Anatomical evaluation of the nasal cavity by computed tomography. The unit for mucosal thickness (MT) and medial space (MS) is millimeters.

### HIGHLIGHTS

- High-intensity focused ultrasound (HIFU) turbinoplasty can coagulate and necrotize submucosal layer without damaging the epithelial layer.
- Decreased glandular structure and increased fibrosis were observed after HIFU ablation.
- The safety and efficacy of HIFU turbinoplasty was demonstrated through animal experiments.

of septal deviation. Based on the average of the patient's features, we use an appropriately sized HIFU instrument. The criterion for statistical significance was set at  $P < 0.05$ . The statistical analysis was performed using the IBM SPSS ver. 22.0 (IBM Corp., Armonk, NY, USA).

### Animal study

#### Animals

This study was conducted after receiving approval from the Animal Experimental Ethics Committee of Seoul National University Bundang Hospital (No.18-0192-S1A0). Five *Sus scrofa*, weighing approximately 20 kg each and aged 1–2 months were purchased from Cronex (CRONEX, Hwaseong, Korea). Pig was selected as an animal model because of the similarities in the similar cylindrical structure of the IT as compared with that in humans [9]. The experimental group was determined, and the experimental schedule was set to conduct the animal experiments.

#### Procedure

HIFU turbinoplasties were performed and the outcome measures were compared to those of radiofrequency turbinoplasties using a Coblator with a ReFlex Ultra 45 wand (Arthrocare, Austin, TX, USA). HIFU turbinoplasty was performed in the left nostril of all subjects, but in the right nostril of subject 5. Radiofrequency turbinoplasty was performed in the right nostril of subjects 2 and 4. No further treatment was performed in the right nostrils of subjects 1 and 3. Subjects 1 and 2 were sacrificed 1 week after the procedure, whereas subjects 3 to 5 were sacrificed 4 weeks postoperatively (Supplementary Fig. 1).

All turbinoplasty were performed under general anesthesia. Based on the distance from the nostril, the probe was moved back and forth to cover the entire IT. The HIFU procedure was divided into two types (high and low) according to the energy intensity of the HIFU. High and low procedures were performed with 120 shots of total energy irradiation for approximately 5 minutes (Supplementary Video 1). The high-HIFU procedure had a 40-ms output time with a heal region size of  $1.08 \times 1.17$  mm, while the low-HIFU procedure used a 24-ms output time with a heal region size of  $0.5 \times 0.75$  mm. Radiofrequency turbinoplasty was

performed with the wand in position for 15 seconds at a power level of 5 mV, with three passes performed submucosally. Care was taken to avoid mucosal penetration posteriorly.

#### Outcome evaluation

Each animal underwent endoscopic and nasal CT scans before and after the surgery. Endoscopy was performed with a 2.7-mm standard rigid endoscope (Olympus Medical Systems Corp., Tokyo, Japan). CT scans were performed before surgery and on the 7th (week 1) and 28th (week 4) day after the surgeries. The volume of the nasal cavity was calculated by summation of the values obtained by multiplying the thickness between the cut and the intranasal cross-sectional area measured at each image cut on the coronal CT image (Supplementary Fig. 2). Preoperative medial MT and MS of our porcine models were measured in the same manner as human to check the feasibility of our device.

The histological evaluation of each group was confirmed by periodic acid-Schiff staining. In the experimental group, the mucous membrane of the IT was collected 1 and 4 weeks after the surgery. A single pathologist who was blinded to the procedure analyzed the pathologic findings. A qualitative assessment of the sections was performed to identify the type of epithelium, presence of inflammation and fibrosis, and estimate the population of the submucosal glands and venous sinusoids.

## RESULTS

### Human anatomical study

In total, 117 patients were analyzed, of whom 57 had a straight septum, while the other 60 presented with a deviated nasal septum. The mean medial MT of the anterior, middle, and posterior portions of the IT was  $4.66 \pm 1.14$ ,  $4.23 \pm 0.97$ , and  $6.17 \pm 1.29$  mm, respectively. The mean MS was  $2.65 \pm 0.79$  mm. The mean values of the anterior and posterior medial MT and the mean MS were significantly different among the study groups ( $P < 0.05$ ), with the values of the deviated septum (i.e., the wide side) being the highest. The results of the subgroup analysis are summarized in Table 1.

The optimal diameter and projection depth should correspond

Table 1. Characteristics of inferior turbinate hypertrophy using computed tomography

Characteristics	Total	Straight septum	Deviated septum (narrow)	Deviated septum (wide)	P-value
No. of patients	117	57	60	60	-
Medial MT (mm)					
Anterior	$4.66 \pm 1.14$	$4.56 \pm 1.18$	$4.15 \pm 1.12$	$5.37 \pm 1.59$	$< 0.001^{a,b)}$
Middle	$4.23 \pm 0.97$	$4.20 \pm 1.00$	$4.11 \pm 1.21$	$4.41 \pm 1.11$	0.191
Posterior	$6.17 \pm 1.29$	$5.87 \pm 1.22$	$6.35 \pm 1.50$	$6.54 \pm 1.50$	$0.044^{a)}$
MS (mm)	$2.65 \pm 0.79$	$2.55 \pm 0.79$	$2.57 \pm 0.94$	$2.91 \pm 0.92$	$0.014^{b)}$

Values are presented as mean  $\pm$  standard deviation.

MT, mucosal thickness; MS, medial space.

<sup>a)</sup> $P < 0.05$  compared to straight septum. <sup>b)</sup> $P < 0.05$  compared to deviated septum (narrow).

to the MS (2.65 mm) and the MT (4.23–6.17 mm), respectively. However, to deliver sufficient energy to the target tissue, the diameter had to be increased and was adjusted to 4 mm. Considering the gap between the airway space and the diameter, the projection depth was adjusted to 3 mm (Fig. 2).

#### Treatment outcomes in the animal study

Eschar formation, bleeding, and crusting were observed 1 week after the procedure in the radiofrequency group, unlike the con-

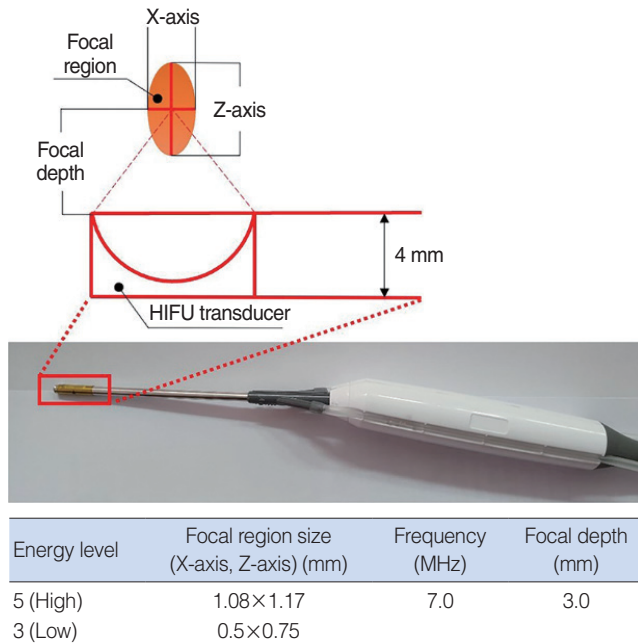


Fig. 2. Specifications of the high-intensity focused ultrasound (HIFU) prototype design and energy. X, width of the healing region; Z, length of the healing region.

trol group (Fig. 3A, B, E, and F). In the radiofrequency group, bleeding and crusting were no longer visible at 4 weeks postoperatively; however, scar formation was observed (Fig. 3C, D, G, and H). In contrast, mucosal damage such as eschar formation and bleeding were not observed in the HIFU group (Fig. 3I-L). At 1 week postoperatively, the nasal volume decreased in the control group and the HIFU-low group by 132.51 mm<sup>3</sup> (5.5%) and 134.70 mm<sup>3</sup> (4.5%), respectively, but increased in the radiofrequency and HIFU-high groups by 87.20 mm<sup>3</sup> (3.1%) and 196.62 mm<sup>3</sup> (7.8%), respectively (Fig. 4A). At 4 weeks postoperatively, the nasal cavity volume decreased in the control group by 241.08 mm<sup>3</sup> (9.5%), while in the radiofrequency, HIFU-low, and HIFU-high groups, the volume increased by 213.81 mm<sup>3</sup> (9.0%), 57.99 mm<sup>3</sup> (2.4%), and 193.74 mm<sup>3</sup> (8.3%) (range, 135.83–230.26 mm<sup>3</sup>), respectively (Fig. 4B). The histological analysis showed marked structural changes in the radiofrequency and HIFU-treated areas when compared with the control areas (Fig. 5A). Epithelial layer disruption, increased fibrosis, and decreased glandular structure were observed in the radiofrequency-treated turbinates at 1 week after turbinoplasty (Fig. 5B). In contrast, an intact epithelial layer without any evidence of tissue disruption was observed in the HIFU-treated turbinates at 1 week postoperatively (Fig. 5C); however, the HIFU-treated group showed increased polymorphonuclear cell infiltration. Infiltrated polymorphonuclear cells tended to be more prominent in the turbinates treated with high-level HIFU than in those treated with low-level HIFU (Fig. 5D-F). At 4 weeks after turbinoplasty, both the radiofrequency and HIFU groups showed increased fibrosis, decreased glandular structure, and a healed epithelial layer compared to the control areas (Fig. 6A-C). Both levels of HIFU turbinoplasty showed similar results (Fig. 6D-F).

The preoperatively measured mean medial MT was 1.55 mm (range, 1.1–1.9 mm), 1.42 mm (range, 1.3–1.6 mm) and 1.87 mm

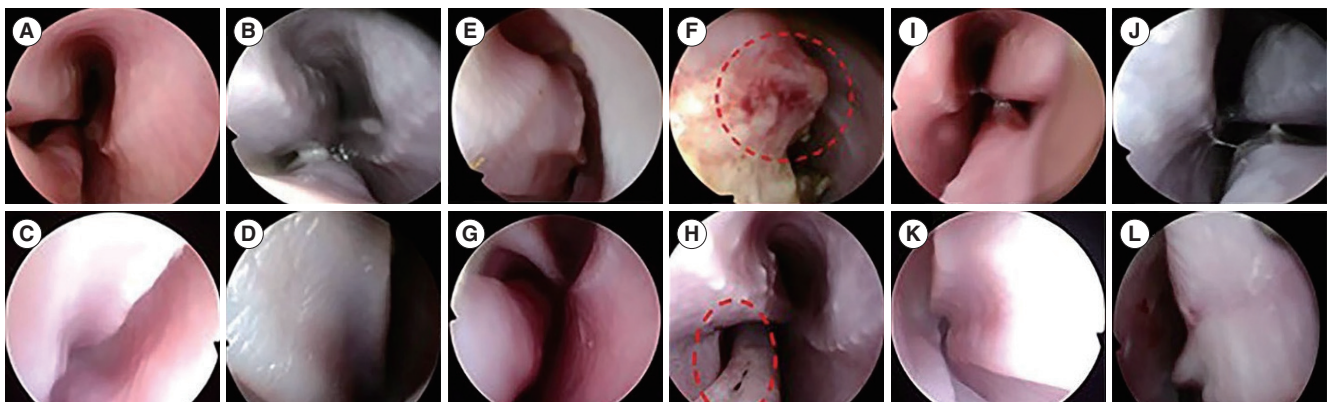


Fig. 3. Nasal endoscopic findings in the control, radiofrequency, and high-intensity focused ultrasound (HIFU) groups. (A, B) Preoperative and postoperative findings in the control group (week 1). (C, D) Preoperative and postoperative findings in the control group (week 4). (E, F) Preoperative and postoperative findings in the radiofrequency group (week 1). (G, H) Preoperative and postoperative findings in the radiofrequency group (week 4). The red circle in (F) indicates eschar formation, bleeding, and crust formation, while the red circle in (H) indicates scar formation. (I, J) Preoperative and postoperative findings in the HIFU group (week 1). (K, L) Preoperative and postoperative findings in the HIFU group (week 4).

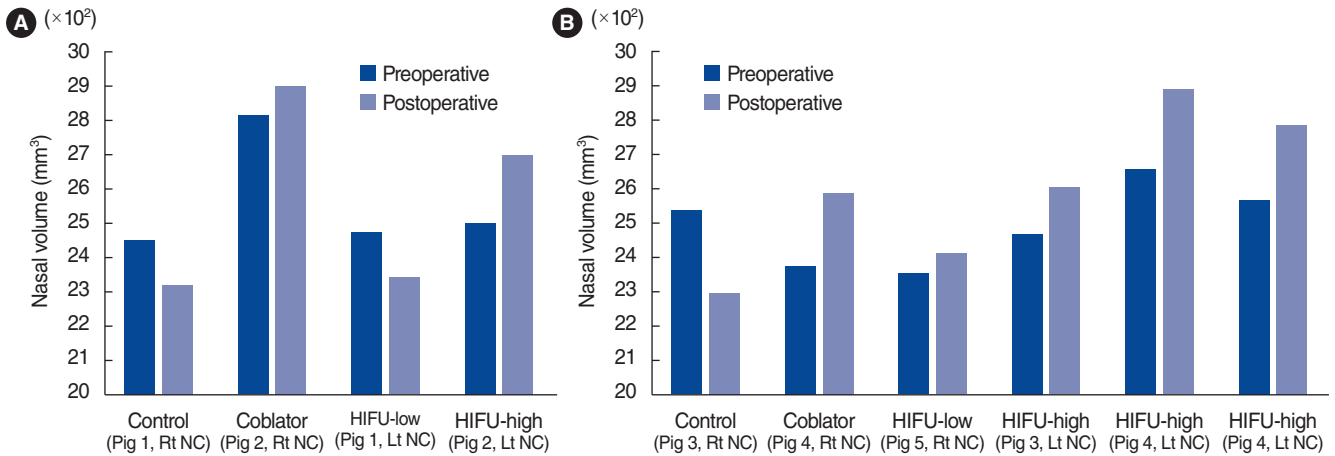


Fig. 4. Computed tomography evaluation of the control, radiofrequency, and high-intensity focused ultrasound (HIFU) groups at 1 week (A) and 4 weeks (B) after turbinoplasty. The numerical values refer to the three-dimensional volume of the nasal cavity (mm<sup>3</sup>) measured preoperatively and postoperatively. Rt, right; Lt, left; NC, nasal cavity.

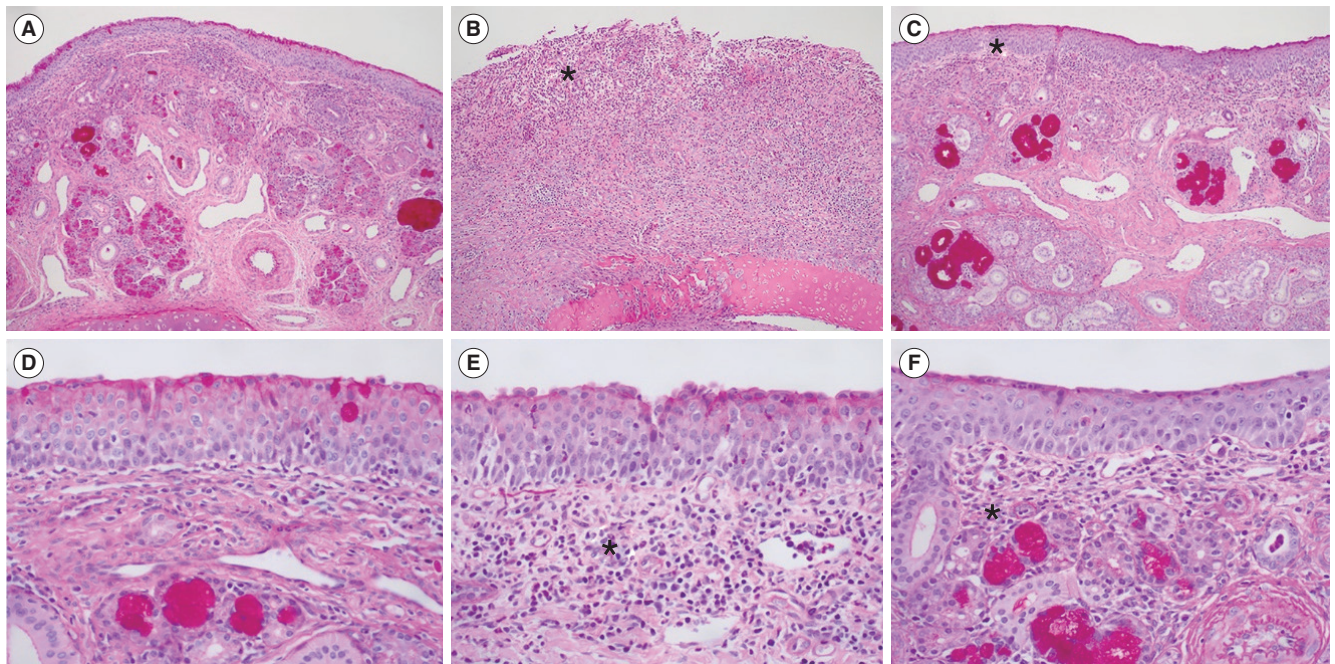
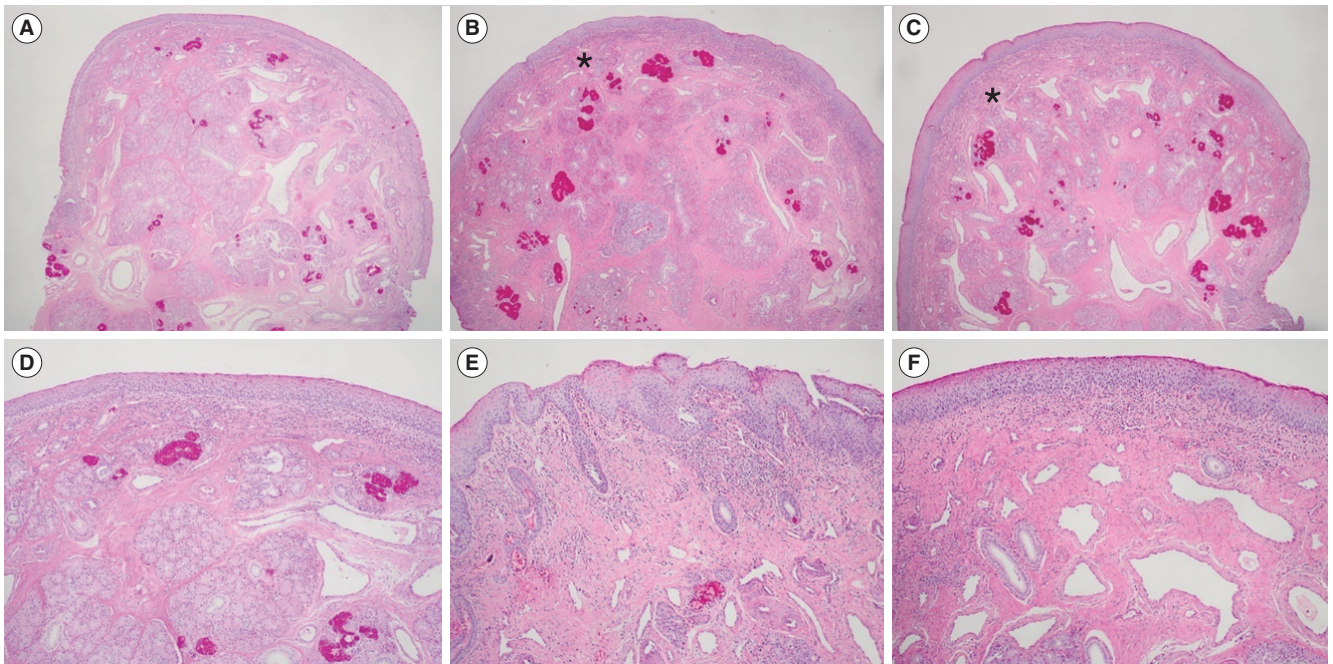


Fig. 5. Pathologic evaluation of the control, radiofrequency, high-intensity focused ultrasound (HIFU)-high, and HIFU-low groups at postoperative week 1 (slide magnification: A-C, ×100; D-F, ×400; periodic acid–Schiff staining). (A) Control, (B) radiofrequency group (asterisk, epithelial disruption), (C) HIFU group (asterisk, intact epithelium), (D) control, (E) HIFU-high group, (F) HIFU-low group (asterisks, similar findings of infiltrated polymorphonuclear cells). The infiltrated polymorphonuclear cells appear more prominently in the turbinates treated with a high level of HIFU than in those treated with low level of HIFU.

(range, 1.1–2.1 mm) at the anterior, middle, and posterior points, respectively. The mean MS was 2.35 mm (range, 1.8–3.5 mm) (Supplementary Table 1). The medial MT and MS of the porcine model were lower than those of humans, suggesting that the feasibility of our animal model is limited.

## DISCUSSION

Hypertrophy of the IT is an important anatomical factor leading to chronic nasal obstruction in patients with chronic rhinitis. The factors underlying hypertrophy include mucosal and bone hypertrophy with the enlargement of venous sinusoids [7]. These pathophysiological findings can be corrected by total/partial tur-



**Fig. 6.** Pathologic evaluation of the control, radiofrequency, and high-intensity focused ultrasound (HIFU) groups at postoperative week 4 (slide magnification: A-C,  $\times 100$ ; D-F,  $\times 400$ ; periodic acid-Schiff staining). (A) Control, (B) radiofrequency group, (C) HIFU group (asterisks, similar findings of increased fibrosis/decreased glandular structure). (D) Control, (E) HIFU-high group, (F) HIFU-low group. Similar findings of increased fibrosis and decreased glandular structure are confirmed in both the HIFU-high and HIFU-low groups.

binate resection or turbinoplasty, for which various techniques have been developed. The classical technique involves raising a submucosal flap and partially removing the submucosal tissues. Recently, remarkably simple radiofrequency ablation equipment and microdebriders have been developed for turbinoplasty. A recent meta-analysis showed that both radiofrequency and microdebrider-assisted turbinoplasty were equally effective and achieved significant improvements in cases of nasal obstruction [10].

The current study described the development of a HIFU prototype for turbinoplasty, which was based on evaluations of the diameter and focal depth of the nasal cavity. HIFU turbinoplasty showed no complications such as bleeding or scar formation and efficiently reduced the turbinate size in a porcine model. Unlike a radiofrequency device, which requires saline injection, pre-treatment manipulation of the turbinate is not needed with our HIFU-assisted technique. Therefore, the device should fit the existing space in the nasal cavity for prompt device manipulation and visualization of the nasal cavity. The HIFU prototype device was designed considering the available range of the nasal cavity airway space. The mucosal depth was also considered to be effective for the HIFU treatment, as a HIFU wave beyond this depth would be transmitted through the bone, potentially reducing the treatment efficacy, whereas a shallower depth could lead to epithelial damage. In this study, the space in the nasal cavity was approximately 2.65 mm. For technical reasons, a diameter of at

least 4 mm was needed to deliver sufficient energy, which would lead to compression of the turbinate mucosa with a difference of approximately 1.35 mm from the thickness (4.23–6.17 mm). Therefore, the projection depth was adjusted to 3 mm.

The histological examinations showed an increased submucosal polymorphonuclear cell count, decreased glandular structure, and increased fibrosis in the HIFU-treated group. Increased fibrosis and the replacement of large venous sinusoids by veins are well-known histological changes observed in radiofrequency turbinoplasty [11]. We also found that histological changes in the IT mucosa were affected by the HIFU intensity, as demonstrated by the higher degree of polymorphonuclear cell infiltration after 1 week of treatment in the HIFU-high group than in the HIFU-low group. Polymorphonuclear cell infiltration with maintenance of the tissue architecture is the hallmark of coagulation necrosis, which may be further replaced by tissue fibrosis [12]. The higher degree of submucosal polymorphonuclear cell infiltration appeared to increase the nasal airway space after 1 week in the HIFU-high group to a greater extent than in the HIFU-low group. However, the difference between the HIFU-high and HIFU-low groups was not significant after 4 weeks. Our results indicate that both levels of HIFU treatment were effective for IT hypertrophy after 4 weeks of treatment.

In our study, the efficacy of HIFU turbinoplasty was similar to that of radiofrequency turbinoplasty. However, HIFU turbinoplasty was more beneficial for treatment of the IT than radiofre-

quency turbinoplasty. First, on endoscopic and histological examinations, the HIFU group showed minimal epithelial layer damage and no bleeding, while the radiofrequency group showed gross and microscopic tissue surface damage. Second, HIFU was performed in a local area without additional preparation such as saline injection. Therefore, the convenience and utility of the HIFU device indicate its potential for use in the outpatient setting.

The depth of our prototype was 3 mm, which was larger than the medial MT in our animal models. However, volume reduction was achieved in all the animal models 4 weeks after HIFU turbinoplasty. Multiple explanations can be proposed for this finding. First, since the energy transmission seemed to be focused on the turbinate bone, which has a high absorption rate, only a small portion of the ultrasound energy may have been transmitted to the soft tissue. However, thermal energy can be secondarily transmitted to the adjacent periosteum from the bone, which may have affected the turbinate mucosa [13]. Additionally, the presence of an oval-shaped healing region (1.08×1.17 mm) from the center indicates partial energy transmission to the turbinate mucosa. The effect of the focal depth on the efficacy of HIFU turbinoplasty needs to be further evaluated.

Our study has several limitations. First, a quantitative analysis was not performed to compare the histological changes. Second, while the nasal cycle is present in swine [14,15], we did not consider it when measuring the airway space by CT scans, and changes in the nasal airway space may have been affected by the nasal cycle [16]. Third, the HIFU turbinoplasty demonstrated only short-term efficacy. Therefore, additional studies using swine models may be warranted. However, this is the first study to demonstrate the efficacy of HIFU turbinoplasty in animal models by showing both radiological and histological changes after HIFU treatment. Considering the safety of HIFU turbinoplasty, human clinical studies may be initiated with our device.

In conclusion, in our study, nasal endoscopic findings showed better mucosal preservation in HIFU-treated turbinates than in radiofrequency-treated turbinates. The volume of the nasal cavity calculated by CT scans was higher in the HIFU-treated turbinates than in the non-treated turbinates, and this effect was similar to the changes observed in radiofrequency-treated turbinates. The histopathological findings of HIFU-treated turbinates revealed the induction of focal tissue coagulation of the submucosal layer, while preserving the mucosal layer. Therefore, HIFU turbinoplasty may be a useful technique to reduce IT hypertrophy without complications.

### CONFLICT OF INTEREST

No potential conflict of interest relevant to this article was reported.

### ACKNOWLEDGMENTS

This work was supported by the Industrial Strategic Technology Development Program (20006066, Development of Optical imaging guide HIFU [High-Intensity Focused Ultrasound] surgical system with less than 10 mm for sleep apnea treatment), funded by the Ministry of Trade, Industry & Energy (MOTIE, Korea).

### ORCID

Joon Kon Kim	<a href="https://orcid.org/0000-0002-6902-476X">https://orcid.org/0000-0002-6902-476X</a>
Sung-Woo Cho	<a href="https://orcid.org/0000-0003-0827-4471">https://orcid.org/0000-0003-0827-4471</a>
Hyojin Kim	<a href="https://orcid.org/0000-0001-9201-8328">https://orcid.org/0000-0001-9201-8328</a>
Sung Chan Jo	<a href="https://orcid.org/0000-0003-2005-9854">https://orcid.org/0000-0003-2005-9854</a>
Hyung Gu Kim	<a href="https://orcid.org/0000-0002-7847-8843">https://orcid.org/0000-0002-7847-8843</a>
Tae-Bin Won	<a href="https://orcid.org/0000-0003-2266-3975">https://orcid.org/0000-0003-2266-3975</a>
Jeong-Whun Kim	<a href="https://orcid.org/0000-0003-4858-3316">https://orcid.org/0000-0003-4858-3316</a>
Jae Hyun Lim	<a href="https://orcid.org/0000-0003-0699-8687">https://orcid.org/0000-0003-0699-8687</a>
Chae-Seo Rhee	<a href="https://orcid.org/0000-0002-1361-8585">https://orcid.org/0000-0002-1361-8585</a>

### AUTHOR CONTRIBUTIONS

Conceptualization: JWK, SWC, CSR. Data curation: SWC, JKK, JHL. Formal analysis: JKK. Methodology: CSR, SWC, JKK, HGK, SCJ, HJK, TBW. Writing—original draft: JKK, CSW. Writing—review & editing: SWC, JKK, CSR.

### SUPPLEMENTARY MATERIALS

Supplementary materials can be found via <https://doi.org/10.21053/ceo.2020.02383>.

### REFERENCES

1. Stewart M, Ferguson B, Fromer L. Epidemiology and burden of nasal congestion. *Int J Gen Med*. 2010 Apr;3:37-45.
2. Jang TY, Kim YH, Shin SH. Long-term effectiveness and safety of endoscopic vidian neurectomy for the treatment of intractable rhinitis. *Clin Exp Otorhinolaryngol*. 2010 Dec;3(4):212-6.
3. Cingi C, Ure B, Cakli H, Ozudogru E. Microdebrider-assisted versus radiofrequency-assisted inferior turbinoplasty: a prospective study with objective and subjective outcome measures. *Acta Otorhinolaryngol Ital*. 2010 Jun;30(3):138-43.
4. Jenne JW, Preusser T, Gunther M. High-intensity focused ultrasound: principles, therapy guidance, simulations and applications. *Z Med Phys*. 2012 Dec;22(4):311-22.
5. Kennedy JE, Ter Haar GR, Cranston D. High intensity focused ultrasound: surgery of the future? *Br J Radiol*. 2003 Sep;76(909):590-9.
6. Wang W, Wang Y, Tang J. Safety and efficacy of high intensity focused ultrasound ablation therapy for adenomyosis. *Acad Radiol*. 2009 Nov;16(11):1416-23.

7. Berger G, Hammel I, Berger R, Avraham S, Ophir D. Histopathology of the inferior turbinate with compensatory hypertrophy in patients with deviated nasal septum. *Laryngoscope*. 2000 Dec;110(12):2100-5.
8. Park DY, Noh MH, Park SB, Ban WW, Bae KG, Kang BS, et al. Radiological examinations of inferior turbinate in patients with or without deviated nasal septum by using computed tomography. *Korean J Otorhinolaryngol-Head Neck Surg*. 2016 Jan;59(1):28-34.
9. Stembirek J, Kyllar M, Putnova I, Stehlik L, Buchtova M. The pig as an experimental model for clinical craniofacial research. *Lab Anim*. 2012 Oct;46(4):269-79.
10. Acevedo JL, Camacho M, Brietzke SE. Radiofrequency ablation turbinoplasty versus microdebrider-assisted turbinoplasty: a systematic review and meta-analysis. *Otolaryngol Head Neck Surg*. 2015 Dec;153(6):951-6.
11. Berger G, Ophir D, Pitaro K, Landsberg R. Histopathological changes after coblation inferior turbinate reduction. *Arch Otolaryngol Head Neck Surg*. 2008 Aug;134(8):819-23.
12. Kumar V, Abbas AK, Fausto N, Aster JC. *Robbins and Cotran pathologic basis of disease*. London: Elsevier Health Sciences; 2014.
13. Catane R, Beck A, Inbar Y, Rabin T, Shabshin N, Hengst S, et al. MR-guided focused ultrasound surgery (MRgFUS) for the palliation of pain in patients with bone metastases: preliminary clinical experience. *Ann Oncol*. 2007 Jan;18(1):163-7.
14. Campbell WM, Kern EB. The nasal cycle in swine. *Rhinology*. 1981 Sep;19(3):127-48.
15. Kahana-Zweig R, Geva-Sagiv M, Weissbrod A, Secundo L, Soroker N, Sobel N. Measuring and characterizing the human nasal cycle. *PLoS One*. 2016 Oct;11(10):e0162918.
16. Hasegawa M, Kern EB. Variations in nasal resistance in man: a rhinomanometric study of the nasal cycle in 50 human subjects. *Rhinology*. 1978 Mar;16(1):19-29.