

Retroperitoneal Laparoscopic Pyelolithotomy in an Ectopic Pelvic Kidney

Ibrahim Halil Bozkurt, MD, Abdullah Cirakoglu, MD, Serafettin Ozer, MD

ABSTRACT

Background and Objectives: Retroperitoneal laparoscopic pyelolithotomy was performed in an ectopic pelvic kidney with renal pelvis calculi.

Methods and Results: Laparoscopic pyelolithotomy was successfully performed in an ectopic pelvic kidney by using the retroperitoneal route. The total operation time was 130 minutes, and the estimated blood loss was <50mL. The patient was discharged on the second postoperative day without any complications.

Conclusion: Laparoscopic pyelolithotomy is an effective treatment option for management of stones in the pelvis of an ectopic pelvic kidney. The retroperitoneal route may help to avoid intraoperative and postoperative complications.

Key Words: Laparoscopy, Pyelolithotomy, Ectopic kidney.

INTRODUCTION

The incidence of the pelvic kidney is approximated to be between 1/2200 and 1/3000.¹ Treatment of stones in ectopic pelvic kidneys poses a challenge to urologists. Laparoscopy assisted percutaneous nephrolithotomy; laparoscopic pyelolithotomy, robot-assisted laparoscopic pyelolithotomy, and shock-wave lithotripsy have important roles in the management of anomalous ectopic kidney calculi. Open surgery has become anecdotal. We present a case of stones in a pelvic ectopic kidney managed by retroperitoneal laparoscopic pyelolithotomy. Differently from the past case reports that used transperitoneal and transmesocolic routes, we performed the operation retroperitoneally. To our knowledge, this is the first case of ectopic pelvic kidney calculi managed with retroperitoneal laparoscopic pyelolithotomy.

CASE REPORT

A 23-year-old man presented with vague pain in the left inguinal and suprapubic region. He had no previous history of urinary tract infection, vesicoureteral reflux, or kidney stones. A urine culture excluded urinary tract infection. An abdominal ultrasonography revealed a single 15mm × 21mm calculus in the pelvis of the ectopic pelvic kidney with minimal pyelocaliectasis. The patient had no other congenital anomaly. Intravenous urography and noncontrast abdominal computed tomography confirmed the diagnosis (**Figure 1**, **Figure 2**). The pelvis of the ectopic kidney was rotated towards the anterior abdominal wall. Left ureteropelvic junction obstruction was excluded with a diuretic renogram. The estimated contribution of the left kidney to total renal function was 49% and that of the right was 51%.

One gram of cephalosporin was administered 60 minutes prior to the surgery. With the patient under general anesthesia, a retrograde pyelography (RGP) was obtained, which demonstrated a normal ureter. A JJ stent was placed over the guidewire in the lithotomy position. A Foley catheter was placed for bladder drainage. Subsequently, the patient was maintained in a supine position in a 30-degree Trendelenburg and 30-degree lateral position,

Kasimpasa Military Hospital, Istanbul, Turkey (all authors).

Address correspondence to: Ibrahim Halil Bozkurt, MD, Kasimpasa Military Hospital Urology Clinic Beyoglu, Istanbul 34440, Turkey, Telephone: 90 505 6578810, E-mail: ihalilbozkurt@yahoo.com

DOI: 10.4293/108680812X13427982376707

© 2012 by JSLS, *Journal of the Society of Laparoendoscopic Surgeons*. Published by the Society of Laparoendoscopic Surgeons, Inc.

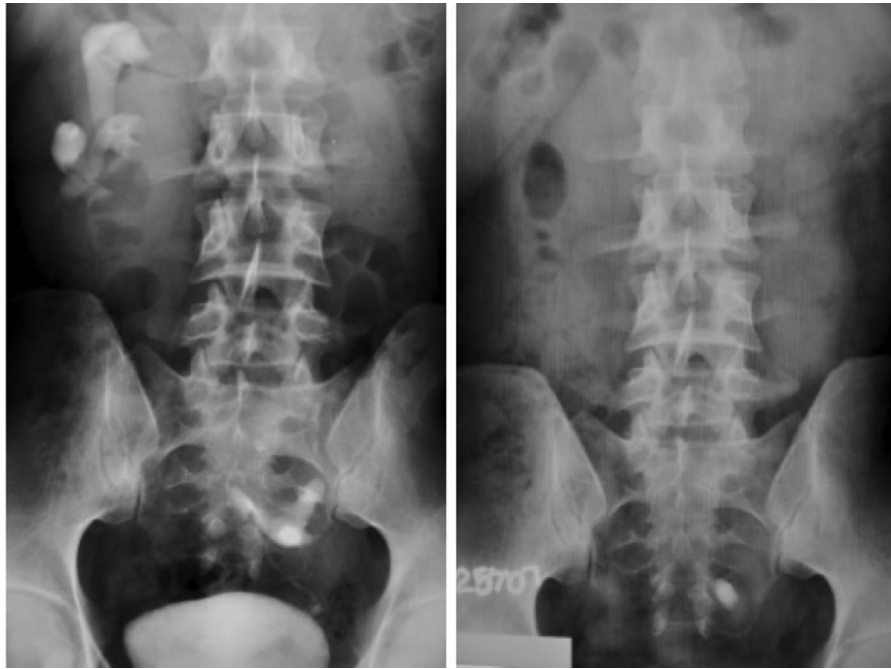

Figure 1. Intravenous urography images.

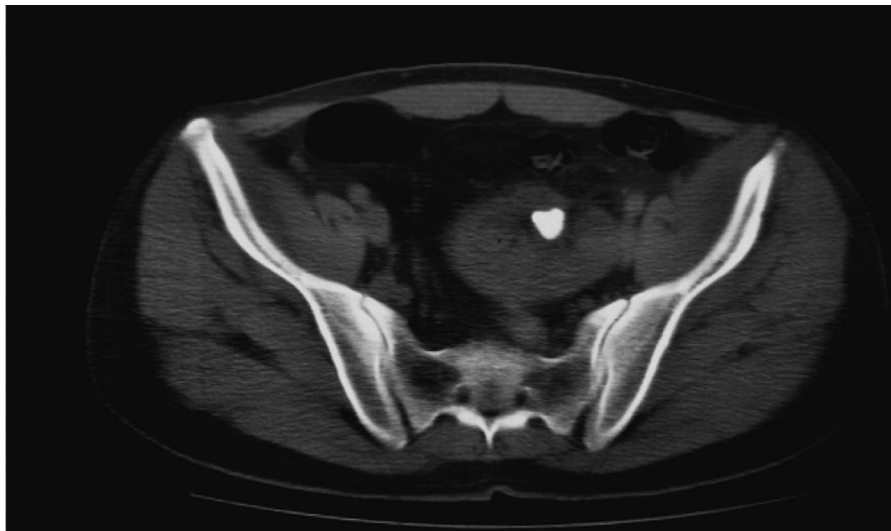


Figure 2. CT image of calculi.

left side up. A 1.5-cm incision was made just above and 2cm medial to the left anterior–superior iliac spine, and a 10-mm trocar was placed with the open technique after balloon (150cc) dilatation. Under 15-mm mercury CO₂ pneumoretroperitoneum and direct vision, a second 10-mm trocar was placed 2cm above the umbilicus and lateral to the left rectus muscle and a 5-mm trocar was placed in the left lower quadrant constituting a triangle

(**Figure 3**). Fluoroscopy helped us to identify the stone in the renal pelvis. The renal pelvis was dissected, and a longitudinal incision was made over the stone by using endoscissors. The stone was extracted intact with an endograsper after a 10-mm trocar was removed from the port site. The renal pelvis was closed using interrupted 4.0 Vicryl sutures. A drain was placed through the port site.

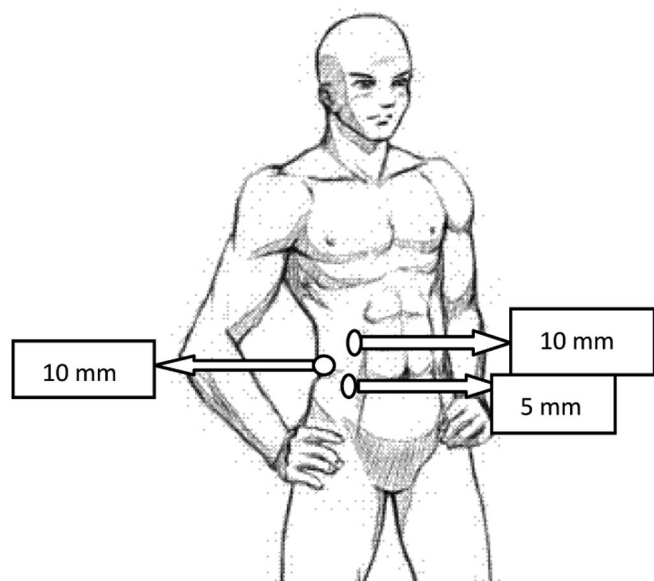


Figure 3. Trocar placement sites.

RESULTS

The total operation time was 130 minutes. The patient was stone free without any complications. Estimated blood loss was <50mL. The drain was removed on the first postoperative day. The patient recovered quickly and was discharged on the second postoperative day. The stone composition was reported as calcium-oxalated dihydrate. The JJ stent was removed 4 weeks after surgery as an office procedure with the patient under local anesthesia. Control intravenous urography revealed a stone-free functional kidney without any extravasation 6 weeks after surgery.

DISCUSSION

Ectopic kidney is a common congenital urological anomaly.¹ The abnormal insertion of the ureter, rotation anomalies, and different localization of the kidneys make the management of calculi in ectopic kidneys difficult. Although shock wave lithotripsy is purported to be an effective therapeutic option, 57% stone-free rates were reached in a study with a mean 2.3-cm² stone burden.² Also in this study,² authors suggested that the best results were obtained in patients with stone diameter <2cm.

Laparoscopy assisted percutaneous nephrolithotomy (PNL) was first described by Eshghi et al³ in a pelvic kidney. Several groups and authors have described different techniques for access points and nephroscopy route. The mobilization of the colon is needed to perform a puncture in the transab-

dominal route. The need for a nephrostomy catheter and the possible leakage of urine to the abdominal cavity are additional possible morbidities for patients. Laparoscopy assisted PNL is a good choice when the stone extends beyond the renal pelvis or lies in the calices.⁴

Transperitoneal and transmesocolic routes have been described for laparoscopic pyelolithotomy in the management of ectopic pelvic kidney calculi. Harmon et al⁵ reported a case in which pyelolithotomy was completed but the pyelotomy was not closed. Due to prolonged intraperitoneal urine leakage, an indwelling stent and urethral catheter were maintained for 8 days. In another case report, although the pyelotomy was closed, the patient experienced peritoneal leakage of urine after the Foley catheter was removed.⁶ Hoenig et al⁷ and Kamat et al⁸ have reported successful cases without any complications with the pyelotomy closed laparoscopically. Gupta et al⁹ described the transmesocolic route for laparoscopic pyelolithotomy in the management of ectopic pelvic kidney calculi. Authors have suggested this technique is safer because of the avoidance of additional procedures of mobilization of the bowel. In these reports, the operative time has averaged from 2 hours to 5 hours using a 3- or 4-port approach. Especially in transperitoneal laparoscopic pyelolithotomy, a fourth port is needed to retract the bowel.

Given the advantages of robot-assisted laparoscopic surgery, this technology has been applied to stone surgery. Nayyar et al¹⁰ reported a case of ectopic pelvic kidney with ureteropelvic junction obstruction and stones managed by robot-assisted laparoscopic pyeloplasty with successful stone removal.

In our case, we successfully used the retroperitoneal approach via 3 ports with fluoroscopic stone localization. The anteriorly rotated renal pelvis allowed us to perform the operation more easily without any contact with abnormal renal vessels. Successful closure of the small pyelotomy resulted in a short hospital stay. Via the retroperitoneal approach, we avoided the possible risk of bowel injury or major vascular injury associated with the mobilization of bowel. In addition, a fourth port was unnecessary to retract the bowel intraoperatively. Given that the entire technique was performed in the retroperitoneal space, in the event of a urine leak, the retroperitoneal approach would likely contain any developing hematoma and, thus, minimize symptomatology from this complication. In addition, it may aid sealing of the urine leak.

CONCLUSION

Laparoscopic pyelolithotomy is a safe and effective treatment option for management of stones in the ectopic pelvic kidney with a laterally and anterior-directed pelvis. The retroperitoneal route may help to avoid intraoperative and postoperative complications.

References:

1. Zafar FS, Lingeman JS. Value of laparoscopy in the management of calculi complicating renal malformations. *J Endourol.* 1996;10:379–383.
2. Tunc L, Tokgoz H, Tan MO, Kupeli B, Karaglan U, Bozkirli I. Stones in anomalous kidneys: results of treatment by shock wave lithotripsy in 150 patients. *Int J Urol.* 2004;11:831–836.
3. Eshghi AM, Roth JS, Smith AD. Percutaneous transperitoneal approach to a pelvic kidney for endourological removal of stag-horn calculus. *J Urol.* 1985;134:525–527.
4. Holman E, Toth C. Laparoscopically assisted percutaneous transperitoneal nephrolithotomy in pelvic dystopic kidneys: Experience in 15 successful cases. *J Laparoendosc Adv Surg Tech A.* 1998;8:431–435.
5. Harmon WJ, Kleer E, Segura JW. Laparoscopic pyelolithotomy in a pelvic kidney. *J Urol.* 1996;155:2019.
6. Chang TD, Dretler SP. Laparoscopic pyelolithotomy in an ectopic kidney. *J Urol.* 1996;156:1753.
7. Hoenig DM, Shalhav AL, Elbahnasy AM, McDougall EM, Clayman RV. Laparoscopic pyelolithotomy in a pelvic kidney: a case report and review of the literature. *JSLS.* 1997;1(2):163–165, Review.
8. Kamat N, Khandelwal P. Laparoscopic pyelolithotomy—a technique for the management of stones in the ectopic pelvic kidney. *Int J Urol.* 2004;11(7):581–584.
9. Gupta NP, Yadav R, Singh A. Laparoscopic transmesocolic pyelolithotomy in an ectopic pelvic kidney. *JSLS.* 2007;11(2):258–260.
10. Nayyar R, Singh P, Gupta NP. Robot-assisted laparoscopic pyeloplasty with stone removal in an ectopic pelvic kidney. *JSLS.* 2010;14(1):130–132.