

# New technique "Right Anterior Small Thoracotomy (RAST operation)" for beating heart grafting of the right internal thoracic artery to the posterior descending artery to the posterior descending artery in a third redo CABG patient. A novel coronary technique.

*Nova técnica "Pequena toracotomia anterior direita (operação RAST)" para enxerto da artéria torácica interna direita para a artéria descendente posterior com o coração batendo em paciente de terceira RM. Uma técnica coronária nova.*

Maximo Guida<sup>1</sup>, MD, PhD; Gustavo Guida<sup>1</sup>, MD; Giuseppina Pecora<sup>1</sup>, MD; Estefania De Garate<sup>1</sup>, MD

DOI 10.5935/1678-9741.20140080

RBCCV 44205-1576

## Abstract

Third REDO-CABG is a challenge for the surgical team. Usually a patent mammary is the only graft working and the sternotomy becomes a risky procedure. Injury to a patent graft has been associated to a high mortality rate. Many different approaches have been proposed. We describe a novel technique to approach the right coronary artery through a right anterior small thoracotomy using the right mammary prolonged with saphenous vein for grafting the posterior descending artery on the beating heart. The technique is very simple and feasible because anatomically the right coronary artery and the right mammary are very close and the mobilization of the heart is minimal.

**Descriptors:** Coronary Artery Bypass. Thoracotomy. Myocardial Revascularization.

## Resumo

A terceira reoperação de revascularização miocárdica é um desafio para a equipe cirúrgica. Normalmente, uma mamária patente é a única possibilidade de enxerto e a esternotomia torna-se um procedimento arriscado. A lesão de enxerto patente tem sido associada a uma alta taxa de mortalidade. Muitas abordagens diferentes têm sido propostas. Descrevemos uma nova técnica de abordagem da artéria coronária direita através de uma pequena toracotomia anterior direita usando a mamária direita prolongada com enxerto de veia safena para a artéria descendente posterior com o coração batendo. A técnica é muito simples e viável, pois anatomicamente a artéria coronária direita e a mamária direita estão muito próximas e a mobilização do coração é mínima.

**Descritores:** Ponte de Artéria Coronária. Toracotomia. Revascularização Miocárdica.

<sup>1</sup>Fundacardio Foundation, Valencia, Venezuela.

This study was carried out at Fundacardio Foundation, Valencia, Venezuela.

No financial support.

Correspondence address:

Maximo Guida

Fundacardio Foundation - Valencia – Venezuela

Av. Bolivar Norte 137-A Street, Sector Camoruco, Res. Pecchinenda D

Planta Baja- Valencia, Venezuela

E-mail: maximo\_guida@hotmail.com

Article received on March 5<sup>th</sup>, 2014

Article accepted on June 8<sup>th</sup>, 2014

#### Abbreviations, acronyms & symbols

CABG	Coronary artery bypass grafting
PDA	Posterior descending artery
RAST	Right anterior small thoracotomy
RCA	Right coronary artery
RITA	Right mammary thoracic artery
SVG	Saphenous Vein

## INTRODUCTION

The Third Redo-CABG (coronary artery bypass grafting) is always a challenge for the surgical team. Usually, the patient has a patent mammary as the only graft working just in the midline which represents a risky situation for a re-sternotomy<sup>[1-2]</sup>. Most of the time other conditions as renal failure, low ejection fraction, increased age, unstable angina, cardiac failure and pulmonary hypertension are present, representing also an increased risk for prolonged mechanical ventilation<sup>[3]</sup>. Worsening this situation is the absence of available conduit for the grafting because most of them have been already used for the previous surgeries.

We are proposing a technique to reduce the risk in this special group of patients, avoiding the re-sternotomy, thus avoiding the cardiopulmonary bypass, and using the skeletonized right internal thoracic artery for grafting the right coronary or the posterior descending artery (PDA) with minimal manipulation of the heart.

## TECHNIQUE

A 78 year-old diabetic patient was admitted in our service with recurrent angina for a REDO third coronary surgery. He had had triple bypass in 1994 via median sternotomy. After that, he had PTCA stents two times in 1996 and 1998. In 2004, our team performed a double bypass from a left thoracotomy using a saphenous vein graft from the descending thoracic aorta to the diagonal and the marginal branch.

The angiogram showed: RCA 100% occluded on the distal third. LAD 100% occluded proximally. Left main with patent stent. CX 80% on the medium third. Collateral circulation from the left to the right coronary artery, the ascending, arch and descending aorta were severely calcified, a patent LITA to LAD was keeping the patient alive. The ejection fraction was of 30% assessed by transesophageal echo. Because of the patient was not suitable for PTCA, and there were no conduits available for grafting, we decided the use of the right internal thoracic artery (RITA), prolonged with a small segment of saphenous vein available on the left groin for grafting the Posterior Descending Artery (PDA). The patient approach was very risky from median Sternotomy because there was a patent LITA to LAD. The left thoracotomy, as we use as a routine, was not possible because there was

no graft of enough length available. The use of the right gastroepiploic artery was also considered, but the patient had previous partial gastrectomy. As we had the experience before operating on a patient with dextrocardia through a right thoracotomy<sup>[4]</sup>, we decided to perform a right anterior thoracotomy for grafting the RCA to the PDA branch.

A fully written informed consent was obtained and signed from the patient and his wife, as well as their consent for the use of the information and pictures for scientific reason.

Before anesthetic induction, the patient was premedicated with 100 mg of Ketoprofen, 2 grams of Dipirone, 8 mg of Dexametasona, and antibiotic profilaxis as per protocol, an intra-aortic balloon pump was inserted via a right femoral artery to assist the left ventricle and improve the severe patient ischemia.

The patient received a 1.5 mg/kg Propofol, 0.07 mcg/kg/min Remifentanyl over 10 min, and 1 mg/kg Rocuronium. Then a bronchial blocker was inserted after the induction in order to exclude the right lung, but the patient didn't tolerate the exclusion and we had to do a partial exclusion with the use of lap sponges. The position was on a left lateral supine at approximately 30 degrees with the right arm elevated (Figure 1).

A right anterior thoracotomy was performed at the 6<sup>th</sup> intercostal space. Bupivacaine was then injected on the upper and lower side of the incision as a part of our pain control protocol. With the use of Finocchetto retractor in combination with a Rultract retractor, the right pleural space was approached. A lot of pleural adhesions were removed from the right lung to achieve a proper surgical field. The pericardial fat and thymus rest were removed. The right internal thoracic artery was dissected in a skeletonized fashion with the use of ultracision harmonic scalpel and a special forceps. Systemic heparin (2 mgs/kg) was given to maintain an activated clotting time around 350 seconds. The right internal thoracic artery was transected distally and a terminal-terminal anastomosis was performed with a small piece of

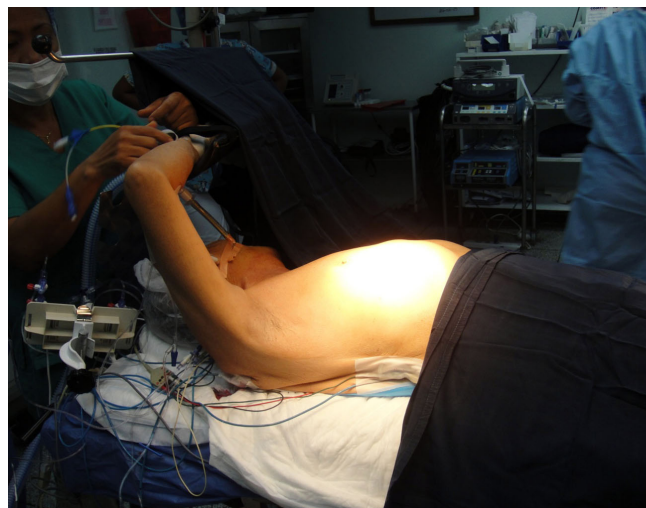

Fig. 1 - Patient position - the patient is positioned with the right arm elevated at approximately 30° toward left side.

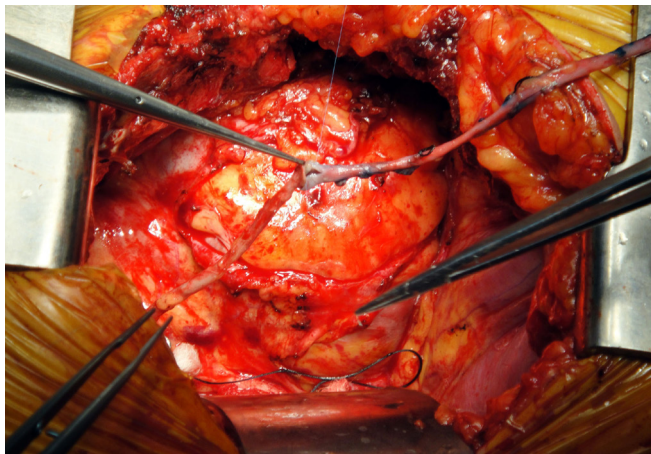


Fig. 2 - Anastomosis RITA-SVG - A small piece of SVG is anastomosed to the RITA with running suture of 8/0 prolene.

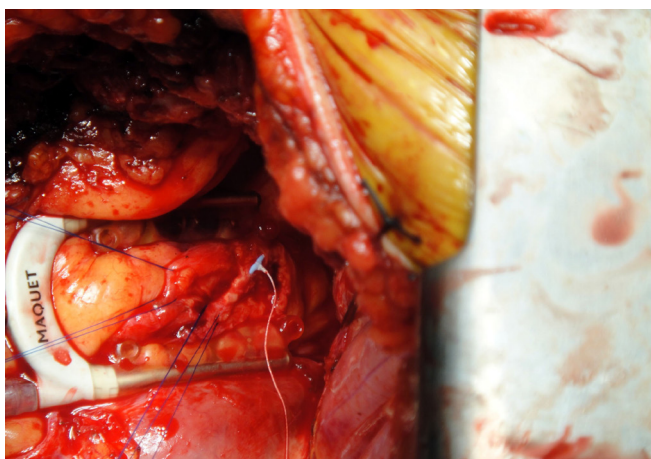


Fig. 3 - PDA stabilization and shunt in - The PDA is stabilized with the use of the Maquet-Acrobat and a 1,5 flow-thru shunt is placed.

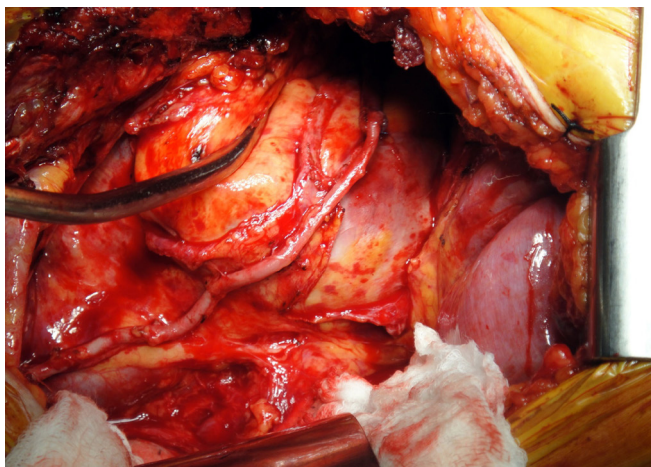


Fig. 4 - Anastomosis performed - The anastomosis RITA-SVG-PDA is performed with an excellent result.

saphenous vein previously removed from the left groin, using an 8/0 Prolene running suture (Figure 2).

Papaverine solution was spread around the RITA to improve its diameter and relieve from a possible spasm. The right side of the heart was dissected from the adhesions of the previous surgeries very carefully avoiding lesion of the right atrium and the right ventricle. The target vessel was founded following the previous occluded saphenous vein graft to the PDA performed in 1994. Using a Maquet Acrobat-i stabilizer®, the artery was dissected, inspected to ensure the feasibility of the anastomosis and opened very carefully. A 1.5 mm flow-through intracoronary shunt was inserted as a part of our routine (Figure 3). The distal anastomosis was then performed in the usual fashion on the beating heart with the continuous running polypropylene 7/0 suture (Figure 4). The Butterfly Medistim Flowmeter was used to check the graft flow, the PI (pulsatility index) was 2,9, the mean flow was 28 ml/min and DF (diastolic filling) was 62% which was considered satisfactory. Protamine was administered to achieve full heparin reversal and a further dose of Bupivacaine was injected on the upper and lower side of the incision as usual.

Transesophageal echo was performed before and after the anastomosis in the same patient conditions: anesthetic drugs, use of inotropics and balloon assistance and an impressive improvement of the postero-lateral wall contraction was showed, increasing the left ventricular ejection fraction from 30 to 45% (Figure 5).

A multi-orifice catheter was placed inside the incision for a postoperative pain control and the incision closed conventionally.

The patient was awakened at the end of the procedure and extubated on the table. The postoperative course was really uneventful. The intraortic balloon pump removed in the ICU 1 hour after and the patient discharged at home on the third postoperative day.

#### COMMENT

The coronary surgery has changed a lot in the last two decades. Now the surgeon has the obligation to know how to perform many different procedures for the same purpose, thus resolving the patient ischemia. From the standard on pump, median sternotomy coronary artery bypass grafting, which was the only technique used before, actually, we have the off pump-median sternotomy, lateral thoracotomy, minimally invasive coronary surgery, video-assisted, robotic and hybrid procedures. And for the REDO-CABG we have also the axillo-coronary via left thoracotomy, postero-lateral approach using the descending aorta and the xiphoidal approach using the right gastroepiploic artery<sup>[5-9]</sup>.

This novel technique that we describe may help to resolve many difficult situations like the above patient, who was no candidate for any of the above mentioned techniques. Moreover, especially in REDO-CABG, would be a good choice

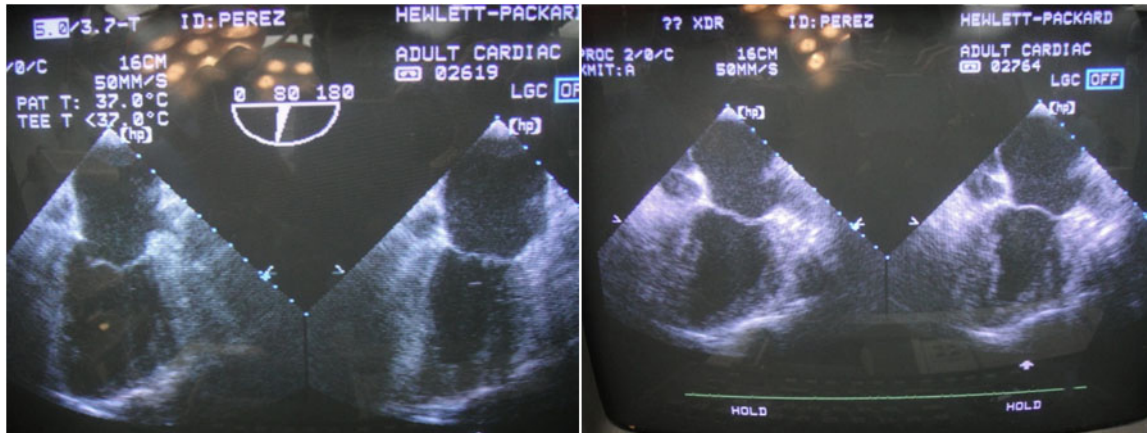


Fig. 5 - Transesophageal echo performed before (left) and after (right) the anastomosis in the same patient conditions: anesthetic drugs, use of inotropics and balloon assistance.

for a hybrid procedure when the LAD or the circumflex could be stented and the RCA or PDA resolved by this RAST operation. Our only concern about this case is the long term patency of the saphenous vein anastomosed to the RITA, of which good short term results are reported<sup>[10]</sup>, but could be a choice when there is a lack of conduit, like in our case. It's very important for the cardiac surgeon in the current era to keep open eyes at any new procedure, because the coronary Surgery is becoming more and more complex every day.

Authors' roles & responsibilities	
MG	Main author
GG	Conception and design of the study
GP	Final approval of manuscript
EG	Drafting of the manuscript and critically review

#### REFERENCES

1. Loop FD. Catastrophic hemorrhage during sternal reentry. *Ann Thorac Surg.* 1984;37(4):271-3.
2. Dobell AR, Jain AK. Catastrophic hemorrhage during redo sternotomy. *Ann Thorac Surg.* 1984;37(4):273-8.
3. Piotto RF, Ferreira FB, Colósimo FC, Da Silva GS, De Souza AC, Braile DM. Independent predictors of prolonged mechanical ventilation after coronary artery bypass surgery. *Rev Bras Cir Cardiovasc.* 2012;27(4):520-8.
4. Romano G, Guida G, De Garate E, Guida MC. Minimally-invasive coronary surgery in dextrocardia and situs inversus totalis. *Interact CardioVasc Thorac Surg.* 2010;11(6):820-1.
5. Ascione R, Narayan P, Rogers CA, Lim KH, Capoun R, Angelini GD. Early and midterm clinical outcome in patients with severe left ventricular dysfunction undergoing coronary artery surgery. *Ann Thorac Surg.* 2003;76(3):793-9.
6. Calafiore AM, Gianmarco GD, Teodori G, Bosco G, D'Annunzio E, Barsotti A, et al. Left anterior descending coronary artery grafting via left anterior small thoracotomy without cardiopulmonary bypass. *Ann Thorac Surg.* 1996;61(6):1658-63.
7. Borst HG. Leftsided thoracotomy for coronary artery reoperation. *Thoraxchir Vasc Chir.* 1978;26(2):95-7.
8. Guida MC, Pecora G, Bacalao A, Muñoz G, Mendoza P, Rodríguez L. Multivessel revascularization on the beating heart by anterolateral left thoracotomy. *Ann Thorac Surg.* 2006;81(6):2142-6.
9. Burlingame MW, Bonchek LI, Vazales BE. Left thoracotomy for reoperative coronary bypass. *J Thorac Cardiovasc Surg.* 1988;95(3):508-10.
10. Cirillo M, Messina A, Dalla Tomba M, Brunelli F, Mhagna Z, Villa E, et al. A new no-touch aorta technique for arterial-source, off-pump coronary surgery. *Ann Thorac Surg.* 2009;88(4):e46-7.