

## SETTING THE SCENE

### REVIEW

# Expanding the indications of robotic surgery in urology: A systematic review of the literature

Raj P. Pal\*, Anthony J. Koupparis

Bristol Urological Institute, Southmead Hospital, Bristol, UK

Received 3 January 2018, Received in revised form 7 May 2018, Accepted 8 May 2018

Available online 7 August 2018

#### KEYWORDS

Robot-assisted surgery;  
Robotic surgery;  
Urology

#### ABBREVIATIONS

AUS, artificial urinary sphincter;  
ICUD, intracorporeal urinary diversion;  
HoLEP, holmium laser enucleation of the prostate;  
LOS, length of hospital stay;  
MIS, minimally invasive surgery;

**Abstract Objectives:** To evaluate the recent developments in robotic urological surgery, as the introduction of robotic technology has overcome many of the difficulties of pure laparoscopic surgery enabling surgeons to perform complex minimally invasive procedures with a shorter learning curve. Robot-assisted surgery (RAS) is now offered as the standard for various surgical procedures across multiple specialities.

**Methods:** A systematic search of MEDLINE, PubMed and EMBASE databases was performed to identify studies evaluating robot-assisted simple prostatectomy, salvage radical prostatectomy, surgery for urolithiasis, distal ureteric reconstruction, retroperitoneal lymph node dissection, augmentation ileocystoplasty, and artificial urinary sphincter insertion. Article titles, abstracts, and full text manuscripts were screened to identify relevant studies, which then underwent data extraction and analysis.

**Results:** In all, 72 studies evaluating the above techniques were identified. Almost all studies were retrospective single-arm case series. RAS appears to be associated with reduced morbidity, less blood loss, reduced length of stay, and comparable clinical outcomes in comparison to the corresponding open procedures, whilst having a shorter operative duration and learning curve compared to the equivalent laparoscopic techniques.

\* Corresponding author at: Bristol Urological Institute, North Bristol NHS Trust, Southmead Hospital, Southmead Rd, Westbury-on-Trym, Bristol BS10 5NB, UK.

E-mail address: [raj.pal@nhs.net](mailto:raj.pal@nhs.net) (R.P. Pal).

Peer review under responsibility of Arab Association of Urology.



Production and hosting by Elsevier

PCNL, percutaneous nephrolithotomy; (L-)(O-)(R-) RPLND, (laparoscopic)(open)(robot-assisted) retroperitoneal lymph node dissection; (L)(RA) PN, (laparoscopic)(robot-assisted) partial nephrectomy; PRISMA, Preferred Reporting Items for Systematic Reviews and Meta-Analyses; RAI, robot-assisted augmentation ileocystoplasty; (s)RALP, (salvage) robot-assisted laparoscopic prostatectomy; RAS, robot-assisted surgery; (RA)RC, (robot-assisted) radical cystectomy; RCT, randomised controlled trial; (L)(R)RP, (laparoscopic)(retropubic)radical prostatectomy; sRRP, salvage RRP; RNL, robot-assisted nephrolithotomy; RPL, robot-assisted pyelolithotomy; (O)(L)(RA)SP, (open)(laparoscopic)(robot-assisted)simple prostatectomy; (S)UI, (stress) urinary incontinence

**Conclusion:** Emerging data demonstrate that the breadth and complexity of urological procedures performed using the da Vinci® platform (Intuitive Surgical Inc., Sunnyvale, CA, USA) is continually expanding. There is a gaining consensus that RAS is producing promising surgical results in a wide range of procedures. A major limitation of the current literature is the sparsity of comparative trials evaluating these procedures.

© 2018 Production and hosting by Elsevier B.V. on behalf of Arab Association of Urology. This is an open access article under the CC BY-NC-ND license (<http://creativecommons.org/licenses/by-nc-nd/4.0/>).

## Introduction

The introduction of the da Vinci® Surgical System (Intuitive Surgical Inc., Sunnyvale, CA, USA) has dramatically transformed the landscape of minimally invasive surgery (MIS). This surgical platform, whilst maintaining the benefits of standard laparoscopy, provides the surgeon with additional advantages of greater dexterity, a wider range of movement, tremor filtration, three-dimensional vision, and primary surgeon camera control. These benefits are useful, especially when there is a deep and narrow field and when intracorporeal suturing and fine tissue dissection are required, as is

the case for pelvic and retroperitoneal surgery [1,2]. This technology has therefore enabled surgeons to replicate complex open procedures using MIS with a much faster learning curve than standard laparoscopy and the potential to supersede the results of open surgery.

Robot-assisted surgery (RAS) has now become the contemporary ‘gold standard’ treatment modality for many urological conditions. Perhaps the most established procedure being robot-assisted laparoscopic prostatectomy (RALP) [3]. After first being described by Menon et al. [4], RALP has now replaced open retropubic radical prostatectomy (RRP) and laparoscopic RP (LRP) in most modern healthcare systems

[3]. Despite the lack of high-quality randomised controlled trials (RCTs) showing a benefit over open RRP [5], there is an abundance of non-randomised data that have shown clear advantages for intraoperative blood loss, transfusion rates, duration of catheterisation, length of hospital stay (LOS), positive margins, potency, continence, and readmission rates [6,7].

Since its first report, again by Menon et al. [8] in 2003, robot-assisted radical cystectomy (RARC) has likewise been adopted by several large institutions. A recent systematic review comparing RARC (with mainly extracorporeal urinary diversion) with open RC showed that RARC benefited from fewer perioperative complications, greater lymph node yield, lower blood loss, and a shorter LOS [9]. With many units now routinely performing intracorporeal urinary diversion (ICUD), further benefits can be derived by a reduction in incision size, postoperative pain, and bowel-related complications [10]. A recent study demonstrated that introduction of RARC and ICUD represented the principal factor leading to the benefits of a RC enhanced-recovery programme [11], and furthermore cost-efficiency analyses have shown promising results even when factoring in purchase, consumable and maintenance expenses [12,13].

A robot-assisted approach for partial nephrectomy (RAPN) has also yielded benefits including reduced blood loss, postoperative pain and LOS [14]. A systematic review comparing RAPN and laparoscopic PN (LPN) showed RAPN to have shorter ischaemia times and a lower overall complication rate than the LPN [15]. RAPN also has a shorter learning curve than LPN and enables more complex cases (> 4 cm, multifocal, central location, solitary kidney) to be carried out [16,17]. These benefits are mirrored in other upper tract procedures including robot-assisted pyeloplasty, where authors present the case for RAS becoming the standard of care [18,19].

With the widespread uptake of RAS in urology, the aim of the present review was to evaluate its expanding role within the speciality.

## Methods

We identified several RAS procedures, which have recently gained attention in the contemporary literature. A systematic review was performed for several urological procedures, with an endeavour to adhere to Preferred Reporting Items for Systematic Reviews and Meta-Analyses (PRISMA) guidelines [19]. For each procedure, we performed a structured, comprehensive literature review searching MEDLINE, PubMed and EMBASE databases. We retrieved citations using the described search combinations (Table 1) for the relevant procedure. Article titles, abstracts and full text manuscripts were then screened to identify relevant studies

**Table 1** List of terms used for relevant database searches.

Procedure	Search terms
Robot-assisted simple prostatectomy (RASP)	'robotic' or 'robot' or 'robot-assisted' AND 'prostatectomy' AND 'benign' or 'simple'
Salvage robot-assisted radical prostatectomy (sRALP)	'salvage' or 'salvage therapy' AND 'prostatectomy' or 'surgery' AND 'robotic' or 'robot' or 'robot-assisted'
Robot-assisted surgery (RAS) for urolithiasis	'robotic' or 'robot' or 'robot-assisted' AND 'urolithiasis' or 'pyelolithotomy' or 'nephrolithotomy' or 'stones' or 'ureterolithotomy'
Robot-assisted distal ureteric reconstruction	'robotic' or 'robot' or 'robot-assisted' AND 'Boari' or 'Psoas' or 'reimplant' or 'uretero-ureterostomy' or 'ureteroureterostomy' or 'ureteroneocystostomy' or 'ureteroneocystostomy'
Robot-assisted retroperitoneal lymph node dissection (R-RPLND)	'robotic' or 'robot' or 'robot-assisted' AND 'testicular' or 'retroperitoneal' or 'RPLND'
Robot-assisted augmentation ileocystoplasty (RAI)	'robotic' or 'robot' or 'robot-assisted' AND 'ileocystoplasty' or 'entrocystoplasty' or 'augmentation'
Robot-assisted artificial urinary sphincter (AUS) insertion	'robotic' or 'robot' or 'robot-assisted' AND 'sphincter' or 'AUS' or 'artificial urinary'

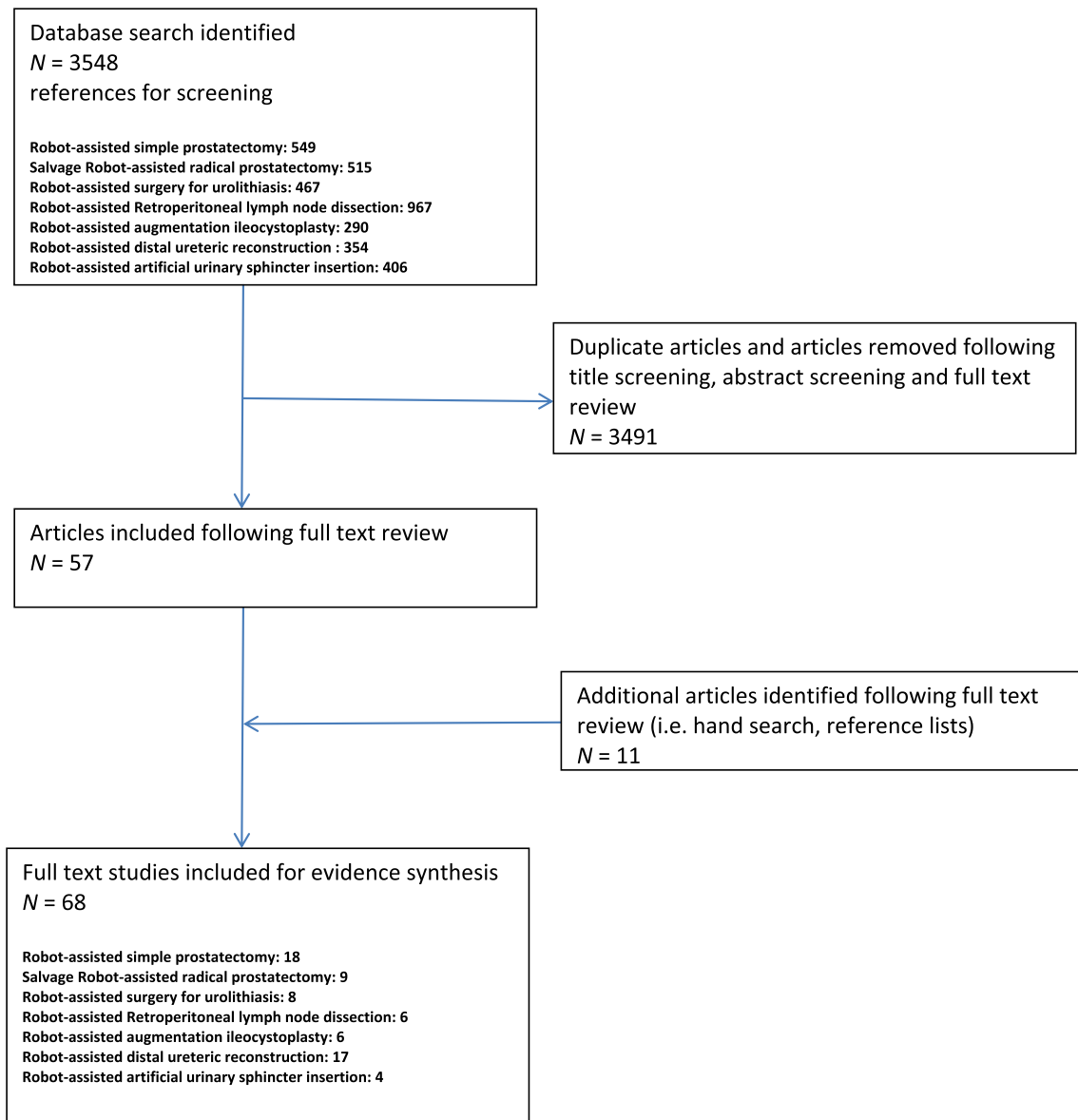
(Fig. 1). We excluded single case reports and case series with less than three patients. As the majority of relevant articles were case series, risk-of-bias assessment was not performed.

## Robot-assisted simple prostatectomy (RASP)

Surgical treatment options for benign prostatic obstruction have expanded considerably over the last 20 years. Whereas TURP for <80 mL glands, and open SP (OSP) for larger prostates was considered the 'gold standard' [20], the development of laser technologies and MIS has provided treatment alternatives with many potential benefits over traditional modalities [21,22].

With the intent of replicating the equivalent open procedure, whilst negating the technical challenges of laparoscopic surgery, RASP was first described in 2008 [23]. Subsequently, 18 case series have been reported, of which, there are three non-randomised comparative studies [24–41]. Table 2 summarises data from studies evaluating RASP [24–41].

Several surgical techniques for RASP are described. Patients are initially positioned as for RALP and in all but two studies a transperitoneal approach is described. Authors perform adenoma excision either through an anterior transcapsular incision (as for a Millen's OSP),



**Fig. 1** PRISMA diagram showing study acquisition.

an anterior horizontal cystotomy in proximity to the prostate-vesical junction (as for a Freyer's OSP), or through a vertical incision at the dome of the bladder. For the two former approaches the space of Retzius is initially developed, whereas for the latter the bladder remains attached to the abdominal wall. For both transvesical approaches, once the bladder neck is exposed, an incision over the mucosa overlying the adenoma is made, and the circumferential plane between the adenoma and the capsule is developed towards the apex, at which point the adenoma is divided from the urethra.

Despite an abundance of RASP cases being described, the literature is limited by the lack of any randomised trial evaluating RASP. In comparison to the contemporary literature on OSP [42], a systematic

review of case series evaluating RASP tend to report a longer operative time but benefits include reduced blood loss, rate of transfusion, LOS, need for irrigation, catheterisation time, and incision size (Table 2) [20,23–41]. Overall complication rates (Clavien–Dindo Grade > II) appear to be similar for both OSP and RASP, as are functional outcomes [20,23–42]. All studies report on significant improvement in IPSS and uroflowmetry parameters after RASP, similar to that obtained for OSP. These findings were also confirmed by the one non-randomised comparative study of RASP vs OSP [41].

Further non-randomised comparative studies between laparoscopic SP (LSP) and holmium laser enucleation of the prostate (HoLEP) have been performed. In a single comparative study, outcomes following

**Table 2** Clinico-demographic data and surgical outcomes from case series/studies evaluating RASP.

Reference	Number of patients	Mean/median:							Surgical technique	Transfusion, <i>n</i>
		Age, years	Preoperative TRUS volume, mL	Operative time, min	Blood loss, mL	Resection weight, g	LOS, days	Duration of catheterisation, days		
Sotelo et al. [23]	7	65	77	195	382	52	1.3	7.5	TP TV	1
Yuh et al. [24]	3	77	323	211	558	301	1.3	NR	TP	1
John et al. [25]	13	70	NR	210	500	82	6	6	EP	0
Uffort et al. [26]	15	66	71	128	140	46	2.5	4.6	TP TV	0
Matei et al. [27]	15	66	98	180	50	103	2.7	7	TP TV	0
Sutherland et al. [28]	9	68	166	183	206	112	1.3	13	TP TC	0
Vora et al. [29]	13	67	NR	179	219	163	2.7	8.8	TP TV	0
Matei et al. [30]	35	65	107	186	121	87	3.2	7.4	TP TV	0
Coelho et al. [31]	6	69	157	90	208	145	1	4.8	TP TV	0
Clavijo et al. [32]	10	71	81	106	375	81	1	9	TP TV	1
Banapour et al. [33]	16	68	142	228	197	94	1.3	8	TP TC or TV	0
Leslie et al. [34]	25	73	149	214	143	NR	4	9	TP TV	1
Pokorny et al. [35]	67	69	129	97	200	84	4	3	TP TV	1
Autorino et al. [36]	487	67	110	145	200	75	2	7	TP TC or TV	5
Patel et al. [37]	20	70.8	NR	NR	NR	134	NR	3–5	TP TV	0
Garzon et al. [38]	79	69	80	152	390	68	NR	9	TP TC	5
Umari et al. [39]	81	69	130	105	NR	89	2	2	TP TV	1
Stolzenburg et al. [40]	10	63	143	122	228	102	8	7	EP TV	0
Sorokin et al. [41]	63	69	136	160	327	81	1.5	5.7	TP TV	2

TP, transperitoneal; EP, extraperitoneal; TV, transvesical; TC, transcapsular; NR, not reported.

RASP and LSP were similar but one could conclude that the qualities and widespread availability of robotic surgical systems are likely to favour RASP if minimally-invasive SP is to become widely adopted [36,38]. A recent retrospective non-randomised study evaluated RASP vs HoLEP and reported that operative times, blood loss, functional outcomes, and complications rates were similar in both groups, despite patients undergoing RASP having greater co-morbidity and a higher IPSS [39]. However, the LOS and catheterisation time were less in HoLEP, due to the avoidance of a cystotomy incision.

Cost-effective analyses of RASP have shown a favourable economic profile against OSP due to reduced LOS, irrigation, and transfusion requirements [30]. Additionally, the cost of RASP has been shown to be equivalent to bipolar-TURP, but this was based on

bipolar-TURP having a longer hospitalisation period than RASP [30].

Further limitations of the existing literature are present. Feasibility of RASP on very large prostate glands has only been truly demonstrated in select studies, as only three (18 patients) have evaluated mean preoperative prostate volumes of >150 mL [24,28,31]. The majority of studies had mean prostate volumes of <150 mL and five studies were in glands of <100 mL [24,26,27,32,38]. Studies evaluating RASP in smaller prostate glands are of questionable value given the minimal morbidity and good functional outcomes of transurethral surgery in this cohort.

RASP may achieve better adenoma clearance than standard endoscopic procedures potentially having superior durable effects. Furthermore, in established robotic surgical units were laser technology for benign

prostatic obstruction are not available, RASP may provide an excellent treatment alternative for larger glands. However, further randomised studies with long-term follow-up and cost-efficiency assessment are required to determine if RASP has a role in routine clinical practice.

### Salvage RALP (sRALP)

Although many consider radiotherapy after surgery for prostate cancer to be a routinely offered second-line treatment modality in appropriate patients, the converse cannot be said. Salvage RRP (sRRP) for radio-recurrent prostate cancer, in addition to having high biochemical relapse rates, has traditionally been associated with significant morbidity. In a systematic review by Chade et al. [43], rectal injury was reported in up to 19% of patients, urinary incontinence (UI) in up to 80%, and stricture disease in as many as 40%. Therefore, the view that open surgery carried a low chance of cure with significant associated morbidity has deterred many clinicians from offering sRRP routinely.

The first report of a sRALP was published in 2008 [44], and subsequently nine further case series have followed reporting on a total of 197 patients (Table 3) [44–53]. As for sRRP, oncological outcomes after sRALP are worse than in men undergoing primary RALP, this being indicative of the increased risk of micrometastatic disease in the men with radio-recurrent prostate cancer [54]. In stage-matched cohorts, although positive surgical margin rates are equivalent between primary and sRALP, relapse rates are higher

after sRALP despite shorter reported follow-up periods [54]. A recent systematic review showed that with a mean of 18 months follow-up, 56/193 of the reported cases of sRALP had biochemical recurrence [54].

Additionally, functional outcomes after sRALP remain worse than for primary RALP [52]. However, the morbidity after sRALP seems less and functional outcomes better than sRRP [43,54]. Almost 40% of patients undergoing sRALP will experience significant stress UI (SUI), up to 15% will require surgery for this [54,50]. Comparing continence rates between studies is difficult due to differing definitions used, but at first glance, these rates of UI appear to be better following sRALP in comparison to data on sRRP, where the majority of series report UI rates of >40% [43,54]. Furthermore, the reported stricture rate of 8% after sRALP appears far less than that reported for open surgery (7–41%). Blood loss is less in sRALP than in sRRP, as is the incidence of rectal injury (0.5% sRALP vs 2–19% for sRRP) [43,54]. Additionally, the incidence of Clavien–Dindo Grade >II complications appears to be lower for sRALP [43,54].

Whether the seemingly reduced morbidity and complication rate after sRALP in comparison to sRRP is due to advantages of robotic surgery or technical innovations in contemporary radiation delivery, is not clear. Although UI rates remain high after sRALP, and longer term outcome data are required to establish its oncological value, the technical feasibility and safety of sRALP shown in these studies renders this treatment a viable oncological option for well-selected patients.

**Table 3** Clinico-demographic data and surgical outcomes from case series/studies evaluating sRALP.

Variable	Reference									
	Jamal et al. [44]	Kaouk et al. [45]	Boris et al. [46]	Strope et al. [47]	Eandi et al. [48]	Zugor et al. [49]	Yuh et al. [50]	Kaffenberger et al. [51]	Bates et al. [52]	Vora et al. [53]
Number of patients	1	4	11	6	18	13	51	34	53	6
Age, years, mean/median	50	–	65	–	67	63	68	61	65	65
Blood loss, mL, mean/median	100	117	113	280	150	130	175	192	120	–
Operative time, min, mean/median	150	125	183	356	156	154	179	176	130	–
Duration of catheterisation, days, mean/median	14	15	10	–	14	6	–	–	11	–
LOS, days, mean/median	1	3	1	2	2	6	2	1	2	–
Clavien–Dindo Grade > II complications, <i>n</i>	0	0	1	1	3	0	8	3	0	0
Rectal injury, <i>n</i>	0	0	0	0	0	0	1	1	0	0
Follow-up, months, mean/median	3	5	21	12	18	23	36	16	27	7
Time to salvage treatment, months, mean/median	NR	NR	NR	NR	NR	48	68	48	NR	NR
PSM, <i>n</i>	0	2	3	1	5	0	16	9	10	NR
Incontinent, <i>n</i>	0	1	3	6	12	3	28	21	12	1
BCR, <i>n</i>	0	NR	3	2	6	8	22	6	8	1
Stricture, <i>n</i>	NR	0	1	1	3	0	8	3	0	NR

BCR, biochemical recurrence; NR not reported.

## RAS for urolithiasis

Although endoscopic surgery has largely displaced open surgery in the management of urolithiasis, MIS has the potential to be a useful modality for treatment in selected cases. Whilst avoiding the morbidity of open surgery, MIS could be used in the management of complex stone disease not amenable to endoscopic or standard minimally-invasive management strategies. In a *meta*-analysis comparing laparoscopic pyelolithotomy with percutaneous nephrolithotomy (PCNL), laparoscopy had significantly lower rates of bleeding and sepsis, whilst displaying a trend towards higher stone-free rates [55]. More recently, robot-assisted pyelolithotomy (RPL) and robot-assisted nephrolithotomy (RNL) have been reported as possible management options in the treatment of renal stones.

To date seven case series have reported on 78 patients undergoing either RNL or RPL (Table 4) [56–62]. Although anatomical and stone characteristics play a crucial role in case selection, RPL appears to be the technique most widely used, conceivably as parenchymal bleeding and potential nephron loss are avoided. Therefore, renal pelvic rather than calyceal stones may be more amenable to RAS.

RPL and RNL are performed using either transperitoneal or retroperitoneal approaches. Surgical positioning and initial renal mobilisation are similar to RAPN. For RPL, once the stone within the collecting system has been identified, a vertical pyelotomy is made in the pelvis, exposing the stone, which is removed with Pro-Grasp forceps. The pyelotomy is closed using a continuous absorbable suture. The technique described for RNL replicates that for open surgery. After identification of the stone with intraoperative ultrasonography, the renal parenchyma is cleared from renal fat. A nephrotomy is made, if possible, where the parenchyma is thinnest, often without the need for renal ischaemia. *En bloc* stone removal is performed, and the incised par-

enchyma is closed using sliding clip renorrhaphy technique as for RAPN.

Characteristics of these case series evaluating RPL and RNL are shown in Table 4. The mean stone size treated varies significantly between studies, from 2.7 to 10.8 cm [56–62]. All studies report low blood loss, a short LOS (usually  $\leq 3$  days), and only three Clavien–Dindo Grade  $\geq$  III complications have been reported in 78 patients. The majority of studies report high stone-free rates, largely with the avoidance of stone fragmentation. However, no comparative studies evaluating robot-assisted stone surgery to standard contemporary treatments exist [56–62]. A key advantage of RPL or RNL over PCNL is complete stone removal avoiding longer-term morbidity and the need for further surgical treatment.

Interestingly, the perception that RPL/RNL is more expensive than standard stone treatments may be erroneous. Studies in the USA have reported that a PCNL costs \$19 845. Data on the expense of neither RPL nor RNL have been presented, but if using RAPN (\$11 962 per case) as a surrogate for the cost of RPL/RNL, the anticipated cost of robotic-assisted stone surgery may justify its future routine use [63,64].

The feasibility and outcomes of robot-assisted laparoscopic ureterolithotomy for large, impacted, lower ureteric stones have also been explored. Dogra et al. [65] presented data from a series of 16 cases undergoing robot-assisted laparoscopic ureterolithotomy for stones not amenable to endoscopic management. The mean console time was only 20 min and stone clearance rates were 100%, due to *en bloc* removal. LOS, interval to drain removal, and complication rates, were significantly shorter than for comparative laparoscopic series. At 20 months follow-up no ureteric strictures were evident [65].

Although many authors acknowledge that endourology remains the standard of care, with falling

**Table 4** Clinico-demographic data and surgical outcomes from case series/studies evaluating RAS for urolithiasis.

Variable	Reference						
	Atug et al. [56]	Badani et al. [57]	Lee et al. [58]	Mufarrji et al. [59]	Ghani et al. [60]	King et al. [61]	Swaringen et al. [62]
Number of patients	8	13	5	13	4	7	28
Technique	RPL	RPL	RPL	RPL	RPL/RNL	RNL	RPL/RNL
Stone size, cm, mean/median	10.8	4.2	3.8	NR	NR	NR	2.74
Operative time, min, mean/median	275	158	315	235	216	222	182
Blood loss, mL, mean/median	48	100	19	60	37	121	38
LOS, days, mean/median	1	NR	3.8	2	2	3	1.7
Clavien–Dindo Grade $\geq$ III complications, <i>n</i>	0	0	NR	0	0	0	2
Stone-free after surgery, <i>n/N</i> (%)	8/8	12/13	3/5	13/13	4/4	2/7	27/28 (96)
Follow-up, months, mean/median	13	1	18	28	NR	5	9

NR, not reported.

anticipated costs and rising experience, RAS has the potential to displace procedures such as PCNL in selected cases. However, prospective RCTs evaluating its short- and long-term safety and efficacy against standard treatment modalities are required prior to implementation.

### Robot-assisted distal ureteric reconstruction

The surgical management of both benign and malignant ureteric pathology often requires simultaneous reconstruction to restore normal renal drainage. Increasingly, authors are demonstrating that this is becoming technically feasible with RAS.

On review of the literature we identified 17 studies (Table 5 [66–82]) evaluating distal ureteric reconstructive surgery, with institutions presenting their experience using a number of differing techniques including uretero-ureterostomy and uretero-neocystostomy (often with adjunct procedures such as Boari flap formation or Psoas hitch).

Standardising data from these studies is challenging due to the heterogeneity of the type of pathology, location and length of the diseased ureteric segment, patient comorbidity, preoperative evaluation, and surgical procedure described.

Most authors describe use of a dorsal lithotomy position (particularly for distal lesions). Adhesiolysis and colonic mobilisation are performed to allow longitudinal mobilisation of the ureter. RAS techniques follow the same principles of ureteric reconstruction as for open surgery; mobilisation of the ureter to healthy tissue avoiding direct ureteric handling and devascularisation, spatulation of the ureter, a water-tight tension-free anastomosis with absorbable sutures over a ureteric stent, placement of a bladder catheter and tube drain overlying the anastomosis, and if feasible an omental wrap is performed.

Comparisons with laparoscopic and open ureteric reconstruction have been made. Baldie et al. [73] and Schiavina et al. [82], both performed non-randomised comparisons of pure laparoscopic against robot-assisted ureteric reconstruction. Using similar reconstructive techniques, short- and long-term complications were similar between both groups, although RAS was associated with a lower operative time, blood loss, and LOS [73,82]. In similar retrospective non-randomised comparisons of RAS vs open surgery, RAS was associated with less blood loss and LOS, whilst operative durations, and short- and long-term complication rates were similar in both groups [72,74]. Additionally stricture rates after robot-assisted ureteric re-implantation appear low. Therefore, the current evidence shows that robot-assisted ureteric excision and reconstruction can be safely performed.

### Robot-assisted retroperitoneal lymph node dissection (R-RPLND)

Laparoscopic RPLND (L-RPLND) is associated with improved cosmesis, reduced complication rate, lower morbidity, and shorter LOS compared to open RPLND (O-RPLND) [83]. However, L-RPLND has a steep learning curve and may have inferior oncological outcomes to O-RPLND due to the associated difficulties of retroaortic and retrocaval dissection, often necessitating patients to have routine adjuvant chemotherapy [84].

R-RPLND was first described in 2006 [85], and subsequent to this there have been a further eight case series of R-RPLND. Two of these case series were in less than three patients. Data summarised from the remaining six larger case series are presented in Table 6 [86–91].

R-RPLND is most commonly performed using a transperitoneal technique, with most patients in a left lateral decubitus position [86–88], although a supine dorsal lithotomy technique with a Trendelenburg tilt is also described [90]. Unilateral templates have been preferred in chemotherapy naïve patients, whereas bilateral templates have been described in surgery for post-chemotherapy residual masses. Boundaries of dissection are analogous with open surgery, with sparing of the hypogastric plexus similarly feasible.

The data show acceptable operative durations and all studies report a mean blood loss of < 500 mL with most studies describing a LOS of  $\leq 3$  days (Table 6). Of the 126 cases described, there were nine open conversions and only five Clavien–Dindo Grade  $\geq$  III complications. The node yield following R-RPLND appears equivalent to open surgery, and oncological outcomes, although limited by the immature follow-up periods, appear acceptable [92]. Morbidity appears to be less in comparison to O-RPLND, with a lower reported incidence of postoperative ileus, respiratory and wound complications, and anejaculation [92]. The one study performing a comparative analysis of R-RPLND vs L-RPLND, showed no clear benefit in favour of R-RPLND [87]. Whereas three-dimensional vision, improved dexterity, reduced hand tremor and surgeon fatigue would potentially favour R-RPLND over L-RPLND, the lack of tactile feedback and the time consuming de-docking process should open conversion be required due to vascular injury make L-RPLND a more attractive option.

One limitation of the existing literature is the bias in studies including mainly chemotherapy naïve Stage I patients. In the largest series of 47 patients (all chemotherapy naïve), Pearce et al. [89] performed R-RPLND in 42 patients with clinical Stage I disease. Although R-RPLND in post-chemotherapy patients has been described, this is only in 37 of the 126 reported cases [86–91]. The preference to perform R-RPLND in chemo-naïve clinical Stage I patients is not consistent with contemporary practice [93]. The majority of Stage



**Table 5** Clinico-demographic data and surgical outcomes from case series/studies evaluating robot-assisted distal ureteric reconstruction.

Reference	Number of patients	Age, years, mean/median	Aetiology, <i>n</i>	Procedure, <i>n</i>	Operative time, min, mean/median	Blood loss, mL, mean/median	LOS, days, mean/median	Follow-up, months, mean/median	Clavian–Dindo Grade $\geq$ III complication, <i>n</i>	Type of study	Stenosis during follow-up, <i>n</i>
Williams et al. [66]	9	44	Benign 9	URI 9	247	110	2	18	1	Case series	1
Schimpf et al. [67]	11	66	Benign 3 Cancer 8	PH 3 BF 2 URI 6	189	82	2.4	12	1	Case series	NR
Glinianski et al. [68]	9	78	Cancer 9	PH 6 URI 1 UU 1	252	44	1.5	23	0	Case series	1
Hemal et al. [69]	30	NR	Benign 24 Cancer 6	UU 12 PH 5 URI 13	137	98	2.4	13.5	1	Case series	0
Patil et al. [70]	12	43	Benign 12	PH 12	208	48	4.3	15.5	0	Case series	2
McClain et al. [71]	6	68	Cancer 6	UU 2 PH 2 URI 2	268	72.5	1.8	33	0	Case series	0
Kozinn et al. [72]	10	53	Benign 10	URI 4 PH 4 BF 2	306	30	2.4	30	NR	Comparative non-RCT vs open surgery	0
Baldie et al. [73]	16	44	Benign 16	PH 8 URI 4 UU 3 BF 1	258	171	2.5	4.4	1	Comparative non-RCT vs laparoscopic surgery	0
Isac et al. [74]	25	49	Benign 25	URI 11 PH 4 BF 10	279	100	7.5	NR	2	Comparative non-RCT vs open surgery	2
Musch et al. [75]	16	63	Benign 12 Cancer 4	URI 7 PH 4 BF 5	260	NR	2.4	10	2	Case series	1
Gellhaus et al. [76]	37	52	Benign 37	UU 15 PH 22	219	89	2.3	14	2	Case series	2
Fifer et al. [77]	55	52	Benign 45 Cancer 10	UU 5 URI/PH 45 BF 9 UL 5 Other 3	233	50	1.6	6	2	Case series	3
Slater et al. [78]	14	39	Benign 9 Congen. 4	UU 1 URI 10 BF 3	286	40	2.3	20.7	0	Case series	0
Wason et al. [79]	13	46	Benign 9	URI 8 PH 6	282	123	2.5	9.8	2	Case series	0

Table 5 (continued)

Reference	Number of patients	Age, years, mean/median <i>n</i>	Aetiology, <i>n</i>	Procedure, <i>n</i>	Operative time, min, mean/median	Blood loss, mL, mean/median	LOS, days, mean/median	Follow-up, months, mean/median	Clavian–Dindo Grade $\geq$ III complication, <i>n</i>	Type of study	Stenosis during follow-up, <i>n</i>
Stolzenberg et al. [80]	11	39	Benign 6 Cancer 5	BF 11	166	155	NR	15.2	0	Case series	0
Franklin et al. [81]	9	44	Benign 9	PH 4 BF 1 URI 4	295	77	2.7	8.3	0	Case series	1
Schiavina et al. [82]	26	44	Benign 26	UU 7 URII2 PH 7	185	47	7	26	1	Comparative non-RCT vs laparoscopic surgery	1

BF, uretero-neocystostomy with Boari flap reconstruction; Congen., congenital; NR, not reported; PH, uretero-neocystostomy with Psoas hitch repair; UL, ureterolysis; URI, direct ureteroneostomy / ureteric re-implantation; UU, ureteroureterostomy.

I patients managed conservatively will not relapse, chemotherapy in this stage of the disease has improved disease-free survival in comparison to surgery, and contemporary practice would suggest that most O-RPLND are performed in post-chemotherapy patients with clinical Stage II disease [93,94]. In those studies that do compare outcomes in pre- and post-chemotherapy, post-chemotherapy surgery appears to be associated with an increased operative duration, higher conversion rates, and increased blood loss [86,90]. Proponents argue that if R-RPLND can establish durable long-term response in Stage I patients, it may offer an equitable compromise between the side-effects of chemotherapy, morbidity of an O-RPLND, and the recurrence rates of observation, but this opinion deviates from recommendations by international authorities [93] and therefore future studies need to focus on selecting post-chemotherapy patients.

### Robot-assisted augmentation ileocystoplasty (RAI)

Augmentation enterocystoplasty is typically reserved for treatment-refractory cases of detrusor overactivity and neuropathic bladder dysfunction. The surgical complexity of the procedure carries significant surgical morbidity, particularly in the neuropathic population in whom it is frequently performed. The increasing use of RARC with ICUD has reinforced the feasibility of performing intracorporeal bowel division and re-anastomosis with associated reduced morbidity and bowel-related complications [10], and has opened the door for other such procedures such as augmentation enterocystoplasty to be performed by RAS.

Following the first case report of RAI by Gundeti et al. [95] in 2008, 64 cases have subsequently been reported in the literature in 13 publications. Seven of these were single case reports and of the remaining six articles, five were published from the same group encompassing similar time periods [96–101].

The solitary adult case series evaluating RAI reported by Madec et al. [96] comprised 19 patients undergoing supra-trigonal RC followed by RAI. In this series, indications for surgery included treatment-refractory detrusor overactivity, low bladder compliance, and painful bladder syndrome. Although robot-assisted intracorporeal supra-trigonal RC was performed in all cases, bowel segment isolation, anastomosis and de-tubularisation were all performed extracorporeally, with a subsequent robot-assisted intracorporeal ileal graft anastomosis performed onto the bladder in the sagittal plane. There were no Clavian–Dindo Grade  $>$  II complications and the authors report on a rapid learning curve, even for surgeons less experienced in robotic surgery, and long-term functional results were quoted as excellent. However, a limitation of this study was the need for extracorporeal bowel division and re-anastomosis.

**Table 6** Clinico-demographic data and surgical outcomes from case series/studies evaluating R-RPLND.

Variable	Reference					
	Cheney et al. [86]	Harris et al. [87]	Kamel et al. [88]	Pearce et al. [89]	Stepanien et al. [90]	Singh et al. [91]
Number of patients	18	16	12	47	20	13
Article type	Case series	Non-randomised comparative study vs L-RPLND	Case series	Case series	Case series	Case series
Age, years, mean/median	32	29.8 (median)	37.8	30	31	26
TNM stage, <i>n</i>						
I	10	14	0	42	11	0
II	8	2	5	5	6	3
III	0	0	6	0	3	10
Prior chemotherapy, <i>n</i>						
Yes	8	0	12	0	4	13
No	10	16	0	47	16	0
Histology, <i>n</i>						
NSGCT	18	16	9	47	20	13
Seminoma	0	0	3	0	0	0
Operative time, min, mean/median	343	271	312	235	293	200
Blood loss, mL, mean/median	172	75	475	50	50	120
Clavien–Dindo Grade ≥ III complications, <i>n</i>	0	1	1	0	1	2
LOS, days, mean/median	2.4	–	3.6	1	1	4
Conversion, <i>n</i>	3	1	2	1	0	0
Node yield, mean/median	20	30	12	26	19.5	20
Follow up, months, mean/median	–	13.5	31	22	49	23
Retroperitoneal recurrence, <i>n</i>	0	0	0	0	0	0

NSGCT, non-seminomatous germ cell tumour.

Murthy et al. [97] reported outcomes from a cohort of 15 paediatric patients undergoing a RAI, performing a non-randomised retrospective comparison against open augmentation enterocystoplasty. Indications for surgery included neuropathic bladder dysfunction (poor compliance, detrusor overactivity refractory to medical treatment, high detrusor leak point pressure) or bladder dysfunction secondary to posterior urethral valves. Most cases also had a concomitant robotic procedure (Mitrofanoff appendicovesicostomy, antegrade colonic enema channel, bladder neck closure). The RAI technique involved intracorporeal isolation bowel division and end-to-end anastomosis, and then bi-valving the bladder with a coronal cystotomy and a subsequent ileal graft continuous anastomosis (all performed intracorporeally). Although the authors report a shorter median LOS with RAI (6 vs 8 days;  $P = 0.01$ ), there were no differences in median blood loss, opiate requirement, and return to full diet, although epidural usage was less in the robotic cohort [97]. Functional outcomes and complications were similar in both groups. The operative duration for RAI in this study was 623 min (vs 265 min for open) indicating this procedure remains in its infancy [97].

Therefore, based on the limited data available, although being a safe and technically feasible procedure the benefits of RAI over open surgery remain to be

confirmed. Further studies expanding on the case numbers currently described are required before transition into routine clinical practice occurs.

### Robot-assisted artificial urinary sphincter insertion (AUS)

The most common indication of AUS insertion in contemporary practice is for post-prostatectomy UI, where the AUS cuff is placed around the bulbar urethra. However, bladder neck cuff placement is the preferred site in men with neurogenic SUI (in order to minimise device erosion) and women with SUI with prior unsuccessful conservative and surgical treatments. Traditionally bladder neck AUS insertion has been performed via an open incision, but recent studies have shown that a RAS approach is feasible.

Six publications were identified reporting on a RAS approach for AUS implantation. Two case series in men have been reported [102,106], a further three publications were case series in women with SUI (103–105), and one paediatric case report, have been published.

Yates et al. [102] reported on six men with neurogenic (spinal cord injury) sphincter incompetence causing refractory SUI. Patients underwent bladder neck AUS (AMS 800, American Medical Systems) placement using a robot-assisted transperitoneal approach. Posterior bladder neck dissection was initially performed via a

posterior peritoneal incision overlying the seminal vesicles/vas deferens. Subsequently, the space of Retzius was developed, and lateral prostate dissection was performed to identify the precise location of the bladder neck circumferentially. Tape measurement of the bladder neck preceded intracorporeal placement of the AUS at this site. Device tubing, pump and reservoir were all inserted via a small right iliac fossa incision, with the reservoir placed intra-abdominally in the lateral vesicular space, and pump placed in the scrotum, before the device was connected and pressurised. The authors report good functional outcomes, with no Clavien–Dindo Grade  $\geq$ II complications and blood loss of  $> 150$  mL in only one patient. However, in a series of four male patients with neurogenic SUI undergoing bladder neck AUS cuff placement, Hervé et al. [106] reported ongoing UI in two patients due to insufficient traction of the cuff around the bladder neck.

Three studies have reported on 25 female patients with intrinsic sphincter deficiency causing SUI treated with robot-assisted AUS insertion [103–105]. In these studies all patients had multiple failed previous procedures for SUI. All authors used a similar surgical approach. The space of Retzius was developed down to the bladder neck, endopelvic fascia incised bilaterally, and the bladder neck dissected from the vagina below the periurethral fascia. Subsequently, tape measurement and subsequent bladder neck cuff placement was performed. The reservoir was placed in the pre-vesical or lateral *para*-vesical space and the pump placed in the labia majora. All authors describe use of a planned cystotomy in selected patients to aid dissection around the bladder neck in an attempt to avoid bladder or vaginal injury.

In one study a non-randomised comparison against open AUS insertion was performed demonstrating a reduced operative duration, blood loss, LOS, and overall complication rate with RAS, but with no significant difference in functional outcomes in comparison to open surgery [105].

However, complication rates following robot-assisted AUS insertion appear high. Peyronnet et al. [105] reported that two of eight patients in the RAS group had intraoperative vaginal injuries, although this was equivalent to a comparative cohort undergoing open surgery. However, the incidence of bladder injury was lower in the RAS group [one of eight patients vs seven of 16 (44%)]. Biardeau et al. [104] also reported a high incidence (four of 11 patients) of visceral injury (two vaginal and two bladder) with robot-assisted AUS insertion. Although the authors' state patient factors heavily contributed to visceral injuries, with such high intraoperative complications [104,105], clearly other prospective studies comparing RAS vs open/laparoscopic insertion are required to assess its safety and benefit over open surgery.

## Conclusions

The role of RAS continues to develop within the field of urological surgery. Here we present the growing evidence demonstrating that the breadth and complexity of surgical procedures performed using the da Vinci platform is continually expanding. There is a gaining consensus that RAS is producing promising surgical results in wide range of procedures and with accumulating expertise will continue to do so. However, a major limitation of the current literature evaluating urological RAS is the sparsity of comparative trials, in particular those randomising patients to RAS and conventional approaches. This is not only for emerging RAS techniques, but also for more established oncological RAS procedures, which are now routinely used.

The foremost controversy concerning the use of RAS lies in the associated capital and running costs of this technology. Therefore it is essential that future studies should not only assess the potential clinical advantages of RAS, but also the cost-effectiveness.

## Conflict of interest

None.

## Source of funding

None.

## References

- [1] Honda M, Morizane S, Hikita K, Takenaka A. Current status of robotic surgery in urology. *Asian J Endosc Surg* 2017;**10**:372–81.
- [2] Iannetti A, Gnech M, Rossanese M, Abbinante M, De Giorgi G, Mottrie A, et al. Robot-assisted renal surgery: current indications and results. *Minerva Urol Nefrol* 2014;**66**:15–24.
- [3] Lowrance WT, Eastham JA, Savage C, Maschino AC, Laudone CB, Dechet CB, et al. Contemporary open and robotic radical prostatectomy practice patterns among urologists in the United States. *J Urol* 2012;**187**:2087–92.
- [4] Menon M, Shrivastava A, Tewari A, Sarle R, Hemal A, Peabody JO, et al. Laparoscopic and robot assisted radical prostatectomy: establishment of a structured program and preliminary analysis of outcomes. *J Urol* 2002;**168**:945–9.
- [5] Yaxley JW, Coughlin GD, Chambers SK, Occhipinti S, Samarungana H, Zajdlewicz L, et al. Robot-assisted laparoscopic prostatectomy versus open radical retropubic prostatectomy: early outcomes from a randomised controlled phase 3 study. *Lancet* 2016;**388**:1057–66.
- [6] Tang K, Jiang K, Chen H, Chen Z, Xu H, Ye Z. Robotic vs. Retropubic radical prostatectomy in prostate cancer: a systematic review and a meta-analysis update. *Oncotarget* 2017;**8**:32237–57.
- [7] Ramsay C, Pickard R, Robertson C, Close A, Vale L, Armstrong N, et al. Systematic review and economic modelling of the relative clinical benefit and cost-effectiveness of laparoscopic surgery and robotic surgery for removal of the prostate in men with localised prostate cancer. *Health Technol Assess* 2012;**16**:1–313. <https://doi.org/10.3310/hta16410>.

- [8] Menon M, Hemal AK, Tewari A, Shrivastava A, Shoma AM, El-Tabey NA, et al. Nerve-sparing robot-assisted radical cystoprostatectomy and urinary diversion. *BJU Int* 2003;**92**:232–6.
- [9] Li K, Lin T, Fan X, Xu K, Bi L, Duan Y, et al. Systematic review and meta-analysis of comparative studies reporting early outcomes after robot-assisted radical cystectomy versus open radical cystectomy. *Cancer Treat Rev* 2013;**39**:551–60.
- [10] Ahmed K, Khan SA, Hayn MH, Agarwal PK, Badani KK, Balbay MD, et al. Analysis of intracorporeal compared with extracorporeal urinary diversion after robot-assisted radical cystectomy: results from the International Robotic Cystectomy Consortium. *Eur Urol* 2014;**65**:340–7.
- [11] Koupparis A, Villeda-Sandoval C, Weale N, El-Mahdy M, Gillatt D, Rowe E. Robot-assisted radical cystectomy with intracorporeal urinary diversion: impact on an established enhanced recovery protocol. *BJU Int* 2015;**116**:924–31.
- [12] Lee R, Chughtai B, Herman M, Shariat SF, Scherr DS. Cost-analysis comparison of robot-assisted laparoscopic radical cystectomy (RC) vs open RC. *BJU Int* 2011;**108**:976–83.
- [13] Bansal SS, Dogra T, Smith PW, Amran M, Auluck I, Bhambra M, et al. Cost analysis of open radical cystectomy versus robot-assisted radical cystectomy. *BJU Int* 2018;**121**:437–44.
- [14] Ghani KR, Sukumar S, Sammon JD, Rogers CG, Trinh QD, Menon M. Practice patterns and outcomes of open and minimally invasive partial nephrectomy since the introduction of robotic partial nephrectomy: results from the Nationwide inpatient sample. *J Urol* 2014;**191**:907–12.
- [15] Aboumarzouk OM, Stein RJ, Eyraud R, Haber GP, Chlosta PL, Somani BK, et al. Robotic versus laparoscopic partial nephrectomy: a systematic review and meta-analysis. *Eur Urol* 2012;**62**:1023–33.
- [16] Eyraud R, Long JA, Snow-Lisy D, Autorino R, Hillyer S, Klink J, et al. Robot-assisted partial nephrectomy for hilar tumors: perioperative outcomes. *Urology* 2013;**81**:1246–52.
- [17] Shuch B, Singer EA, Bratslavsky G. The surgical approach to multifocal renal cancers: hereditary syndromes, ipsilateral multifocality, and bilateral tumors. *Urol Clin North Am* 2012;**39**:133–48.
- [18] Autorino R, Eden C, El-Ghoneimi A, Guazzoni G, Buffi N, Peters CA, et al. Robot-assisted and laparoscopic repair of ureteropelvic junction obstruction: a systematic review and meta-analysis. *Eur Urol* 2014;**65**:430–52.
- [19] Moher D, Liberati A, Tetzlaff J, Altman DG, The PRISMA Group. Preferred Reporting Items for Systematic Reviews and Meta-Analyses: the PRISMA statement. *PLoS Med* 2009;**6**: e1000097. <https://doi.org/10.1371/journal.pmed1000097>.
- [20] Gravas S, Bach T, Drake M, Gacci M, Gratzke C, Herrmann TR et al. EAU Guidelines Management of Non-neurogenic Male Lower Urinary Tract Symptoms (LUTS), incl. Benign Prostatic Obstruction (BPO). European Association of Urology, 2017. Available at: [https://uroweb.org/wp-content/uploads/13-Non-Neurogenic-Male-LUTS\\_2017\\_web.pdf](https://uroweb.org/wp-content/uploads/13-Non-Neurogenic-Male-LUTS_2017_web.pdf). Accessed June 2018.
- [21] Humphreys MR, Miller NL, Handa SE, Terry C. Holmium laser enucleation of the prostate—outcomes independent of prostate size? *J Urol* 2008;**180**:2431–5.
- [22] Asimakopoulos AD, Mugnier C, Hoepffner JL, Spera E, Vespasiani G, Gaston R, et al. The surgical treatment of a large prostatic adenoma: the laparoscopic approach—a systematic review. *J Endourol* 2012;**26**:960–7.
- [23] Sotelo R, Clavijo R, Carmona O, Garcia A, Banda E, Miranda M, et al. Robotic simple prostatectomy. *J Urol* 2008;**179**:513–5.
- [24] Yuh B, Laungani R, Perlmutter A, Eun D, Peabody JO, Mohler JL, et al. Robot-assisted Millin's retropubic prostatectomy: case series. *Can J Urol* 2008;**15**:4101–5.
- [25] John H, Bucher C, Engel N, Fischer B, Fehr JL. Preperitoneal robotic prostate adenectomy. *Urology* 2009;**73**:811–5.
- [26] Uffort EE, Jensen JC. Robotic-assisted laparoscopic simple prostatectomy: an alternative minimal invasive approach for prostate adenoma. *J Robot Surg* 2010;**4**:7–10.
- [27] Matei DV, Spinelli MG, Nordio A, Brescia A, Crisan N, Coman I. Robotic simple prostatectomy. *Eur Urol Suppl* 2008;**9**:337.
- [28] Sutherland DE, Perez DS, Weeks DC. Robot-assisted simple prostatectomy for severe benign prostatic hyperplasia. *J Endourol* 2011;**25**:641–4.
- [29] Vora A, Mittal S, Hwang J, Bandi G. Robot-assisted simple prostatectomy: multi-institutional outcomes for glands larger than 100 grams. *J Endourol* 2012;**26**:499–502.
- [30] Matei DV, Brescia A, Mazzoleni F, Spinelli M, Musi G, Melegari S, et al. Robot-assisted simple prostatectomy (RASP): does it make sense? *BJU Int* 2012;**110**:972–9.
- [31] Coelho RF, Chauhan S, Sivaraman A, et al. Modified technique of robotic-assisted simple prostatectomy: advantages of a vesicourethral anastomosis. *BJU Int* 2012;**109**:426–33.
- [32] Clavijo R, Carmona O, Palmer KJ, Orvieto MA, Rocco B, et al. Robot-assisted simple prostatectomy: novel technique. *J Endourol* 2013;**27**:328–32.
- [33] Banapour P, Patel N, Kane CJ, Cohen SA, Parsons JK. Robotic-assisted simple prostatectomy: a systematic review and report of a single institution case series. *Prostate Cancer Prostatic Dis* 2014;**17**:1–5.
- [34] Leslie S, de Castro Abreu AL, Chopra S, Ramos P, Park D, Berger AK, et al. Transvesical robotic simple prostatectomy: initial clinical experience. *Eur Urol* 2014;**66**:321–9.
- [35] Pokorny M, Novara G, Geurts N, Dovey Z, De Groote R, Ploumidis A, et al. Robot-assisted simple prostatectomy for treatment of lower urinary tract symptoms secondary to benign prostatic enlargement: surgical technique and outcomes in a high-volume robotic centre. *Euro Urol* 2015;**68**:451–7.
- [36] Autorino R, Zargar H, Mariano MB, Sanchez-Salas R, Sotelo PL, Chlosta PL, et al. Perioperative outcomes of robotic and laparoscopic simple prostatectomy: a European-American multi-institutional analysis. *Eur Urol* 2015;**68**:86–94.
- [37] Patel ND, Parsons JK. Robotic-assisted simple prostatectomy: is there evidence to go beyond the experimental stage? *Curr Urol Rep* 2014;**15**:443. <https://doi.org/10.1007/s11934-014-0443-0>.
- [38] Martín Garzón OD, Azhar RA, Brunacci L, Ramirez-Troche L, Medina Navarro L, Hernández LC, et al. One-year outcome comparison of laparoscopic, robotic, and robotic intrafascial simple prostatectomy for benign prostatic hyperplasia. *J Endourol* 2016;**30**:312–8.
- [39] Umari P, Fossati N, Gandaglia G, Pokorny M, De Groote R, Geurts N, et al. Robotic assisted simple prostatectomy (RASP) versus holmium laser enucleation of the prostate (HoLEP) for lower urinary tract symptoms in patients with large volume prostates (> 100ml): a comparative analysis from a high volume center. *J Urol* 2017;**197**:1108–14.
- [40] Stolzenburg JU, Kallidonis P, Qazi H, Ho Thi P, Dietel A, Liatsikos EN, et al. Extraperitoneal approach for robotic-assisted simple prostatectomy. *Urology* 2014;**84**:1099–105.
- [41] Sorokin I, Sundaram V, Singla N, Walker J, Margulis V, Roehrborn C, et al. Robot-assisted versus open simple prostatectomy for benign prostatic hyperplasia in large glands: a propensity score-matched comparison of perioperative and short-term outcomes. *J Endourol* 2017;**31**:1164–9.
- [42] Li M, Qiu J, Hou Q, Wang D, Huang W, Hu C, et al. Endoscopic enucleation versus open prostatectomy for treating large benign prostatic hyperplasia: a meta-analysis of randomized controlled trials. *PLoS One* 2015;**10**. <https://doi.org/10.1371/journal.pone.0121265> e0121265.
- [43] Chade DC, Eastham J, Graefen M, Hu JC, Karnes RJ, Klotz L, et al. Cancer control and functional outcomes of salvage radical prostatectomy for radiation-recurrent prostate cancer: a systematic review of the literature. *Eur Urol* 2012;**61**:961–71.

- [44] Jamal K, Challacombe B, Elhage O, Popert R, Kirby R, Dasgupta P. Successful salvage robotic-assisted radical prostatectomy after external beam radiotherapy failure. *Urology* 2008;**72**:1356–8.
- [45] Kaouk JH, Hafron J, Goel R, Haber GP, Jones JS. Robotic salvage retropubic prostatectomy after radiation/brachytherapy: initial results. *BJU Int* 2008;**102**:93–6.
- [46] Boris RS, Bhandari A, Krane LS, Eun D, Kaul S, Peabody J. Salvage robotic-assisted radical prostatectomy: initial results and early report of outcomes. *BJU Int* 2009;**103**:952–6.
- [47] Strobe SA, Coelho M, Wood DP, Hollenbeck BK. Robot-assisted salvage prostatectomy: evaluation of initial patient-reported outcomes. *J Endourol* 2010;**24**:425–7.
- [48] Eandi JA, Ba Link, Nelson RA, Josephson DY, Lau C, Kawachi MH, et al. Robotic assisted laparoscopic salvage prostatectomy for radiation resistant prostate cancer. *J Urol* 2010;**183**:133–7.
- [49] Zugar V, Labanarisa P, Porres D, Heidenreich A, Witt JH. Robot-assisted radical prostatectomy for the treatment of radiation-resistant prostate cancer: surgical, oncological and short-term functional outcomes. *Urol Int* 2014;**92**:20–6.
- [50] Yuh B, Ruel N, Muldrew S, Mejia R, Novara G, Kawachi M, et al. Complications and outcomes of salvage robot-assisted radical prostatectomy: a single-institution experience. *BJU Int* 2014;**113**:769–76.
- [51] Kaffenberger SD, Keegan KA, Bansal NK, Morgan TM, Tang DA, Barocas DA, et al. Salvage robotic assisted laparoscopic radical prostatectomy: a single institution, 5-year experience. *J Urol* 2013;**189**:507–13.
- [52] Bates AS, Samavedi S, Kumar A, Mouraviev V, Rocco B, Coelho R, et al. Salvage robot assisted radical prostatectomy: a propensity matched study of perioperative, oncological and functional outcomes. *Eur J Surg Oncol* 2015;**41**:1540–6.
- [53] Vora A, Agarwal V, Singh P, Patel R, Rivas R, Nething J, et al. Single-institution comparative study on the outcomes of salvage cryotherapy versus salvage robotic prostatectomy for radio-resistant prostate cancer. *Prostate Int* 2016;**4**:7–10.
- [54] Zargar H, Lamb AD, Rocco B, Porpiglia F, Liatsikos E, Davis J, et al. Salvage robotic prostatectomy for radio recurrent prostate cancer: technical challenges and outcome analysis. *Minerva Urol Nefrol* 2017;**69**:26–37.
- [55] Wang X, Li S, Liu T, Guo Y, Yang Z. Laparoscopic pyelolithotomy compared to percutaneous nephrolithotomy as surgical management for large renal pelvic calculi: a meta-analysis. *J Urol* 2013;**190**:888–93.
- [56] Atug F, Castle EP, Burgess SV, Thomas R. Concomitant management of renal calculi and pelvi-ureteric junction obstruction with robotic laparoscopic surgery. *BJU Int* 2005;**96**:1365–8.
- [57] Badani KK, Hemal AK, Fumo M, Kaul S, Shrivastava A, Rajendram AK, et al. Robotic extended pyelolithotomy for treatment of renal calculi: a feasibility study. *World J Urol* 2006;**24**:198–201.
- [58] Lee RS, Passerotti CC, Cendron M, Estrada CR, Borer JG, Peters CA. Early results of robot assisted laparoscopic lithotomy in adolescents. *J Urol* 2007;**177**:2306–9.
- [59] Mufarrij PW, Woods M, Shah OD, Palese MA, Berger AD, Thomas R, et al. Robotic dismembered pyeloplasty: a 6-year, multi-institutional experience. *J Urol* 2008;**180**:1391–6.
- [60] Ghani KR, Rogers CG, Sood A, Kumar R, Ehlert M, Jeong W, et al. Robot-assisted anastrophic nephrolithotomy with renal hypothermia for managing staghorn calculi. *J Endourol* 2013;**27**:1393–8.
- [61] King SA, Klaassen Z, Madi R. Robot-assisted anastrophic nephrolithotomy: description of technique and early results. *J Endourol* 2014;**28**:325–9.
- [62] Swearingen R, Sood A, Madi R, Klaassen Z, Badani K, Elder JS, et al. Zero-fragment nephrolithotomy: a multi-center evaluation of robotic pyelolithotomy and nephrolithotomy for treating renal stones. *Eur Urol* 2017;**72**:1014–21.
- [63] Mir SA, Cadeddu JA, Sleeper JP, Lotan Y. Cost comparison of robotic, laparoscopic, and open partial nephrectomy. *J Endourol* 2011;**25**:447–53.
- [64] Hyams ES, Shah O. Percutaneous nephrostolithotomy versus flexible ureteroscopy/holmium laser lithotripsy: cost and outcome analysis. *J Urol* 2009;**182**:1012–7.
- [65] Dogra PN, Regmi SK, Singh P, Saini AK, Nayak B. Lower ureteral stones revisited: expanding the horizons of robot. *Urology* 2013;**82**:95–9.
- [66] Williams SK, Leveillee RJ. Expanding the horizons: robot-assisted reconstructive surgery of the distal ureter. *J Endourol* 2009;**23**:457–61.
- [67] Schimpf MO, Wagner JR. Robot-assisted laparoscopic distal ureteral surgery. *JSLs* 2009;**13**:44–9.
- [68] Glinianski M, Guru KA, Zimmerman G, Mohler J, Kim HL. Robot-assisted ureterectomy and ureteral reconstruction for urothelial carcinoma. *J Endourol* 2009;**23**:97–100.
- [69] Hemal AK, Nayyar R, Gupta NP, Dorairajan LN. Experience with robot assisted laparoscopic surgery for upper and lower benign and malignant ureteral pathologies. *Urology* 2010;**76**:1387–93.
- [70] Patil NN, Mottrie A, Sundaram B, Patel VR. Robotic-assisted laparoscopic ureteral reimplantation with psoas hitch: a multi-institutional, multinational evaluation. *Urology* 2008;**72**:47–51.
- [71] McClain PD, Mufarrij PW, Hemal AK. Robot-assisted reconstructive surgery for ureteral malignancy: analysis of efficacy and oncologic outcomes. *J Endourol* 2012;**26**:1614–7.
- [72] Kozinn SI, Canes D, Sorcini A, Moizadeh A. Robotic versus open distal ureteral reconstruction and reimplantation for benign stricture disease. *J Endourol* 2012;**26**:147–51.
- [73] Baldie K, Angell J, Ogan K, Hood N, Pattaras JG. Robotic management of benign mid and distal ureteral strictures and comparison with laparoscopic approaches at a single institution. *Urology* 2012;**80**:596–601.
- [74] Isac W, Kaouk J, Altunrende F, Rizkala E, Autorino R, Hillyer SP, et al. Robot-assisted ureteroneocystostomy: technique and comparative outcomes. *J Endourol* 2013;**27**:318–23.
- [75] Musch M, Hohenhorst L, Pailliart A, Loewen H, Davoudi Y, Kroepfl D. Robot-assisted reconstructive surgery of the distal ureter: single institution experience in 16 patients. *BJU Int* 2013;**111**:773–83.
- [76] Gellhaus PT, Bhandari A, Monn MF, Gardner TA, Kanagarajah P, Reilly CE, et al. Robotic management of genitourinary injuries from obstetric and gynaecological operations: a multi-institutional report of outcomes. *BJU Int* 2015;**115**:430–6.
- [77] Fifer GL, Raynor MC, Selph P, Woods ME, Wallen EM, Viprakasit DP, et al. Robotic ureteral reconstruction distal to the ureteropelvic junction: a large single institution clinical series with short-term follow up. *J Endourol* 2014;**28**:1424–8.
- [78] Slater RC, Farber NJ, Riley JM, Shilo Y, Ost MC. Contemporary series of robotic-assisted distal ureteral reconstruction utilizing side docking position. *Int Braz J Urol* 2015;**41**:1154–9.
- [79] Wason SE, Lance RS, Given RW, Malcolm JB. Robotic-assisted ureteral re-implantation: a case series. *J Laparoendosc Adv Surg Tech A* 2015;**25**:503–7.
- [80] Stolzenburg JU, Rai BP, Do M, Dietel A, Liatsikos E, Ganzer R, et al. Robot-assisted technique for Boari flap ureteric reimplantation: replicating the techniques of open surgery in robotics. *BJU Int* 2016;**118**:482–4.
- [81] Franklin A, Pokala N, Jones C, Johans C, Strom K, Cummings J. Is the robotic approach feasible for repair of iatrogenic injuries of the lower ureter? *World J Urol* 2016;**34**:1323–8.
- [82] Schiavina R, Zaramella S, Chessa F, Pultrone CV, Borghesi M, Minervini A, et al. Laparoscopic and robotic ureteral stenosis repair: a multi-institutional experience with a long-term follow-up. *J Robot Surg* 2016;**10**:323–30.
- [83] Rassweiler JJ, Scheitlin W, Heidenreich A, Laguna MP, Janetschek G. Laparoscopic retroperitoneal lymph node dissec-

- tion: does it still have a role in the management of clinical stage I nonseminomatous testis cancer? A European perspective. *Eur Urol* 2008;**54**:1004–15.
- [84] Steiner H, Leonhartsberger N, Stoehr B, Peschel R, Pichler R. Postchemotherapy laparoscopic retroperitoneal lymph node dissection for low-volume, stage II, nonseminomatous germ cell tumor: first 100 patients. *Eur Urol* 2013;**63**:1013–7.
- [85] Davol P, Sumfest J, Rukstalis D. Robotic-assisted laparoscopic retroperitoneal lymph node dissection. *Urology* 2006;**67**(199): e7–8.
- [86] Cheney SM, Andrews PE, Leibovich BC, Castle EP. Robot-assisted retroperitoneal lymph node dissection: technique and initial case series of 18 patients. *BJU Int* 2015;**115**:114–20.
- [87] Harris KT, Gorin MA, Ball MW, Pierorazio PM, Allaf ME. A comparative analysis of robotic vs laparoscopic retroperitoneal lymph node dissection for testicular cancer. *BJU Int* 2015;**116**:920–3.
- [88] Kamel MH, Littlejohn N, Cox M, Eltahawy EA, Davis R. Post-chemotherapy robotic retroperitoneal lymph node dissection: institutional experience. *J Endourol* 2016;**30**:510–9.
- [89] Pearce SM, Golan S, Gorin MA, Luckenbaugh AN, Williams JF, Ward JF, et al. Safety and early oncologic effectiveness of primary robotic retroperitoneal lymph node dissection for nonseminomatous germ cell testicular cancer. *Eur Urol* 2017;**71**:476–82.
- [90] Stepanian S, Patel M, Porter J. Robot-assisted laparoscopic retroperitoneal lymph node dissection for testicular cancer: evolution of the technique. *Eur Urol* 2016;**70**:661–7.
- [91] Singh A, Chatterjee S, Bansal P, Bansal A, Rawal S. Robot-assisted retroperitoneal lymph node dissection: feasibility and outcome in postchemotherapy residual mass in testicular cancer. *Indian J Urol* 2017;**33**:304–9.
- [92] Heidenreich A, Pfister D, Witthuhn R, Thüer D, Albers P. Postchemotherapy retroperitoneal lymph node dissection in advanced testicular cancer: radical or modified template resection. *Eur Urol* 2009;**55**:217–24.
- [93] Albers P, Albrecht W, Algaba F, Bokemeyer C, Cohn-Cedermarck G, Fizaziet K et al. EAU Guidelines on. Testicular cancer. European Association of Urology 2017. Available at: [https://uroweb.org/wp-content/uploads/11-Testicular-Cancer\\_2017\\_-web.pdf](https://uroweb.org/wp-content/uploads/11-Testicular-Cancer_2017_-web.pdf). Accessed June 2018.
- [94] Albers P, Siener R, Krege S, Schmelz HU, Dieckmann KP, Heidenreich A, et al. Randomized phase III trial comparing retroperitoneal lymph node dissection with one course of bleomycin and etoposide plus cisplatin chemotherapy in the adjuvant treatment of clinical stage I Nonseminomatous testicular germ cell tumors: AUO trial AH 01/94 by the German Testicular Cancer Study Group. *J Clin Oncol* 2008;**26**:2966–72.
- [95] Gundeti MS, Eng MK, Reynolds WS, Zagaja GP. Pediatric robotic-assisted laparoscopic augmentation ileocystoplasty and Mitrofanoff appendicovesicostomy: complete intracorporeal – initial case report. *Urology* 2008;**72**:1144–7.
- [96] Madec FX, Hedhli O, Perrouin-Verbe MA, Levesque A, Le Normand L, Rigaud J. Feasibility, morbidity, and functional results of supratrigonal cystectomy with augmentation ileocystoplasty by combined robot-assisted laparoscopy and mini-laparotomy approach. *J Endourol* 2017;**31**:655–60.
- [97] Murthy P, Cohn JA, Selig RB, Gundeti MS. Robot-assisted laparoscopic augmentation ileocystoplasty and Mitrofanoff appendicovesicostomy in children: updated interim results. *Eur Urol* 2015;**68**:1069–75.
- [98] Cohen AJ, Brodie K, Murthy P, Wilcox DT, Gundeti MS. Comparative outcomes and perioperative complications of robotic vs open cystoplasty and complex reconstructions. *Urology* 2016;**97**:172–8.
- [99] Gundeti MS, Acharya SS, Zagaja GP, Shalhav AL. Paediatric robotic-assisted laparoscopic augmentation ileocystoplasty and Mitrofanoff appendicovesicostomy (RALIMA): feasibility of and initial experience with the University of Chicago technique. *BJU Int* 2011;**107**:962–9.
- [100] Gundeti MS, Acharya SS, Zagaja GP. The University of Chicago technique of complete intracorporeal pediatric robotic-assisted laparoscopic augmentation ileocystoplasty and Mitrofanoff appendicovesicostomy. *J Robot Surg* 2009;**3**:89–93.
- [101] Razmaria AA, Marchetti PE, Prasad SM, Shalhav AL, Gundeti MS. Does robot-assisted laparoscopic ileocystoplasty (RALI) reduce peritoneal adhesions compared with open surgery? *BJU Int* 2014;**113**:468–75.
- [102] Yates DR, Phé V, Rouprêt M, Vaessen C, Parra J, Mozer P, et al. Robot-assisted laparoscopic artificial urinary sphincter insertion in men with neurogenic stress urinary incontinence. *BJU Int* 2013;**111**:1175–9.
- [103] Fournier G, Callerot P, Thoulouzan M, Valeri A, Perrouin-Verbe MA. Robotic-assisted laparoscopic implantation of artificial urinary sphincter in women with intrinsic sphincter deficiency incontinence: initial results. *Urology* 2014;**84**:1094–8.
- [104] Biardeau X, Rizk J, Marcelli F, Flamand V. Robot-assisted laparoscopic approach for artificial urinary sphincter implantation in 11 women with urinary stress incontinence: surgical technique and initial experience. *Eur Urol* 2015;**67**:937–42.
- [105] Peyronnet B, Vincendeau S, Tondut L, Bensalah K, Dampousse M, Manunta A. Artificial urinary sphincter implantation in women with stress urinary incontinence: preliminary comparison of robot-assisted and open approaches. *Int Urogynecol J* 2016;**27**:475–81.
- [106] Hervé F, Lumen N, Goessaert AS, Everaert K. Persistent urinary incontinence after a robot-assisted artificial urinary sphincter procedure: lessons learnt from two cases. *BMJ Case Rep* 2016. <https://doi.org/10.1136/bcr-2016-216971>, pii: bcr2016216971.