



## Lateral dislocation of the elbow joint in children: a case report

Zied Missaoui, MD\*, Mohamad K. Moussa, MD, Lucas Pouzenc, MD, Ali A. Hellani, MD, Ali Alayane, MD

Department of Orthopedic Surgery, Grand Hospital de l'Est Francilien – Site de Meaux, Meaux, France

### ARTICLE INFO

#### Keywords:

Closer reduction  
Dislocation  
Lateral elbow injury  
Pediatric elbow

Elbow dislocations are rare injury in pediatric traumatology, with a reported incidence of 3%–6% of all injuries around the elbow.<sup>11</sup> When it occurs, the direction of the dislocation is posterior in most reported cases.<sup>6</sup> Other rare directions include anterior, medial, lateral, and divergent types. Of these types, pure lateral dislocation without associated fracture represents a particularly rare form that deserves special attention because of the lack of enough data and clear guidelines to treat it.<sup>4,13</sup> Only a few cases have been reported in the literature, where the population was mainly older children and adults.<sup>4,13</sup> The aim of this article is to report a rare case of a 14-year-old female patient presenting with pure lateral elbow dislocation that was treated with gentle closed reduction and immobilization. We present a review of literature of similar cases and a discussion of all aspects of the case.

### Case presentation

A 14-year-old girl was brought to our orthopedic emergency department after she fell down on her left wrist with left elbow extension during a gymnastic training session. On general examination, she was in severe pain with functional impotence of his left upper limb and moderate swelling of the left elbow. No other injury was noted, distal neurovascular status was intact. Elbow radiographs revealed a pure incomplete lateral elbow dislocation without associated fracture (Fig. 1). No other investigations were advised.

Closed reduction under sedation with longitudinal traction to the distal forearm in supination with counter-traction applied from the upper arm, this was followed by manual medial pressure at the

elbow region leading to a clinical reduction confirmed on check radiographs (Fig. 2). The elbow was tested to confirm its stability, and then, it was immobilized in 90 degrees with an above elbow posterior splint for 3 weeks.

At the 3-week follow-up, she had a pain level of 2/10 especially with extreme of motion. She had a range of motion from 5° to 100° of flexion, without any elbow instability (no varus stress instability, no valgus stress instability, no apprehension with posterolateral drawer test, or posterolateral instability testing, no apprehension at any level of the range of motion). She was able to do her daily living activities such as combing her hair, performing her personnel hygiene, eating independently, and putting on her shirts and shoes. At this time, active and passive rehabilitation of the elbow was started under the supervision of a physiotherapist, at a rate of two times per week for three weeks, associated with self-rehabilitation at home. The rehab protocol was focusing on early active range of motion and muscle strengthening exercise. At 3 months, her physical examination revealed an elbow with complete range of motion, comparable with the contralateral arm without any residual objective elbow instability. At this time, she was allowed to practice sport again.

She was able to return to sport competition the following year.

She was seen in consultation after two years. She presented with a stable, pain-free elbow with full range of motion, and denied any elbow instability. Radiograph at the 2-year follow-up is shown in Figure 3.

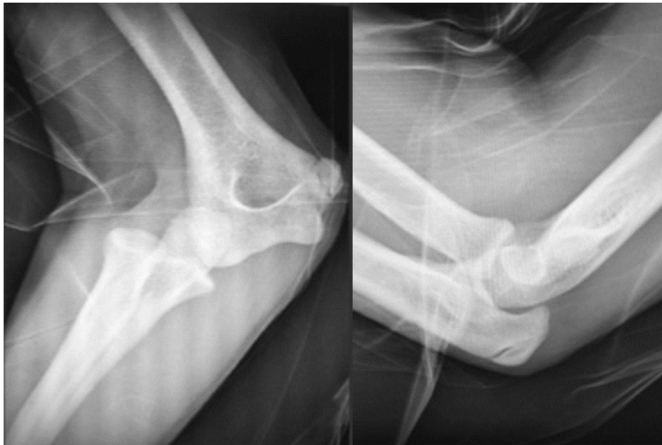### Discussion

Pure lateral elbow dislocation is an extremely rare variant of the elbow dislocation that is scarcely reported in literature.<sup>5</sup> In 1965, Linscheid and Wheeler reviewed 110 cases of elbow dislocation and found only two cases of lateral dislocations.<sup>8</sup> Similarly, in 1989, Robert reviewed 60 dislocations and found only two cases.<sup>9</sup> Borris et al<sup>1</sup> found only 1 lateral dislocation when reviewing 63 cases

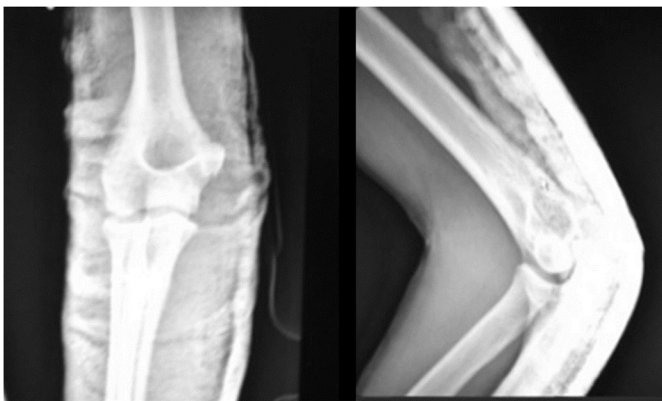
Institutional review board approval was received.

\*Corresponding author: Zied Missaoui, MD, Department of Orthopedic Surgery, Grand Hospital de l'Est Francilien – Site de Meaux, Meaux 77100, France.

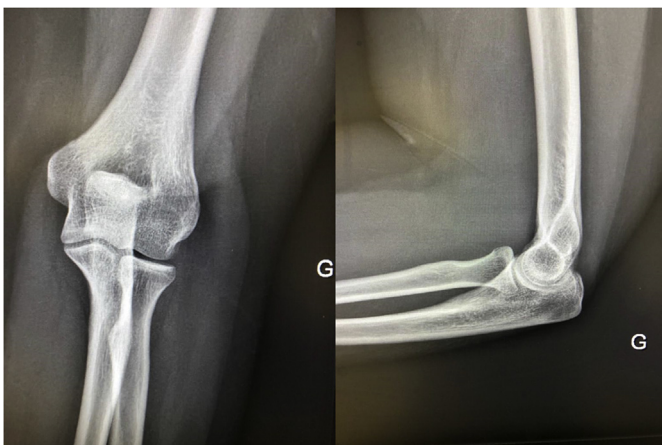
E-mail address: [ziedmissaoui79@gmail.com](mailto:ziedmissaoui79@gmail.com) (Z. Missaoui).



**Figure 1** Anteroposterior and lateral radiograph of elbow showing incomplete pure left lateral elbow dislocation.



**Figure 2** Anteroposterior and lateral radiograph of elbow after reduction of dislocation.



**Figure 3** Anteroposterior and lateral radiograph of elbow at 2-year follow-up.

among both adults and children. Furthermore, in 2016, Kaziz et al<sup>7</sup> conducted a study about the outcomes of elbow dislocations in pediatric age group and they found only 1 case of lateral elbow dislocation out of 48 cases.

The mechanism of injury for lateral elbow dislocation could be either direct trauma to the elbow on the medial side with elbow extension or indirect fall onto an outstretched hand with elbow hyperextension and pronation like our patient.<sup>3</sup> Speed et al<sup>10</sup> classified lateral dislocation into three types: complete with pronation of the forearm, complete without pronation of the forearm, and incomplete dislocation. In complete lateral dislocation of the elbow, there is loss of contact between the semilunar notch and the capitulo-trochlear groove on AP views.<sup>3</sup> Our case showed incomplete lateral elbow dislocation subtype owing to the preserved contact between the ulna and the lateral humeral condyle on AP view.

Medial epicondyle avulsion fracture due to immature growth plate and medial condyle fractures can be found in association with lateral dislocation and it can prevent reduction in pediatric age group owing to intra-articular fragments incarceration.<sup>12</sup> These associated injuries are considered equivalent to medial elbow collateral ligament injury responsible for valgus elbow stability.<sup>14</sup>

Ulnar and radial nerves are the most common nerve injuries associated with lateral elbow dislocation.<sup>10</sup>

When it comes to treatment, closed reduction is the treatment of choice of most dislocations.<sup>5</sup> The mechanism of reduction of pure lateral dislocation involves longitudinal traction and medial forearm pressure. This should be performed gently, and surgeons must be aware of the risk of soft-tissue incarceration; in fact, the anconeus muscle, brachialis muscle, and ulnar nerve have been reported as the cause of failure of close reduction after lateral dislocation of elbow.<sup>2,5</sup> In these cases operative treatment is inevitable.

## Conclusion

Pure incomplete lateral dislocation of the elbow is a rare entity in children. Careful analysis of elbow x-rays are essential to make the diagnosis of dislocation and associated bony injuries. Closed reduction with longitudinal traction and medial forearm pressure is a successful method of treatment in the absence of associated bony injuries and soft-tissue incarceration with excellent long-term functional outcome.

## Disclaimers:

*Funding:* No funding was disclosed by the author(s).

*Conflicts of interest:* The authors, their immediate families, and any research foundations with which they are affiliated have not received any financial payments or other benefits from any commercial entity related to the subject of this article.

*Patient consent:* Obtained.

## References

1. Borris LC, Lassen MR, Christensen CS. Elbow dislocation in children and adults. A long-term follow-up of conservatively treated patients. *Acta Orthop Scand* 1987;58:649-51.
2. Chhapparwal M, Aroojis A, Divekar M, Kulkarni S, Vaidya SV. Irreducible lateral dislocation of the elbow. *J Postgrad Med* 1997;43:19-20.
3. Dharmshaktu GS. Incomplete lateral elbow dislocation in children: a report of two cases. *Indian J Case Rep* 2019;5:126-9. <https://doi.org/10.32677/IJCR.2019.v05.i02.011>.
4. Dharmshaktu GS, Singhal A. Lateral dislocation of the elbow: a report of two cases and literature review. *Clin Trials Orthop Disord* 2016;1:79-82. <https://doi.org/10.4103/2468-5674.183006>.
5. Exarchou EJ. Lateral dislocation of the elbow. *Acta Orthop Scand* 1977;48:161-3.
6. Gokcen B, Ozyurek S, Atik A, Sivrioglu AK, Kaya E, Keklikci K. Successful closed manipulation of simple lateral dislocation of the elbow joint: a case report. *Oman Med J* 2013;28:e062. <https://doi.org/10.5001/omj.2013.131>.
7. Kaziz H, Naouar N, Osman W, Ayeche M. Outcomes of paediatric elbow dislocations. *Malays Orthop J* 2016;10:44-9. <https://doi.org/10.5704/MOJ.1603.008>.

8. Linscheid RL, Wheeler DK. Elbow dislocations. *JAMA* 1965;194:1171-6.
9. Roberts PH. Dislocation of the elbow. *Br J Surg* 1969;56:806-15.
10. Speed K. Dislocations at the elbow. In: *A textbook of fractures and dislocations*. 3rd ed. Philadelphia, PA: Lea and Febiger; 1935. p. 509.
11. Stans AA, Lawrence JTR. Dislocations of the elbow, medial epicondylar humerus fractures. In: *Rockwood and Wilkins' fractures in children*. 8<sup>th</sup> ed. (International); Wolter Kluwer Health; 2015. p. 651-700.
12. Vijaya S. Lateral dislocation of the elbow joint. *Singapore Med J* 1966;7:139-41.
13. Watanabe K, Fukuzawa T, Mitsui K. Successful closed reduction of a lateral elbow dislocation. *Case Rep Orthop* 2016;2016:5934281. <https://doi.org/10.1155/2016/5934281>.
14. Zarraa M, Saied W, Bouchoucha S, Ben Ghachem M. Purely lateral elbow dislocation in a child. Case report and literature review. *Chir Main* 2012;31:38-40. <https://doi.org/10.1016/j.main.2011.11.007>.