

## Nasal route for endoscopic ultrasound-guided fine-needle aspiration using echobronchoscope: The last resort

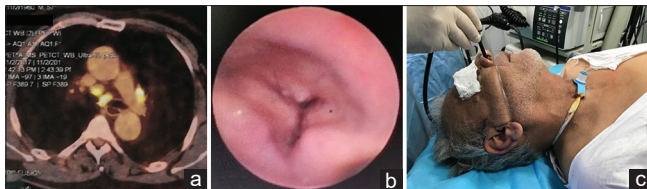
Sir,

Endoscopic ultrasound using echobronchoscope-guided fine-needle aspiration (EUS-B-FNA) is a technique where echobronchoscope is passed through the esophagus to perform needle aspiration from mediastinal lesions. Since its first description in 2009, the technique is increasingly being used by pulmonologists.<sup>[1,2]</sup> This technique is a path midway between endobronchial ultrasound (EBUS) performed by pulmonologists and endoscopic ultrasound (EUS) used by gastroenterologists. One crucial difference between EBUS scope and EUS scope is the larger size of the EUS scope, which helps in better stabilization during needle puncture. Both these scopes are conventionally inserted via the oral route using bite block. EBUS scope can be inserted using a nasal route, while EUS scope can only be used via oral route due to its large size.<sup>[3]</sup> Here, we present a case of mediastinal lymphadenopathy with reduced mouth opening and bilateral vocal cord palsy, which made the performance of EBUS as well as EUS virtually impossible, and we performed mediastinal lymph node sampling by EUS-B with scope insertion via nasal route.

A 57-year-old male patient was referred from otorhinolaryngology for the evaluation of mediastinal lymphadenopathy [Figure 1a]. He was a follow-up case of carcinoma larynx and had received chemoradiation for the same 2 years back. He had bilateral complete vocal cord adduction [Figure 1b] and was on tracheostomy for the last 2 years with a tracheostomy tube of size 5.5 mm (upsizing could not be done due to long-standing fibrosed tract). With this status, performing EBUS was considered not feasible. He had severely restricted mouth opening attributable to radiotherapy and tobacco use in the past, which made the insertion of EUS also impossible. Hence, keeping these two issues in mind, we performed EUS-B-FNA via nasal route using 5 mL of lignocaine gel as a lubricant and topical

anesthetic in the nasal cavity [Figure 1c]. Subcarinal lymph node was identified (12 mm × 14 mm), and three EUS-B-FNA passes were obtained. The cytological analysis of the aspirates showed fragments of squamous cell carcinoma, and the patient was referred to the radiotherapy unit for further management.

This is the first report of the use of the nasal route for echobronchoscope insertion during EUS-B-FNA. Echobronchoscope is usually inserted via oral route keeping its larger diameter (than flexible bronchoscope) in mind fearing the risk of nasal trauma in case of nasal insertion. As the external diameter of the EBUS scope is much smaller (6.9 mm) than the echoendoscope (14–15 mm), it can be used via nasal route, and the nasal route is feasible.<sup>[3]</sup> A randomized controlled trial has shown a nasal approach to be an acceptable way for EBUS scope insertion though a significant number of patients required a change of approach from nasal to the oral route during the study.<sup>[4]</sup> Flexible bronchoscopy is commonly performed through the nasal route, and it is perceived to provide better scope stabilization. While the oral route has been shown to cause less cough, it is also associated with higher chances of patient willingness to return for the bronchoscopy.<sup>[5]</sup> Oral route probably leads to earlier vocal cord visualization, but it needs the help of an assistant for bronchoscope stabilization. The route of scope insertion is usually determined by an operator depending upon comfort and previous experience. We usually perform EBUS and EUS-B via the oral route. The nasal route is used for EBUS in cases where oral entry is not feasible. EUS-B-FNA is commonly performed for obtaining samples from mediastinal lesions in the left paratracheal or subcarinal location. This technique is usually performed in small children or patients with unstable airway or respiratory failure. This is our first experience of performing EUS-B via nasal route, and we found it an acceptable route for sampling mediastinal lesions in patients with difficult oral entry as well as a difficult or unstable airway.



**Figure 1:** (a) Positron emission tomography–computed tomography demonstrating subcarinal and prevascular lymphadenopathy, (b) endoscopic view demonstrating complete adduction of vocal cords with no mobility, (c) external image of echobronchoscope insertion via nostril due to small size tracheostomy and restricted mouth opening

### Declaration of patient consent

The authors certify that they have obtained all appropriate patient consent forms. In the form the patient(s) has/have given his/her/their consent for his/her/their images and other clinical information to be reported in the journal. The patients understand that their names and initials will not be published and due efforts will be made to conceal their identity, but anonymity cannot be guaranteed.

**Financial support and sponsorship**

Nil.

**Conflicts of interest**

There are no conflicts of interest.

**Saurabh Mittal, Karan Madan, Anant Mohan, Vijay Hadda**

*Department of Pulmonary, Critical Care and Sleep Medicine,  
All India Institute of Medical Sciences, New Delhi, India.  
E-mail: saurabh\_kgmu@yahoo.co.in*

**Submitted:** 04-Jan-2020

**Accepted:** 17-Apr-2020

**Published:** 30-Oct-2020

**REFERENCES**

- Hwangbo B, Lee HS, Lee GK, Lim KY, Lee SH, Kim HY, *et al*. Transoesophageal needle aspiration using a convex probe ultrasonic bronchoscope. *Respirology* 2009;14:843-9.
- Madan K, Garg P, Kabra SK, Mohan A, Guleria R. Transesophageal bronchoscopic ultrasound-guided fine-needle aspiration (EUS-B-FNA) in a 3-year-old child. *J Bronchology Interv Pulmonol* 2015;22:347-50.
- Mittal S, Madan K, Hadda V, Mohan A, Guleria R. Nasal route for endobronchial ultrasound-guided transbronchial needle aspiration (EBUS-TBNA): An alternative modality in difficult oral bronchoscope insertion. *Lung India* 2017;34:472-4.
- Beaudoin S, Martel S, Pelletier S, Lampron N, Simon M, Laberge F, *et al*. Randomized trial comparing patient comfort between the oral and nasal insertion routes for linear endobronchial ultrasound. *J Bronchol Interv Pulmonol* 2016;23:39-45.
- Lechtzin N, Rubin HR, White P Jr., Jenckes M, Diette GB. Patient satisfaction with bronchoscopy. *Am J Respir Crit Care Med* 2002;166:1326-31.

This is an open access journal, and articles are distributed under the terms of the Creative Commons Attribution-NonCommercial-ShareAlike 4.0 License, which allows others to remix, tweak, and build upon the work non-commercially, as long as appropriate credit is given and the new creations are licensed under the identical terms.

**Access this article online****Quick Response Code:****Website:**

[www.lungindia.com](http://www.lungindia.com)

**DOI:**

10.4103/lungindia.lungindia\_5\_20

**How to cite this article:** Mittal S, Madan K, Mohan A, Hadda V. Nasal route for endoscopic ultrasound-guided fine-needle aspiration using echobronchoscope: The last resort. *Lung India* 2020;37:544-5.

© 2020 Indian Chest Society | Published by Wolters Kluwer - Medknow