

**STANDARD ARTICLE**

# Prevalence of gastrointestinal lesions in dogs chronically treated with nonsteroidal anti-inflammatory drugs

Kasey Mabry<sup>1</sup> | Tracy Hill<sup>2</sup>  | Mary Katherine Tolbert<sup>3</sup> 

<sup>1</sup>Department of Small Animal Medicine and Surgery, College of Veterinary Medicine, The University of Georgia, Athens, Georgia

<sup>2</sup>Department of Veterinary Clinical Services, College of Veterinary Medicine, University of Minnesota, St. Paul, Minnesota

<sup>3</sup>Department of Small Animal Clinical Sciences, College of Veterinary Medicine and Biomedical Sciences, Texas A & M University, College Station, Texas

**Correspondence**

Tracy Hill, Department of Veterinary Clinical Services, College of Veterinary Medicine, The University of Minnesota, 1365 Gortner Avenue, St. Paul, MN 55108.  
 Email: tlhill@umn.edu

**Abstract**

**Background:** Nonsteroidal anti-inflammatory drugs (NSAIDs) are the most common pharmaceutical associated with gastroduodenal ulceration and perforation. The prevalence of gastrointestinal (GI) injury associated with chronic use of NSAIDs in dogs is unknown.

**Objective/Hypothesis:** To determine the prevalence of GI mucosal erosions in dogs receiving chronic treatment with NSAIDs. We hypothesized that dogs receiving NSAIDs would have more GI mucosal erosions and longer GI transit time than a control population.

**Animals:** Fourteen client-owned medium- and large-breed dogs receiving an NSAID for at least 30 days and 11 client-owned control dogs undergoing video capsule endoscopy (VCE) for evaluation of chronic GI disease.

**Methods:** Dogs were prospectively recruited after determining no clinically relevant comorbidities were present and VCE was performed. The GI transit time and the presence of mucosal lesions were recorded.

**Results:** Twelve dogs receiving NSAIDs and 11 retrospectively evaluated control dogs were included. The NSAIDs administered included carprofen (9 dogs), meloxicam (2 dogs), and firocoxib (1 dog) for a median of 6 months. Ten (83.3%; 95% confidence interval; 51.6%-97.9%) NSAID-treated dogs had GI erosions. Erosions were seen with all 3 NSAIDs in at least 1 dog. Three of 11 control dogs had gastric erosions. Dogs receiving NSAIDs had more erosions detected ( $P = .004$ ).

**Conclusions and Clinical Relevance:** Subclinical GI erosions are more common in dogs receiving chronic treatment with NSAIDs than in control dogs with chronic GI disease, suggesting that NSAIDs be used with caution, particularly in dogs with comorbidities predisposing them to GI ulceration.

**KEYWORDS**

dog, gastrointestinal, NSAID, video capsule endoscopy

**Abbreviations:** BCS, body condition score; BW, body weight; COX, cyclooxygenase; GI, gastrointestinal; GITT, gastrointestinal transit time; GTT, gastric transit time; H<sub>2</sub>, histamine 2; NSAID, nonsteroidal anti-inflammatory drug; SI, small intestine; SITT, small intestinal transit time; VCE, video capsule endoscopy.

This is an open access article under the terms of the Creative Commons Attribution-NonCommercial License, which permits use, distribution and reproduction in any medium, provided the original work is properly cited and is not used for commercial purposes.

© 2021 The Authors. *Journal of Veterinary Internal Medicine* published by Wiley Periodicals LLC, on behalf of the American College of Veterinary Internal Medicine.

## 1 | INTRODUCTION

Gastroduodenal ulceration is a well-recognized complication of nonsteroidal anti-inflammatory drug (NSAID) use,<sup>1</sup> and NSAID treatment, both with non-cyclooxygenase (COX) selective and COX-2 selective inhibitors, is the most frequently cited factor associated with gastroduodenal ulceration and perforation in dogs.<sup>2-11</sup> Most cases of NSAID-associated ulceration and perforation have been attributed to inappropriate dosing,<sup>4,12</sup> concurrent conditions (eg, hepatic disease, sepsis, neoplasia) or concurrent treatment with corticosteroids or other NSAIDs.<sup>3</sup> Gastroduodenal perforation, however, has been described with NSAIDs used at therapeutic doses.<sup>4</sup> Dogs diagnosed with spontaneous gastroduodenal ulceration or perforation associated with NSAID treatment are most often large breed dogs (average 35 kg) that are middle-aged (5-7 years), but it is unknown whether if these dogs are overrepresented in terms of receiving NSAID treatment or if they are predisposed to develop gastroduodenal erosions with NSAIDs. Death occurs as a complication of NSAID treatment in 1 per 2000 PO doses and <1 per 500 injectable doses in dogs.<sup>13</sup>

In people, the rate of gastric or duodenal erosions within the first 12 weeks of treatment with NSAIDs is 12%, with 40% of cases being asymptomatic.<sup>14</sup> The risk of severe gastrointestinal (GI) complications, including abdominal pain, GI bleeding, GI ulceration, obstruction, or perforation is 0.3% to 1%.<sup>1</sup>

The rate of subclinical gastroduodenal erosions or lesions in dogs receiving NSAIDs for clinical use is unknown. Mild to moderate punctate erosions were observed in 70% of healthy research dogs that received ketoprofen, carprofen, meloxicam, or placebo for 28 days. No differences were found between NSAID groups and the placebo group, and no baseline pretreatment endoscopies were performed, leaving open the possibility that research dogs might have had subclinical gastroduodenal erosions independent of NSAID treatment.<sup>9</sup> In a separate study using healthy research dogs, mild gastroduodenal mucosal erosions were observed in 73% of dogs after 7 days of PO NSAID administration, and dogs receiving PO aspirin experienced significantly more severe gastric erosions than did the placebo group. As in the previous study, no pretreatment endoscopies were performed.<sup>15</sup> Regardless, no dog in either study showed clinical signs related to the GI lesions. The prevalence of subclinical erosions in healthy client-owned dogs is unknown because these dogs typically do not have conventional or video capsule endoscopy (VCE) performed.

Under-recognition of adverse GI events after NSAID treatment in dogs could result in higher morbidity and mortality with chronic use.<sup>1,3</sup> Conversely, exaggerated concerns about NSAID use might result in ineffective management of pain in dogs. Establishing the prevalence of subclinical ulceration in dogs receiving chronic NSAID treatment should allow for reduction of risk in susceptible populations and ensure that dogs that would benefit from NSAIDs are not denied treatment based on concern of adverse events.

Video capsule endoscopy has been used previously to detect mucosal abnormalities (eg, frank blood, mucosal erosions, masses, parasites) in dogs with GI hemorrhage or microcytosis.<sup>16-23</sup> Gastrointestinal motility also has been assessed using VCE and

showed wide variability in gastrointestinal transit time (GITT). There is no documented relationship between gastroenteropathy and GI motility in dogs.<sup>16,18,24-26</sup> Use of NSAIDs also can cause delayed gastric emptying in dogs because of inhibition of prostaglandin production.<sup>27</sup>

We used VCE to evaluate the GI mucosa in dogs receiving chronic NSAID treatment. We hypothesized that the rate of subclinical gastroduodenal erosions would be higher and the GITT longer in dogs receiving chronic NSAID treatment as compared with a control population of dogs undergoing VCE for assessment of chronic GI signs.

## 2 | MATERIALS AND METHODS

Client-owned dogs weighing 25 to 45 kg that received NSAIDs daily for at least 30 days were eligible. Dogs were excluded if they had received acid suppressants or gastroprotectants (histamine 2 [H<sub>2</sub>] receptor antagonists, proton pump inhibitors, sucralfate, magnesium, or aluminum hydroxide) or exogenous corticosteroids within the previous 30 days. A complete clinical history including reason for NSAID treatment, type of NSAID used, and duration of treatment was obtained from the client. Physical examination, hematology, serum biochemistry, urinalysis, and postprandial bile acid concentration were performed before enrollment. Any dog with a suspicion of GI, renal, or hepatic disease based on these findings was excluded. A zinc sulfate fecal flotation was performed on every dog. The study was approved by the Clinical Research Committee of The University of Georgia College of Veterinary Medicine.

After a 16 to 24 hour fast, each study dog underwent VCE (ALICAM, Inforti Medical LLC, Redwood City, California). This 11 × 31 mm capsule was administered PO by a direct pilling technique after activating the capsule. The dog was fasted for an additional 8 hours after capsule administration. Clients monitored the feces until the capsule could be retrieved from the feces and returned for processing.

For control dogs, the previous 200 VCE studies were retrospectively evaluated for dogs that underwent VCE for assessment of chronic GI disease. These dogs were fasted for the manufacturer-recommended 16 to 24 hours before VCE. Any dog that was receiving an NSAID, a proton pump inhibitor, an H<sub>2</sub> receptor antagonist, had evidence of GI bleeding (melena, hematochezia, hematemesis), anemia, or was <10 kg was excluded, which resulted in 188 cases being excluded. One additional case was excluded because of species (wolf). Eleven cases remained for analysis.

Video capsule endoscopy images were interpreted individually by 2 trained investigators (T. Hill and M.K. Tolbert) in a blinded manner for mucosal changes in the stomach and small intestine (SI) and for assessment of gastric transit time (GTT) and small intestinal transit time (SITT). Mucosal changes recorded included estimated percentage of mucosa visualized and the presence of erosions. For each dog, the presence of an erosion was recorded along with whether the location (gastric or SI) was affected by a single erosion, few erosions (2-7), or many erosions (>8). Erosions were defined as mucosal breaks with white, yellow, or brown bases surrounded by red or pink collars or

actively hemorrhaging lesions. If both investigators observed a lesion, it was considered a definitive lesion. If only 1 of the 2 investigators observed a lesion, it was considered suspicious. The estimated percentage of mucosa that was visualized (not obscured) was graded subjectively as 0% to 25% visualized, 26% to 50% visualized, 51% to 75% visualized, and 76% to 100% visualized for both stomach and SI. The location of lesions was recorded.

### 3 | STATISTICS

Age, body weight (BW), body condition score (BCS), duration of NSAID treatment, GTT, and SITT were analyzed for normality using a Shapiro-Wilk test; the mean and SD and median and ranges were reported as appropriate. Control and NSAID-treated dogs were compared for age, BW, BCS, presence of erosions, GTT, and SITT using a *t* test or Mann-Whitney *U* test as appropriate. Proportions of the primary outcome (erosions) were described using a 95% binomial confidence interval (CI). Fisher's 2-tailed exact test was used to detect statistical differences between the 2 groups and presence of GI lesions. For purposes of comparison, suspicious erosions (detected by 1 investigator) were considered definitive in the control population group, whereas suspicious erosions were not included in the total number of dogs with erosions from the NSAID-treated group. A significance level of  $P < .05$  was used. We intended to stratify groups to compare signalment and NSAID characteristics with the presence of lesions but because of the high percentage of dogs affected, no further statistical analysis was performed.

### 4 | RESULTS

Video capsule endoscopy was performed on 14 NSAID-treated dogs and 11 control dogs. Of the NSAID-treated dogs, 1 dog experienced malfunction of the capsule, and the images could not be retrieved and the gastric mucosa of another dog was nearly completely obscured by food and gastric retention of the capsule, and no analyzable images were obtained. Twelve NSAID-treated dogs had VCE successfully completed and were included for further analysis. The median age was 9 years (range, 2-12) with mean BW of 25.7 kg (range, 20.9-45). Breeds included American Staffordshire Terrier or American Staffordshire Terrier Cross (4 dogs), Labrador Retriever or Labrador Cross (2 dogs), Newfoundland, smooth-coated Collie, German Shepherd Mix, Golden Retriever, flat-coated retriever, and Border Collie Cross (1 dog each). There were 5 neutered male and 7 spayed female dogs. Minor physical examination abnormalities were detected in 5 dogs including dental disease (3 dogs), lameness (1 dog), and a palpable tibial plateau leveling osteotomy plate (1 dog). Dogs had normal to mildly increased BCS with a median BCS of 5 (range, 4-7). Abnormal laboratory findings included mild anemia in 1 dog (hematocrit, 32.7%) and mild thrombocytopenia ( $167\,000/\mu\text{L}$ ) in another dog. Postprandial serum bile acid concentrations all were normal, and evaluation of urinalysis and fecal flotation identified no clinically relevant findings in any dog. No dog experienced adverse clinical effects directly related to NSAID treatment.

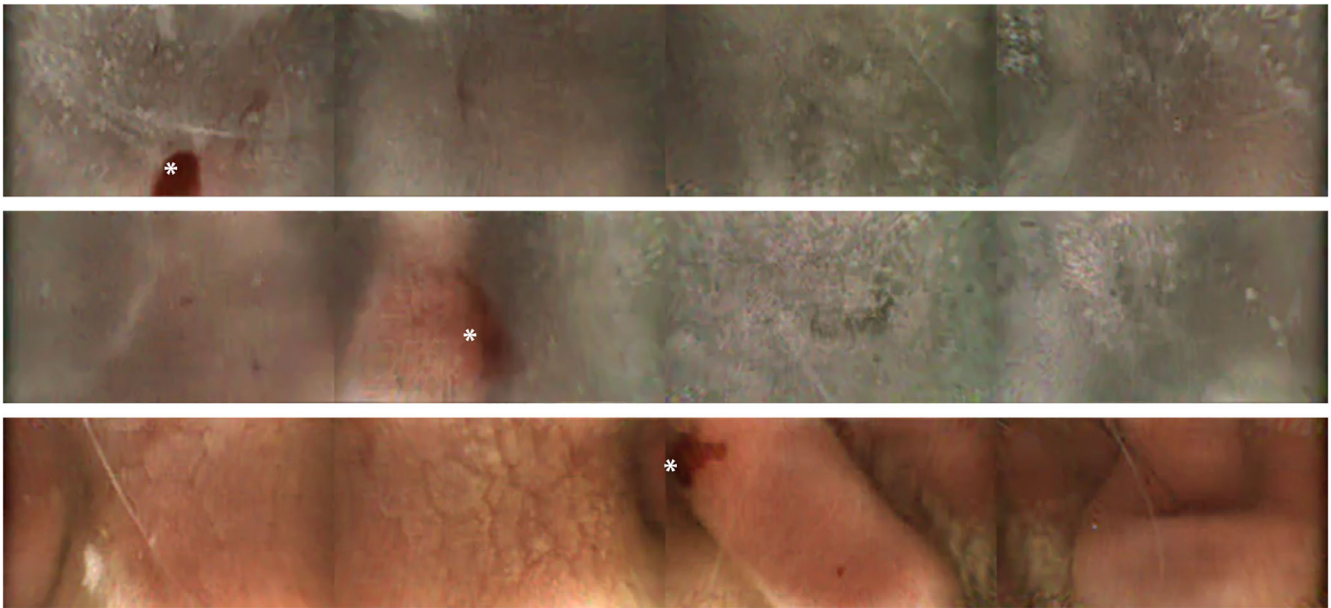
Types of NSAIDs administered included carprofen (9 dogs; average daily dose, 3.79 mg/kg), meloxicam (2 dogs; average daily dose, 0.08 mg/kg), and firocoxib (1 dog; average daily dose, 4.2 mg/kg). One dog received a slight overdose of carprofen at 2.5 mg/kg/day either once or twice daily (administered based subjectively on orthopedic clinical signs observed by the owner). Median duration of NSAID treatment was 34 months (range, 1-60). Other than monthly anthelmintic preventative medications, 3 dogs also received glucosamine, and 1 dog each was being treated with phenylpropanolamine, oclacitinib, cetirizine, diphenhydramine, fluoxetine, or gabapentin.

Gastrointestinal transit times were as follows: median, 45 minutes (range, 7-181) for GTT and 106 minutes (range, 73-317) for SITT. Gastric mucosal visualization was 76% to 100% in 2 dogs, 51% to 75% in 6 dogs, 26% to 50% in 1 dog, and 0% to 25% in 2 dogs. Small intestinal mucosal visualization was 76% to 100% in 9 dogs and 51% to 75% in 2 dogs. One dog had gastric retention, and this dog was not included in the analysis of GTT or SITT.

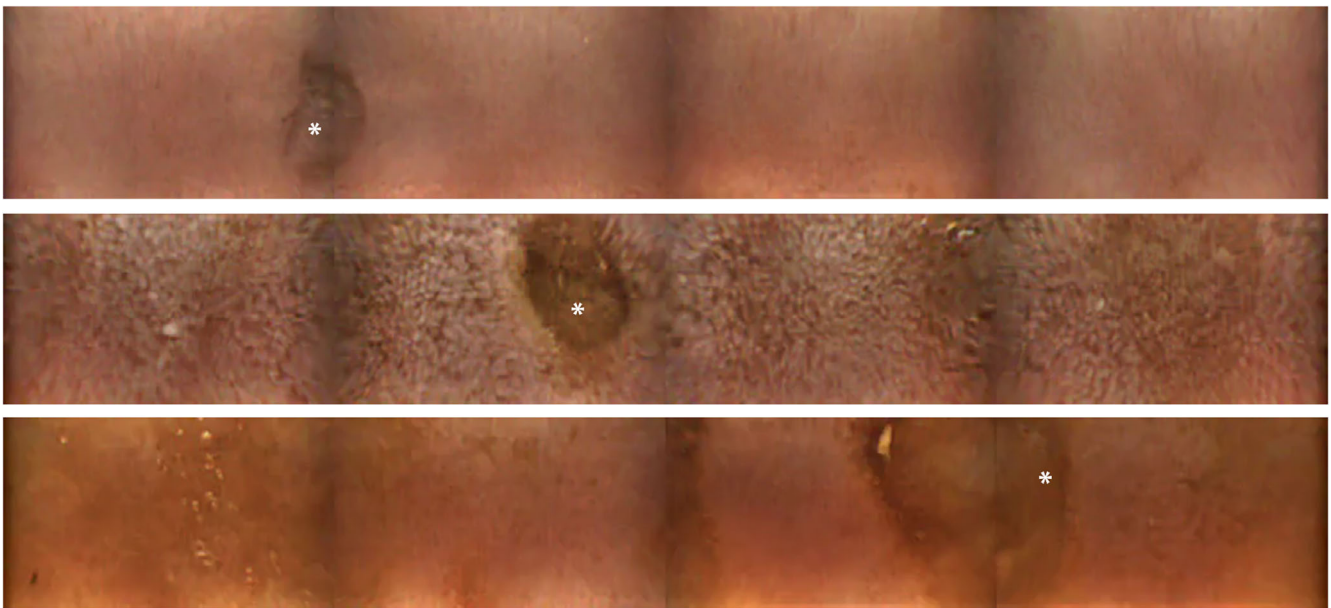
Nine of 12 dogs (75.0%; 95% CI, 42.8%-94.5%) had gastric erosions definitively observed (Figure 1). One dog had an erosion that was deemed suspicious but not definitive by both reviewers. In 2 dogs, no erosions were visualized. Of the dogs with recorded definitive erosions, 4/8 dogs had multiple (>8), 3/8 dogs had few lesions (2-7), and 2/8 dogs had 1 lesion visualized.

In the SI, 6 of 12 dogs (50.0%; 95% CI, 21.1%-78.9%) had erosions definitively visualized (Figure 2). An additional 3 dogs had suspicious erosions and 1 dog had gastric retention, so that no SI images were obtained before the capsule battery expired and the capsule passed. No erosions were observed in 2 dogs. All 6 dogs with identifiable erosions had erosions visualized in the proximal third of the SI, as did the 3 dogs with suspicious erosions, which likely corresponded to the duodenum. Five of the 6 dogs also had suspicious or confirmed erosions in the second (5 dogs) or third (2 dogs) tertile. Video capsule endoscopy cannot definitively distinguish the 3 segments of SI, but these latter lesions likely correspond to jejunum and ileum.

Overall, 10 of 12 dogs (83.3%; 95% CI, 51.6%-97.9%) had erosions in either the stomach or SI or both. One dog had no erosions visualized in the GI tract. One additional dog had a suspicious erosion in the stomach and no erosions visualized in the SI. The first dog was being treated with carprofen for 6 months, the second with meloxicam for 5 months, and both at recommended dosages. For the control dogs, the median age was 7.1 years (range, 3.1-14.3 years), median BW was 26.4 kg (range, 10-52 kg), and BCS was 4 (range, 3-9). Age, BW, and BCS were not different between control and NSAID-treated dogs. Breeds included 3 Labrador Retrievers and 1 each of: Golden Retriever, Fox Terrier cross, Catalan Sheepdog, Shetland Sheepdog, Dogo Argentino, German Shepherd Dog, mixed breed dog, and Whippet. There were 5 neutered male, 4 spayed female, and 2 intact male dogs. Dogs underwent VCE for a variety of presenting clinical signs, including vomiting, diarrhea, hypo- or anorexia, weight loss, polyphagia, regurgitation, and flatulence. Duration of clinical signs at the time of VCE was a median of 6 months (range, 1-30). Drugs being administered at the time of VCE included: maropitant (4 dogs), amoxicillin (2 dogs), probiotics (2 dogs), tylosin (2 dogs), and 1 dog each receiving enrofloxacin or clindamycin.



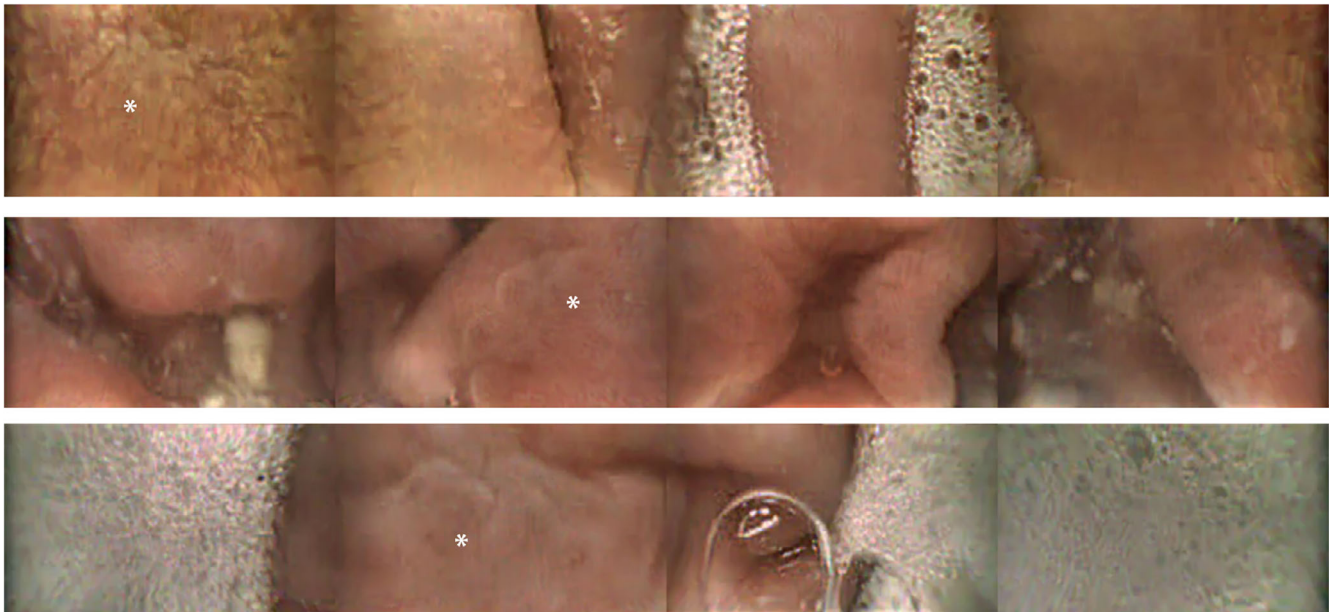
**FIGURE 1** Video capsule endoscopy (VCE) images of the stomach in 3 affected dogs. A focal gastric erosion (asterisk) is visualized in each image



**FIGURE 2** Video capsule endoscopy (VCE) images of the small intestine in 3 affected dogs. A focal intestinal erosion (asterisk) is visualized in each image

In the control dogs, 3 of 11 (27.2%; 95% CI, 6.0%-60.9%) had gastric erosions; 1 dog with many pinpoint erosions, 1 with 1 to 2 erosions, and 1 dog with 2 suspicious erosions. The dog with 1 to 2 gastric erosions had a few lesions suspicious for pinpoint erosions in the distal half of the SI. Overall, 3 dogs had suspected or identified gastric or SI erosions. Gastric mucosa visualization was estimated as 76% to 100% in 5 dogs, 51% to 100% in 4 dogs, 26% to 50% in 1 dog, and 0% to 25% in 1 dog. Small intestinal mucosal visualization was 76% to 100% in 7 dogs, 26% to 50% in 1 dog, and 0% to 25% in 1 dog. Gastric retention

occurred in 2 dogs, and 1 additional dog had only the proximal SI visualized before the battery expired (estimated 0%-25% visualized). The most common lesion detected was patchy or diffusely thickened irregular gastric mucosa (10/11 dogs), edematous villi (8 dogs), dilated lacteals (5 dogs), and hookworms (1 dog; Figure 3). Gastrointestinal transit times were as follows: median, 143 minutes (range, 24-1109) for GTT and 150 minutes (range, 86-275) for SITT. Gastric transit time for control dogs was longer than for NSAID-treated dogs ( $P = .01$ ); no difference was observed for SITT.



**FIGURE 3** Video capsule endoscopy (VCE) images of the stomach in 3 affected dogs. Focal areas of thickened irregular mucosa (asterisk) are visualized in each image

The NSAID-treated dogs were more likely to have a gastric ( $P = .02$ ) or SI ( $P = .02$ ) erosion. They were more likely to have either a gastric or an SI erosion ( $P = .004$ ). For the purposes of our analysis, a suspected erosion was considered definitive for control cases and negative for NSAID-treated dogs to minimize the risk of over-interpretation of results. Dogs receiving NSAIDs had a relative risk of 3.14 ( $P = .005$ ; 95% CI, 1.170%-8.445%) for the detection of an erosion.

## 5 | DISCUSSION

Nearly all dogs (10/12, 83.3%) receiving chronic NSAID treatment had either gastric or SI erosions or both. These dogs were chronically treated with NSAIDs in the form of carprofen, meloxicam, or firocoxib. All types of NSAIDs were associated with GI mucosal changes in at least 1 dog, which is higher than the reported incidence of subclinical GI erosions in people (12%).<sup>28</sup> Additionally, 60% of people with NSAID-induced erosions are symptomatic,<sup>1</sup> whereas none of our 12 dogs with lesions had any clinical signs noted by the owners. These dogs may have had mild signs that were undetected, but nearly all of the dogs were owned by veterinary students, technicians, or veterinarians, observers who likely were relatively attentive to their pet's clinical signs. Previously, NSAID-associated erosions have been reported in 70% to 73% of healthy research dogs<sup>9</sup> and healthy client-owned dogs<sup>15</sup> after treatment with variable types of NSAIDs, all of which also were subclinical.

A single dog had mild anemia and thrombocytopenia. This dog was included in the study because the abnormalities were mild and not expected to predispose this dog to adverse effects.

The median GTT of 36 minutes (range, 5-160) and SITT of 106 minutes (range, 59-604) in these dogs are comparable or slightly faster than previously reported, with GTT of 164 minutes (range, 40-410) and SITT of 131 minutes (range, 91-206) in 1 study,<sup>29</sup> GTT of  $79 \pm 40$  minutes and SITT of  $119 \pm 44$  minutes in a second study,<sup>30</sup> and GTT of 429 minutes (range, 306-1370) in another study,<sup>31</sup> with healthy medium-sized, unreported size, and large to giant breed dogs, respectively. In the third study, dogs were not fasted as they were in our study, and included giant breed dogs, both of which factors could have affected GITT. Despite the presence of lesions, it did not appear that the GTT or SITT were markedly prolonged. The GITT of the control dogs that received VCE for assessment of chronic GI disease was longer than that of the NSAID-treated dogs. Although NSAIDs likely induced GI erosions, they did so without altering GITT.

Gastric retention is a common complication of VCE, occurring in up to 25% of dogs with GI disease<sup>16,18,20</sup> and in 17% of dogs with intestinal parasites,<sup>20</sup> and thus it was not unexpected that 1 dog would have gastric retention. It is uncertain whether the presence of gastric erosions in this dog affected its gastric motility or if it was simply a variant of normal. In the control dogs with chronic GI signs, 2 to 3 of the dogs had gastric retention (the third dog had only its proximal duodenum imaged). This observation is more consistent with the 25% rate of gastric retention seen in dogs with GI disease. Visualization of the SI was largely excellent (76%-100%) in > 70% in both groups, except in dogs with gastric retention. Gastric mucosa visualization was good (51%-75%) or excellent (76%-100%) in > 60% of dogs. No differences in mucosal assessment were identified between the groups, making it unlikely that the control population had lesions that were inadequately visualized.

Because we elected to include client-owned dogs that had already received NSAIDs, we could not perform VCE before NSAID

treatment began. Therefore, some of the dogs may have had lesions before NSAID administration. The effect of chronic osteoarthritis (OA), and chronic administration of nutraceuticals, and certain other medications on the GI tract and the mucosa is unknown in dogs, but it is possible that underlying OA factored into the high rate of erosions and they may not have been because of the NSAIDs alone. This finding is still clinically relevant, however, because most dogs receiving chronic NSAID treatment do have concurrent OA.

Our control population included dogs that were undergoing VCE for assessment of chronic GI disease. Only 3 of these 11 dogs had erosions present (2 definitive, 1 suspicious). Dogs with chronic GI disease might be expected to have a higher rate of erosions than healthy control dogs and have been used previously as control populations for documentation of exercise-associated erosions. A previous study documented erosions in racing Alaskan sled dogs at a higher rate than in a control population, which included dogs that were undergoing gastroduodenoscopy for assessment of GI disease. In that study, erosions were detected at a higher rate in the racing dogs (48.5%) than in the control dogs with chronic GI signs (32.1%).<sup>32</sup> The rate seen in our NSAID-treated dogs (83.3%) is higher than previously reported for the racing dogs, control dogs with GI signs, and our control population of dogs undergoing VCE, suggesting that NSAIDs or NSAIDs and concurrent OA (with or without long-term use of medications or nutraceuticals) may have played a role in GI erosions in these dogs. It would be ideal to perform VCE on dogs with moderate to severe OA without concurrent NSAID treatment but these dogs benefit from pain control and withholding NSAIDs in these cases would not be feasible.

The clinical relevance of our findings is unclear, and we do not recommend withholding NSAIDs if dogs require pain control, or that all NSAIDs be administered concurrently with gastroprotectants. Lesions were subclinical in all dogs, and none were known to later develop clinical signs of ulceration. Newer NSAID-type drugs, such as grapiprant, are marketed as having a lower risk of injury. We caution against exclusively using these drugs over traditional NSAIDs based on the data provided here, because we have observed GI erosions in a dog treated with grapiprant. Although NSAIDs are the most highly cited risk factor for gastroduodenal ulceration in dogs,<sup>3,15</sup> NSAIDs are a commonly prescribed class of drugs.

Our study utilized client-owned dogs that were volunteered for the study and already receiving NSAIDs, and there was variability in diet type and frequency, living environment, comorbidities, and daily stressors that may have affected the clinical relevance of their GI lesions. Each study dog's NSAID type, dose, and duration of administration also were not standardized. Although these are potential limitations of the study, we believe this population reflects a random sample of dogs receiving chronic NSAIDs and therefore is clinically applicable.

The sensitivity and specificity of VCE to detect GI lesions is unknown. Although both endoscopists were trained and had experience reviewing VCE, erosions may have been missed either in the NSAID or in control populations. Further investigation is warranted into the incidence of ulceration with various types of NSAIDs, as well as the effect of duration of treatment on the development of lesions.

Ultimately, the presence of lesions might not have clinical relevance if none of the affected dogs ever go on to develop clinical signs of ulceration.

Overall, our study suggests that the prevalence of NSAID-induced erosions is higher than previously expected, and caution is warranted in the chronic use of NSAIDs in dogs with comorbidities that could increase the risk of erosions or ulceration.

## ACKNOWLEDGMENTS

No funding was received for this study. This work was supported by an internal departmental grant within The University of Georgia Department of Small Animal Medicine and Surgery. The authors thank Lisa Reno for her work in collecting lab samples and administration of ALICAM® capsules.

## CONFLICT OF INTEREST DECLARATION

Dr. Tracy Hill has previously acted as a consultant for Infiniti Medical LLC interpreting video capsule endoscopy images. She has not been employed or received payment in that capacity in over 3 years.

## OFF-LABEL ANTIMICROBIAL DECLARATION

Authors declare no off-label use of antimicrobials.

## INSTITUTIONAL ANIMAL CARE AND USE COMMITTEE (IACUC) OR OTHER APPROVAL DECLARATION

Approved by the University of Georgia Clinical Research Committee.

## HUMAN ETHICS APPROVAL DECLARATION

Authors declare human ethics approval was not needed for this study.

## ORCID

Tracy Hill  <https://orcid.org/0000-0001-5701-9704>

Mary Katherine Tolbert  <https://orcid.org/0000-0001-8725-9530>

## REFERENCES

- Schoenfeld P, Kimmey MB, Scheiman J, Bjorkman D, Laine L. Review article: nonsteroidal anti-inflammatory drug-associated gastrointestinal complications—guidelines for prevention and treatment. *Aliment Pharmacol Ther.* 1999;13:1273-1285.
- Hinton LE, McLoughlin MA, Johnson SE, et al. Spontaneous gastroduodenal perforation in 16 dogs and seven cats (1982-1999). *J Am Anim Hosp Assoc.* 2002;38:176-187.
- Stanton ME, Bright RM. Gastroduodenal ulceration in dogs. Retrospective study of 43 cases and literature review. *J Vet Intern Med.* 1989;3:238-244.
- Lascelles BD, Blikslager AT, Fox SM, et al. Gastrointestinal tract perforation in dogs treated with a selective cyclooxygenase-2 inhibitor: 29 cases (2002-2003). *J Am Vet Med Assoc.* 2005;227:1112-1117.
- Reed S. Nonsteroidal anti-inflammatory drug-induced duodenal ulceration and perforation in a mature rottweiler. *Can Vet J.* 2002;43:971-972.
- Gfeller RW, Sandors AD. Naproxen-associated duodenal ulcer complicated by perforation and bacteria- and barium sulfate-induced peritonitis in a dog. *J Am Vet Med Assoc.* 1991;198:644-646.
- Godshalk CP, Roush JK, Fingland RB, Sikkema D, Vorhies MW. Gastric perforation associated with administration of ibuprofen in a dog. *J Am Vet Med Assoc.* 1992;201:1734-1736.

8. Wallace MS, Zawie DA, Garvey MS. Gastric-ulceration in the dog secondary to the use of nonsteroidal antiinflammatory drugs. *J Am Anim Hosp Assoc.* 1990;26:467-472.
9. Forsyth SF, Guilford WG, Haslett SJ, Godfrey J. Endoscopy of the gastroduodenal mucosa after carprofen, meloxicam and ketoprofen administration in dogs. *J Small Anim Pract.* 1998;39:421-424.
10. Knapp DW, Richardson RC, Bottoms GD, Teclaw R, Chan TCK. Phase I trial of piroxicam in 62 dogs bearing naturally occurring tumors. *Cancer Chemother Pharmacol.* 1992;29:214-218.
11. Vonderhaar MA, Salisbury SK. Gastroduodenal ulceration associated with flunixin meglumine administration in three dogs. *J Am Vet Med Assoc.* 1993;203:92-95.
12. Gabriel SE, Jaakkimainen L, Bombardier C. Risk for serious gastrointestinal complications related to use of nonsteroidal anti-inflammatory drugs. A meta-analysis. *Ann Intern Med.* 1991;115:787-796.
13. Hunt JR, Dean RS, Davis GN, et al. An analysis of the relative frequencies of reported adverse events associated with NSAID administration in dogs and cats in the United Kingdom. *Vet J (London, England: 1997).* 2015;206:183-190.
14. Graham DY, White RH, Moreland LW, et al. Duodenal and gastric ulcer prevention with misoprostol in arthritis patients taking NSAIDs. Misoprostol Study Group. *Ann Intern Med.* 1993;119:257-262.
15. Forsyth SF, Guilford WG, Lawoko CR. Endoscopic evaluation of the gastroduodenal mucosa following non-steroidal anti-inflammatory drug administration in the dog. *N Z Vet J.* 1996;44:179-181.
16. Davignon DL, Lee AC, Johnston AN, et al. Evaluation of capsule endoscopy to detect mucosal lesions associated with gastrointestinal bleeding in dogs. *J Small Anim Pract.* 2016;57:148-158.
17. Hardy BT, Gentile-Solomon J, Solomon JA. Multiple gastric erosions diagnosed by means of capsule endoscopy in a dog. *J Am Vet Med Assoc.* 2016;249:926-930.
18. Mabry K, Hill T, Marks SL, Hardy BT. Use of video capsule endoscopy to identify gastrointestinal lesions in dogs with microcytosis or gastrointestinal hemorrhage. *J Vet Intern Med.* 2019;33:1964-1969.
19. Chang HS, Yang HT, Kim SY, et al. Assessment on gastrointestinal transit movement of capsule endoscopy in beagle dogs. *Korean J Med Phys.* 2008;19:125-130.
20. Lee ACY, Epe C, Simpson KW, Bowman DD. Utility of capsule endoscopy for evaluating anthelmintic efficacy in fully conscious dogs. *Int J Parasitol.* 2011;41:1377-1383.
21. Lee AC, Hostetler JA, Bowman DD. Assessing the speed of kill of hookworms, *Ancylostoma caninum*, by Advantage Multi (R) for Dogs using endoscopic methods. *Vet Parasitol.* 2014;204:402-406.
22. Pomrantz JS, Hardy BT, Sharma A, Solomon JA. *Feasibility of a Novel Gastrointestinal Imaging Device for Use in Dogs.* Denver, CO: ACVM; 2016.
23. Pomrantz JS, Lidbury JA, Hardy BT, et al. *Comparison of Gastric Transit Time in Healthy Dogs and Dogs with Signs of Gastric Hypomotility.* Denver, CO: ACVIM; 2016.
24. Boillat CS, Gaschen FP, Gaschen L, Stout RW, Hosgood GL. Variability associated with repeated measurements of gastrointestinal tract motility in dogs obtained by use of a wireless motility capsule system and scintigraphy. *Am J Vet Res.* 2010;71:903-908.
25. Boillat CS, Gaschen FP, Hosgood GL. Assessment of the relationship between body weight and gastrointestinal transit times measured by use of a wireless motility capsule system in dogs. *Am J Vet Res.* 2010;71:898-902.
26. Davis M, Willard M, Williamson K, et al. Temporal relationship between gastrointestinal protein loss, gastric ulceration or erosion, and strenuous exercise in racing Alaskan sled dogs. *J Vet Intern Med.* 2006;20:835-839.
27. Narita T, Okabe N, Hane M, et al. Nonsteroidal anti-inflammatory drugs induce hypermotilinemia and disturbance of interdigestive migrating contractions in instrumented dogs. *J Vet Pharmacol Ther.* 2006;29:569-577.
28. Graham DY, Agrawal NM, Roth SH. Prevention of NSAID-induced gastric ulcer with misoprostol: multicentre, double-blind, placebo-controlled trial. *Lancet.* 1988;2:1277-1280.
29. Hardy T, Solomon J, Archer TM, et al. Assessment of image quality produced by a novel GI imaging device used in client-owned dogs. *J Vet Intern Med.* 2016;30:392.
30. Rychlik A, Nowicki M, Kander M, Szveda M. The effect of macrogol administration on the quality of macroscopic images and transit time in canine capsule endoscopy. *Pol J Vet Sci.* 2014;17:673-679.
31. Balsa IM, Culp WTN, Drobotz KJ, Johnson EG, Mayhew PD, Marks SL. Effect of laparoscopic-assisted Gastropexy on gastrointestinal transit time in dogs. *J Vet Intern Med.* 2017;31:1680-1685.
32. Davis MS, Willard MD, Nelson SL, et al. Prevalence of gastric lesions in racing Alaskan sled dogs. *J Vet Intern Med.* 2003;17:311-314.

**How to cite this article:** Mabry K, Hill T, Tolbert MK. Prevalence of gastrointestinal lesions in dogs chronically treated with nonsteroidal anti-inflammatory drugs. *J Vet Intern Med.* 2021;35:853-859. <https://doi.org/10.1111/jvim.16057>