

MR urography (MRU) of non-dilated ureter with diuretic administration: Static fluid 2D FSE T2-weighted versus 3D gadolinium T1-weighted GE excretory MR

C. Roy^{a,*}, M. Ohana^a, Ph. Host^a, G. Alemann^a, A. Labani^a, A. Wattiez^b, H. Lang^c

^a Department of Radiology B, University Hospital of Strasbourg – New Civil Hospital, 1, place de l'hôpital BP 426, 67091 Strasbourg Cedex, France

^b Department of Gynecology – University Hospital of Strasbourg – Hospital Hautepierre, 1, place de l'hôpital BP 426, 67091 Strasbourg Cedex, France

^c Department of Urology, University Hospital of Strasbourg – New Civil Hospital, 1, place de l'hôpital BP 426, 67091 Strasbourg Cedex, France

Received 30 May 2014; received in revised form 4 August 2014; accepted 6 August 2014

Available online 6 September 2014

Abstract

Objective: The goal of this prospective study was to compare the efficiency of two types of MRU after diuretic administration to identify the non-dilated ureter.

Methods: MR pelvic examinations were performed in 126 patients after receiving furosemide. Each patient underwent in addition to their protocol for context, two types of MRU: 2D T2-weighted FSE (T2w-MRU) and 3D Gd T1-weighted GE (CE-MRU). Four segments were checked for each ureter.

For the first part of the analysis, readers evaluated the whole image quality using a four points subjective scale and for the second part, they were asked to score separately each ureteral segment as present or absent.

Results: 1008 ureteral segments were checked. For the image quality, readers did not find any significant difference (3.8 ± 0.5 vs 3.6 ± 0.7 , p value: 0.13) between MRU methods. The interobserver agreement was excellent with a κ correlation coefficient as high as 0.89 for T2w-MRU and 0.92 for CE-MRU, respectively.

For the detection of the segments and considering the 9 rotations for the T2W MRU, there were no statistically significant differences between the two groups.

Conclusion: T2-weighted MRU with multiple orientations and diuretic is sufficient to identify the non-dilated ureter. It offers information on ureteral peristaltism. It can be suggested that this sequence is able to detect an initial obstruction before hydronephrosis occurs.

© 2014 The Authors. Published by Elsevier Ltd. This is an open access article under the CC BY-NC-ND license (<http://creativecommons.org/licenses/by-nc-nd/3.0/>).

Keywords: Magnetic resonance imaging; Urography; Ureter; Technology; Diuretics

1. Introduction

MR urography (MRU) can be performed with two different imaging strategies: unenhanced MR urography (T2w-MRU), based on heavily T2-weighted FSE sequences and contrast-enhanced excretory MR urography (CE-MRU), which is performed with a 3D GE T1-weighted sequences following intravenous gadolinium administration.

A heavily T2-weighted sequence, utilizing the single-shot fast spin-echo (SSFSE) sequence, provides static “hydrographic” images of fluid inside the urinary tract. It is known to be mainly useful for only evaluating dilated systems [1–3] because of its inability to visualize entirely non-dilated ureters [4]. So

Abbreviations: MRU, magnetic resonance imaging; MIP, maximum intensity projection; 3D, three dimensional; 2D, two dimensional; Gd, gadolinium; FSE, fast spin echo; GE, gradient echo.

* Corresponding author. Tel.: +33 33 69 55 07 31; fax: +33 33 69 18 15.

E-mail addresses: catherine.roy@chru-strasbourg.fr (C. Roy),

mickael.ohana@chru-strasbourg.fr (M. Ohana),

philippe.host@chru-strasbourg.fr (Ph. Host),

guillaume.alemann@chru-strasbourg.fr (G. Alemann),

aissam.labani@chru-strasbourg.fr (A. Labani),

arnau.wattiez@chru-strasbourg.fr (A. Wattiez),

herve.lang@chru-strasbourg.fr (H. Lang).

<http://dx.doi.org/10.1016/j.ejro.2014.08.001>

2352-0477/© 2014 The Authors. Published by Elsevier Ltd. This is an open access article under the CC BY-NC-ND license (<http://creativecommons.org/licenses/by-nc-nd/3.0/>).

that, in routine practice, excretory CE-MRU is the technique most commonly used to evaluate the non-dilated collecting system. This later also provides rough renal functional information [5,6]. Low-dose (5–20 mg) intravenous furosemide administration has been recommended for excretory CE-MRU to improve the visualization of the non-dilated upper urinary tract [7,8].

To the best of our knowledge, no recent paper has explored the potential of the repetition of this simple breath hold T2w-MRU sequence. Our hypothesis was that by using low-dose of furosemide and additional multiple rotations around the ureter may improve the detection of the whole non-dilated ureter as well as MRU with intravenous administration of contrast medium and provides a pertinent information.

The purpose of this prospective study was to compare those two types of MRU in terms of ureteral visualization in patients with non-dilated ureters, using diuretic administration by means of a direct confrontation of each technique in the same patient. To the best of our knowledge, there is no paper in the literature concerning this evaluation.

2. Materials and methods

2.1. Patient population

This prospective, single-institution study received approval by our local ethical committee and no written informed consent was necessary. However all patients were orally informed just before the examination of this additional exploration of their urinary tract regarding to the use of a supplementary drug. During a period of 12 months from April 2012 through April 2013, among a cohort of 155 patients referred to our MR department for a pelvic with retroperitoneal MR exploration, we have selected 126 patients (extensive endometriosis: 38 patients, various pelvic carcinoma staging: 54 patients, suspicion for retroperitoneal fibrosis: 15 patients, lymph nodes or retroperitoneal masses recurrency: 19 patients) with bilateral non-dilated ureter who underwent both a 2D T2w-MRU immediately followed by an excretory 3D CE-MRU. Serum creatinine level was normal for all cases. We have excluded from the study the patients with urinary tract dilatation ($n=6$) or urinary symptoms ($n=2$), moderate renal deficiency or known allergic reaction to medication ($n=6$) and those who had undergone a previous pelvic surgery ($n=15$) (Fig. 4).

2.2. MR imaging

MR examinations were performed on a 3.0T MR unit (Achieva, Philips Medical Systems, Best, the Netherlands) by using the phased array dedicated coil for pelvic and lower abdomen exploration. The field of view was large enough to cover entirely the retroperitoneum with the exploration of the whole ureter from the uretero pelvic junction to the bladder neck.

Each patient was explored in addition to our routine protocol for the clinical context with two breath-hold MRU sequences in coronal orientation. Patients were asked to void their bladder before MR examination and received an intravenous antispasmodic medication as glucagon at the dose of 1 mg (Glucagon®

Table 1
Parameters for the two types of MRU.

	CE-MRU 3D GE T1-weighted excretory phase	T2w-MRU 2D single shot turbo spin-echo T2-weighted
TR/TE (ms)	3.6/1.6	5750/744
Flip angle	25°	90°
Matrix size (mm)	231 × 480 interpolated to 512	384 × 229 interpolated to 512
Orientation	Coronal/MIP	Coronal/rotations
Fat suppression	Yes	–
Parallel imaging acceleration factor	1	2
FOV (mm)	400/450	425/297
ETL	1	254
EPI	1	1
Excitation(s)	2	1
Slice number	80	12
Slice thickness/gap (mm)	2/1	40
Acquisition time	18 s	5 s

Lab Novo Nordisk Pharmaceuticals SA) at the beginning of the exploration. If no urinary dilatation was observed on the first non-injected routine sequences, the patient received an intravenous injection of furosemide at the dose of 20 mg (Lasilix® Lab Sanofi-Aventis) (Fig. 4). Patients were orally informed of potential side effects such as increased urination at the end of the exploration. Technologists completed a standardized adverse events form for each patient.

Five minutes later a 2D coronal single shot turbo fast SE T2-weighted static fluid MRU (T2w-MRU) was performed localized on the right and the left urinary tract with an acquisition time of 5 s. Each sequence was repeated nine times with coronal rotations and cine loop registration on each urinary tract.

At the end of this first MRU sequence, an intravenous injection of 0.2 ml/kg body weight gadolinium-based contrast medium, (Dotarem, Guerbet, Roissy CdG, France) followed by a 15 mL saline flush was performed. Five minutes later, coronal excretory phase MR urogram was obtained by means of a 3D breath-hold T1-weighted GE sequence with an acquisition time from 15 to 18 s (Table 1). Maximum-intensity-projection (MIP) images were processed from the original source images of this excretory MRU.

MRU sequences were followed by post-injected morphologic sequences if needed.

2.3. Image interpretation

The two types of MRU, including original source images and MIP reformations available from the workstation, were retrospectively reviewed. Each sequence was evaluated separately and independently by two radiologists (PhH, GA) with five and three years of experience in abdominal MR imaging, respectively. Disagreements were checked by consensus with a third radiologist (CR) with twenty years experienced in that field to find a consensus. The readings were done in several sessions

and in each session; it was given to each reviewer a random combination of isolated MRU with native images and MIP.

Readers were neither informed of the clinical context nor the radiological report done by the radiologist who was in charge of the examination.

2.4. Image analysis

Readers evaluated the whole technical image quality with the precise criterion of the presence of disturbing artifacts such as ghosting or pulsation artifacts using a four points subjective scale (1 – poor, 2 – fair, 3 – good, 4 – excellent). The distension of the ureter on CE-MRU was compared with that of obtained on T2w-MRU and quoted as higher or equal. The presence of a deviation of the pelvic ureter was registered.

Based on visual assessment, readers were asked to score four segments of each ureter. The lumbar ureter was divided in two segments: a proximal part (from the pelvic junction to the level of the lower pole of the kidney) (pL) and a distal part (from the lower pole of the kidney and iliac crest) (dL). The pelvic ureter was also checked with two segments: an upper portion from iliac vessels to mid pelvic cavity (pP) and an inferior portion from mid pelvic cavity to the bladder (dP).

Each segment was checked as present or absent.

For T2w-MRU, readers were asked to evaluate independently one rotation (chosen as strictly anteroposterior view), 6 rotations and finally the entire sequence (9 rotations).

For CE-MRU, they were asked to quote the number of entire ureter identified on MIP images.

2.5. Statistical analysis

The kappa statistic was used to measure the degree of interobserver agreement for qualitative assessment. Strength of agreement was classified as poor (κ value less than or equal to 0.20), fair (κ value between 0.21 and 0.40), moderate (κ value between 0.41 and 0.60), substantial (κ value between 0.61 and 0.80), or excellent (κ value between 0.81 and 1.0).

We used the Wilcoxon test to compare the scoring of the segmental analysis of our two MRU techniques. A *p* value less than 0.05 was considered to be statistically significant.

Statistical analysis were performed using the PC statistical software package (Biostat TGV)

3. Results

The mean patient age was 42 years old (range: 27–74 years). No patient suffered from any serious side effects of furosemide, especially no sign of allergic reaction was recorded.

A total of 252 ureters were evaluated and 1008 segments were checked.

For the assessment of image quality, readers judged both sequences good or excellent for all segments (score 3: 35/252; 51/252; score 4: 217/252; 201/252 for T2w-MRU and CE-MRU, respectively). There was not any score inferior to 3.

Comparison of the two sets of images revealed no significant difference with respect to overall image quality (3.8 ± 0.5 vs

Table 2
Results for the identification of the 4 ureteral segments with the two MRU techniques and according the number of rotations for T2w-MRU for 126 patients.

Segments	T2w-MRU 1 rotation			T2w-MRU 6 rotations			T2w-MRU 9 rotations			CE-MRU			
	Right /126	Left /126	Both /252	Right/126	Left /126	Both /252	Right/126	Left /126	Both /252	Sensitivity	Both /252	right/126	Left /126
Lumbar pL	48	52	100	98	108	206	122	126	248	98%	250	126	124
Lumbar dL	15	21	36	58	67	125	91	88	179	71%	198	100	98
Pelvic pP	10	12	22	75	50	125	99	97	196	77%	197	101	96
Pelvic dP	58	51	109	95	101	196	115	119	234	92%	235	115	120
Segments per ureter	131/504	136/504	267/1008	326/504	324/504	650/1008	427/504	430/504	857/1008	85%	880/1008	442/504	438/504
										<i>p</i> =0.37			
										<i>p</i> =0.12			
										<i>p</i> =0.12			
										<i>p</i> =0.09			
										<i>p</i> =0.12			

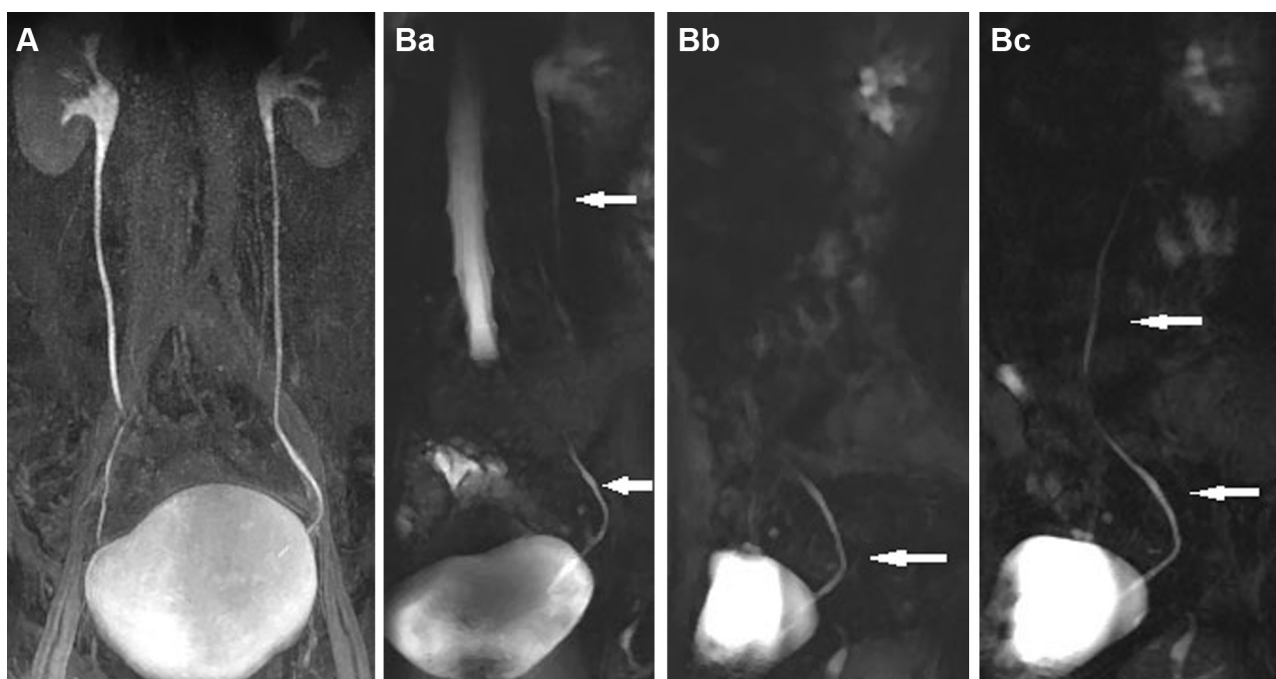


Fig. 1. MR study for retroperitoneal nodes. 24 years old, MRU normal aspect. A: CE-MRU, MIP, coronal view: entire visualization of the two ureters. B: T2w-MRU, multiple rotations: each rotation shows a segment of ureter (\uparrow). The ureter is entirely visualized at the end of the sequence. The vesicoureteral junction is also depicted. Ba: rotation number 2, Bb: rotation number 4, Bc: rotation number 7

3.6 ± 0.7 , p value: 0.13). CE-MRU was found to have a quite good opacification. Ghosting and pulsation artifacts related to ureteric peristalsis were not observed.

Statistically, the interobserver agreement was excellent with a κ correlation coefficient as high as 0.89 for T2w-MRU and 0.92 for CE-MRU, respectively.

The results for the detection of segments are presented in Table 2.

One rotation of T2w-MRU was found clearly inaccurate to assess the non-dilated ureter. Increasing the number of rotations, significantly improved the visualization of all segments.

With 9 rotations and regard to identification, there were no statistically significant differences in the visualization of the ureteral segments between the two types of MRU. The lumbar distal portion of the ureter was less pertinent for identification on T2w-MRU with a sensitivity of 71% vs 78% for CE-MRU (Table 2).

Both segments up and down the pelvic ring have less than excellent identification in both MRU techniques by comparison with two others.

A bilateral entirely opacified ureteral column until the vesicoureteral junction was found in 236/252 cases with CE-MRU, simulating a mild obstruction. On the contrary, on one rotation of T2w-MRU, it was constantly found at least one segment, indicating that the others were collapsed. The identification of the vesicoureteral junction was constantly depicted on both sequences (Fig. 1).

With regards to distension, in all cases of CE-MRU the ureter was visualized as a linear thicker structure than on T2w-MRU (Fig. 2).

Deviation of the pelvic ureter due to the genital tract was found in 118 ureteral segments equally recognized on both sequences (Fig. 3). Deviations due to ovarian cysts and follicles were easier to diagnose on T2w-MRU than on standard T2 sequence.

4. Discussion

MRU permits an evaluation of the urinary tract without the exposure to ionizing radiation and iodinated contrast medium.

T2w-MRU was the first sequence to be proposed to study excretory urinary tract. Its initial relatively low resolution has been improved by the development of heavily T2-weighted turbo spin-echo sequences such as rapid acquisition with relaxation enhancement (RARE) utilizing multiple thin-slices with MIP or a thick-slice imaging technique and half-Fourier acquisition single-shot turbo spin-echo (HASTE) sequences [9]. High-resolution thick-slice images can be achieved during a single breath-hold. However, in the literature, T2w-MRU is known to have several limitations. These include the superimposition of hyperintense extraurinary fluid collections on thick slice MRU, no functional information and undetectable small stones. The inability of T2-W MRU to fully visualize complete non-dilated ureters is cited as a major negative point in many papers [4,6,10,11]. Finally, T2w-MRU has been shown to be a rapid and non-invasive imaging technique which is useful and reliable to reveal hydronephrosis and perirenal high-intensity signals in acute urinary obstruction [12–15].

The concept of CE-MRU has been developed later. In his initial experimental study, Nolte-Ernsting et al. [16] presented the

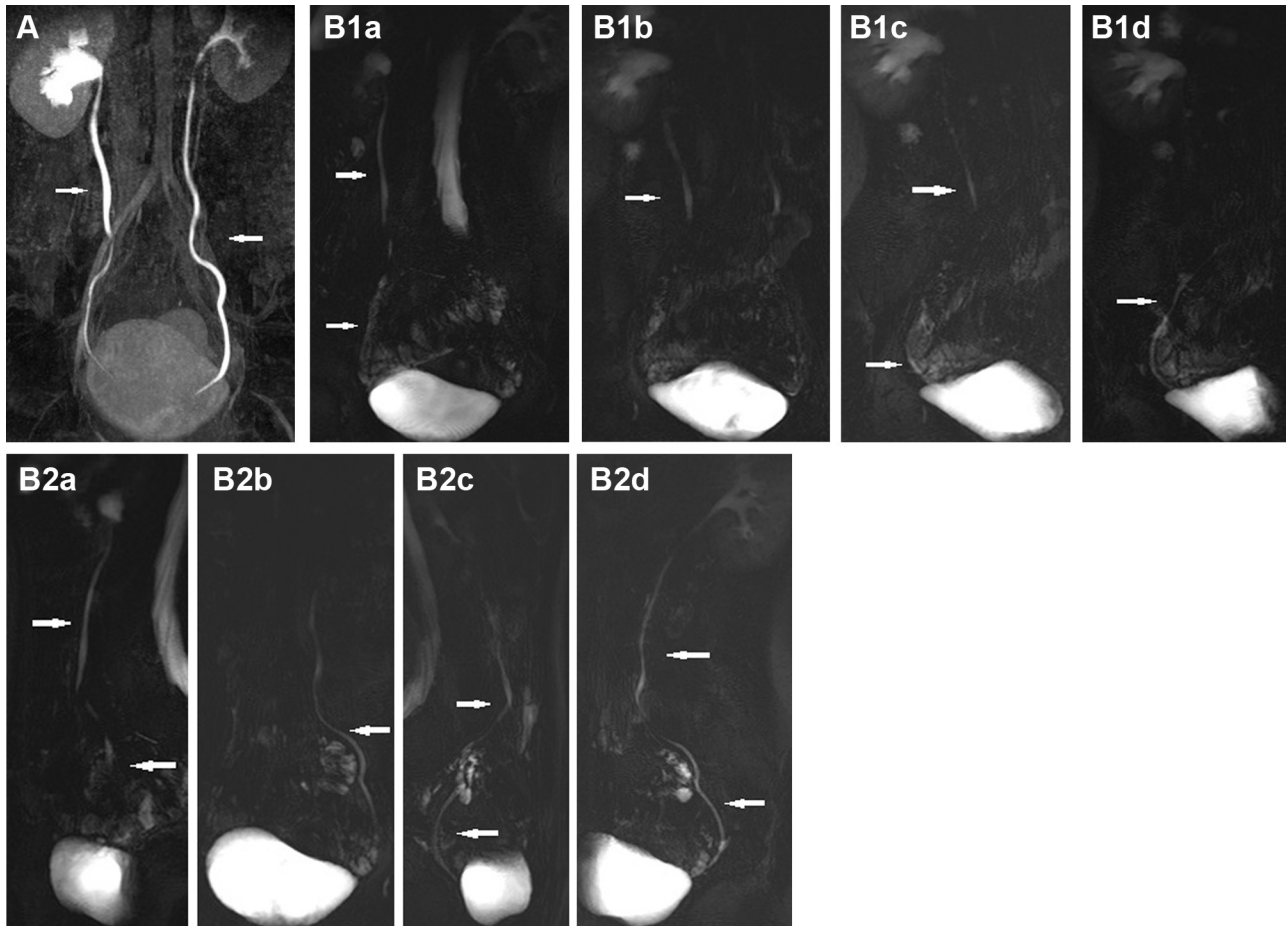


Fig. 2. MR pelvic study for suspicion of endometrial lesion. 55 years old, MRU normal aspect. A: CE-MRU, MIP, coronal view: entire visualization of the two ureters with suspicious of mild dilatation (\uparrow). Lateral deviation of the left upper part of the pelvic ureter. B: T2w-MRU, multiple rotations: each rotation shows a segment of ureter (\uparrow). The ureter is entirely visualized at the end of the sequence. B1: right side (a–d), B2: left side (a–d). Some parts are visualized on each rotation without any dilatation (\uparrow). The pelvic deviation of the left ureter is recognized on rotation B2 c and d due to the displacement by small bowel loop.

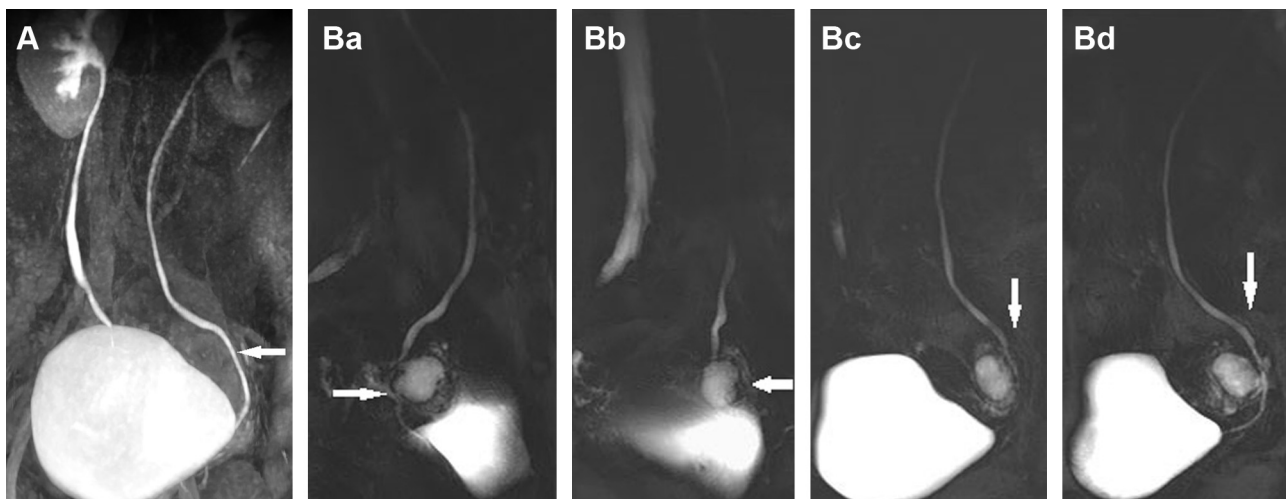


Fig. 3. MR pelvic study for survey of pelvic pain, 35 years old-MRU normal aspect. A: CE-MRU, MIP, oblique view: entire visualization of the two ureters with suspicious of mild dilatation (\uparrow). B: T2w-MRU, multiple rotations on left side (a–d): a small ovarian cyst is clearly identified (\uparrow) with a constant visualization of the ureter above the ovary.

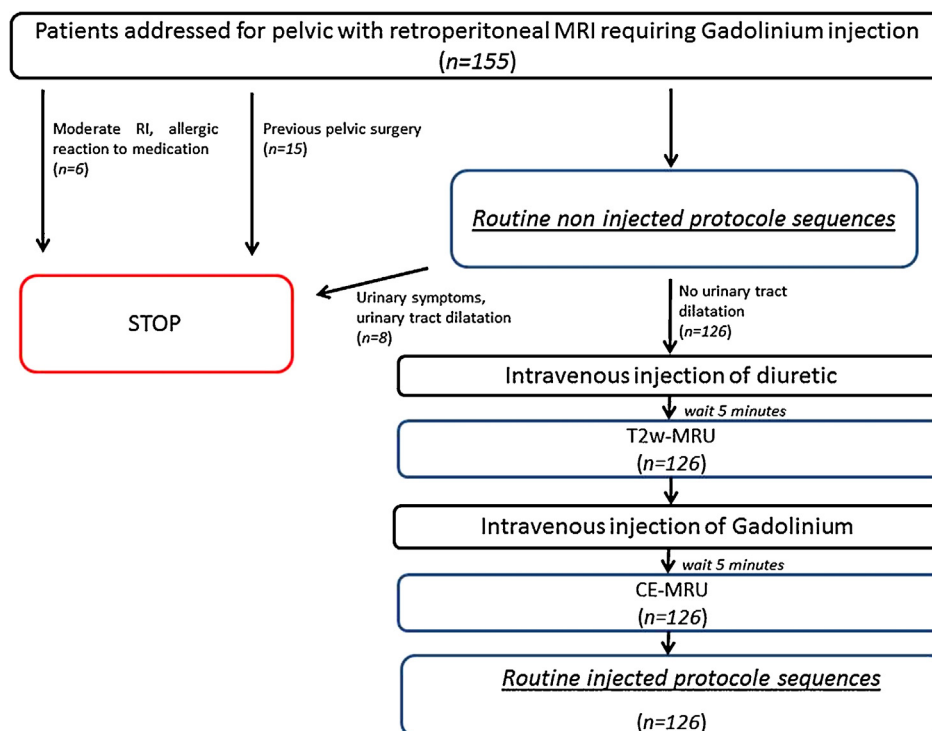


Fig. 4. Design of the study protocol.

advantages of this imaging technique in retrieving high-spatial-resolution images in non-obstructed urinary tracts. The use of a paramagnetic contrast agent permits the evaluation of renal excretory function and better visualization of the non-dilated urinary tract. Several papers [5,6,8,17] have advocated the need for a diuretic to optimize the endoluminal concentration of gadolinium and to produce accelerated distention. These authors stated that furosemide initially induces an increase in urine volume resulting in mild distention of the urinary tract, and then there is a dilution effect on the excreted gadolinium. The increased urine flow leads to a rapid and uniform distribution of gadolinium. The fast 3D GE T1-weighted sequence allows a reduction of motion artifacts [6,11].

The limitation of CE-MRU is for cases with delayed excretion due to severe obstruction, the long duration of examination for revealing the underlying abnormality increasing patient and personnel inconvenience [12,18].

As several previous papers have shown the superiority of enhanced over unenhanced imaging, CE-MRU is becoming in clinical routine practice the technique most commonly used to evaluate the non-dilated collecting system.

To our knowledge, in the previous recent literature in adult, there are no clinical studies comparing those two MRU techniques in the same patient [19].

Additionally, our evaluation has been focused on the non-dilated ureter, which is considered as being the most difficult task to obtain a visualization of all segments. As the use of low-dose (5–20 mg) intravenous furosemide administration is essential to perform CT Urography; we have also used this medication at the dose of 20 mg to adequately distend the non-dilated ureter [20].

No allergic reaction to furosemide was reported by any of our patients. In addition, it causes no real additional cost as it has a very low price.

This T2w-MRU sequence, with its short acquisition time, permits repeated series of breath-hold images in several coronal oblique orientations, thus providing obvious improvement to the use of this sequence previously described by other investigators. The whole non-dilated ureteral tract was visualized with 9 rotations. Our results attest that furosemide alone is sufficient to distend and visualize all parts. In identifying ureteral segments our results with T2w-MRU were quite similar to those of CE-MRU, except for the lower part of abdominal ureter. Image quality was excellent in all patients, and, unlike other investigators, we never have difficulty in removing superimposed fluid-filled bowel loops by changing the orientation by rotations.

A potential advantage of T2w-MRU over CE-MRU is that it can reveal an ovarian cyst or follicles which cause a deviation of the pelvic ureter. Another advantage might be the evaluation of an inflammatory process, due to the superiority of T2-weighted sequences in revealing edema and a small amount of ascites. The ability to identify one or two different segment by rotation is an indicator for normal contractions of some parts of the ureter. This visualization of the peristalsis is a good indicator to affirm that there is no ureteral repercussion for instance of a pelvic mass. In contrary when using CE-MRU, we have commonly found the entire column simulation mild obstruction. The size of ureter on CE-MRU was larger than on T2w-MRU with the same dose of diuretic. We suggest that the contrast medium itself is a significant factor to distend the ureter and produces rapidly an over distended bladder with a risk of false positive diagnosis of mild obstruction. We could not attribute this aspect to our protocol

firstly because patients were asked to void their bladder just before the beginning of the MR examination, secondly because the two sequences were performed without any supplementary delay between them (5 min to obtain the excretory phase after gadolinium administration).

In addition, T2w-MRU has the advantage of obtaining high quality images in a few seconds, without need for multiplanar and MIP reconstructions in the contrary of CE-MRU. As breath-hold T2w-MRU with intravenous diuretic and multiple rotations is sufficient to produce a qualitative study of non-dilated ureter with identification of the peristaltism, we can speculate that it could be an adequate sequence to detect an initial ureteral involvement before hydronephrosis occurs. The identification of the same missing segment on all rotations with a persistent non-dilated column above could reflect an abnormal peristaltism indicating a thorough analysis of this localization. This can be potentially very useful in the cases of extrinsic ureteral involvement such as in endometriosis which is progressive and clinically silent or can be confuse with other symptoms of the disease [21]. The identification of the same segment on all rotations can be a clue for this initial diagnosis, before the classical appearance of persistent column with gradual tapering or filling defect at the level of obstruction. However, it needs further investigation to prove that T2-MRU can detect initial obstruction, prior to clinical presentation of hydronephrosis. It could also be used to evaluate potential renal donors or in patients unable to receive gadolinium [22].

Even if our material has an important number of cases, this study has some limitations. First, there is no data regarding the relative performance of the techniques in a clinical context, but we would like to focus on the ability of T2w-MRU to visualize the entire ureter. Second, even if our field of view was large enough to obtain an evaluation of the whole ureter it does not permit a constant evaluation of the renal pelvic cavities, especially for our tallest patients. However a precise caliceal anatomy or pathology was not the purpose of our MR examinations.

Of course, equally to CE-MRU, the major drawback of T2w-MRU remains its poor sensitivity in detecting calcifications.

5. Conclusion

The T2w-MRU sequence performed with multiple coronal orientations and diuretic administration is sufficient to identify entirely the non-dilated ureter. It offers information on ureteral contractions and might be able to detect initial obstruction. Our series was large enough to suggest that pelvic MR imaging combined with T2w-MRU allows a complete work-up in a single imaging evaluation, especially if gadolinium injection is not necessary or contraindicated.

Conflicts of interest

The authors confirm that there are no known conflicts of interest associated with this publication and there has been no significant financial support for this work that could have influenced its outcome.

Ethical approval

The authors confirm that any aspect of the work covered in this manuscript that has involved human patients has been conducted with the ethical approval of all relevant bodies and that such approvals are acknowledged within the manuscript.

References

- [1] Aerts P, Van Hoe L, Bosmans H, Oyen R, Marchal G, Baert AL. Technical note: breath-hold MR urography using the HASTE technique. *Am J Roentgenol* 1996;166:543–5.
- [2] Regan F, Bohlman ME, Khazan R, Rodriguez R, Schultze-Haakh H. MR urography using HASTE imaging in the assessment of ureteric obstruction. *Am J Roentgenol* 1996;167:1115–20.
- [3] Roy C, Saussine C, Guth S, Horviller S, Tuchmann C, Vasilescu C, et al. MR urography in the evaluation of urinary tract obstruction. *Abdom Imaging* 1998;23:27–34.
- [4] Hughes J, Jan W, Goodie J, Lund R, Rankin S. MR urography: evaluation of different techniques in non-dilated tracts. *Clin Radiol* 2002;57:989–94.
- [5] Rothpearl A, Frager D, Subramanian A, Bashist B, Baer J, Kay C, et al. MR urography: technique and application. *Radiology* 1995;194:125–30.
- [6] Leyendecker JR, Gianini JW. Magnetic resonance urography. *Abdom Imaging* 2009;34:527–40.
- [7] Nolte-Ernsting CC, Bucker A, Adam GB, Neuerburg JM, Jung P, Hunter DW, et al. Gadolinium-enhanced excretory MR urography after low-dose diuretic injection: comparison with conventional excretory urography. *Radiology* 1998;209:147–57.
- [8] Szopínska K, Szopínska M, Borówka A, Jakubowski W. Magnetic resonance urography: initial experience of a low-dose Gd-DTPA-enhanced technique. *Eur Radiol* 2000;10:1158–64.
- [9] Tang Y, Yamashita Y, Namimoto T, Abe Y, Nishiharu T, Sumi S, et al. The value of MR urography that uses HASTE sequences to reveal urinary tract disorders. *Am J Roentgenol* 1996;167:1497–502.
- [10] Nolte-Ernsting CCA, Adam GB, Gunther RW. MR urography: examination techniques and clinical applications. *Eur Radiol* 2001;11:355–72.
- [11] Blandino A, Gaeta M, Minutoli F, Salamone T, Magno C, Scribano E, et al. MR urography of the ureter. *Am J Roentgenol* 2002;179:1307–14.
- [12] Muthusami P, Bhuvaneshwari V, Elangovan S, Dorairajan LN, Ramesh A. The role of static magnetic resonance urography in the evaluation of obstructive uropathy. *Urology* 2013;81:623–7.
- [13] Semins MJ, Feng Z, Trock B, Bohlman M, Hosek W, Matlaga BR. Evaluation of acute renal colic: a comparison of non-contrast CT versus 3-T non-contrast HASTE MR urography. *Urolithiasis* 2013;41:43–6.
- [14] Mullins JK, Semins MJ, Hyams ES, Bohlman ME, Matlaga BR. Half Fourier single-shot turbo spin-echo magnetic resonance urography for the evaluation of suspected renal colic in pregnancy. *Urology* 2012;79:1252–5.
- [15] Kalb B, Sharma P, Salman K, Ogan K, Pattaras JG, Martin DR. Acute abdominal pain: is there a potential role for MRI in the setting of the emergency department in a patient with renal calculi? *J Magn Reson Imaging* 2010;32:1012–23.
- [16] Nolte-Ernsting C, Adam G, Bucker A. Contrast enhanced magnetic resonance urography: first experimental results with a polymeric gadolinium blood pool agent. *Invest Radiol* 1997;32:418–23.
- [17] Ergen FB, Hussain HK, Carlos RC, Timothy D, Johnson TD, Adusumilli S, et al. 3D excretory MR urography: improved image quality with intravenous saline and diuretic administration. *J Magn Reson Imaging* 2007;25:783–9.
- [18] Sudah M, Vanninen R, Partanen K, Heino A, Vainio P, Ala-Opas M. MR urography in evaluation of acute flank pain: T2-weighted sequences and gadolinium-enhanced three-dimensional FLASH compared with urography. *Am J Roentgenol* 2001;176:105–12.
- [19] Tsubota M, Takahara T, Nitatori T, Hachiya J. Utility of cine MR urography of the urinary tract and comparison with static MR urography. *Radiat Med* 2004;22:212–7.

- [20] Roy C, Jeantroux J, Irani FG, Sauer B, Lang H, Saussine Ch. Accuracy of intermediate dose of furosemide injection to improve multidetector row CT urography. *Eur J Radiol* 2008;66:253–61.
- [21] Seracchioli R, Mabrouk M, Manuzzi L, Guerrini M, Villa G, Montanari G, et al. Importance of retroperitoneal ureteric evaluation in cases of deep infiltrating endometriosis. *J Minim Invasive Gynecol* 2008;15:435–9.
- [22] Hagspiel KD, Butty S, Nandalur KR, Bissonette EA, Shih MC, Leung DA, et al. Magnetic resonance urography for the assessment of potential renal donors: comparison of the RARE technique with a low-dose gadolinium-enhanced magnetic resonance urography technique in the absence of pharmacological and mechanical intervention. *Eur Radiol* 2005;15:2230–7.