

Case Report

Pulmonary Tumor Thrombotic Microangiopathy in a Patient with Rapid Progressive Triple-Negative Breast Cancer

Fiona Rudolf^a Albert Baschong^b Deniz Bilecen^c Nicola Aceto^d
Marcus Vetter^{a, e}

^aUniversity Clinic of Medicine, Cantonal Hospital Basel-Land, Liestal, Switzerland; ^bInstitute of Pathology, Cantonal Hospital Basel-Land, Liestal, Switzerland; ^cDepartment of Radiology, Cantonal Hospital Basel-Land, Liestal, Switzerland; ^dDepartment of Biology, Institute of Molecular Health Sciences, Swiss Federal Institute of Technology (ETH) Zurich, Zurich, Switzerland; ^eCenter for Oncology and Haematology, Cancer Center, Cantonal Hospital Basel-Land, Liestal, Switzerland

Keywords

Pulmonary tumor thrombotic microangiopathy · Pulmonary embolism · Triple-negative breast cancer · Circulating tumor cells and clusters

Abstract

Introduction: Pulmonary tumor thrombotic microangiopathy (PTTM) is a rare complication of metastatic carcinoma, which occurs in patients with pulmonary arterial hypertension, and is mostly fatal. Circulating tumor cell clusters have been recognized as critical factors during breast cancer progression. **Case Presentation:** An 80-year-old woman with triple-negative breast cancer was admitted to our hospital with progressive dyspnea and lower back pain. Breast cancer treatment included mastectomy, neoadjuvant and adjuvant chemotherapy as well as adjuvant radiotherapy, receiving her last cycle of radiotherapy 8 days before death. At admission, D-dimers were strongly elevated and platelets were low. NT-pro-BNP was moderately elevated. A CT scan of the chest did not show pulmonary embolism but revealed interlobular septal thickening, centrilobular consolidation, and distension of the pulmonary arteries. Moreover, new skeletal and most likely lymphatic metastasis was described. Treatment with oxygen and oral glucocorticoids was initiated, assuming radiotherapy-induced pneumonitis. Due to low expression of PD-L1 and her markedly bad performance status, tumor-specific therapy was not possible, and the treatment regimen was changed to best supportive care. The patient died 8 days after admission. Autopsy revealed numerous events consistent with tumor emboli in the pulmonary vessels, suggesting PTTM. **Conclusion:** PTTM is a rare and mostly fatal complication

Correspondence to:
Fiona Rudolf, fiona.rudolf@ksbl.ch

in malignant breast cancer. As an early detection is difficult, further investigation is needed. Circulating tumor cluster cells may be one way to detect PTTM early and improve patients' survival.

© 2024 The Author(s).

Published by S. Karger AG, Basel

Introduction

Triple-negative breast cancer is a type of breast cancer that does not express the estrogen receptor and progesterone receptor and lacks gene amplification of the epidermal growth factor 2 (HER2). The standard treatment for triple-negative breast cancer is surgery, followed by chemotherapy and/or radiation therapy. Newer therapy regimens include immunotherapy. The mortality rate from triple-negative breast cancer has been declining over the past few decades [1]. One end-stage manifestation of malignancies is a pulmonary tumor embolism. This is a clot, containing embolized tumor cells, that originates in a tumor and lodges in the lungs. They are considered to be relatively rare, being detected in about 5% of breast cancer patients [2].

Activation of the coagulation system on the surface of the pulmonary embolic tumor clot and intimal proliferation is a syndrome called pulmonary tumor thrombotic microangiopathy (PTTM), which is a rare and severe complication and can lead to pulmonary hypertensive arteriopathy, first described in 1990 by von Herbay et al. [3, 4]. Typical symptoms include cough, dyspnea, and other signs of right heart failure [5, 6]. Antemortem diagnosis is difficult due to nonspecific symptoms and lack of clear radiological findings. Treatment options for a pulmonary tumor embolism and PTTM, respectively, consist of treatment of the primary tumor; further supportive measures are application of oxygen and intravenous glucocorticoids. The role of anticoagulants and thrombolytic therapy is not clear in this context. There is no certain way to prevent a pulmonary tumor embolism, but early detection and treatment of breast cancer may help reduce the risk [7]. Detection of circulating tumor cells (CTCs) and CTC clusters is a newer method for cancer monitoring [8], and an association between the presence of CTC clusters and microembolism has been found [9].

We present a case of PTTM in the setting of triple-negative breast cancer treated at the Cantonal Hospital of Basel-Land, a secondary care hospital with approximately 300 beds in Northwestern Switzerland. With this case report, we would like to recall this rare diagnosis and present newer diagnostic possibilities using detection of CTCs. The CARE Checklist has been completed by the authors for this case report, attached as supplementary material (for all online suppl. material, see <https://doi.org/10.1159/000535873>).

Case Presentation

An 80-year-old woman was admitted to the emergency department of our hospital with dyspnea and without other respiratory symptoms or fever. She had back pain, which started 1 week before admission, radiating in the right knee. She had similar complaints a year before, due to a herniated disc. The patient's past medical history included triple-negative, node-positive cancer of the right breast (cT3 cN1 cM0 G2, estrogen receptor- and progesterone receptor-negative, HER2-negative, PD-L1-negative, BRCA-negative) diagnosed 7 months earlier. After eleven cycles of chemotherapy with paclitaxel and carboplatin, a mastectomy was performed. Subsequently, she received adjuvant chemotherapy with capecitabine and percutaneous radiotherapy of the right breast inclusive of axillary, paraclavicular and

parasternal lymphatic drainage. When radiotherapy was completed, she had shortness of breath on light exertion. At admission, tachypnea was present with a respiratory rate of 24 breaths per minute and an oxygenation saturation of 89% breathing ambient air. The heart rate was 78 beats per minute, and blood pressure 160/76 mm Hg. The hemoglobin level was 11.2 g/dL, and the platelet count was 68,000/mm³. The white blood cell count was 7,400/mm³, with 79.6% neutrophils. Serum C-reactive protein was elevated (80 mg/L), and the sodium level was decreased (125 mmol/L), diagnosed as syndrome of inadequate antidiuretic hormone secretion. A pronounced D-dimer elevation (55 µg/mL) was also detected. The patient's characteristics are summarized in Table 1.

A CT scan with pulmonary embolism detection program of the chest revealed smooth interlobular septal thickening with centrilobular consolidation and pleural effusions, as shown in Figure 1. Angiography of the greater pulmonary arteries was negative for pulmonary embolism, and there were no signs of acute right heart failure, but signs of chronic pulmonary arterial hypertension were evident. Additionally, progressive mediastinal lymphadenopathy and right mammary soft tissue thickening, highly suspicious for a locoregional recurrence of the breast cancer, were detected. Further, the CT scan showed multiple metastases and suspect sclerotic lesions in the thoracic spine.

Advanced tumor progression was suspected, but neither chemotherapy (due to the poor condition [ECOG 3] and low platelets) nor immunotherapy (due to low PD-L1 expression in a previous biopsy) nor an antibody-drug conjugate (due to hematotoxicity) was a causative treatment option. Symptomatic treatment for the respiratory distress consisted of oxygen, inhalation therapy with anticholinergic and beta-agonist bronchodilators, as well as oral corticosteroids. A follow-up CT scan of the chest 7 days later showed regressive pulmonary congestion. The platelets continued to decrease with a count of 22,000/mm³ 7 days after admission. The patient's condition massively deteriorated under the initiated therapy, and finally, end-of-life-care was initiated, given a situation with rapidly progressive carcinoma. The patient died 8 days after admission.

An autopsy was then performed, revealing numerous tumor embolisms in the small- and medium-sized pulmonary vessels, partly with associated thrombi indicating PTTM (Fig. 2). In addition, advanced metastatic disease with manifestations in the liver, non-regional lymph nodes, visceral pleura, all vertebral bodies, both suprarenal glands, and the mucosa of the stomach was found. The histomorphology was consistent with the pre-diagnosed triple-negative breast cancer.

Discussion

Diagnosis of PTTM is difficult and mainly postmortem. Most cases are described as gastric carcinoma, followed by breast carcinoma and lung carcinoma; histologically, mostly adenocarcinoma [10].

PTTM is characterized by an embolization of the pulmonary vasculature through CTCs [3, 10]. Histologically, fibrocellular intimal proliferation of small pulmonary vessels can be seen. This eventually can lead to stenosis and occlusion of the pulmonary vessels through the tumor cells themselves and through local release of tissue factors, leading to thrombosis due to activation of the coagulation system [5, 11, 12]. CTCs and CTC clusters are associated with severe outcome with rapid progression and early death in patients with metastatic breast cancer [13]. Recently, Gkountela et al. [14] demonstrated that the ability of CTCs to form clusters has been linked to increased metastatic potential. Furthermore, there is an association between CTCs, circulating tumor microemboli, and intravascular coagulation activation in progressive breast cancer [9, 12]. In this patient, detection of CTCs and CTC clusters was not performed, but retrospectively, it might have been a relevant additional diagnostic test.

Table 1. Patients characteristics

Characteristics	
Demographic	
Gender	Female
Age, years	81
Laboratory parameter	
Leucocytes count, /mm ³	7,400 (3,600–10,500)
Platelet count, /mm ³	68,000 (150,000–370,000)
Hemoglobin, g/L	112 (118–158)
D-dimers, µg/mL	55 (<0.5)
LDH, U/L	Not determined
CT scan of the chest	
Lung	Septal thickening, pleural effusions, signs of pulmonary hypertension
Skeleton	Multiple bone metastases in the spinal column
Others	Progressive mediastinal lymphadenopathy and right mammary soft tissue thickening. Plum left adrenal gland
LDH, lactate dehydrogenase.	

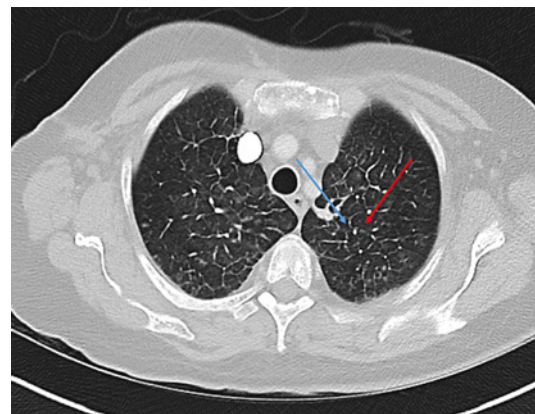


Fig. 1. CT scan of the chest demonstrating (blue) thickened interlobular septa, (red) centrilobular faint compression.

An increase in lactate dehydrogenase, thrombocytopenia, and elevated D-dimers is a common constellation in PTTM. Low platelets and high D-dimers were both detected in our patient. Lactate dehydrogenase could not be determined in our case due to hemolysis. Although there is no pathognomonic imaging, ground glass opacities, septal thickening, and lymphadenopathy are radiological findings of PTTM that can occur in a CT scan of the chest. In addition, the source of the primary malignancy may influence radiological findings [10]. Clinical presentation, laboratory results, and CT findings of this patient are thus consistent with PTTM.

Patients' critical condition, in particular at the PTTM onset, and diagnostic difficulties make it complex to initiate adequate treatment, which is nota bene only based on case reports. Although there is no standard treatment regimen available, therapeutic options include pulmonary vasodilators, chemotherapy, and anti-inflammatory/antiproliferative approaches with the aim to decrease pulmonary hypertension and tumor load [3, 15]. In our case, the patient's poor condition only allowed anti-inflammatory and supportive measures.

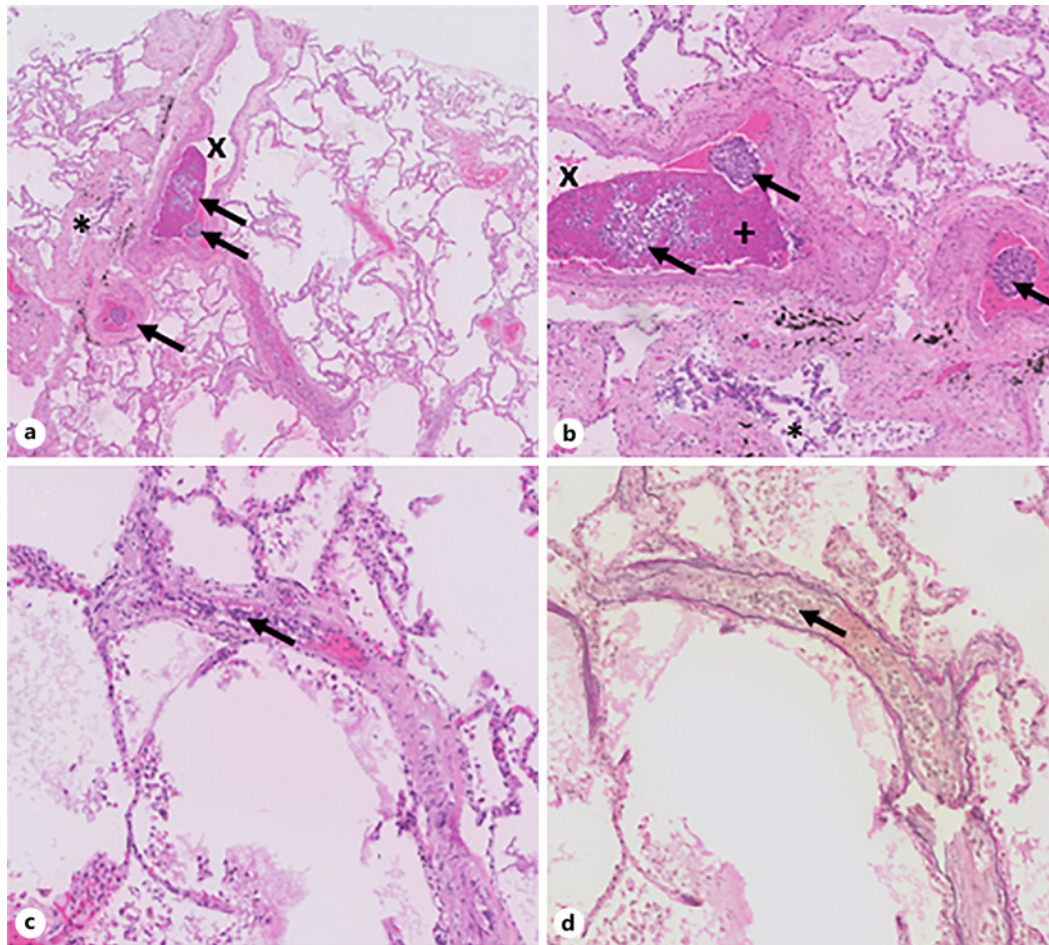


Fig. 2. Histology of pulmonary vessels. **a, b** Multiple tumor cells within the lumen of pulmonary vessels and thrombus formation (H and E, $\times 100$). **c, d** High-power field of an obstructed small pulmonary vessel (H and E, EVG $\times 400$). Legend: black arrows point at embolized tumor cell clusters; x: artery, +: clot, *: bronchioles.

This case shows a typical course of PTTM with unclear diagnosis antemortem and rapidly worsening clinical condition. Further investigation in pathophysiological pathways, diagnostic and therapeutic features are desirable for a better assessment and outcome in these patients.

Statement of Ethics

Written informed consent was obtained from the patient for the publication of this case report including any accompanying images. The authors have no ethical conflicts to disclose. The study was conducted according to the guidelines of the Declaration of Helsinki. Ethical approval is not required for this study in accordance with local guidelines.

Conflict of Interest Statement

Related to the present work, the authors disclose no potential conflicts of interest. The authors declare that they have no competing interests.

Funding Sources

No funding was received.

Author Contributions

F.R. and M.V. wrote the manuscript. A.B. contributed to the histological sections. D.B. contributed to the radiological sections. N.A. critically reviewed the report. All the authors read and approved the final manuscript.

Data Availability Statement

All data generated or analyzed during this study are included in this article. Further inquiries can be directed to the corresponding author.

References

- 1 Siegel RL, Miller KD, Fuchs HE, Jemal A. Cancer statistics, 2022. *CA Cancer J Clin*. 2022;72(1):7–33.
- 2 Khan UT, Walker AJ, Baig S, Card TR, Kirwan CC, Grainge MJ. Venous thromboembolism and mortality in breast cancer: cohort study with systematic review and meta-analysis. *BMC Cancer*. 2017;17(1):747–13.
- 3 Price LC, Seckl MJ, Dorfmueller P, Wort SJ. Tumoral pulmonary hypertension. *Eur Respir Rev*. 2019;28(151):180065.
- 4 von Herbay A, Illes A, Waldherr R, Otto HF. Pulmonary tumor thrombotic microangiopathy with pulmonary hypertension. *Cancer*. 1990;66(3):587–92.
- 5 Kato A, Kato H, Komori S, Nakano S, Murase T, Nakamura M, et al. Pulmonary tumor thrombotic microangiopathy secondary to extramammary paget's disease: an autopsy case report and literature review. *Case Rep Oncol*. 2021;14(3):1328–32.
- 6 Neverauskaite-Pilipioniene G, Cesas K, Pranys D, Miliauskas S, Padervinskiene L, Laukaitiene J, et al. Fatal pulmonary tumour thrombotic microangiopathy in patient with ovarian adenocarcinoma: review and a case report. *BMC Cardiovasc Disord*. 2022;22(1):1–7.
- 7 Ren W, Chen M, Qiao Y, Zhao F. Response to comment on: "Global guidelines for breast cancer screening: a systematic review". *Breast*. 2023;67:131.
- 8 Ring A, Nguyen-Sträuli BD, Wicki A, Aceto N. Biology, vulnerabilities and clinical applications of circulating tumour cells. *Nat Rev Cancer*. 2023;23(2):95–111.
- 9 Tao J, Zhu L, Yakoub M, Reißfelder C, Loges S, Schölich S. Cell-cell interactions drive metastasis of circulating tumor microemboli. *Cancer Res*. 2022;82(15):2661–71.
- 10 Godbole RH, Saggarr R, Kamangar N. Pulmonary tumor thrombotic microangiopathy: a systematic review. *Pulm Circ*. 2019;9(2):2045894019851000.
- 11 Fujikawa H, Wakabayashi T. Pulmonary tumour thrombotic microangiopathy. *Cmaj*. 2020;192(10):E256.
- 12 Dirix LY, Oeyen S, Buys A, Liégeois V, Prové A, Van De Mooter T, et al. Coagulation/fibrinolysis and circulating tumor cells in patients with advanced breast cancer. *Breast Cancer Res Treat*. 2022;192(3):583–91.
- 13 Radovich M, Jiang G, Hancock BA, Chitambar C, Nanda R, Falkson C, et al. Association of circulating tumor DNA and circulating tumor cells after neoadjuvant chemotherapy with disease recurrence in patients with triple-negative breast cancer: preplanned secondary analysis of the BRE12-158 randomized clinical trial. *JAMA Oncol*. 2020;6(9):1410–5.
- 14 Gkountela S, Castro-Giner F, Szczerba BM, Vetter M, Landin J, Scherrer R, et al. Circulating tumor cell clustering shapes DNA methylation to enable metastasis seeding. *Cell*. 2019;176(1–2):98–112.e14.
- 15 Yoshikawa S, Hara T, Suzuki M, Fujioka M, Taniguchi Y, Hirata KI. Imatinib dramatically improved pulmonary hypertension caused by pulmonary tumor thrombotic microangiopathy (PTTM) associated with metastatic breast cancer. *Int Heart J*. 2020;61(3):624–8.