

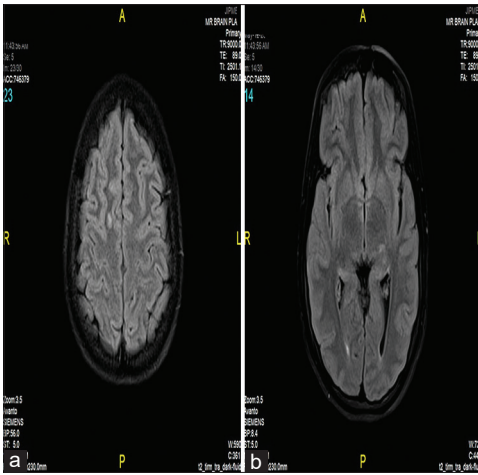
## Anaesthetic concerns in pregnancy associated with myelin oligodendrocyte glycoprotein encephalomyelitis

Sir,

Myelin oligodendrocyte glycoprotein encephalomyelitis (MOG-EM) is a rare demyelinating autoimmune disorder,

characterised by optic neuritis, myelitis and brain stem encephalomyelitis. Previously, it was categorised as a variant of multiple sclerosis (MS) or neuromyelitis optica spectrum disorder (NMOSD). However, it has recently been classified as a separate disease entity with unique radiological and immunopathological findings.<sup>[1]</sup> We report the anaesthetic considerations and management of a parturient with MOG-EM who underwent a caesarean section (CS).

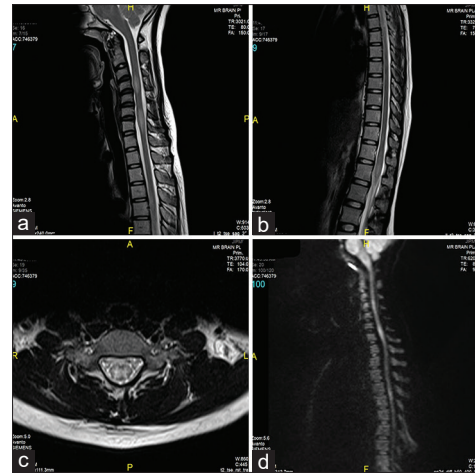
A 32-year-old gravida 2, para 1 pregnant woman, with a case of demyelinating disorder was admitted for CS.



**Figure 1:** (a) FLAIR axial image shows a focal sub-cortical white matter hyperintensity in the right superior frontal gyrus. (b) FLAIR axial image shows a lesion involving the left thalamus laterally

During her first pregnancy, the patient underwent CS under spinal anaesthesia due to cephalopelvic disproportion. Surgery was uneventful with no reports of prolonged motor or sensory blockade following neuraxial anaesthesia. One year later, the patient developed new-onset paraesthesia in both legs, with exaggerated deep tendon reflexes. Magnetic resonance imaging (MRI) of the spine revealed demyelinating lesions of the cerebrum, cerebellum, brain stem [Figure 1a and b) and spinal cord [Figure 2a–d]. Based on clinical, serological and radiological tests, the patient was diagnosed with aquaporin negative-MOG-positive NMOSD. Clinical improvement was noted and remission was obtained after three cycles of methylprednisolone therapy. Oral prednisolone and azathioprine were started to prevent relapse. After 1 year of remission, the patient was diagnosed to be pregnant. She continued to take oral prednisolone and azathioprine during the course of her pregnancy and remained in remission.

During the preoperative anaesthetic visits, neurological examination was regular. Taking available evidence and the possibility of post-partum relapse of the disease into consideration, we decided to administer general anaesthesia after discussion with the patient about the risks and benefits of both anaesthetic techniques. Along with standard monitors (electrocardiogram, pulse oximetry, non-invasive blood pressure), neuromuscular monitoring and bispectral index monitoring were also instituted. Rapid sequence induction was performed using thiopentone and rocuronium. General anaesthesia was maintained with sevoflurane in a mixture of nitrous oxide and oxygen. Midazolam and



**Figure 2:** (a) T2-weighted sagittal image of the cervical spine shows a short-segment hyperintense lesion with the expansion of the cord at the C4 level and C6–C7 levels. (b) T2-weighted sagittal image of the thoraco-lumbar spine shows the conus medullaris is involved with hyperintensity and expansion. (c) T2-weighted axial image of the cervical spine shows the lesion involving the entire cross-section of the cord. (d) Diffusion-weighted sagittal image of the cervical spine shows restricted involved regions of the spinal cord

fentanyl were administered after cord clamping. The neonate had a normal Appearance, Pulse, Grimace, Activity and Respiration (APGAR) score.

The surgery lasted for 90 min and deep neuromuscular blockade (train of four [TOF] count of 0) was observed throughout the surgery. The time from the administration of the intubating dose of rocuronium to the appearance of the first response was approximately 120 min. Neuromuscular blockade was reversed with neostigmine and glycopyrrolate at a TOF count of 4 (which appeared at 160 min) and the trachea was successfully extubated. She was shifted to the post anaesthesia care unit for observation, and the postoperative course was uneventful. Due to the possibility of exacerbation of the disease in the postpartum period, she was closely monitored by a neurologist until discharge. At subsequent post-natal visits, there was no evidence of worsening of her neurological symptoms.

In the limited evidence available pertaining to the anaesthetic management of a parturient with NMOSD, it is not clear as to which anaesthetic modality is safer in these patients. The administration of neuraxial anaesthesia for these patients is subject to debate. There are case reports describing disease exacerbation following neuraxial anaesthesia.<sup>[2,3]</sup> In contrast, uneventful post-operative outcomes have also been demonstrated in NMOSD patients who received epidural anaesthesia for CS and labour

analgesia.<sup>[4,5]</sup> At present, it can be assumed only as a temporal consequence, because studies assessing exacerbation in relation to neuraxial anaesthesia have failed to establish a cause–effect relationship.

The administration of general anaesthesia in patients with NMOSD has its own disadvantages. Succinylcholine should be avoided to prevent a hyperkalemic response. Increased sensitivity and incomplete recovery from non-depolarising neuromuscular blockade requiring bilevel positive airway pressure (BiPAP) therapy after extubation has been reported.<sup>[6]</sup> Even in our case, there was a delay in the appearance of the first TOF response after the intubating dose, and the reversal agent was administered after 160 min. The concern of increased sensitivity to neuromuscular blocking drugs warranted us to use neuromuscular monitoring during the surgery. Nonetheless, ensuring foetomaternal safety is also very important and has to be kept in mind.<sup>[7]</sup>

Knowledge about this rare disease process, its interaction with pregnancy and how anaesthesia affects it may equip the anaesthesiologist to manage these patients optimally.

#### Declaration of patient consent

The authors certify that they have obtained all appropriate patient consent forms. In the form, the patient has given her consent for her images and other clinical information to be reported in the journal. The patient understands that her name and initials will not be published and due efforts will be made to conceal identity, but anonymity cannot be guaranteed.

#### Financial support and sponsorship

Nil.

#### Conflicts of interest

There are no conflicts of interest.

**Aswini Kuberan, Rajasekar Ramadurai,  
Mukilan Balasubramanian, Ankita Dey**

Department of Anaesthesiology and Critical Care, Jawaharlal Institute of Postgraduate Medical Education and Research, Puducherry, India

#### Address for correspondence:

Dr. Rajasekar Ramadurai,  
Department of Anaesthesiology and Critical Care, Jawaharlal  
Institute of Postgraduate Medical Education and Research (JIPMER),  
Puducherry, India.  
E-mail: rajasekar.dx@gmail.com

**Submitted:** 25-Mar-2022

**Revised:** 27-Jul-2022

**Accepted:** 03-Aug-2022

**Published:** 22-Aug-2022

## REFERENCES

1. Jarius S, Paul F, Aktas O, Asgari N, Dale RC, de Seze J, *et al.* MOG encephalomyelitis: International recommendations on diagnosis and antibody testing. *J Neuro inflammation* 2018;15:134-44.
2. Facco E, Giorgetti R, Zanette G. Spinal anaesthesia and neuromyelitis optica: Cause or coincidence? *Eur J Anaesthesiol* 2010;27:578-80.
3. Hosseini H, Brugieres P, Degos JD, Cesaro P. Neuromyelitis optica after a spinal anaesthesia with bupivacaine. *Mult Scler* 2003;9:526-8.
4. Gunaydin B, Akcali D, Alkan M. Epidural anaesthesia for caesarean section in a patient with Devic's syndrome. *Anaesthesia* 2001;56:565-7.
5. Bourre B, Marignier R, Zéphir H, Papeix C, Brassat D, Castelnovo G, *et al.* Neuromyelitis optica and pregnancy. *Neurology* 2012;78:875-9.
6. Sadana N, Houtchens M, Farber MK. Anesthetic management of a parturient with neuromyelitis optica. *Int J Obstet Anesth* 2012;21:371-5.
7. Mehdiratta L, Chakravarthy K, Anand S. Improving the perioperative compliance and quality care in obstetric and paediatric anaesthesia: Challenges and anodynes. *Indian J Anaesth* 2020;64:927-30.

This is an open access journal, and articles are distributed under the terms of the Creative Commons Attribution-NonCommercial-ShareAlike 4.0 License, which allows others to remix, tweak, and build upon the work non-commercially, as long as appropriate credit is given and the new creations are licensed under the identical terms.

Access this article online	
Quick response code	Website: www.ijaweb.org
	DOI: 10.4103/ija.ija_288_22

**How to cite this article:** Kuberan A, Ramadurai R, Balasubramanian M, Dey A. Anaesthetic concerns in pregnancy associated with myelin oligodendrocyte glycoprotein encephalomyelitis. *Indian J Anaesth* 2022;66:614-6.

© 2022 Indian Journal of Anaesthesia | Published by Wolters Kluwer - Medknow