

Clinical Features of Human Metapneumovirus Pneumonia in Non-Immunocompromised Patients: An Investigation of Three Long-Term Care Facility Outbreaks

Yosuke Karimata,¹ Takeshi Kinjo,¹ Gretchen Parrott,¹ Ayako Uehara,¹ Daijiro Nabeya,¹ Shusaku Haranaga,¹ Futoshi Higa,^{1,a} Masao Tateyama,¹ Keiko Miyagawa,² Tomoo Kishaba,³ Kanako Otani,^{4,5} Michiko Okamoto,⁵ Hidekazu Nishimura,⁴ and Jiro Fujita¹

¹Department of Infectious Diseases, Respiratory, and Digestive Medicine, Graduate School of Medicine, University of the Ryukyus, Okinawa, Japan; ²Personnel Health Management Center, Department of General Affairs, Okinawa Prefectural Government, Japan; ³Department of Respiratory Medicine, Okinawa Chubu Hospital, Japan; ⁴Virus Research Center, Sendai Medical Center, National Hospital Organization, Miyagi, Japan; ⁵Department of Virology, Tohoku University Graduate School of Medicine, Miyagi, Japan

Background. Several studies have reported outbreaks due to human metapneumovirus (hMPV) in long-term care facilities (LTCF) for the elderly. However, most of these reports are epidemiological studies and do not investigate the clinical features of hMPV pneumonia.

Methods. Three independent outbreaks of hMPV occurred at separate LTCF for intellectually challenged and elderly residents. A retrospective evaluation of hMPV pneumonia and its clinical and radiological features was conducted using available medical records and data.

Results. In 105 hMPV infections, 49% of patients developed pneumonia. The median age of pneumonia cases was significantly higher than non-pneumonia cases ($P < .001$). Clinical manifestations of hMPV pneumonia included high fever, wheezing in 43%, and respiratory failure in 31% of patients. An elevated number of white blood cells as well as increased levels of C-reactive protein, creatine phosphokinase, and both aspartate and alanine transaminases was also observed among pneumonia cases. Evaluation of chest imaging revealed proximal bronchial wall thickenings radiating outward from the hilum in most patients.

Conclusions. The aforementioned characteristics should be considered as representative of hMPV pneumonia. Patients presenting with these features should have laboratory testing performed for prompt diagnosis.

Keywords. bronchial wall thickenings; human metapneumovirus; long-term care facility; outbreak; pneumonia.

Human metapneumovirus (hMPV) was discovered in 2001; however, seroprevalence studies indicate this virus has circulated among humans for at least 60 years [1]. Although it is considered a community-acquired respiratory virus, children <5 years of age experience hMPV infection at least once, and reinfection is common [1]. Seasonal patterns of infection have been observed in several regions, with the majority of cases occurring from late winter to early spring in European countries, the United States, and Canada, and between spring and summer in Asian countries, including Japan [2–11]. Even though it is usually a mild and self-limiting disease, hMPV can potentially cause severe lower respiratory infections, especially in young children, the elderly, and immunocompromised patients [3–5, 12–14].

Several studies have reported outbreaks due to hMPV in long-term care facilities (LTCF) for the elderly and described the high incidence of pneumonia [3–5, 14–17]. However, most reports are epidemiological studies, and they often do not include the clinical and radiological features of hMPV pneumonia. Three independent outbreaks of hMPV occurred in LTCF for intellectually challenged and elderly residents in Okinawa, Japan. As a result, approximately 50% of the symptomatic patients developed pneumonia during the outbreaks. The objective of the present study was to retrospectively evaluate the clinical features, laboratory, and radiological findings of hMPV pneumonia.

METHODS

Outbreaks

Patients with hMPV infection were identified during 3 independent LTCF outbreaks in Okinawa, a subtropical region of Japan. The outbreaks were designated as outbreak A, B, and C, and the facilities where those outbreaks occurred are also identified as facility A, B, and C, respectively. Outbreak A occurred in an LTCF for intellectually challenged patients from March 28 to April 30, 2012. Outbreak B occurred in a complex containing a nursing home and a hospital for the elderly from March 26 to May 1, 2013. Outbreak C occurred in a different LTCF for

Received 19 February 2018; editorial decision 27 April 2018; accepted 1 May 2018; published online May 4, 2018.

Presented in part: International Conference of American Thoracic Society, May 2014, San Diego, CA.

^aPresent Affiliation: National Hospital Organization Okinawa Hospital, 3-20-14 Ganeko, Ginowan, Okinawa 901-2214, Japan.

Correspondence: T. Kinjo, MD, PhD, 207 Uehara, Nishihara, Okinawa 903-0215, Japan (t_kinjo@med.u-ryukyu.ac.jp).

The Journal of Infectious Diseases® 2018;218:868–75

© The Author(s) 2018. Published by Oxford University Press for the Infectious Diseases Society of America. All rights reserved. For permissions, e-mail: journals.permissions@oup.com. DOI: 10.1093/infdis/jiy261

intellectually challenged patients from May 1 to June 11, 2013. Within their grounds, facilities A and B have the capacity and staff to provide primary care and routine check-ups; however, facility C does not.

Definition of Human Metapneumovirus Infection and Review Process for Medical Records

During the outbreaks, confirmed cases of hMPV were defined as having clinical respiratory samples positive for virus via an hMPV-specific polymerase chain reaction (PCR) and/or rapid antigen test (RAT). Probable cases had recently acquired clinical manifestations compatible with a respiratory infection (eg, respiratory symptoms and fever $\geq 37.5^{\circ}\text{C}$), within the appropriate time frame. Cases of febrile disease without respiratory symptoms, or diagnosed with alternative causation, were excluded from the sample population. The medical records for both confirmed and probable cases were retrospectively evaluated.

The Institutional Review Board of the University of the Ryukyus approved this study. Informed consent from each patient was waived because the study was retrospective in approach and caused no additional adverse events for any subjects.

Detection of Human Metapneumovirus in Clinical Samples

During outbreak A, nasal swabs were collected from 14 patients and tested with a RAT for influenza virus. After all patients returned negative results, the residual liquid underwent nucleic acid extraction using a commercially available extraction kit (Ribospin vRD; GeneAll, Seoul, Korea). Purified eluent from the sample was tested using a multiplex reverse-transcription PCR kit (Seeplex RV15 OneStep ACE Detection; Seegene, Seoul, Korea), which can detect 15 respiratory viruses, including hMPV, influenza virus A/B, human adenovirus, coronavirus, parainfluenza virus 1/2/3, rhinovirus A/B/C, respiratory syncytial virus A/B, bocavirus 1/2/3/4, and enterovirus, simultaneously. The Seeplex RV15 OneStep ACE Detection kit targets the hMPV N and L genes. During outbreak B, nasal swabs from 11 patients were tested with an hMPV RAT (CHECK hMPV; SA Scientific, San Antonio, TX) targeting the hMPV N and F proteins. Residual liquid from the hMPV RAT was also tested using the multiplex PCR method described above. During outbreak C, hMPV RAT and multiplex PCR were used for 4 patients each. Overall, multiplex PCR and RAT was performed in 29 and 15 patients and returned 27 and 10 positive results, respectively.

Measurement of Serum Antibody for Human Metapneumovirus

Serum antibodies against hMPV were also examined in a subset of patients ($n = 11$) from outbreak A. Acute phase serum samples were collected within 1 week after the onset of symptoms, and convalescent phase samples were collected 1 month later. The hMPV antibody titers were determined by enzyme-linked

immunosorbent assay (ELISA) using purified virion as the antigen, a method described by Okamoto et al [18]. In brief, 96 microwell plates (Thermo Fisher Scientific, Waltham, MA) were coated with a Sendai-155-D06 (hMPV-A) and Sendai-1311-04 (hMPV-B) antigen mixture and refrigerated at 4°C for 2 hours. Plates were then blocked for 1 hour at room temperature and washed. Starting at a 1:100 dilution, 50- μL serial 2-fold dilutions of samples were added to the prepared plates and incubated at 37°C for 1 hour. Plates were labeled with horseradish peroxidase-labeled goat anti-human IgG (Millipore, Billerica, MA) and detected using a peroxidase substrate kit (Bio-Rad Laboratories, Hercules, CA) at 415 nm. Patients with a ≥ 4 -fold increase of antibody titers between the acute and convalescent phase were regarded as having an acute hMPV infection [19].

Analysis of Chest Images

Chest x-rays and computed tomography (CT) images were analyzed by 3 pulmonologists. Attention was focused on distribution, location, and pattern of the abnormal shadows. Bronchial wall thickenings and pleural effusions were also assessed. Final decisions were reached by consensus.

For chest CT images, dense consolidation was considered to be present when vascular margins were obscured. Ground-glass opacity (GGO) was defined as a hazy increase in attenuation without obscuring vascular markings. Centrilobular nodule was defined as either a nodule recognized near the peripheral pulmonary artery branches or 3 to 5 mm away from the pleura, interlobular septa, or pulmonary veins.

Statistics

Continuous variables, such as age, body temperature, and laboratory findings, between pneumonia and non-pneumonia cases were compared using the Wilcoxon/Kruskal-Wallis test. Categorical variables were evaluated using the Pearson's χ^2 test or Fisher's exact test, when appropriate. A two-sided P value of $<.05$ was considered to be statistically significant. All data were analyzed with JMP version 13 (SAS Institute Inc., Cary, NC).

RESULTS

During the outbreaks, 105 patients with hMPV infections (30 confirmed cases and 75 probable cases) were identified. Each facility experienced 63 (12 confirmed cases), 22 (11 confirmed cases), and 20 (7 confirmed cases) hMPV infections. The attack rates were 16% (63 of 406 residents) in outbreak A, 10% (22 of 220 residents) in outbreak B, and 20% (20 of 100 residents) in outbreak C.

Patient characteristics and clinical manifestations are shown in Table 1. The most frequently encountered disorders were intellectual disabilities, cerebral palsy, and schizophrenia. Among 105 hMPV infections, 51 cases (49%) developed pneumonia as evident on chest x-rays and/or CT. For 49 of 51 (96%) cases, pneumonia was diagnosed within 5 days after the onset of symptoms. Pneumonia patients were significantly older than

Table 1. Patients' Characteristics

Characteristics	All Patients (n = 105)	Pneumonia (n = 51)	Non-pneumonia (n = 54)	P Value ^a
Male gender ^b (%)	45 (42.9%)	17 (33.3%)	28 (51.9%)	.0553
Age, median (range)	48 (16–104)	58 (16–104)	44 (20–100)	<.001
Underlying Disorders (%)				
Intellectual disabilities ^b	63 (60.0%)	20 (39.2%)	43 (79.6%)	<.001
Cerebral palsy ^b	27 (25.7%)	9 (17.6%)	18 (33.3%)	.066
Schizophrenia ^b	12 (11.4%)	8 (15.7%)	4 (7.4%)	.1826
Dementia	10 (9.5%)	8 (15.7%)	2 (3.7%)	.048
Epilepsy	8 (7.6%)	3 (5.9%)	5 (9.3%)	.7166
Cerebrovascular disorder	7 (6.7%)	6 (11.8%)	1 (1.9%)	.0556
Other neurological disease	6 (5.7%)	4 (7.8%)	2 (3.7%)	.4285
Bedridden state	6 (5.7%)	6 (11.8%)	0 (0%)	.0112
Tracheostomy	4 (3.8%)	4 (7.8%)	0 (0%)	.0523
Chronic heart failure	4 (3.8%)	3 (5.9%)	1 (1.9%)	.3537
Diabetes mellitus	3 (2.9%)	3 (5.9%)	0 (0%)	.1111
Asthma	3 (2.9%)	1 (2.0%)	2 (3.7%)	1
Cancer	2 (1.9%)	2 (3.9%)	0 (0%)	.2335
Chronic liver disease	1 (1.0%)	1 (2.0%)	0 (0%)	.4857
Manifestations				
Fever at peak [°C]	38.8 (37.5–40.4)	39 (37.9–40.4)	38.6 (37.5–40)	.0001
Wheezing	27 (25.7%)	22 (43.1%)	5 (9.3%)	<.0001
Respiratory failure	18 (17.1%)	16 (31.4%)	2 (3.7%)	.0002

^aDifferences between pneumonia and non-pneumonia cases were analyzed by Fisher's exact test, except variables labeled with b.

^bDifferences between 2 groups were analyzed by Pearson's χ^2 test.

non-pneumonia cases (median age, 58 vs 44; $P < .001$). It is interesting to note that almost all patients with dementia or in a bedridden state acquired pneumonia. However, these patients were frequently septuagenarians or older (age range, 70–100 and 83–100, respectively; data not shown). Pneumonia patients also developed higher fever ($P = .0001$), wheezing ($P < .0001$), and needed oxygen therapy administered ($P = .0002$) more frequently.

Sputum culture for bacterial identification was performed for 26 pneumonia patients; 14 were positive for pathogenic bacteria and 12 were negative. *Streptococcus pneumoniae* was the most commonly isolated ($n = 5$) followed by *Pseudomonas aeruginosa* ($n = 4$) (Supplementary Table 1). *Moraxella catarrhalis* and *Haemophilus influenzae* were coinfecting in 1 patient. All pneumonia patients were treated with empirical antibiotics regardless of the bacterial test results. Seven pneumonia patients from facility C, where acute medical care could not be provided, required admittance to a local hospital for care. Most patients improved within 1 week and none of the patients died.

Blood tests were performed in 81 patients including 49 pneumonia and 32 non-pneumonia patients. Median white blood cell (WBC) count, C-reactive protein (CRP), aspartate aminotransferase (AST), alanine aminotransferase (ALT), and creatine phosphokinase (CPK) concentrations were significantly higher for pneumonia cases than non-pneumonia cases (Figure 1). More than a 4-fold increase in antibody titers

was observed between the acute and convalescent phase of 5 patients. These patients were regarded as having acute hMPV infection. Among 6 other patients, 5 had titers more than 12800 at either the acute or convalescent phase. Because 80% of healthy Japanese adults do not have titers over 3200 [18], these 5 symptomatic patients were assumed to have an acute hMPV infection during an hMPV outbreak, regardless of PCR results. One final patient had no significant elevation in antibody titers but was also regarded as having acute hMPV infection due to a positive PCR result (Supplementary Table 2).

The chest x-ray findings of 41 pneumonia patients are summarized in Table 2. For these patients, abnormal shadows were primarily found in the proximal area of the lung (100%) and bilateral distribution was common (80%). Bronchial wall thickenings were observed in all 41 pneumonia patients. Of note, proximal bronchial wall thickenings radiating outward from the hilum were observed in most patients, and representative images are depicted in Figure 2. Abnormal opacities were observed in a patchy pattern (90%) more frequently than confluent (12%).

Table 3 summarizes the chest CT findings of 24 pneumonia patients. Multilobar distribution was observed in all cases and lower lobes were frequently involved. Again, abnormal shadows were primarily found in the proximal rather than peripheral areas of the lung. Lobular opacity was the most common shadow pattern (92%), in contrast to GGO (21%) and dense

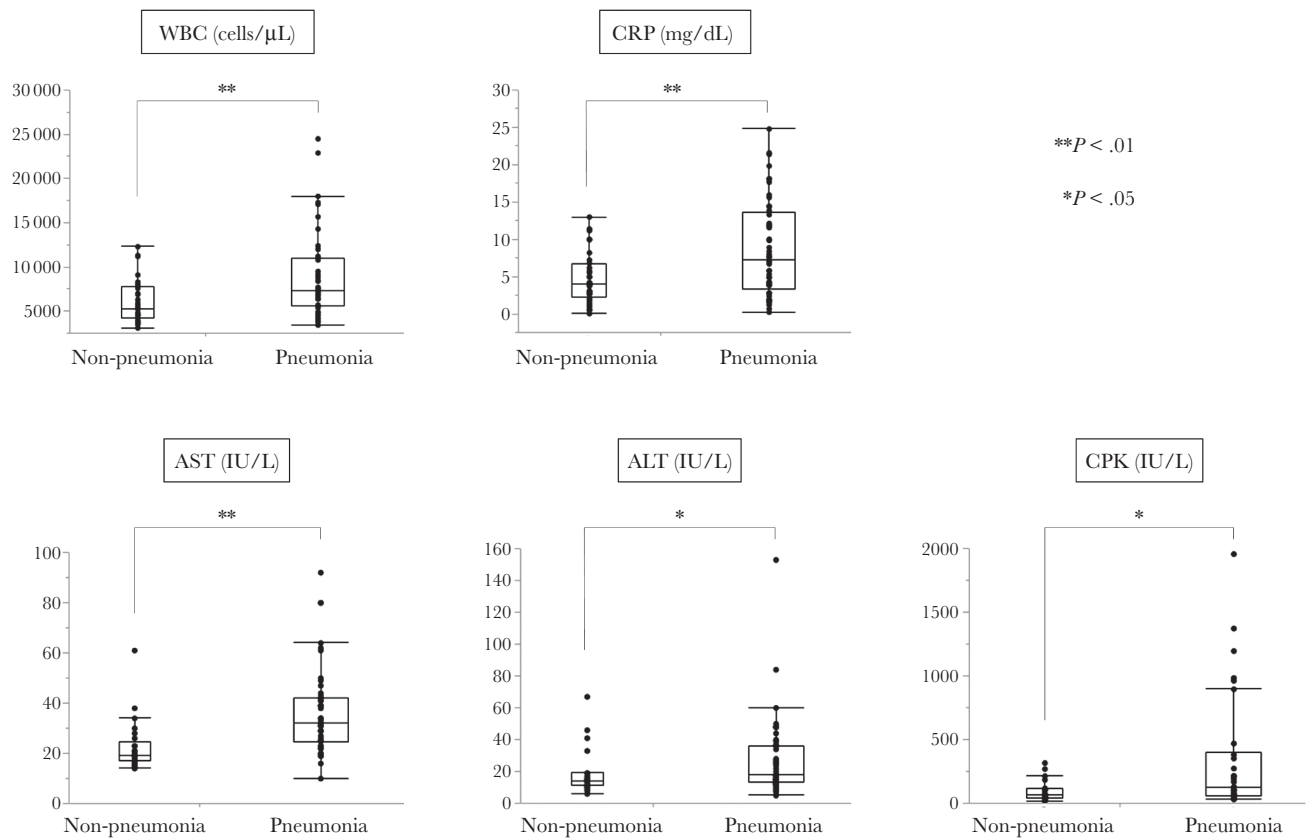


Figure 1. Laboratory findings among non-pneumonia and pneumonia patients. The numbers of non-pneumonia and pneumonia patients included are as follows: white blood cell (WBC) ($n = 29$ and $n = 48$), C-reactive protein (CRP) ($n = 32$ and $n = 49$), aspartate aminotransferase/alanine aminotransferase (AST/ALT) ($n = 25$ and $n = 46$), and creatine phosphokinase (CPK) ($n = 20$ and $n = 30$). The box and whisker plots describe the 10th, 25th, 50th, 75th, and 90th percentiles. *, $P < .05$; **, $P < .01$.

consolidation (13%). Bronchial wall thickenings were also frequently seen on CT images (96%). Representative CT images of selected pneumonia patients are shown in Figures 3 and 4. A follow-up chest x-ray or CT was performed in 47 of 51 pneumonia

patients (92.2%), and abnormal shadows seen during the out-breaks were diminished, as demonstrated in Figures 2 and 4.

DISCUSSION

To date, many outbreaks due to hMPV have been reported; however, few studies focus on the clinical features of hMPV pneumonia. Our data shows older LTCF residents, especially those with dementia or in a bedridden state, frequently developed pneumonia due to hMPV when compared with other residents. Moreover, high fever, respiratory failure, wheezing, and elevated WBC, CRP, AST, ALT, and CPK levels were frequently observed among hMPV pneumonia cases. Typical hMPV pneumonia chest images exhibit proximal bronchial wall thickenings radiating outward from the hilum.

Although it is frequently the cause of a mild, self-limiting respiratory infection in healthy children and adults, hMPV infection can also induce a severe infection in the elderly. Falsey et al [20] reported that older adults more frequently experience dyspnea and wheezing, during the course of the disease, compared with younger patients. Although no fatal cases were recorded in this cohort, the mortality rate of elderly patients in LTCF during an hMPV outbreak has been reported to be approximately 10%

Table 2. Chest X-Ray Findings

Findings	Number of Patients (%)
	($n = 41$)
Distribution	
Unilateral	8 (20%)
Bilateral	33 (80%)
Location	
Upper	19 (46%)
Middle	34 (83%)
Lower	39 (95%)
Pattern	
Patchy	37 (90%)
Confluent	5 (12%)
Other findings	
Bronchial wall thickenings	41 (100%)
Pleural effusion	4 (10%)

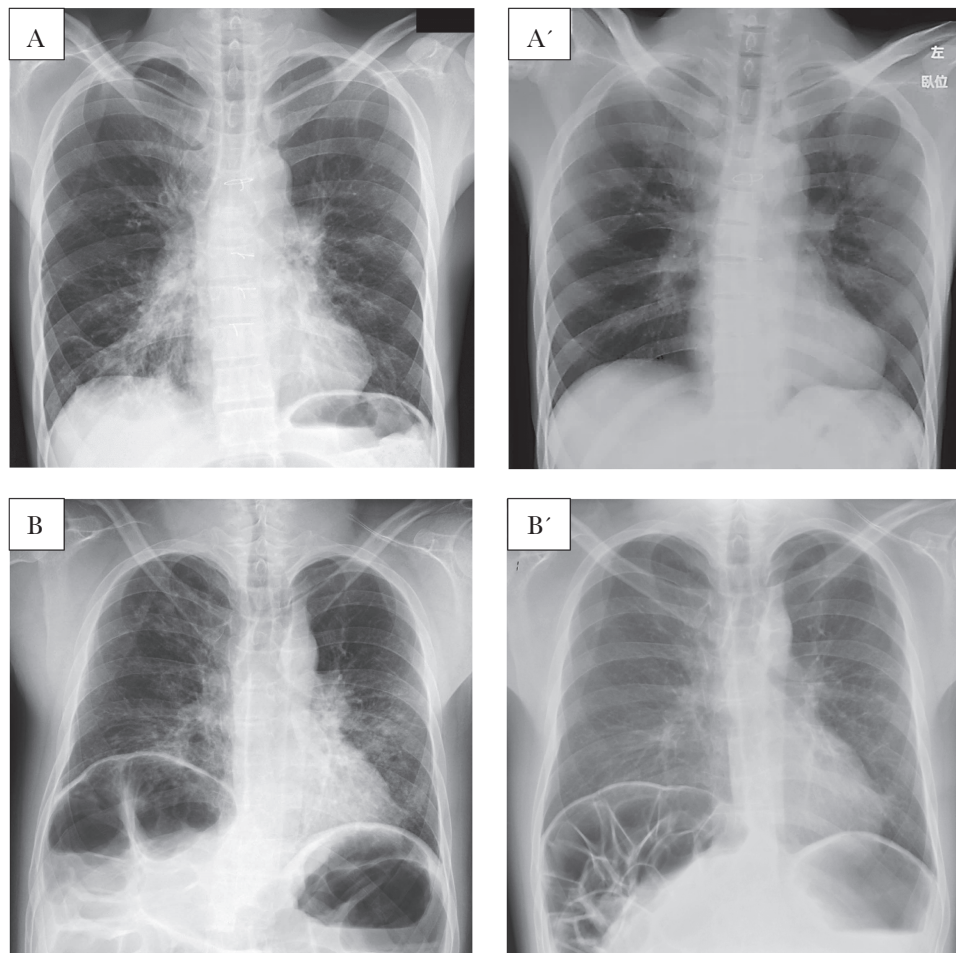


Figure 2. Representative chest x-ray images for human metapneumovirus pneumonia. Bronchial wall thickenings radiating outward from the hilum and patchy infiltrations were seen during the outbreaks (A and B). Postinfection images demonstrate abnormal shadows were diminished along with symptoms (A', B'). Chest x-rays obtained from a (A) 44-year-old male and (B) 36-year-old male are shown.

Table 3. Chest Computed Tomography Findings

Findings	Number of Patients (%)
	(n = 24)
Distribution	
Unilobar	0 (0%)
Multilobar	24 (100%)
Bilateral	21 (88%)
Proximal	23 (96%)
Peripheral	11 (46%)
Location	
Upper lobe (except lingula)	17 (71%)
Middle lobe or lingula	21 (88%)
Lower lobe	24 (100%)
Pattern	
Dense consolidation	3 (13%)
Ground-glass opacity	5 (21%)
Lobular opacity	22 (92%)
Centrilobular nodules	8 (33%)
Other Findings	
Bronchial wall thickenings	23 (96%)
Pleural effusion	4 (17%)

[3, 5], demonstrating again that elderly patients are susceptible to more severe hMPV infections. Darniot et al [21] also demonstrated that older mice develop a more severe hMPV infection compared with young mice. Nevertheless, outbreaks of hMPV also occurred in LTCF for intellectually disabled patients (facilities A and C), where residents were not elderly. In general, the immune system of intellectually disabled patients is not weak; however, we speculate they may have been susceptible to hMPV due to isolation and lack of exposure to natural infection of hMPV for an extended time. Therefore, it is possible their antibodies against hMPV might be unusually diminished.

The present study demonstrated that WBC and CRP, AST, ALT, and CPK concentrations were higher in patients with pneumonia than non-pneumonia infections. Although Scheurman et al [22] reported that AST and ALT were slightly elevated in hMPV-infected immunocompromised children, no studies have revealed the novel characteristics of serum markers in adult patients with hMPV pneumonia. Some viral and bacterial pathogens can cause rhabdomyolysis. Influenza virus,

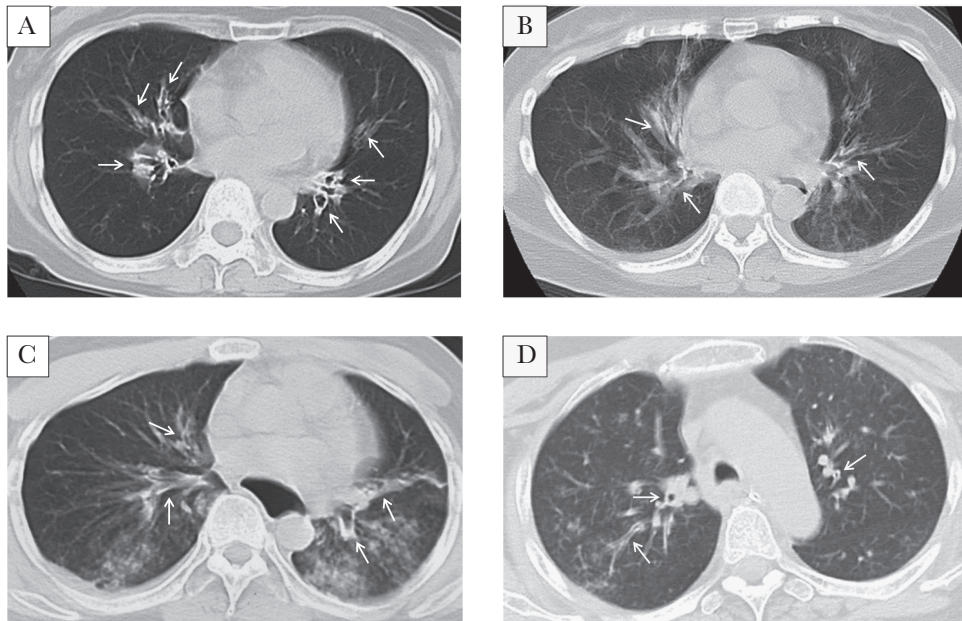


Figure 3. Representative chest computed tomography (CT) images in human metapneumovirus pneumonia. Bronchial wall thickenings in the proximal bronchus (A, B, C, and D) and multiple lobular opacities (C and D) were observed. Chest CTs obtained from a (A) 61-year-old female, (B) 59-year-old female, (C) 36-year-old male, and (D) 55 year-old female are shown. White arrows indicate bronchial wall thickenings.

human immunodeficiency virus, and coxsackie virus are the most commonly documented [23], whereas *Legionella* species, *Francisella tularensis*, and *S. pneumoniae* [23, 24] are common among bacterial pathogens. Respiratory pathogens, such as *Chlamydophila psittaci* and *Mycoplasma pneumoniae*, have also been implicated [25]. However, neither rhabdomyolysis nor elevated levels of CPK have been reported in patients with hMPV pneumonia before. More importantly, these data indicate that

hMPV infection should be included in the differential diagnosis when we treat pneumonia patients with elevated CPK.

Chest imaging revealed bronchial wall thickenings radiating out from the hilum were common for hMPV pneumonia. Proximal tramlines arising out from the hilum seem like “spider legs” on the chest x-ray. Although some studies report the radiological findings of hMPV pneumonia in immunocompromised patients, studies conducted within immunocompetent

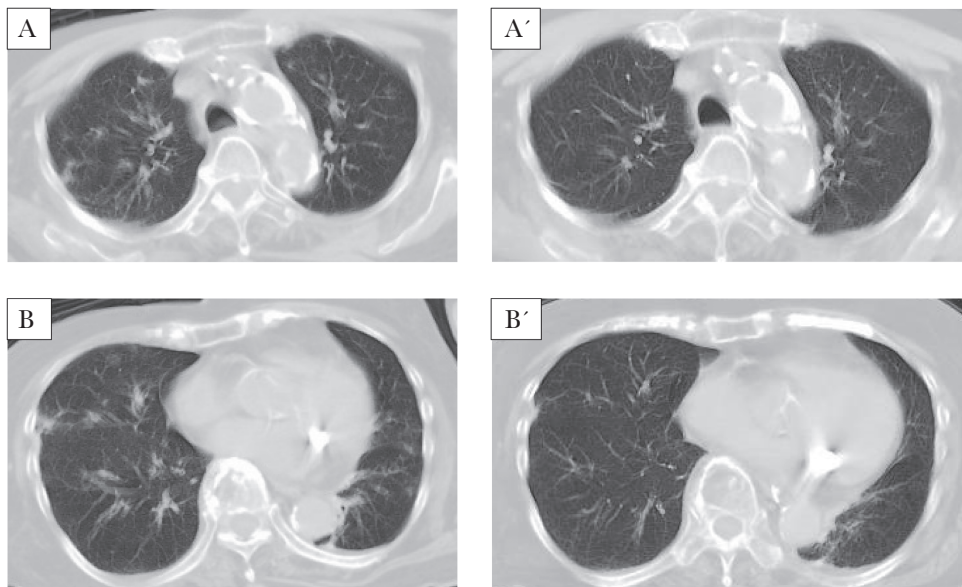


Figure 4. Computed tomography (CT) improvement through human metapneumovirus outbreak. Bronchial wall thickenings in the proximal bronchus and multiple lobular opacities seen during the outbreak (A and B) were diminished after the remission of the symptoms (A', B'). Chest CTs from a 77-year-old female are shown.

adults or the elderly are limited. Previous studies have shown interstitial infiltrates, GGO, as well as centrilobular nodules suggestive of bronchitis and bronchiolitis are common radiological features for hMPV pneumonia in immunocompromised patients [26–29]. However, only 1 report describes chest images among elderly, immunocompetent inpatients during an hMPV outbreak. Four of the 8 affected patients had abnormal shadows in the chest x-ray, and 3 of the 4 had linear shadows and were diagnosed with hMPV-induced bronchitis or bronchiolitis [17]. Because ciliated airway epithelial cells are the primary targets for hMPV infection [30], it is easily justifiable for bronchial wall thickenings, evidence of bronchitis or bronchiolitis, to be common radiological features in hMPV pneumonia. Centrilobular nodules, interstitial infiltrates, and GGO were not frequently observed in the present study. It is possible that an immunocompromised host's weaker immune response to hMPV may allow the virus to spread into the peripheral bronchiole and lung parenchyma. However, this cohort did not contain immunocompromised individuals, and radiological findings may reflect a more reasonable host response to hMPV infections.

Unfortunately, complete and detailed information regarding symptoms and physical examinations were not possible due to study design. In addition, this study may contain other limitations beyond those expected of a retrospective study. First, hMPV RAT and/or PCR were not performed in all symptomatic patients during the outbreaks. Due to the restrictions of the national health insurance system in Japan, RAT and PCR testing for hMPV is not approved for diagnostic decisions in adult patients. As such, attending physicians in each LTCF consulted the University of the Ryukyus' Department of Infectious Diseases, Respiratory, and Digestive Medicine as each outbreak waned. As a result, only a subset of affected patients could be tested. Other laboratory testing, bacterial cultures, and imaging tests (eg, chest x-ray and CT) were also only performed on subsets of patients. Moreover, by including fever in the case definition, it is possible that the mildest forms of hMPV infection were overlooked. Elderly patients do not always exhibit fever during infection. However, using respiratory symptoms alone may have broadened the case definition beyond usefulness. Our cohort contained multiple, and in many cases severe, underlying disorders. Therefore, patients were frequently unable to self-report and physicians had to rely solely on observation. Thus, bias should be considered when interpreting these data.

CONCLUSIONS

In conclusion, we report the clinical and radiological features of hMPV pneumonia in non-immunocompromised patients collected from 3 outbreaks in LTCF in Okinawa, Japan. As a common virus, hMPV is capable of causing outbreaks in LTCF and causing pneumonia, especially in the elderly. When treating adult pneumonia patients that present with the features described, physicians should consider hMPV infection and

perform laboratory testing for prompt diagnosis and adequate infection control, especially in isolated and at-risk populations.

Supplementary Data

Supplementary materials are available at *The Journal of Infectious Diseases* online. Consisting of data provided by the authors to benefit the reader, the posted materials are not copyedited and are the sole responsibility of the authors, so questions or comments should be addressed to the corresponding author.

Notes

Acknowledgments. We thank Haley Cash for help in laboratory testing. We also thank the physicians and other health-care workers of the National Hospital Organization Ryukyu Hospital, Hokuzan Hospital, and Okinawa Ryouikuen.

Financial support. This work was funded by a research grant from Okinawa Prefectural Government.

Potential conflicts of interest. All authors are without any conflict of interest. All authors have submitted the ICMJE Form for Disclosure of Potential Conflicts of Interest.

References

1. van den Hoogen BG, de Jong JC, Groen J, et al. A newly discovered human pneumovirus isolated from young children with respiratory tract disease. *Nat Med* **2001**; 7:719–24.
2. Kahn JS. Epidemiology of human metapneumovirus. *Clin Microbiol Rev* **2006**; 19:546–57.
3. Centers for Disease Control and Prevention (CDC). Outbreaks of human metapneumovirus in two skilled nursing facilities - West Virginia and Idaho, 2011–2012. *MMWR Morb Mortal Wkly Rep* **2013**; 62:909–13.
4. Te Wierik MJ, Nguyen DT, Beersma MF, Thijsen SF, Heemstra KA. An outbreak of severe respiratory tract infection caused by human metapneumovirus in a residential care facility for elderly in Utrecht, the Netherlands, January to March 2010. *Euro Surveill* **2012**; 17: pii: 20132.
5. Boivin G, De Serres G, Hamelin ME, et al. An outbreak of severe respiratory tract infection due to human metapneumovirus in a long-term care facility. *Clin Infect Dis* **2007**; 44:1152–8.
6. Døllner H, Risnes K, Radtke A, Nordbø SA. Outbreak of human metapneumovirus infection in Norwegian children. *Pediatr Infect Dis J* **2004**; 23:436–40.
7. Hamada N, Hara K, Matsuo Y, et al. Performance of a rapid human metapneumovirus antigen test during an outbreak in a long-term care facility. *Epidemiol Infect* **2014**; 142:424–7.
8. Yang Z, Suzuki A, Watanabe O, et al. Outbreak of human metapneumovirus infection in a severe motor-and-intellectual disabilities ward in Japan. *Jpn J Infect Dis* **2014**; 67:318–21.

9. Peiris JS, Tang WH, Chan KH, et al. Children with respiratory disease associated with metapneumovirus in Hong Kong. *Emerg Infect Dis* **2003**; 9:628–33.
10. Kim S, Sung H, Im HJ, Hong SJ, Kim MN. Molecular epidemiological investigation of a nosocomial outbreak of human metapneumovirus infection in a pediatric hemato-oncology patient population. *J Clin Microbiol* **2009**; 47:1221–4.
11. Cheng VC, Wu AK, Cheung CH, et al. Outbreak of human metapneumovirus infection in psychiatric inpatients: implications for directly observed use of alcohol hand rub in prevention of nosocomial outbreaks. *J Hosp Infect* **2007**; 67:336–43.
12. Feuillet F, Lina B, Rosa-Calatrava M, Boivin G. Ten years of human metapneumovirus research. *J Clin Virol* **2012**; 53:97–105.
13. Hoellein A, Hecker J, Hoffmann D, et al. Serious outbreak of human metapneumovirus in patients with hematologic malignancies. *Leuk Lymphoma* **2016**; 57:623–7.
14. Liao RS, Appelgate DM, Pelz RK. An outbreak of severe respiratory tract infection due to human metapneumovirus in a long-term care facility for the elderly in Oregon. *J Clin Virol* **2012**; 53:171–3.
15. Osbourn M, McPhie KA, Ratnamohan VM, Dwyer DE, Durrheim DN. Outbreak of human metapneumovirus infection in a residential aged care facility. *Commun Dis Intell Q Rep* **2009**; 33:38–40.
16. Louie JK, Schnurr DP, Pan CY, et al. A summer outbreak of human metapneumovirus infection in a long-term-care facility. *J Infect Dis* **2007**; 196:705–8.
17. Honda H, Iwahashi J, Kashiwagi T, et al. Outbreak of human metapneumovirus infection in elderly inpatients in Japan. *J Am Geriatr Soc* **2006**; 54:177–80.
18. Okamoto M, Sugawara K, Takashita E, et al. Development and evaluation of a whole virus-based enzyme-linked immunosorbent assay for the detection of human metapneumovirus antibodies in human sera. *J Virol Methods* **2010**; 164:24–9.
19. Okamoto M, Sugawara K, Takashita E, et al. Longitudinal course of human metapneumovirus antibody titers and reinfection in healthy adults. *J Med Virol* **2010**; 82:2092–6.
20. Falsey AR, Erdman D, Anderson LJ, Walsh EE. Human metapneumovirus infections in young and elderly adults. *J Infect Dis* **2003**; 187:785–90.
21. Darniot M, Pitoiset C, Petrella T, Aho S, Pothier P, Manoha C. Age-associated aggravation of clinical disease after primary metapneumovirus infection of BALB/c mice. *J Virol* **2009**; 83:3323–32.
22. Scheuerman O, Barkai G, Mandelboim M, Mishali H, Chodick G, Levy I. Human metapneumovirus (hMPV) infection in immunocompromised children. *J Clin Virol* **2016**; 83:12–6.
23. Singh U, Scheld WM. Infectious etiologies of rhabdomyolysis: three case reports and review. *Clin Infect Dis* **1996**; 22:642–9.
24. Byrd RP Jr, Roy TM. Rhabdomyolysis and bacterial pneumonia. *Respir Med* **1998**; 92:359–62.
25. Takayanagi N, Tokunaga D, Kubota M, et al. Community-acquired pneumonia with rhabdomyolysis. *Nihon Kokyuki Gakkai Zasshi* **2005**; 43:731–5.
26. Franquet T, Rodríguez S, Martino R, Salinas T, Giménez A, Hidalgo A. Human metapneumovirus infection in hematopoietic stem cell transplant recipients: high-resolution computed tomography findings. *J Comput Assist Tomogr* **2005**; 29:223–7.
27. Kamboj M, Gerbin M, Huang CK, et al. Clinical characterization of human metapneumovirus infection among patients with cancer. *J Infect* **2008**; 57:464–71.
28. Shahda S, Carlos WG, Kiel PJ, Khan BA, Hage CA. The human metapneumovirus: a case series and review of the literature. *Transpl Infect Dis* **2011**; 13:324–8.
29. Syha R, Beck R, Hetzel J, et al. Human metapneumovirus (HMPV) associated pulmonary infections in immunocompromised adults—initial CT findings, disease course and comparison to respiratory-syncytial-virus (RSV) induced pulmonary infections. *Eur J Radiol* **2012**; 81:4173–8.
30. Kuiken T, van den Hoogen BG, van Riel DA, et al. Experimental human metapneumovirus infection of cynomolgus macaques (*Macaca fascicularis*) results in virus replication in ciliated epithelial cells and pneumocytes with associated lesions throughout the respiratory tract. *Am J Pathol* **2004**; 164:1893–900.