

# Knotless Tendoscopic Peroneal Retinaculum Repair Technique for Recurrent Peroneal Tendon Dislocation



Akinobu Nishimura, M.D., Ph.D., Shigeto Nakazora, M.D., Ph.D., Yoshiyuki Senga, M.D.,  
Aki Fukuda, M.D., Ph.D., Ko Kato, M.D., Ph.D., and Akihiro Sudo, M.D., Ph.D.

**Abstract:** Peroneal tendon dislocation (PTD) is sometimes diagnosed as a sports-related injury, of which many cases lead to recurrent PTD (RPTD). Superior retinaculum repair is the major operative treatment of RPTD. The technique described herein comprises 8 steps: (1) Standard tendoscopic examination, (2) debridement of the pseudo-pouch base, (3) first anchor insertion, (4) suture relay, (5) second anchor insertion and suture relay, (6) third anchor insertion and suture relay, (7) suture tightening, and (8) suture bridge. Although this tendoscopic peroneal retinaculum repair technique is complicated, expensive, and requires a longer operation time, it incorporates a double-row suture bridge. Therefore, it has a wider contact surface between the superior retinaculum repair and fibula bone and tighter fixation than does a single-row technique. Moreover, our technique is knotless and thereby avoids knot-related complications. Tendoscopy has additional advantages in terms of less postoperative pain, fewer complications, and better cosmesis. In conclusion, this knotless tendoscopic peroneal retinaculum repair technique for RPTD is a patient-friendly surgery compared with previous procedures.

**P**eroneal tendon dislocation (PTD) is a rare occurrence that may occur due to a sports-related injury. Since PTD is similar to an ankle sprain, it is often misdiagnosed as lateral ankle sprain.<sup>1</sup> Regarding acute PTDs, conservative treatment is the first choice. However, the recurrence rate of PTD has been reported to be 17% to 60%,<sup>2,3</sup> leading to recurrent PTD (RPTD). Usually, RPTD requires operative treatment. To date, several operative procedures have been reported. One of the major operative procedures for RPTD is peroneal retinaculum repair.<sup>4</sup> This procedure is usually performed under direct vision. However, some tendoscopic procedures have been reported.<sup>5-8</sup> All previous tendoscopic procedures used suture anchors and incorporated a knot-tying element. Therefore, some problems related to knots, such as knot irritation, may occur, especially around thin subcutaneous areas. This study aimed to introduce a knotless tendoscopic

peroneal retinaculum repair technique for RPTD that has not been previously reported.

## Surgical Technique (With Video Illustration)

In this study, the surgery is performed under combined sciatic and saphenous nerve block, lumbar spinal anesthesia, or general anesthesia. The patient is placed in the lateral decubitus position with the surgery side facing up on a standard operating table (Video 1). A pneumatic tourniquet is placed on the proximal tibia, which is not generally used. The anatomical landmarks (the distal part of the fibula, fifth metatarsal base, and peroneus brevis tendon) and portals are drawn on the patient's skin as previously described (Fig 1).<sup>6</sup> The proximal portal is made 2 fingerbreadths proximal to the lateral malleolus tip. Moreover, the distal portal is made 1 fingerbreadth distal to the lateral malleolus tip. We use a 2.7-mm short arthroscope (Arthrex, Naples,

*From the Department of Orthopaedic and Sports Medicine, Graduate School of Medicine, Mie University, Tsu, Mie, Japan.*

*The authors report that they have no conflicts of interest in the authorship and publication of this article. Full ICMJE author disclosure forms are available for this article online, as [supplementary material](#).*

*Received February 3, 2022; accepted March 12, 2022.*

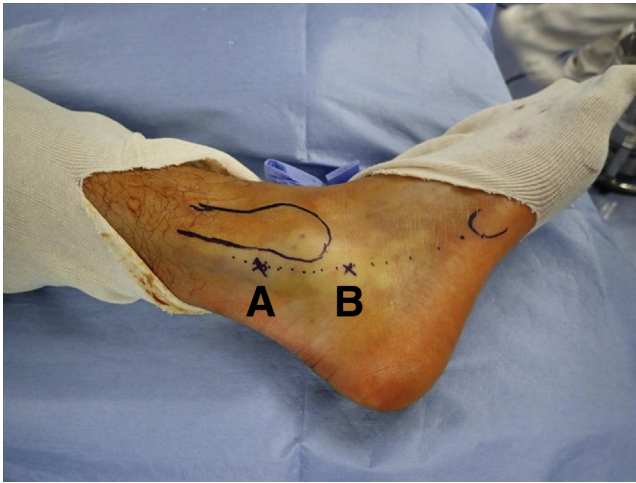
*Address correspondence to Akinobu Nishimura, M.D., Ph.D., Department of Orthopaedic and Sports Medicine, Graduate School of Medicine, Mie*

*University, 2-174 Edobashi, Tsu, Mie 514-8507, Japan. E-mail: [meiten@med.mie-u.ac.jp](mailto:meiten@med.mie-u.ac.jp)*

© 2022 THE AUTHORS. Published by Elsevier Inc. on behalf of the Arthroscopy Association of North America. This is an open access article under the CC BY-NC-ND license (<http://creativecommons.org/licenses/by-nc-nd/4.0/>).

2212-6287/22175

<https://doi.org/10.1016/j.eats.2022.03.028>



**Fig 1.** Tenoscopy portal positions. The patient is placed in the lateral decubitus position with the surgery side facing up. The proximal portal (A) is placed 2 fingerbreadths proximal to the lateral malleolus tip and the distal portal (B) is placed one fingerbreadth proximal to the lateral malleolus tip.

FL) and an irrigation fluid management system (Continuous Wave II Arthroscopy Pump; Arthrex) for this procedure. Before the skin incision is made, the position of the peroneal tendons is checked by ultrasonography, and some irrigation solution is injected

into the peroneal tendon sheath under ultrasonography. A distal portal is created under arthroscopic transillumination guidance. This surgical procedure consists of 8 steps: (1) Standard tenoscopic examination, (2) debridement of the pseudo-pouch base, (3) first anchor insertion, (4) suture relay, (5) second anchor insertion and suture relay, (6) third anchor insertion and suture relay, (7) tightening of sutures, and (8) suture bridge. Each step has pearls and pitfalls (Table 1).

### Standard Tenoscopic Examination

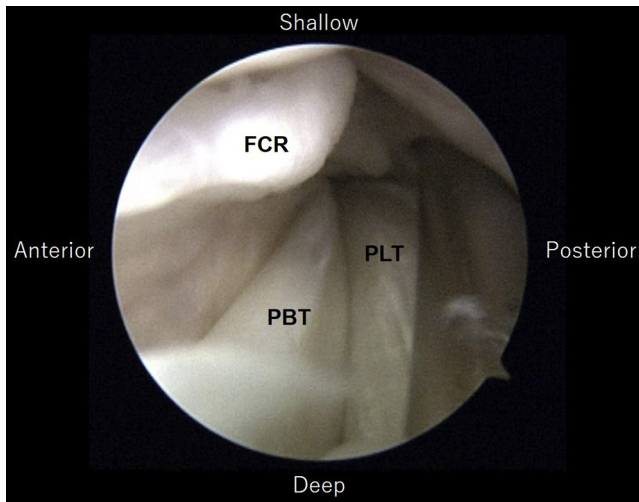
A standard tenoscopic examination is performed. The peroneal tendons and intrasheath pseudo-cavity are visible, and the peroneal tendons are checked with the probe. The condition of the fibrocartilaginous ridge is also checked (Fig 2). In patients with tenosynovitis, tenosynovectomy is performed using arthroscopic shaver.

### Debridement of the Base of the Pseudo-pouch

The lateral surface of the lateral malleolus, which is the base of the pseudo-pouch, is cleaned with a shaver and/or a radiofrequency device and slightly roughened with an arthroscopic shaver and/or burr (Fig 3).

**Table 1.** Surgical Steps, Pearls, and Pitfalls

Surgical Steps	Pearls	Pitfalls
Tendoscope insertion and portal making	Using ultrasonography makes it easier to introduce the tendoscope. A second portal (distal portal) is made under arthroscopic transillumination guidance.	Poor portal positions make it difficult to observe and sometimes destroy the tendon and/or retinaculum.
Debridement of the base of the pseudo-pouch	The lateral surface of the lateral malleolus under the pseudo-pouch is slightly roughened with an arthroscopic shaver and/or a burr until the cancellous bone is slightly exposed.	Insufficient debridement may not result in adhesion between the lateral surface of the lateral malleolus bone and superior peroneal retinaculum. Too much debridement may worsen anchor fixations.
Suture anchor insertion	Suture anchors are inserted into the fibula bone adjacent to the fibrocartilaginous ridge. Pulling the suture allows confirmation that the suture anchors are inserted tightly into the bone.	Shallow insertions of the suture anchor can easily slip out from bone. Anchor insertions into the fibula away from the fibrocartilaginous ridge may result in re-dislocation.
Suture relay	The 18-G needle with a 2-0 nylon loop is inserted through the superior peroneal retinaculum and the skin just over peroneal tendons.	If the retinaculum covering is too tight, the patient may feel discomfort after the operation. If the retinaculum covering is too loose, there is a risk of redislocation.
Tightening of the sutures	The shuttling suture loops and shuttling sutures are picked up subcutaneously not to catch the sural nerve. The threads are picked up one by one subcutaneously and tightened one by one to prevent entanglement.	Pulling up all the threads subcutaneously together increases the risk of entanglement. In cases of poor bone quality, the anchors may be pulled out from the bone when the thread is tightened.
Suture bridge	A drill for an anchor of suture bridge is inserted into the fibula from the distal side at a 45° angle. The anchor is inserted into the fibula bone with the threads which have desired tension.	Without a careful check of the drill hole for the knotless suture anchor for the suture bridge, the anchor may insert incorrectly.



**Fig 2.** Tendoscopic view from the proximal portal. The peroneal tendons and intrasheath pseudo-cavity are visible, and the peroneal tendons and the fibrous cartilaginous ridge are checked with the probe. (FCR, fibrous cartilaginous ridge; PBT, peroneal brevis tendon; PLT, peroneal longus tendon.)

### First Anchor Insertion

The first anchor (1.8-mm Knotless FiberTak Soft Anchor; Arthrex) is inserted into the distal fibula ridge through the distal portal (Fig 4). The insertion point is immediately adjacent to the fibrous cartilaginous ridge. The suture is pulled tight to ensure that the suture anchors are inserted tightly into the lateral malleolus. This anchor is loaded with 3 sutures: a repair suture, a shuttling suture loop, and a shuttling suture.

### Suture Relay

An 18-gauge needle, into which a shuttle relay is looped (No. 2-0 PROLENE; Johnson & Johnson, Tokyo, Japan), is used as a suture lasso. This needle complex penetrates the superior peroneal retinaculum (SPR) through the skin (Fig 5). The loop and 3 sutures of the first anchor are picked up with a grasper and pulled out through the portal. The sutures are placed into the nylon loop outside the skin. Thereafter, the opposite end of the nylon loop is pulled out through the portal. This allows all the sutures of the anchor to penetrate the SPR.

### Second Anchor Insertion and Suture Relay

The second knotless anchor is inserted via the proximal portal. The position of the second anchor insertion is approximately 1.0 to 1.5 cm proximal to the first anchor. The suture relay is performed as explained in Step 4.

### Third Anchor Insertion And Suture Relay

The third knotless anchor is inserted via the proximal portal. The position of the third anchor insertion is approximately 1.0-1.5 cm proximal to the second

anchor. The suture relay is also performed as indicated in Step 4. Three passes and 9 threads penetrate the SPR and skin after this step (Fig 6).

### Tightening the Sutures

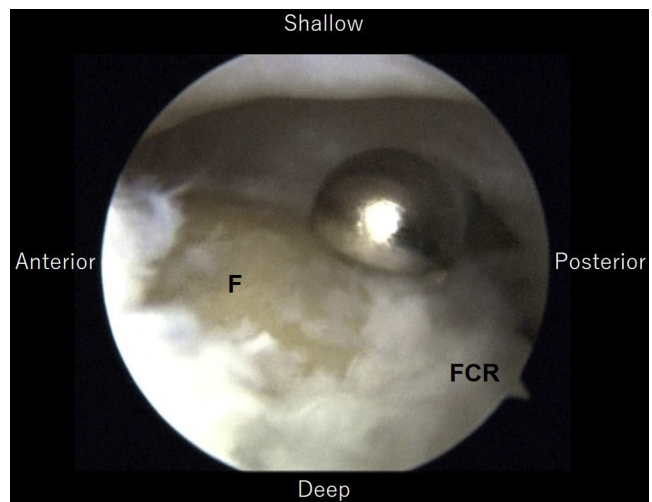
The repair suture of the first anchor and shuttling suture loop and shuttling suture from the second anchor are picked up subcutaneously through the proximal portal. The repair suture is inserted into the shuttle suture loop, and the shuttling suture of the second anchor is pulled to pass the repair suture through the second anchor (Fig 7A). The repair anchor of the first anchor is tightened by pulling it.

The repair suture of the second anchor and shuttling suture loop and shuttling suture from the third anchor are retrieved subcutaneously via the proximal portal. The repair suture is inserted into the shuttle suture loop. In addition, the shuttling suture of the third anchor is pulled to pass the repair suture through the third anchor (Fig 7B). The repair anchor of the second anchor is tightened by pulling it.

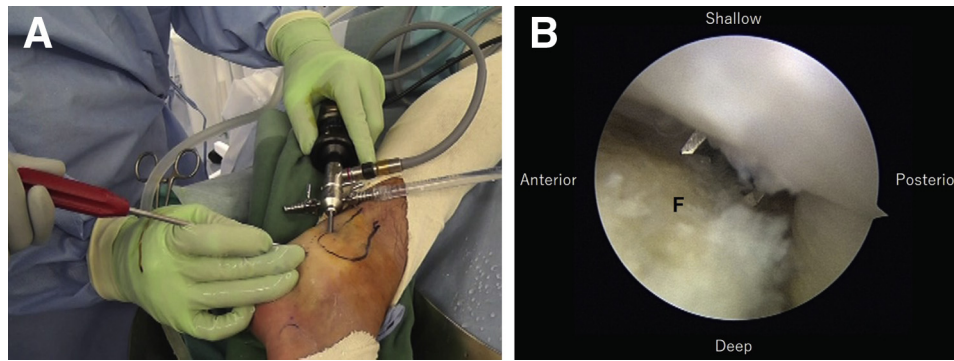
The repair suture of the third anchor and shuttling suture loop and shuttling suture from the first anchor are retrieved subcutaneously through the distal portal. The repair suture is inserted into the shuttle suture loop, and the shuttling suture of the first anchor is pulled to pass the repair suture through the first anchor (Fig 7C). The repair anchor of the third anchor is tightened by pulling it (Fig 7D).

### Suture Bridge

An additional skin incision is made on the lateral malleolus for the suture bridge technique. A drill for a short 2.9-mm PushLock knotless anchor (Arthrex) is inserted into the fibula through the distal side at an



**Fig 3.** Roughing of lateral surface of fibula under superior peroneal retinaculum. The lateral surface of the fibula under a pseudo-pouch is slightly roughened with an arthroscopic shaver or burr. ((F, fibula; FCR, fibrous cartilaginous ridge.)



**Fig 4.** First anchor insertion. Knotless suture anchors (1.8-mm Knotless Fiber Tak) are inserted into the fibula next to the fibrocartilaginous ridge through the portals. (A) Macroscopic finding, and (B) tendonoscopic viewing. (F, fibula.)

angle of 45° (Fig 8). All anchor threads are picked up subcutaneously (the layer above the SPR). These are passed into the eyelet of the anchor that is brought to the top edge of the drill hole. The threads are pulled to the desired tension and are marked at the level of the black laser line on the anchor. Then, the anchor is pulled back, and the eyelet is placed at a marked point on the thread. Finally, the anchor is inserted into the fibula. After the final anchor is correctly inserted, the remnant thread tails are cut with a suture cutter (Fig 9).

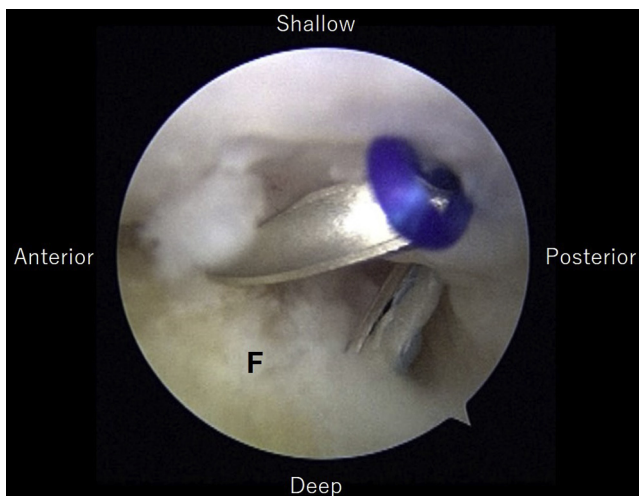
### Postoperative Rehabilitation

A below-knee cast is used for 3 weeks after surgery. A non-weight-bearing cast is used for the first half of the cast period, and a weight-bearing cast with heel is used for the second half of the cast period. The sutures are removed after approximately 10 days. After the cast is removed, ankle range of motion, proprioception, and

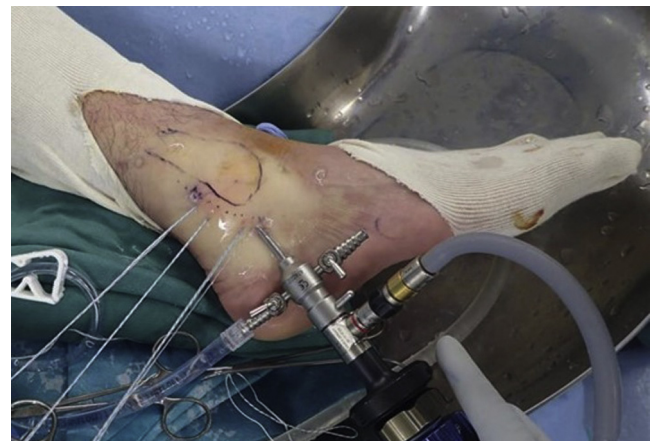strengthening training are initiated. If there is no swelling or pain, jogging is permitted at 6 weeks after surgery. Return to full sports activity is permitted approximately 12 weeks after the operation.

### Discussion

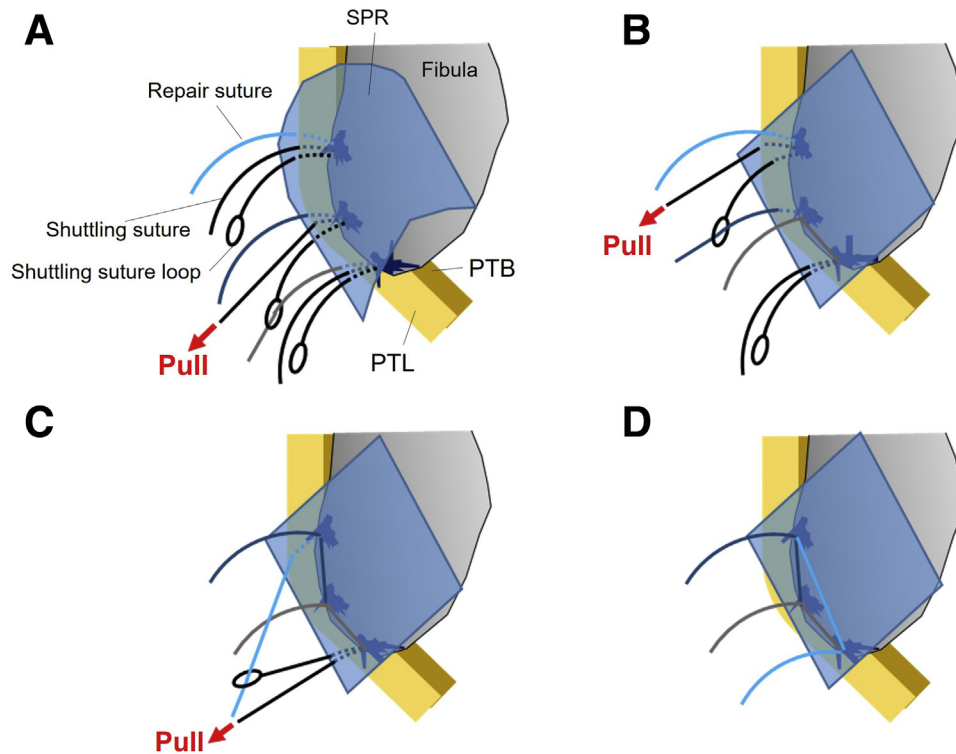
Endoscopic surgery has more advantages than open procedures in many areas. In general, tendoscopy also has some advantages in terms of less postoperative pain, fewer complications, and same-day surgery performance (Table 2).<sup>9</sup> A similar procedure to tendoscopic surgery for RPTD was reported to enable earlier return to sports activity than in open procedure.<sup>10</sup> Moreover, peroneal tendons have some variations and abnormalities, such as low-lying peroneal brevis muscle belly, peroneus quartus, tenosynovitis, and longitudinal tear of the peroneal brevis muscle belly. Furthermore, RPTDs often occur combined with these variations and abnormalities. Peroneal tendoscopy led us to assess intrasheath pathology without cutting the SPR. We also



**Fig 5.** Shuttle relay. An 18-gauge needle, into which a shuttle relay is looped (No. 2-0 PROLENE; Johnson & Johnson, Tokyo, Japan), is used as a suture lasso to thread through the skin and the superior peroneal retinaculum. (F, fibula.)



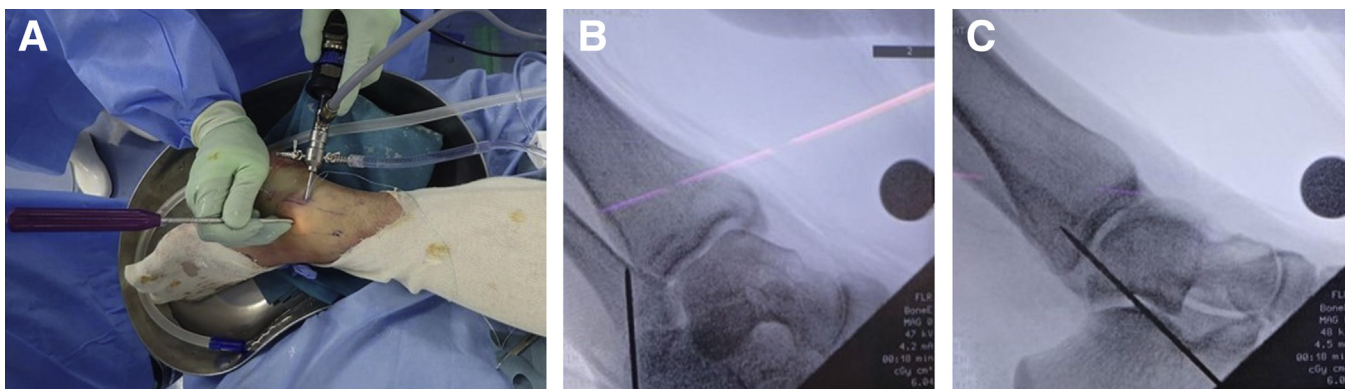
**Fig 6.** Macroscopic finding after 3 anchor insertions. Three passes and 9 threads penetrated the superior peroneal retinaculum and skin.



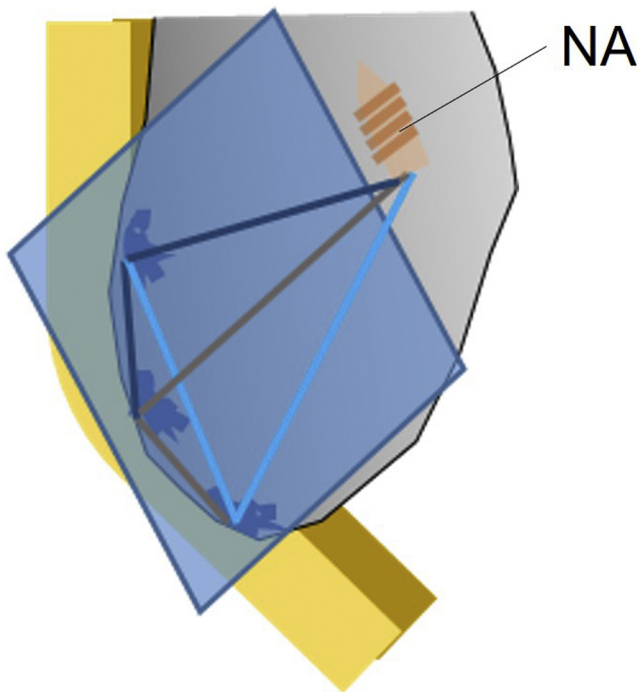
**Fig 7.** Schema of knotless tendoscopic peroneal retinaculum repair technique. (A) Sutures of the 3 anchors penetrate the superior peroneal retinaculum respectively. The repair suture of the first anchor is inserted into the shuttle suture loop of the second anchor, and the shuttling suture of the second anchor is pulled to pass the repair suture through the second anchor. The repair anchor of the first anchor is tightened by pulling it. (B) The repair suture of the second anchor is inserted into the shuttle suture loop of the third anchor, and the shuttling suture of the third anchor is pulled to pass the repair suture through the third anchor. The repair anchor of the second anchor is tightened by pulling it. (C) The repair suture of the third anchor is inserted into the shuttle suture loop of the first anchor, and the shuttling suture of the first anchor is pulled to pass the repair suture through the first anchor. The repair anchor of the third anchor is tightened by pulling it. (D) This figure shows the schema after all sutures are tightened. (PBT, peroneal brevis tendon; PLT, peroneal longus tendon; SPR, superior peroneal retinaculum.)

performed synovectomy of the peroneal tenosynovitis and resection of the peroneus quartus tendon and/or of the low-lying peroneal brevis muscle belly using a tendoscope. Tendoscopic repair for longitudinal tear of

the peroneal tendon may be possible if the surgeon is an expert in arthroscopy and the tear size is small. Otherwise, conversion from tendoscopic surgery to conventional open one is easy because surgical position



**Fig 8.** Drilling for suture bridge. An additional skin incision is made on the lateral malleolus for the suture bridge technique. A drill for a knotless anchor is inserted into the fibula through the distal side at an angle of 45°. (A) Macroscopic finding, (B) fluoroscopic images, anteroposterior view, and (C) medial–lateral view.



**Fig 9.** The schema of completed tendoscopic surgery. (NA, knotless anchor.)

is the same between the 2 (lateral decubitus position). For these reasons, peroneal tendoscopy is useful.

The knots of the anchors in more conventional techniques can cause problems. Knot irritation sometimes occurs, especially in thin subcutaneous fat areas. In shoulder arthroscopy, knot impingement is a complication after arthroscopic surgery. Hotta and Yamashita<sup>11</sup> reported that osteolysis in the inferior surface of the acromion appeared to have been caused by knot impingement of the suture thread. To avoid these problems, knotless anchors are used in many areas.<sup>12-14</sup> This procedure is a knotless technique. Thus, it can eliminate the challenges of knots.

Koga et al.<sup>15</sup> reported medial meniscus centralization using knotless FiberTak anchors for extrusion of the

medial meniscus. We mimicked this technique for RPTD. Our knotless technique has several advantages over many conventional techniques. Our technique is a suture bridge technique. Thus, the contact area is wider than that in the conventional single row technique. Most previous tendoscopic Das De procedures were single row techniques.<sup>5,7,8</sup> In a review paper<sup>16</sup> of arthroscopic rotator cuff repair, suture bridge repair had lower retear rates than single-row repair in most tear-size categories. Biomechanical studies of arthroscopic rotator cuff repair showed that the suture bridge technique had superior mechanical strength and greater contact pressure at the tendon footprint compared with the double-row technique.<sup>17,18</sup> Theoretically, the suture bridge technique is better than single row or double row repair even for RPTD. Nishimura et al.<sup>6</sup> reported a tendoscopic suture bridge technique for PTD. However, this technique requires knot tying. Therefore, knot irritations are a major concern. In addition, the first 3 soft anchors fix a small area (like a point) of the SPR. However, the technique that is presented in this study and consists of the first 3 soft anchors (knotless fiber tak) can fix the SPR as a line. The technique has a greater contact area between the SPR and fibula than previous techniques.

Our technique has some disadvantages (Table 2). First, it is technically demanding. Second, the operation time is longer than that in the conventional open Das De procedure. However, the operative time of our technique may be shorter according to the surgeon's experience. Third, this technique is not indicated for patients with bone fragility. The procedure used a Knotless Fiber Tak, which requires strong pulling of the shuttling sutures. If the patient has bone fragility, the anchors may be pulled out from the bone.

In conclusion, a knotless tendoscopic peroneal retinaculum repair technique for RPTD is described. This procedure requires some training. However, it promotes less knot irritation and more contact area and pressure than previous techniques.

**Table 2.** Advantages and Risks And/or Limitations of the Knotless Tendoscopic Peroneal Retinaculum Repair Technique

Advantages	Risks And/or Limitations
We can more clearly assess the condition of intra-tendon sheath lesions and deal with those lesions endoscopically.	Tendoscopic surgery experience is needed.
The tendoscopic procedure has less postoperative pain and fewer complications for the patient than open procedures. It also can lead to earlier recovery.	This tendoscopic procedure requires a longer operation time than conventional open procedure.
Our suture bridge procedure has a wider contact area between the superior peroneal retinaculum and fibula bone surface than a single row procedure.	In cases of poor bone quality, the anchor may be pulled out when the thread is pulled or tightened.
Our knotless technique does not have knot-related complications such as knot irritation.	Our tendoscopic procedure is not economical because it requires 4 anchors as well as tendoscopic-related equipment.
The tendoscopic procedure has better cosmesis than open procedures.	

## Acknowledgments

The authors thank Forte for English-language editing.

## References

1. Davda K, Malhotra K, O'Donnell P, Singh D, Cullen N. Peroneal tendon disorders. *EFORT Open Rev* 2017;2: 281-292.
2. Lugo-Pico JG, Kaiser JT, Sanchez RA, Aiyer AA. Peroneal tendinosis and subluxation. *Clin Sports Med* 2020;39: 845-858.
3. Bakker D, Schulte JB, Meuffels DE, Piscaer TM. Non-operative treatment of peroneal tendon dislocations: A systematic review. *J Orthop* 2020;18:255-260.
4. Das De S, Balasubramaniam P. A repair operation for recurrent dislocation of peroneal tendons. *J Bone Joint Surg Br* 1985;67:585-587.
5. Miyamoto W, Takao M, Miki S, Giza E. Tendoscopic repair of the superior peroneal retinaculum via 2 portals for peroneal tendon instability. *Foot Ankle Int* 2015;36: 1243-1250.
6. Nishimura A, Nakazora S, Ito N, Fukuda A, Kato K, Sudo A. Tendoscopic double-row suture bridge peroneal retinaculum repair for recurrent dislocation of peroneal tendons in the ankle. *Arthrosc Tech* 2016;5:e441-e446.
7. Lui TH. Endoscopic peroneal retinaculum reconstruction. *Knee Surg Sports Traumatol Arthrosc* 2006;14:478-481.
8. Guillo S, Calder JD. Treatment of recurring peroneal tendon subluxation in athletes: Endoscopic repair of the retinaculum. *Foot Ankle Clin* 2013;18:293-300.
9. Montegudo M, Maceira E, Martinez de Albornoz P. Foot and ankle tendoscopies: Current concepts review. *EFORT Open Rev* 2016;1:440-447.
10. Nishimura A, Kato K, Nakazora S, Senga Y, Fukuda A, Sudo A. Tendoscopic peroneal retinaculum repair for recurrent peroneal tendon dislocation enables earlier return to sports than the open procedure. *Knee Surg Sports Traumatol Arthrosc* 2020;28:3318-3323.
11. Hotta T, Yamashita T. Osteolysis of the inferior surface of the acromion caused by knots of the suture thread after rotator cuff repair surgery: Knot impingement after rotator cuff repair. *J Shoulder Elbow Surg* 2010;19: e17-e23.
12. Goldenberg NB, Nuelle CW. Knotless suture anchor fixation of a traumatic osteochondral lesion of the lateral femoral condyle. *Arthrosc Tech* 2021;10:e2547-e2551.
13. Freisleder F, Scheibel M. Arthroscopic knotless-anchor rotator cuff repair. *JBJS Essent Surg Tech* 2020;10(3).
14. Hug K, Gerhardt C, Haneveld H, Scheibel M. Arthroscopic knotless-anchor rotator cuff repair: A clinical and radiological evaluation. *Knee Surg Sports Traumatol Arthrosc* 2015;23:2628-2634.
15. Koga H, Nakamura T, Nakagawa Y, et al. Arthroscopic centralization using knotless anchors for extruded medial meniscus. *Arthrosc Tech* 2021;10:e639-e645.
16. Hein J, Reilly JM, Chae J, Maerz T, Anderson K. Retear rates after arthroscopic single-row, double-row, and suture bridge rotator cuff repair at a minimum of 1 year of imaging follow-up: A systematic review. *Arthroscopy* 2015;31:2274-2281.
17. Park MC, ElAttrache NS, Tibone JE, Ahmad CS, Jun BJ, Lee TQ. Part I: Footprint contact characteristics for a transosseous-equivalent rotator cuff repair technique compared with a double-row repair technique. *J Shoulder Elbow Surg* 2007;16:461-468.
18. Park MC, Tibone JE, ElAttrache NS, Ahmad CS, Jun BJ, Lee TQ. Part II: Biomechanical assessment for a footprint-restoring transosseous-equivalent rotator cuff repair technique compared with a double-row repair technique. *J Shoulder Elbow Surg* 2007;16:469-476.