



## Case report

# Antiphospholipid syndrome presenting with amaurosis fugax and cotton wool spots



Kimberly D. Tran, Sarah P. Read, Nimesh A. Patel, Harry W. Flynn Jr. <sup>\*</sup>, Norman J. Schatz

Department of Ophthalmology, Bascom Palmer Eye Institute, University of Miami Miller School of Medicine, Miami, FL, United States

## ARTICLE INFO

## Article history:

Received 19 January 2017

Received in revised form

28 June 2017

Accepted 6 July 2017

Available online 8 July 2017

## Keywords:

Antiphospholipid syndrome

Cotton wool spots

Amaurosis fugax

## ABSTRACT

**Purpose:** To describe the importance of considering vaso-occlusive disease on the differential diagnosis of a patient presenting with amaurosis fugax (AF) and unilateral cotton wool spots (CWS).

**Observations:** A 69-year-old female with history of obesity, hyperlipidemia and recent orthopedic surgery, presented with 3 days of worsening monocular AF and CWS in the right eye. She was diagnosed with antiphospholipid syndrome based on positive serologic testing for antiphosphatidylserine IgM, anticardiolipin IgM. The patient was treated with lipid lowering medication, long-term aspirin, and has followed a weightloss and physical therapy program under medical supervision. The CWS resolved and AF symptoms have not recurred.

**Conclusions and importance:** Antiphospholipid syndrome can be considered in the differential diagnosis of patients presenting with AF, assymmetric CWS, and/or rapid progression of symptoms.

© 2017 The Authors. Published by Elsevier Inc. This is an open access article under the CC BY-NC-ND license (<http://creativecommons.org/licenses/by-nc-nd/4.0/>).

## 1. Introduction

Retinal artery occlusive disease can be associated with life-threatening systemic disorders that warrant urgent thromboembolic and serologic evaluation. Cotton wool spots (CWS), in contrast, are nonspecific and may often be underappreciated. In the differential diagnosis of new onset CWS, a number of systemic diseases can be considered in addition to more common disorders such as diabetic and hypertensive retinopathy. Antiphospholipid syndrome (APS) can be considered in the differential diagnosis of CWS and medical evaluation can confirm the diagnosis and reduce the potential for further retinal changes.

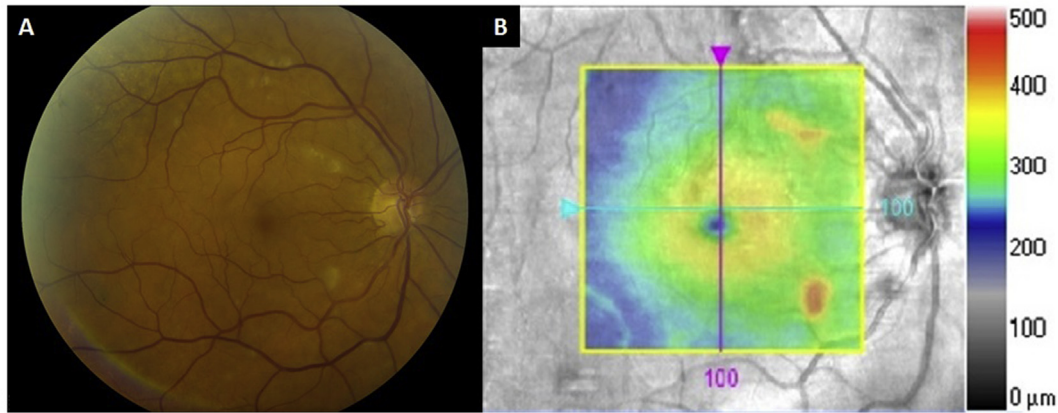
## 2. Case report

A 69-year-old female with history of obesity, hyperlipidemia presented with 3 days of worsening monocular transient visual obscurations, best corrected visual acuity (BCVA) 20/30, and CWS in the right eye (Fig. 1). The left eye exam was normal with BCVA 20/20. She had a history of orthopedic Achilles tendon surgery and post-operative immobilization 3 days prior to the onset of her symptoms. She had no known prior ocular disease, no smoking

history, and she was not on hormone therapy. Her review of systems and physical examination were otherwise noncontributory.

The rapid progression of her symptoms and asymmetric finding of CWS was concerning for an acute ischemic process in the right eye. The patient was admitted for urgent thromboembolic and serologic workup. A brain MRI was negative. CT angiogram and MR angiogram of the neck were negative for stenosis, dissection, or plaque. Echocardiogram and electrocardiogram were negative for embolic source, valvular abnormality, patent foramen ovale or cardiac arrhythmia. Erythrocyte sedimentation rate (ESR) and C-reactive protein (CRP) were normal (Table 1). Further serologic workup showed elevated total cholesterol, elevated triglycerides, elevated lipoprotein (a), positive lupus anticoagulant, positive antiphosphatidylserine IgM antibody, positive anticardiolipin IgM antibody, elevated homocysteine, and elevated antithrombin activity (Table). Testing for hemoglobin A1c, PT/INR, aPTT, thrombin time, fibrinogen level, platelet function test, protein S and C antigens, antithrombin III deficiency, activated protein C resistance, prothrombin and factor V Leiden mutations, and beta-2 glycoprotein 1 antibodies were within normal limits. On repeat testing, homocysteine, antiphosphatidylserine IgM antibody, anticardiolipin IgM remained elevated (Table). Lupus anticoagulant was negative on repeat testing. She was diagnosed with APS and treated with antiplatelet therapy. Her BCVA returned to 20/20 in both eyes and the CWS resolved (Fig. 2). She has continued physical therapy

<sup>\*</sup> Corresponding author. 900 NW 17th St., Miami, FL 33136, United States.  
E-mail address: [hflynn@med.miami.edu](mailto:hflynn@med.miami.edu) (H.W. Flynn).



**Fig. 1.** (A) Color fundus photograph of the right eye demonstrating unilateral cotton wool spots. (B) Optical coherence tomography macular thickness map shows retinal thickening in areas of cotton wool spots (orange/yellow). (For interpretation of the references to colour in this figure legend, the reader is referred to the web version of this article.)

**Table 1**  
Serologic values in patient with amaurosis fugax.

Test	Value	Interpretation	Repeat Value	Interpretation
Erythrocyte sedimentation rate	9 mm/hr	Within reference range	—	—
C-reactive protein	<0.1 mg/dL	Within reference range	—	—
Total cholesterol	240 mg/dL	High	—	—
Triglycerides	217 mg/dL	High	—	—
High-density lipoprotein	60 mg/dL	Low	—	—
Low-density lipoprotein	136 mg/dL	Within reference range	—	—
Lipoprotein (a)	158 nmol/L	High	—	—
Lupus anticoagulant	—	Positive	—	Negative
Antiphosphatidylserine IgM antibody	43 U/mL	Positive	43 U/mL	Positive
Anticardiolipin IgM antibody	11.5 MPL U/mL	Positive	17 MPL U/mL	Positive
Homocysteine	12.8 μmol/L	High	15.5 μmol/L	High
Antithrombin activity	119%	High	—	—

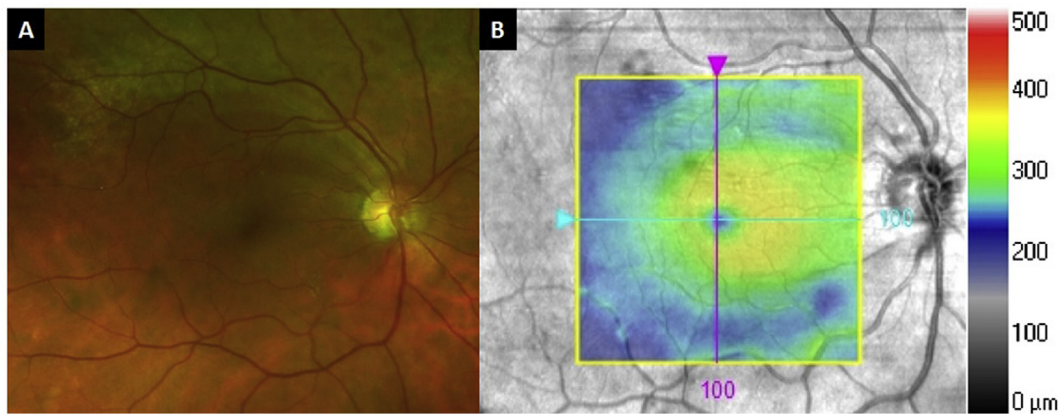
and mobility training under medical supervision after her Achilles tendon surgery.

**3. Discussion**

CWS represent the occlusion of the terminal retinal capillaries in the nerve fiber and ganglion cell layer leading to acute focal inner retinal ischemia and infarction. CWS are nonspecific, and have been described in a variety of diseases including hypertensive and

diabetic retinopathy. Given their prevalence, CWS may be underappreciated in early stages of retinal occlusive disease and may not trigger the comprehensive workup they merit. The distinguishing features in this case that led to an urgent systemic evaluation were amaurosis fugax (AF), unilateral CWS, and rapid progression of symptoms.

Amaurosis fugax (AF) is painless transient vision loss that can be of embolic or hemodynamic origin as in thrombotic disease, vasculitis, and impaired retinal perfusion,<sup>1</sup> ocular origin as in



**Fig. 2.** (A) Follow-up color fundus photograph of the right eye demonstrating resolution of cotton wool spots. (B) Optical coherence tomography macular thickness map at follow-up shows retinal thinning in areas of previous cotton wool spots (blue dimples). (For interpretation of the references to colour in this figure legend, the reader is referred to the web version of this article.)

increased intraocular pressure or optic disc drusen, or neurologic origin as in migraine or optic nerve edema. The prevalence of AF prior to CRAO, BRAO, and vision loss due to GCA has been reported as high as 12.2%, 15.4%, and 31% respectively.<sup>2–4</sup> Thus, in the absence of obvious ocular or neurologic contributors, a retinal vaso-occlusive disorder due to embolic or hemodynamic disease was highly suspected in this case. Hypercoagulable testing was pursued, and carotid ultrasound, echocardiogram, and electrocardiogram were performed to rule out embolic source. Additionally, in a prior series of 170 patients with temporal artery biopsy (TAB) - confirmed GCA, 72.4% had CWS, and 21% of patients had no systemic symptoms.<sup>3,4</sup> Thus, ESR and CRP were drawn to rule out GCA despite the fact that the patient did not complain of any GCA-related symptoms.

Cotton wool spots and amaurosis fugax have been previously reported as ocular manifestations of APS.<sup>5–10</sup> The occurrence of isolated cotton wool spots together with AF, even in the absence of related systemic manifestations, requires one to investigate APS.

APS is a multisystem autoimmune condition characterized by vascular thromboses or pregnancy loss associated with persistently positive antiphospholipid antibodies (aPL).<sup>11</sup> The prevalence of APS has been reported to be approximately 40–50 cases per 100,000 persons. When untreated, APS is associated with increased risk of stroke, myocardial infarction, pulmonary embolus, and multiorgan thromboses. Treatment of APS includes appropriate anticoagulant and antiplatelet therapy, and patients may require antithrombotic prophylaxis prior to prothrombotic procedures.<sup>12</sup> Of note, the patient in this case did have high plasma total homocysteine levels which are associated with increased risk of atherosclerotic disease and may have additionally predisposed her to an ischemic event.<sup>13</sup>

#### 4. Conclusions

CWS are a prevalent, often underappreciated finding. While it is neither practical nor cost-effective to submit all patients with CWS to an extensive hypercoagulable and thromboembolic workup, in cases with AF, asymmetric CWS, and/or rapid progression of symptoms, vaso-occlusive disease should be considered on the differential diagnosis, and appropriate and timely comprehensive workup pursued.

#### Patient consent

The patient consented to publication of the case orally, and this report does not contain any personal information that could lead to the identification of the patient.

#### Acknowledgements and disclosures

##### Funding

Supported in part by NIH Center Core Grant P30EY014801 and Research to Prevent Blindness Unrestricted Grant.

##### Conflicts of interest

The authors have no financial or proprietary interest in the materials presented herein. The following authors have no financial disclosures: KDT, SPR, NAP, HWF, NJS.

##### Authorship

All authors attest that they meet the current ICMJE criteria for Authorship.

##### Acknowledgements

None.

#### References

1. Pula JH, Kwan K, Yuen CA, Kattah JC. Update on the evaluation of transient vision loss. *Clin Ophthalmol*. 2016;10:297–303.
2. Hayreh SS, Zimmerman MB. Amaurosis fugax in ocular vascular occlusive disorders: prevalence and pathogenesis. *Retina*. 2014;34(1):115–122.
3. Hayreh SS, Podhajsky PA, Zimmerman B. Ocular manifestations of giant cell arteritis. *Am J Ophthalmol*. 1998;125(4):509–520.
4. Hayreh SS, Podhajsky PA, Zimmerman B. Occult giant cell arteritis: ocular manifestations. *Am J Ophthalmol*. 1998;125(4):521–526.
5. Arf S, Sayman Muslubas I, Hocaoglu M, Karacorlu M. Retinal deep capillary plexus ischemia in a case with antiphospholipid syndrome. *Retin Cases Brief Rep*. 2016;0:1–5.
6. Dori D, Gelfand YA, Brenner B, Miller B. Cilioretinal artery occlusion: an ocular complication of primary antiphospholipid syndrome. *Retina*. 1997;17(6):555–557.
7. Sebrow DB, Jung JJ, Horowitz J, Odel JG, Freund KB. Macular perivenous retinal whitening and presumed retino-ciliary sparing in a recurrent central retinal vein occlusion associated with the antiphospholipid syndrome and cryoglobulinemia. *Retin Cases Brief Rep*. 2016;0:1–7.
8. Wiechens B, Schröder JO, Pötzsch B, Rochels R. Primary antiphospholipid antibody syndrome and retinal occlusive vasculopathy. *Am J Ophthalmol*. 1997;123(6):848–850.
9. Leo-Kottler B, Klein R, Berg PA, Zrenner E. Ocular symptoms in association with antiphospholipid antibodies. *Graefes Arch Clin Exp Ophthalmol*. 1998;236(9):658–668.
10. Suvajac G, Stojanovich L, Milenkovich S. Ocular manifestations in antiphospholipid syndrome. *Autoimmun Rev*. 2007;6(6):409–414.
11. Miyakis S, Lockshin MD, Atsumi T, et al. International consensus statement on an update of the classification criteria for definite antiphospholipid syndrome (APS). *J Thromb Haemost*. 2006;4(2):295–306.
12. Gómez-Puerta JA, Cervera R. Diagnosis and classification of the antiphospholipid syndrome. *J Autoimmun*. 2014;48–49:20–25.
13. Martí-Carvajal AJ, Solà I, Lathyris D. Homocysteine-lowering interventions for preventing cardiovascular events. *Cochrane Database Syst Rev*. 2015;1:CD006612.