

Case Report

# *Escherichia coli* Panophthalmitis after Pecking by a Great Egret (*Ardea alba*)

Takashi Ono<sup>a, b</sup> Kentaro Abe<sup>a</sup> Yosai Mori<sup>a</sup> Ryohei Nejima<sup>a</sup>  
Takuya Iwasaki<sup>a</sup> Makoto Aihara<sup>b</sup> Kazunori Miyata<sup>a</sup>

<sup>a</sup>Department of Ophthalmology, Miyata Eye Hospital, Miyazaki, Japan; <sup>b</sup>Department of Ophthalmology, Graduate School of Medicine, The University of Tokyo, Tokyo, Japan

## Keywords

Bird injury · Ocular trauma · Panophthalmitis · *Ardea alba* · Eye evisceration

## Abstract

We report a case of open globe injury caused by *Ardea alba* pecking that resulted in *Escherichia coli* panophthalmitis. A woman in her 70s complaining of ocular pain was referred to our hospital because her right eye had been pecked by an *A. alba* 2 days earlier. Visual acuity in her right eye was reduced to light sensation. The right conjunctiva became hyperemic and edematous with swelling of the right upper eyelid. The upper side of the right cornea was densely cloudy with focal defect. Ultrasonography showed a thick sclera and choroid-like structure. Pathological investigation of a scraped sample from the infected site revealed gram-negative rods; *E. coli* was isolated. She had fever with elevated serum C-reactive protein levels and leukocytosis confirmed by laboratory examination. Topical levofloxacin and cefmenoxime and intravenous fosfomycin and aspoxicillin were initiated, but the right cornea melted near the perforated site with leakage of the eyeball contents on the next day. We decided to perform eye evisceration because of difficulty in controlling corneal melting and panophthalmitis. Her general state recovered the day after surgery. Orbital cellulitis improved gradually with normal C-reactive protein levels and white blood cell counts. As ocular injury caused by birds could

become severe and cause ocular infection and visual dysfunction, it is important to exercise caution in the vicinity of wild birds, especially when they are aggressive.

© 2020 The Author(s)  
Published by S. Karger AG, Basel

## Introduction

Ocular injury caused by bird pecking is rarely encountered, primarily in individuals who work or live in exposed environments. Importantly, hard beak pecking has the potential to cause severe visual function impairment [1–6]. Previous reports have shown that various types of birds, such as the sparrow [1], ostrich [2], rooster [7], common myna [3], crane [4], domestic hen [5], bittern [6], and eagle [8], can cause human ocular injuries, such as corneal infiltration, defects, cataract, retinal detachment, and endophthalmitis. Pecking damage is dependent on the injured site, bird size, or their attacking habit, as well as the condition of the wounds, and the clinical outcome may sometimes be poor [5].

*Ardea alba*, a big white bird with a long beak, commonly called a great egret, broadly lives in temperate or tropical areas and is commonly encountered in Japan [9]. Two species are broadly observed in Japan: *A. alba alba*, which migrates to Japan in winter, and *A. alba modesta*, which migrates in the summer. To our knowledge, there have been no reports of ocular injury caused by *A. alba* and its clinical course, probably because such injury is rare. Herein, we report the case of a patient injured by *A. alba* that resulted in corneal perforation and panophthalmitis requiring eye evisceration.

## Case Report

A woman in her 70s complaining of ocular pain was referred to our hospital in April. Two days earlier, she had been poked in her right eye by a great egret coincidentally caught in a net. She gently tried to help the caught bird, but it became aggressive and attacked her. She first consulted a local ophthalmologist and was diagnosed with corneal perforation of the right eye; she proceeded to consult us on the same day.

Her right upper eyelid was severely swollen, and the right visual acuity was light sensation at the time of the visit. The intraocular pressure was unmeasurable. The right conjunctiva became hyperemic and markedly edematous with an amount of discharge (Fig. 1a). There was a hole in the upper side of the right cornea, and it was plugged with the iris. The cornea was densely cloudy with cellular infiltration around the hole with a shallow anterior chamber. Fluorescein staining revealed a corneal epithelial defect but no leakage of aqueous humor from the anterior chamber (Fig. 1b). Edema of the upper eyelid caused difficulty in eye opening. We performed ultrasonographic examination of the right eye and found a thick sclera- and choroid-like structure (Fig. 1c) without retinal or choroidal detachment. Her left eye was intact. Microscopic examination of the smear of the discharge revealed a number of neutrophils and red blood cells with many gram-negative rods.

The patient's body temperature was 37.1°C. Blood pressure was 128/78 mm Hg with regular pulse. Body weight was 48 kg and height was 148 cm. She was a farmer with a history of oophorectomy 5 years earlier. Laboratory examination showed C-reactive protein elevation to 5.9 mg/dL and increase of white blood cells to 17,200/μL with neutrophilia.

She was diagnosed with traumatic panophthalmitis caused by the bird pecking and was admitted to our hospital on the same day, where we started both topical and intravenous

antibiotic treatment as follows: 0.5% topical levofloxacin and 0.5% cefmenoxime instillation every hour, and intravenous fosfomycin 1 g and aspoxicillin 1 g twice a day to broadly cover gram-positive and -negative organisms.

However, her pain persisted even after the antibiotic administration. The cornea became melted around the lacerated site, and the contents of the eyeball, including of the iris, leaked out on the next day (Fig. 2). Additionally, ocular hemorrhage was observed inside the anterior chamber. Because it was difficult to control the corneal melting and panophthalmitis, we decided to perform eye evisceration after obtaining informed consent from the patient and her family. The surgery was performed under retrobulbar anesthesia guided by an anesthesiologist. First, the cornea was removed and the surgical site was washed with gentamycin. The eyeball contents were removed, and the sclera was sutured continuously with 5-0 silk strings. Drainage gauge was inserted, and finally, ofloxacin ointment was instilled. Postoperatively, cefmenoxime and vancomycin instillation were performed every 2 h and ofloxacin ointment was instilled twice a day.

After eye evisceration, the discharge from the drainage gradually decreased and the pain also resolved. The day after the surgery, her body temperature decreased to 36.6°C. *Escherichia coli* was isolated in microbiology. No fungi or other aerobic bacteria were isolated. The isolate was sensitive to levofloxacin, cefmenoxime, and vancomycin in antibiotic sensitivity tests. We continued intravenous antibiotic administration for the treatment of orbital cellulitis. One week later, the drainage gauge was removed and the intravenous antibiotic dosage was decreased to 1 g/day. Blood examination revealed that her C-reactive protein levels were lowered to 0.9 mg/dL, and the white blood cell count was 5,800/ $\mu$ L. No other abnormality was noted on blood examination. Therefore, intravenous antibiotic administration was stopped. No fungi or aerobic bacteria were isolated from the scraped specimen of her right eye. The infection did not affect her left eye, whose visual acuity was 1.5 and intraocular pressure was 7 mm Hg.

## Discussion/Conclusion

Herein, we report the first, to the best of our knowledge, case of ocular injury caused by *A. alba*, which resulted in corneal perforation and panophthalmitis requiring eye evisceration. Ocular injury caused by birds is an uncommon clinical situation but sometimes leads to severe impairment of visual function [1–6]. As birds are often observed flying at a distance from the ground, one may tend to consider that they would not cause injuries; however, birds approach the ground in search of nourishment and may engage in aggressive attacks under certain conditions. A previous report suggested that they often attack the face and eyes of their perceived enemies using their claw or beak [7]. In our case, the patient gently approached the bird, which was caught in a net, to release it and was unfortunately pecked in the eye. The attack site was the pericenter of the cornea; subsequently, the cornea was infected, eventually leading to panophthalmitis. Injury caused by birds whose beak is small or straight, such as of the sparrow, would lead to small corneal perforations [1]. However, injury caused by pecking of large beaks of big birds could cause more severe damage to the cornea. Our case was an example of the latter scenario because *A. alba* is a large bird, with an average height of approximately 100 cm. It catches fish with its sharp and long beak, whose length ranges from 10 to 15 cm.

Al-Sharif and Alkharashi [6] mentioned that ocular injury caused by birds occurs more frequently in children, especially aged 1–12 years, and in males. Other studies have also

reported a high prevalence in children [10]. In contrast, in our case, the patient was female, in her 70s, and worked as a farmer. Children who play outdoors and adults who work outside have high chances of coming in contact with birds and wild animals. Therefore, this case emphasizes the importance of protecting the eyes from unexpected attacks by wild animals with their claws or beaks both for children and adults. Furthermore, ocular injury by birds occurs frequently in the spring because it is the breeding season of birds [6]. Our case occurred in April, which is consistent with this tendency.

The prognosis of ocular injury depends on the cause and the situation. Tabatabaei et al. [5] reported that the visual acuity on first consultation is related to the final visual acuity. In the current case, the right eye detected only light sensation, and eye evisceration was finally required. Traumatic cataract or aniridia may also be present, and the iris was injured in the current case, but cataract was not evaluated in detail because of corneal opacity. In this case, open-globe injury was observed in zone 1, as defined in the report of the Ocular Trauma Classification Group [11]; injuries in this zone are the ones most frequently observed [5]. The perforated site was relatively limited, and aqueous humor leakage was not observed because the iris was plugged in the corneal hole at the initial presentation. We considered that a bandage contact lens could have led to exacerbation of the ocular infection and selected to observe without using a bandage contact lens in this case. However, corneal melting, combined with ocular infection, progressed and the contents leaked out.

Essex et al. [12] reported that endophthalmitis occurs in 6.8% of patients after ocular trauma. Posttraumatic endophthalmitis is associated with infected wounds, delay in primary repair, and ruptured lens capsule [12]. In our case, we observed that the wound was infected, and treatment was initiated with a delay of 2 days. We did not confirm whether the lens capsule was intact, but considering the leakage of contents from the eye, we speculate that the lens must have been injured. Baskaran et al. [4] reported that the cause of bacterial endophthalmitis after bird pecking was gram-positive cocci. Conversely, we encountered gram-negative *E. coli* in our case. Coagulase-negative staphylococci, *Bacillus* species, streptococci, gram-negative bacilli, and fungi have been reported as causative organisms of posttraumatic endophthalmitis [13]. *E. coli* endophthalmitis is rare, reportedly occurring in 6.4% of posttraumatic endophthalmitis cases [14]. Extended-spectrum  $\beta$ -lactamases produced by *E. coli* could cause severe panophthalmitis with poor prognosis [15]. Therefore, it is important to select specific antibiotics after treatment with broad-spectrum antibiotics. In the current case, we opted for treatment with topical levofloxacin and cefmenoxime with intravenous fosfomycin and aspicillin, and the causative bacteria, *E. coli*, were found to be sensitive to these antibiotics, probably because *E. coli* derived from wild animals are rarely exposed to antibiotics. However, panophthalmitis acutely progressed after ocular injury, and the corneal melting and panophthalmitis could not be controlled. Because it is difficult to anticipate whether microorganisms, such as bacteria or fungi, will cause panophthalmitis after ocular injury caused by wild animals, we should immediately perform examinations to the extent possible, including microscopic examinations and cultures, and seek antibiotic sensitivity confirmation with consideration of the clinical presentation.

In conclusion, we reported an ocular perforating injury resulting in panophthalmitis after pecking by *A. alba*. It is important to assess the traumatic condition and initiate antibiotic treatment as soon as possible because the condition could progress to severe ocular infection leading to irreversible impairment of visual function. Additionally, caution must be exercised in the vicinity of wild birds, especially when they are aggressive.

## Statement of Ethics

Written informed consent was obtained from the patient.

## Conflict of Interest Statement

The authors have no conflicts of interest to declare regarding this article.

## Funding Sources

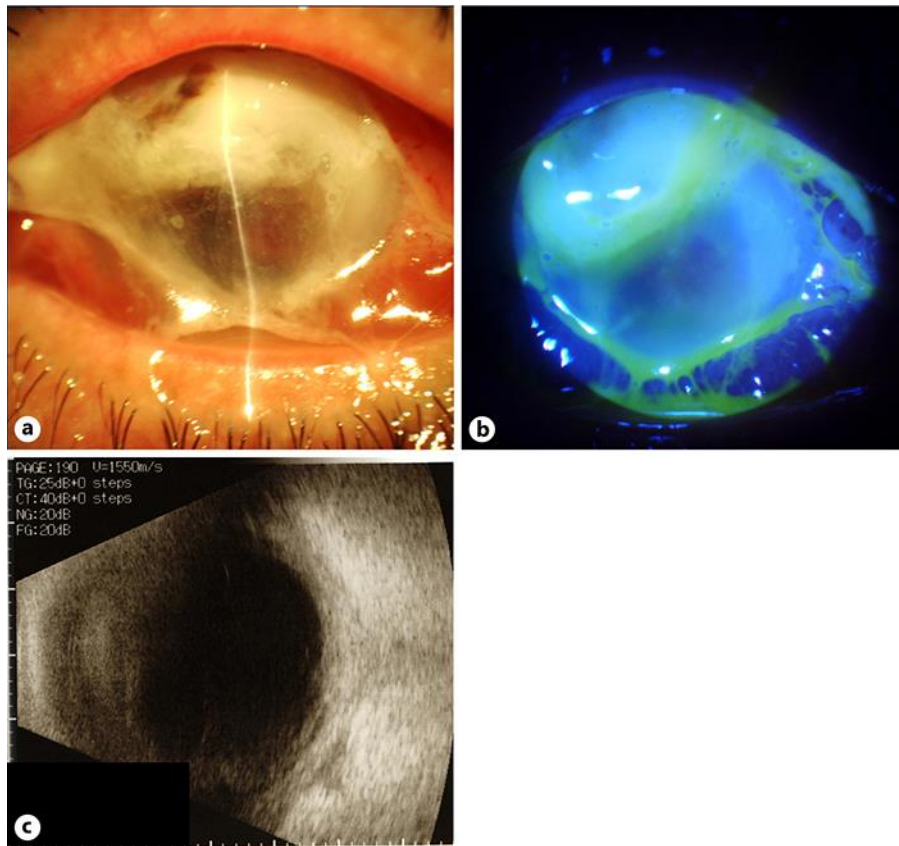
There was no funding or grant support.

## Author Contributions

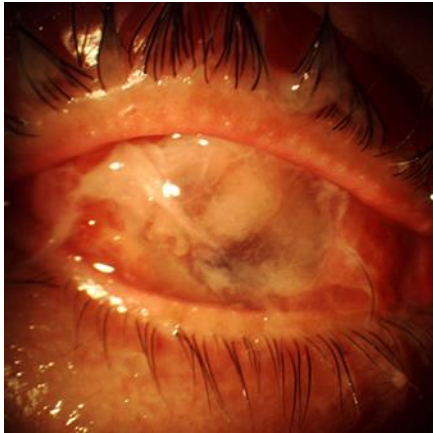
The authors were involved in the design and conduct of the study (T.O. and K.A.); collection, management, analysis, and interpretation of data (T.O., Y.M., and R.N.); and preparation, review, and approval of the manuscript (T.O., K.A., Y.M., R.N., T.I., M.A., and K.M.).

## References

- 1 Collin JR. Ocular perforating injury caused by a sparrow. *BMJ*. 1975 Aug;3(5982):520–1.
- 2 Chaudhry IA, Al-Sharif AM, Hamdi M. Severe ocular and periocular injuries caused by an ostrich. *Ophthalm Plast Reconstr Surg*. 2003 May;19(3):246–7.
- 3 Abdulla HA, Alkhalifa SK. Ruptured globe due to a bird attack. *Case Rep Ophthalmol*. 2016 Feb;7(1):112–4.
- 4 Baskaran P, Ramakrishnan S, Dhoble P, Gubert J. Traumatic endophthalmitis following a crane pecking injury – An unusual mode. *GMS Ophthalmol Cases*. 2016 Feb;6:Doc01.
- 5 Tabatabaei SA, Soleimani M, Behrouz MJ. Bird attack ocular injuries. *Retina*. 2018 May;38(5):945–50.
- 6 Al-Sharif EM, Alkharashi AS. An unusual case of penetrating eye injury caused by a bird: A case report with review of the pertinent literature. *Saudi J Ophthalmol*. 2019 Apr-Jun;33(2):196–9.
- 7 Kronwith SD, Hankin DE, Lipkin PH. Ocular injury from a rooster attack. *Clin Pediatr (Phila)*. 1996 Apr;35(4):219–20.
- 8 Muller L, Kohnen T. Scleral and corneal laceration with iris prolapse caused by an eagle claw. *Graefes Arch Clin Exp Ophthalmol*. 2005 Apr;243(4):377–9.
- 9 Kubo M, Kobayashi K, Masegi T, Sakai H, Tsubota T, Asano M, et al. A case of chondrosarcoma in a free-flying Great Egret. *J Wildl Dis*. 2007 Jul;43(3):542–4.
- 10 Ahmadzadeh A, Larsen M, Jacobsen N, Soliman W. Risk of pecking injury of the eye when children and chickens roam together. *Acta Ophthalmol*. 2018 Nov;96(7):e902–3.
- 11 Pieramici DJ, Sternberg P Jr, Aaberg TM Sr, Bridges WZ Jr, Capone A Jr, Cardillo JA, et al.; The Ocular Trauma Classification Group. A system for classifying mechanical injuries of the eye (globe). *Am J Ophthalmol*. 1997 Jun;123(6):820–31.
- 12 Essex RW, Yi Q, Charles PG, Allen PJ. Post-traumatic endophthalmitis. *Ophthalmology*. 2004 Nov;111(11):2015–22.
- 13 Durand ML. Bacterial and fungal endophthalmitis. *Clin Microbiol Rev*. 2017 Jul;30(3):597–613.
- 14 Long C, Liu B, Xu C, Jing Y, Yuan Z, Lin X. Causative organisms of post-traumatic endophthalmitis: a 20-year retrospective study. *BMC Ophthalmol*. 2014 Mar;14(1):34.
- 15 Kim YC, Kim KS. A case of postoperative endophthalmitis by extended-spectrum beta-lactamase-producing *Escherichia coli*. *Korean J Ophthalmol*. 2012 Aug;26(4):306–8.



**Fig. 1.** Anterior segment and ultrasonographic examination images of the right eye of the patient on admission. **a** An image of the anterior segment of the patient. Conjunctival edema with copious amounts of discharge is observed. The anterior chamber depth is shallow. The upper side of the cornea is melted. **b** An image of the anterior segment of the patient with fluorescein staining. Leakage of aqueous humor is not observed. **c** An ultrasonographic image of the patient. A thick sclera and choroid-like structure are observed. Retinal detachment is not observed.



**Fig. 2.** An anterior segment image of the right eye of the patient on the next day. Corneal melting progressed and it was difficult to evaluate the inside of the anterior chamber. Hyperemia and conjunctival edema are observed.