

## Case Report

# Effect of the Gant-Miwa-Thiersch Procedure for Rectal Prolapse on the Mesorectum

Sachio Yokoyama, Yoshiaki Ikuta, Masayo Tsukamoto and Takanobu Yamao

*Department of Gastroenterological Surgery, Kumamoto City Hospital, Kumamoto, Japan*

### Abstract

Rectal prolapse (RP) most commonly occurs among elderly women and is caused by vulnerable suspensory tissue in the pelvis. In Japan, the Gant-Miwa-Thiersch procedure (GMT) is recommended for elderly people with poor general health. We retrospectively analyzed clinical data from 12 patients who underwent GMT at our hospital from September 2005 to July 2021 and investigated the effect of GMT on the mesorectum using abdominal-pelvic computed tomography (CT) performed for other diseases. The median age of the cohort was 82 years, and 92% of the subjects were women. The median RP length was 5 cm, and the median follow-up period was 60 months. Recurrence was observed in 1 of 12 patients (8.0%). CT conducted before and more than 6 months after GMT revealed no abnormal findings in the mesorectum, whereas CT within 5 months after GMT revealed hyperdense fat in the mesorectum in all three patients (100%;  $P < 0.05$ ). The RP recurrence rate after the GMT was low. The mechanism of the effect of GMT may involve not only a direct mucosal plicating effect but also adhesional rectosacral fixation due to the presence of inflammation extending to the mesorectum.

### Keywords

rectal prolapse, Gant-Miwa-Thiersch procedure, mesorectum, rectosacral fixation

J Anus Rectum Colon 2022; 6(3): 190-194

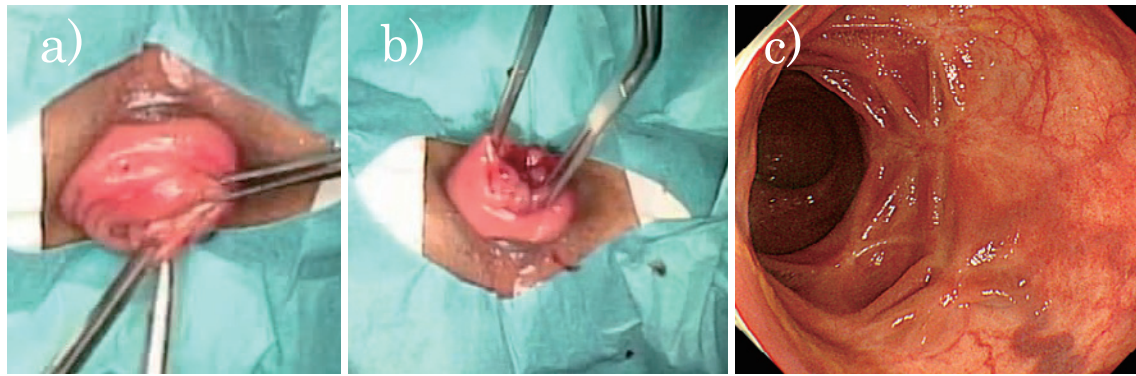
## Introduction

Rectal prolapse (RP) most frequently occurs among elderly women and is accompanied by anal pain and fecal incontinence, which significantly degrade the quality of life[1]. With the aging of the population in Japan[2], the incidence of RP is expected to increase. The anatomical cause of RP is thought to be loose rectosacral fixation and vulnerable pelvic floor muscles[1].

Both transabdominal and transperineal approaches have been employed to treat RP. The recurrence rate of RP following rectopexy, which pulls up the redundant rectum and fixes it to the sacrum, is the lowest, ranging from 0% to 12%[3]; however, the procedure is performed under general anesthesia, which is problematic because elderly people

often have poor general health and cannot tolerate general anesthesia. According to Japanese guidelines for RP[1], transperineal surgery is recommended if general anesthesia cannot be tolerated. The Altemeier procedure is recommended in cases with RP >5 cm in length, and the Delorme or Gant-Miwa-Thiersch procedure (GMT) is recommended for RP ≤5 cm in length.

Among these procedures, GMT had been reported to have a high recurrence rate[4-6], although it is technically simple to perform. Recently, there have been some studies indicating that the recurrence rate with GMT is lower than previously reported[5,6], and therefore, we retrospectively analyzed clinical data from 12 patients who underwent GMT at our hospital and also had abdominal-pelvic computed tomography (CT) for other diseases before and/or after GMT



**Figure 1.** Gant-Miwa procedure and postoperative colonoscopy.

a) The early state of surgery, b) mid-state of surgery, and c) multiple scars in the lower rectum 13 months after surgery.

from September 2005 to July 2021. This case series aimed to investigate the recurrence rate after GMT and the effect of GMT on the mesorectum, which is one of the suspensory tissues in the pelvis.

### Case Report

The surgical procedure for RP was decided upon considering the patient's condition and wishes, and with reference to the guidelines[1].

The GMT procedure (Figure 1a, 1b) was performed according to the method of Yamana[5], partially modified with respect to the depth of suture, materials for ligation, etc. In summary, the tip of the prolapsed rectum was held using Alis forceps, a tag of the mucosa was lifted off the muscle layers, and a needle with 3-0 OPEPOLYX N suture (Alfresa Pharma Co. Tokyo, Japan) was inserted into the surface of the muscle layer to prevent postoperative bleeding due to suture slip off and ligated along the head of the forceps to create a tag. The diameter of each tag was ~7-10 mm. By repeating this procedure, multiple tags were created from the tip of the prolapsed rectum down to 1 cm from the dentate line. After the perianal skin was fully sterilized, four small incisions were made at 12, 3, 6, and 9 o'clock positions on the anal verge. The material for the Thiersch procedure was changed over time from 3-mm-wide Teflon tape (E.I. du Pont de Nemours & Co. Inc. Wilmington, DE) to 0 PROLENE suture (Ethicon, Somerville, New Jersey, USA) or CV-0 suture (W. L. Gore and Associates, Inc., Elkton, MD), inserted from the incisions, and placed subcutaneously around the anal canal. A bougie (20-25 mm in diameter) was inserted into the anal canal to ensure suitable tightening of the encirclement. When two ends of the thread or the tape were tied together, the skin incision was closed with 3-0 OPEPOLYX N.

To evaluate the mesorectum, CT performed for other diseases was used. Inflammatory findings in the mesorectum

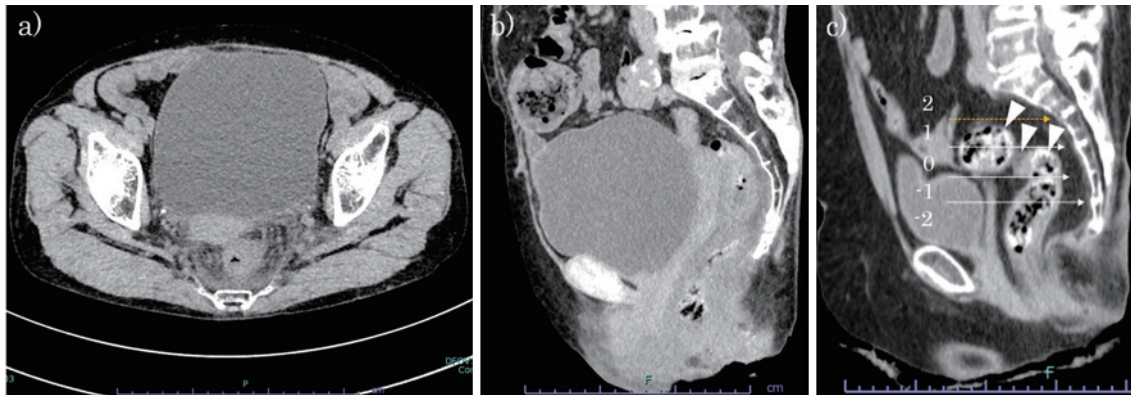
were assessed and compared with those in the abdominal subcutaneous fat in the coronal view at the level of the lower margin of the fourth sacral vertebrae or the mid-sagittal level on CT (Figure 2a, 2b). Regarding loose recto-sacral fixation, which is one of the anatomical causes of RP, the height at which the rectum dropped apart from the sacrum in the mid-sagittal view on CT was defined as the fixation failure point (FFP)[7], and the FFP was classified according to five levels (-2: below the lower edge of S5, -1: in S5, 0: in S4, 1: in S3, 2: above the lower edge of S2, Figure 2c).

Comparisons were performed using the Fisher exact or Wilcoxon rank-sum tests for categorical variables, and statistical significance was set to  $P < 0.05$ .

This case series was approved by the Kumamoto City Hospital Ethics Review Board (Ethics Committee Approval No. 595). Consent was obtained from all patients using the opt-out method.

Table 1 presents the clinical characteristics. The median age of the patients was 82 years, and 92% were women. Comorbidities were observed in 11 patients (92%), led by brain-heart diseases in eight patients (67%), followed by orthopedic diseases in seven patients (58%). There were two patients (17%) who had been treated for RP at other hospitals and one patient (8%) who simultaneously underwent gynecological surgery for uterine prolapse at our hospital. According to the American Society of Anesthesiologists classification, eight patients (67%) were grade II or III. Lumbar anesthesia was performed in seven patients (58%), whereas general anesthesia was used in four patients (33%) due to lumbar spondylosis and anticoagulant therapy. The median length of RP was 5 cm, the median length of hospital stay after surgery was 5 days, and the median follow-up period was 60 months.

Serious complications, such as perforation, pelvic abscess, or massive bleeding, were not observed. One patient (8%) reported having severe anal pain related to the Thiersch pro-



**Figure 2.** Evaluation of the mesorectum by computed tomography (CT).

In the acute phase, the swollen rectal wall and hyperdense mesorectal fat were observed in the a) coronal CT view at the lower edge of the fourth sacral vertebrae or b) mid-sagittal CT view, and c) the fixation failure points (FFPs) between the rectum and sacrum were classified into five levels. White arrowheads indicate that the rectum had dropped apart from the sacrum, and the height of the FFP was level 0. The dotted line shows the lower edge of the second sacral vertebrae.

**Table 1.** Clinical Characteristics of 12 Gant-Miwa-Thiersch Patients (2005–2021).

Characteristics	Median (range) or number (%)
Age (y)	82 (67–92)
Male:Female	1:11
Length of rectal prolapse (cm)	5 (3–7)
ASA class (I:II:III)	4:6:2
Anesthesia (local:lumbar:general)	1:7:4
Complication rate during hospitalization (%)	0
Late complication rate (%)	1 (8%; 1 related to the Thiersch procedure)
Postoperative hospital stay (days)	5 (2–11)
Median follow-up period (months)	60 (2–101)
Recurrence rate (%)	1 (8%)

ASA: American Society of Anesthesiologists

cedure 6 months after surgery and recurrence 12 months after the removal of the CV-0 suture for the Thiersch procedure.

Figure 3 presents the status of mesorectum and FFP of an informative case.

A 71-year-old woman suffered from collagen disease and had RP 7 cm in length. She underwent CT before GMT for a suspicious pancreatic tumor and again two times after surgery when presented with fever, constipation, and other symptoms. There were no abnormal findings in the rectal mesentery 5 days before GMT. On day 23 after GMT, swelling of the rectal wall, hyperdense fat in the mesorectum, and a high C-reactive protein level of 18.9 mg/dL (reference range, 0-0.14) were observed. Although the hyperdense fat in the mesorectum was maintained, swelling of the rectal wall was absent on day 59. The FFP was graded as level 0 at 5 days before GMT but was level 2 on day 59.

In this case series, two patients underwent CT before

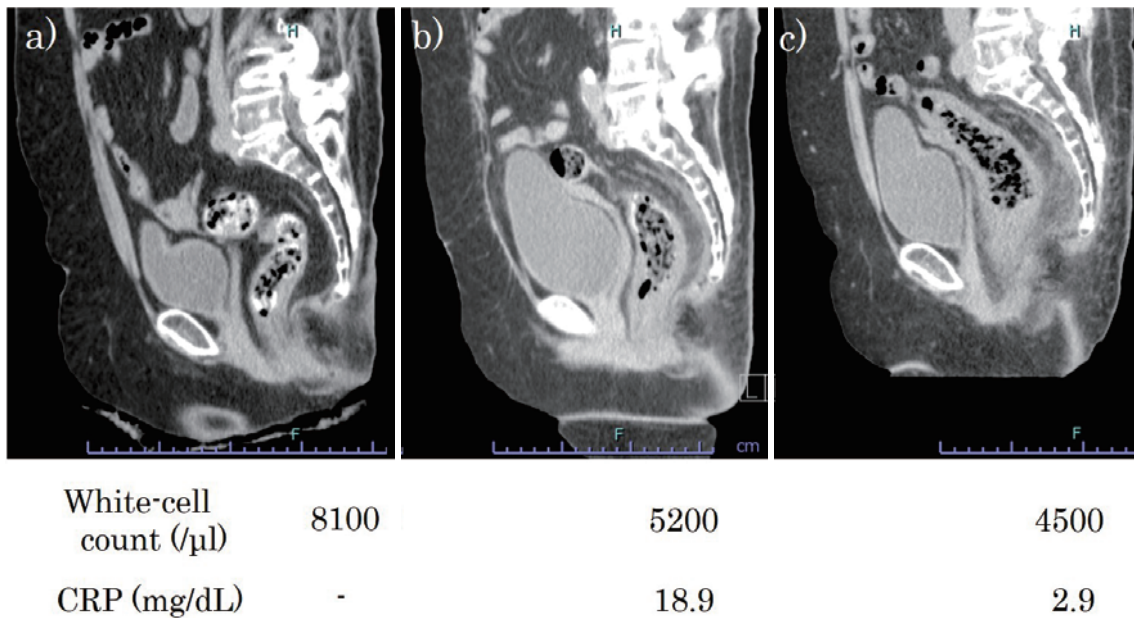
GMT, two patients before and after GMT, and eight patients after GMT. No abnormal findings in the mesorectum were obtained in any of the four patients who underwent preoperative CT or the seven patients who underwent CT more than 6 months after GMT. CT within 5 months after GMT showed hyperdense mesorectal fat in all three patients ( $P < 0.05$ ). No focus causing inflammation in the mesorectum was observed except for GMT.

Figure 4 presents the distribution of FFP. All four GMT patients who underwent preoperative CT had a low FFP at level 0 or below, and two of these patients had FFP at level 2 after GMT. Conversely, more than half of the GMT patients who underwent postoperative CT had a high FFP at level 2 ( $P = 0.09$ ).

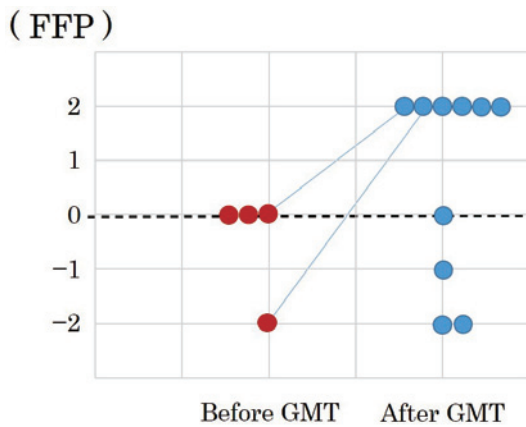
### Discussion

The mechanism of GMT for RP has not been eluci-





**Figure 3.** Changes in the rectal and mesorectal images in the mid-sagittal CT view and inflammatory markers before and after GMT. a) Five days before GMT, b) 23 days after GMT, and c) 59 days after GMT.



**Figure 4.** Distribution of the fixation failure points between the rectum and sacrum before and after GMT.

Red circles, preoperative CT image; blue circles, postoperative CT image.

dated[6]. It is known that the mucosa and muscular layer are fixed by scarring after mucosal plication (Figure 1c); however, if this is the sole mechanism, the effect on complete RP, in which the rectum prolapses at all layers, may be limited, and it is easy to imagine that the recurrence rate would be high. The recurrence rate of GMT has been reported to range from 24% to 31%[4], but some recent studies[5,6] have reported lower rates, ranging from 7% to 14%. The recurrence rate at our department was 8% in patients treated using GMT, which was similar to the rate with transabdominal rectopexy (4%-8%)[3]. As a hypothesis to explain this discrepancy, the effect of GMT on the rectal mesentery, which is one of the suspensory tissues for the intrapelvic or-

gans, was considered, in part because inflammation extended to the rectal mesentery after GMT (Figure 2, 3;  $P < 0.05$ ). Furthermore, Sumida et al. reported insufficient fixation of the rectum to the sacrum in contrast to enema for pediatric RP[7]. In the present case series, we used Sumida’s definition[7] to quantify the height of the insufficient fixation. As presented in Figure 4, all four patients had fixation at level 4 or lower in preoperative CT images, and 6 of 10 patients who underwent postoperative CT had fixation at level 2. Two patients who underwent CT before and after GMT had FFP at a higher level. Notably, in the patient presented in Figure 3, inflammation in the mesorectum continued until 59 days after GMT. We speculated that fixation between the rectum and sacrum would be promoted by inflammatory adhesion.

This case series has some limitations, not only due to its retrospective nature but also the small number of CT scans performed. Moreover, it cannot be ruled out that postoperative constipation may have caused rectal extension and led to the elevated FFP. Pelvic CT combined with contrast enema before and after surgery will be needed to prove this hypothesis.

In conclusion, the recurrence rate of RP after GMT is low. Regarding the mechanism of the surgical effect, not only the direct effect of mucosal plication but also adhesional rectosacral fixation due to the presence of inflammation extending to the mesorectum may be involved.

**Conflicts of Interest**

There are no conflicts of interest.

### Author Contributions

Sachio Yokoyama wrote the manuscript with support from Yoshiaki Ikuta, Masayo Tsukamoto and Nobuyuki Yamao.

All authors discussed the results and commented on the manuscript.

### References

1. Japanese Society of Coloproctology. Clinical guidelines for anal disease (hemorrhoids, anal fistula, anal fissure), rectal prolapse. 2nd ed. Tokyo: Nankodo Shuppan; 2020.
2. National Institute of Population and Social Security Research [Internet]. Household Projections for Japan: 2015-2040, Outline of Results and Methods. 2018 February. Available from: [https://www.ipss.go.jp/pp-ajsetai/e/hhprj2018/hhprj2018\\_DL.pdf](https://www.ipss.go.jp/pp-ajsetai/e/hhprj2018/hhprj2018_DL.pdf)
3. Tsunoda A. Surgical treatment of rectal prolapse in the laparoscopic era; a review of the literature. *J Anus Rectum Colon*. 2020 Jul; 4(3): 89-99.
4. Iwadare J, Sumikoshi Y, Ono R, et al. [Etiology and treatment of rectal prolapse]. *J Jpn Soc Coloproctol*. 1989 Sep; 42(6): 981-6. Japanese.
5. Yamana T, Iwadare J. Mucosal plication (Gant-Miwa procedure) with anal encircling for rectal prolapse--a review of the Japanese experience. *Dis Colon Rectum*. 2003 Oct; 46(10 Suppl): S94-9.
6. Iida Y, Honda K, Saitou H, et al. Modified Gant-Miwa-Thiersch procedure (mucosal plication with anal encircling) for rectal prolapse. *Colorectal Dis*. 2019 May; 21(5): 588-94.
7. Sumida W, Ono Y, Watanabe Y, et al. Insufficient fixation of rectum to sacrum in rectal prolapse. *J Jpn Soc Pediatr Surg*. 2016; 52: 83-8. Japanese.

Journal of the Anus, Rectum and Colon is an Open Access journal distributed under the Creative Commons Attribution-NonCommercial-NoDerivatives 4.0 International License. To view the details of this license, please visit (<https://creativecommons.org/licenses/by-nc-nd/4.0/>).