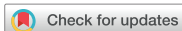

## Original Article



# Non-exposure Simple Suturing Endoscopic Full-thickness Resection with Sentinel Basin Dissection in Patients with Early Gastric Cancer: the SENORITA 3 Pilot Study

Bang Wool Eom , Chan Gyoo Kim , Myeong-Cherl Kook , Hong Man Yoon ,  
Keun Won Ryu , Young-Woo Kim , Ji Yoon Rho , Young-Il Kim ,  
Jong Yeul Lee , Il Ju Choi

Center for Gastric Cancer, National Cancer Center, Goyang, Korea

## OPEN ACCESS

Received: Jan 13, 2020

Revised: Apr 23, 2020

Accepted: May 29, 2020

### Correspondence to

Chan Gyoo Kim

Center for Gastric Cancer, National Cancer Center, 323 Ilsan-ro, Ilsandong-gu, Goyang 10408, Korea.

E-mail: glse@ncc.re.kr

Copyright © 2020. Korean Gastric Cancer Association

This is an Open Access article distributed under the terms of the Creative Commons Attribution Non-Commercial License (<https://creativecommons.org/licenses/by-nc/4.0>) which permits unrestricted noncommercial use, distribution, and reproduction in any medium, provided the original work is properly cited.

### ORCID iDs

Bang Wool Eom

<https://orcid.org/0000-0002-0332-2051>

Chan Gyoo Kim

<https://orcid.org/0000-0002-1651-2559>

Myeong-Cherl Kook

<https://orcid.org/0000-0002-3435-3301>

Hong Man Yoon

<https://orcid.org/0000-0002-6218-7080>

Keun Won Ryu

<https://orcid.org/0000-0002-5935-9777>

Young-Woo Kim

<https://orcid.org/0000-0002-1559-9672>

Ji Yoon Rho

<https://orcid.org/0000-0001-7351-2785>

Young-Il Kim

<https://orcid.org/0000-0002-2614-3419>

## ABSTRACT

**Purpose:** Recently, non-exposure simple suturing endoscopic full-thickness resection (NESS-EFTR) was developed to prevent tumor exposure to the peritoneal cavity. This study aimed to evaluate the feasibility of NESS-EFTR with sentinel basin dissection for early gastric cancer (EGC).

**Materials and Methods:** This was the prospective SENORITA 3 pilot. From July 2017 to January 2018, 20 patients with EGC smaller than 3 cm without an absolute indication for endoscopic submucosal dissection were enrolled. The sentinel basin was detected using Tc<sup>99m</sup>-phytate and indocyanine green, and the NESS-EFTR procedure was performed when all sentinel basin nodes were tumor-free on frozen pathologic examination. We evaluated the complete resection and intraoperative perforation rates as well as the incidence of postoperative complications.

**Results:** Among the 20 enrolled patients, one dropped out due to large tumor size, while another underwent conventional laparoscopic gastrectomy due to metastatic sentinel lymph nodes. All NESS-EFTR procedures were performed in 17 of the 18 other patients (94.4%) without conversion, and the complete resection rate was 83.3% (15/18). The intraoperative perforation rate was 27.8% (5/18), and endoscopic clipping or laparoscopic suturing or stapling was performed at the perforation site. There was one case of postoperative complications treated with endoscopic clipping; the others were discharged without any event.

**Conclusions:** NESS-EFTR with sentinel basin dissection is a technically challenging procedure that obtains safe margins, prevents intraoperative perforation, and may be a treatment option for EGC after additional experience.

**Trial Registration:** ClinicalTrials.gov Identifier: [NCT03216174](https://clinicaltrials.gov/ct2/show/study/NCT03216174)

**Keywords:** Stomach neoplasms; Endoscopy, gastrointestinal; Minimally invasive surgical procedures

## INTRODUCTION

Various techniques for the local resection of gastric tumors were recently reported [1]. For local resection, an accurate and safe resection method is required; endoscopic full-thickness

Jong Yeul Lee   
<https://orcid.org/0000-0001-8709-5097>  
Il Ju Choi   
<https://orcid.org/0000-0002-8339-9824>

#### Trial Registration

ClinicalTrials.gov Identifier: [NCT03216174](https://clinicaltrials.gov/ct2/show/study/NCT03216174)

#### Funding

This work was supported by a grant from the National Cancer Center, Korea (No. 2010130-1).

#### Author Contributions

Conceptualization: K.C.G.; Data curation: E.B.W., K.C.G., K.M.C., Y.H.M., R.K.W., K.Y.W., R.J.Y., K.Y.I.; Formal analysis: E.B.W., K.C.G.; Funding acquisition: K.C.G.; Writing - original draft: E.B.W., K.C.G.; Writing - review & editing: E.B.W., K.C.G., K.M.C., Y.M.M., R.K.W., K.Y.W., R.J.Y., K.Y.I., L.J.Y., C.I.J.

#### Conflict of Interest

No potential conflict of interest relevant to this article was reported.

resection (EFTR) is one novel method that can obtain precise and secure surgical margins for gastric tumor. An appropriate resection line can be acquired via endoscopic visualization, and the possibility of deep margin invasion is excluded by full-thickness resection. Thus, EFTR could be an alternative approach to overcome limitations of endoscopic submucosal dissection (ESD) or laparoscopic wedge resection for gastric tumors.

EFTR, initially introduced as laparoscopic and endoscopic cooperative surgery (LECS), reportedly has favorable results [2-5]. A circumferential incision is made using ESD devices and techniques and intentional perforation is performed. Then, seromuscular resection and closure are performed using laparoscopic devices and techniques. However, LECS requires an artificial perforation and can increase the risk of bacterial contamination and dissemination of peritoneal tumor cells.

We previously reported on non-exposure simple suturing endoscopic full-thickness resection (NESS-EFTR) in a porcine model [6,7]. NESS-EFTR permits the EFTR of gastric tumor without exposing the tumor to the peritoneal cavity. In a previous randomized controlled trial comparing NESS-EFTR with laparoscopic wedge resection in the porcine model, incomplete resection and complications occurred exclusively in the laparoscopic wedge resection group and NESS-EFTR was feasible and safe.

Here we performed a prospective pilot human study of NESS-EFTR for patients with early gastric cancer (EGC) and evaluated its feasibility. Sentinel basin dissection was conducted to evaluate possible lymph node metastasis and NESS-EFTR was attempted only when the sentinel basin was confirmed as tumor-free on frozen examination.

## MATERIALS AND METHODS

### Study design and patients

The SENIORITA 3 pilot study is an investigator-initiated, single-center, prospective, feasibility pilot study. Prior to the application of NESS-EFTR to patients with gastric cancer, treatment for lymph node metastasis should be considered. Sentinel node navigation surgery was applied in a previous randomized controlled phase III clinical trial (Sentinel Node ORiented Tailored Approach [SENIORITA] 1 trial) [8]. The patient inclusion and exclusion criteria are similar to those of the SENIORITA 1 trial as follows.

#### Inclusion criteria:

1. Single lesion of histologically confirmed adenocarcinoma in the stomach on preoperative endoscopic biopsy
2. Clinical stage T1N0 gastric cancer according to the American Joint Committee for Cancer 7th edition determined by preoperative endoscopy and computed tomography and/or endoscopic ultrasonography [9]
3. Differentiated adenocarcinoma (well or moderately differentiated tubular adenocarcinoma) smaller than 3 cm or undifferentiated adenocarcinoma (poorly differentiated tubular adenocarcinoma or signet ring cell carcinoma) less than 2 cm in its longest diameter
4. Gastric cancer at least 2 cm from the pylorus or the cardia
5. Age of 20–80 years
6. Eastern Cooperative Oncology Group performance status of 0 or 1
7. Agreement to participate in the clinical study by providing informed consent

**Exclusion criteria:**

1. A lesion meeting the absolute indications of endoscopic resection (smaller than 2 cm, mucosal tumor, differentiated type, ulcer negative)
2. Serious cardiovascular or pulmonary disease
3. Current pregnancy
4. Past history of drug-related anaphylactic reaction, prior upper abdominal surgery (except for laparoscopic cholecystectomy) or radiation therapy

Written informed consent was obtained from all patients prior to their recruitment. The Institutional Review Board (IRB) of the National Cancer Center of Korea approved this study (IRB No. NCC2017-0088), and this study was registered in the database of clinical trials (NCT03216174).

**Detection of sentinel basin**

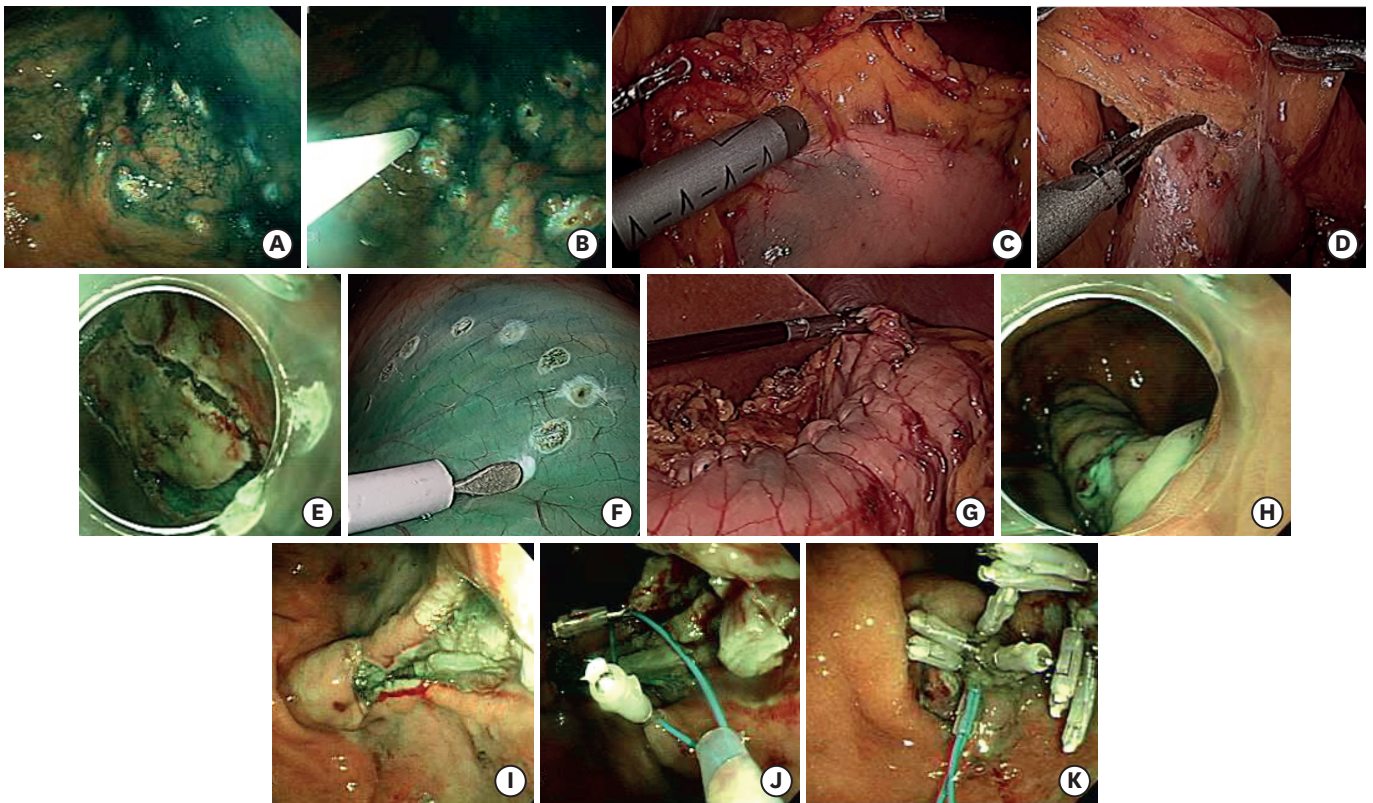
The sentinel basin was detected as follows [10]. A mixture of indocyanine green (Diagnogreen<sup>®</sup>; Daiichi-Sankyo Co., Ltd., Tokyo, Japan; 2 mL, 5 mg/mL) and radiolabeled phytate (Tc<sup>99m</sup>-phytate; 2 mL, 0.1 mCi/mL) is used as a tracer to detect the sentinel nodes. A 4-mL volume of the dual tracer is injected into the submucosal layer in 4 quadrants of the primary tumor via an intraoperative endoscopic approach. At 15 minutes after the endoscopic tracer injection, sentinel basins containing sentinel nodes (green or hot) are identified based on the level of green staining and the radioactivity of the laparoscopic gamma probe. Laparoscopic basin dissection is carefully performed, and the harvested sentinel basins are dissected to isolate the lymph nodes in the back table. All of the isolated lymph nodes from the sentinel basins, which are defined as sentinel basin nodes, are classified into 4 groups: hot nodes (radioactive nodes), green nodes (stained nodes), both hot and green nodes, and basin nodes (those the sentinel basins that were neither hot nor green). The dissected nodes were labeled with the respective lymph node station numbers and sent to the pathologist for intraoperative frozen section evaluation.

**NESS-EFTR**

NESS-EFTR was performed when there was no lymph node metastasis noted on frozen examination of the sentinel basin. A detailed description of NESS-EFTR is provided in our preceding report of the animal model [6,7]. First, endoscopic marking and circumferential incision of the mucosal layer were performed (**Fig. 1**). The endoscopist made several marking dots 5–10 mm outside the margin of the EGC lesion to ensure a safe margin. Multiple dots were added on the distal side to identify where the distal part was in the specimen. A submucosal saline injection was performed, and an endoscopic circumferential mucosal incision was performed in a manner similar to that of ESD for EGC.

Second, a laparoscopic serosal marking was made on the opposite side of the endoscopic mucosal incision line using a monopolar device guided by intraluminal endoscopy. Next, laparoscopic seromuscular suturing was performed with a continuous method using unidirectional barbed thread (V-loc 180 3-0; Covidien, Mansfield, MA, USA). An interrupted method using black silk thread (MERSILK 3-0; Ethicon, Somerville, NJ, USA) was also allowed according to the surgeon's preference. This procedure inverts the stomach wall.

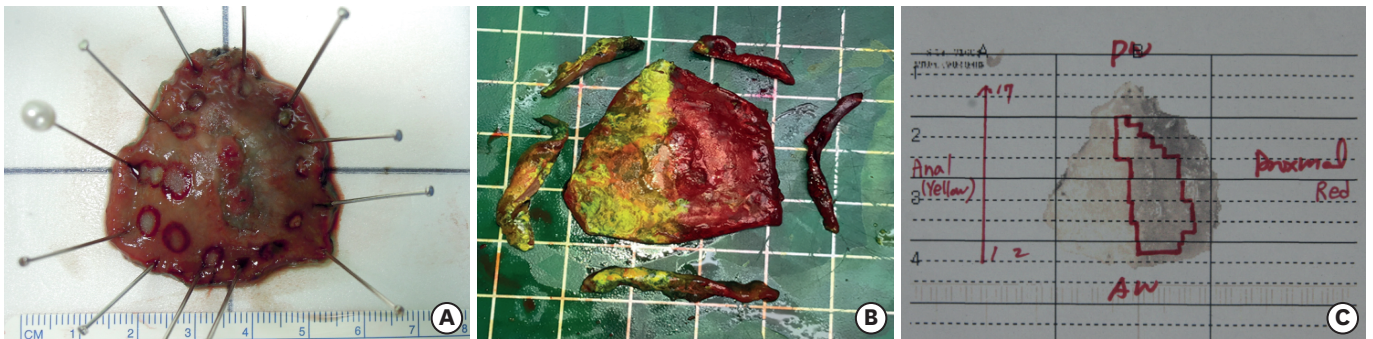
Third, EFTR is performed of the inverted stomach wall from inside the stomach. An IT-2 knife (Olympus, Tokyo, Japan), Helmet knife (Kachu Technology Co., Ltd., Seoul, Korea) or conventional needle knife (needle papillotome; MTW Endoscopy, Wesel, Germany) was



**Fig. 1.** Non-exposure simple suturing endoscopic full-thickness resection. (A) Mucosal marking. (B) Tracer injection. (C) Sentinel basin detection. (D) Sentinel basin dissection. (E) Mucosal incision. (F) Serosal marking. (G) Serosal suturing. (H) Endoscopic view after serosal suturing. (I) Completion of endoscopic full-thickness resection. (J) Endoscopic suturing using endoloops and clips. (K) Completion of endoscopic suturing.

used for this procedure. Resected tissues were grasped endoscopically with alligator jaws (FG-6L-1; Olympus) and retrieved via the oral cavity. After an endoscopist evaluated the entire specimen, 4 resection margins (proximal, distal, anterior wall, and posterior wall) were evaluated by frozen section examination by a pathologist (M-C Kook) (**Fig. 2**).

Finally, endoscopic mucosal suturing with endoloops was performed. An open endoloop with a 30-mm diameter (MAJ-340; Olympus) was positioned along both edges of the resection site using 3–5 clips (HX-610-90L or HX-610-135L; Olympus). The endoloop was then closed and released, and 2 or 3 endoloops were required to achieve complete mucosal closure of the resected site.



**Fig. 2.** Resected specimen with clear resection margins after the procedure. (A) Specimen before frozen examination. (B) Resection of lateral margin for frozen examination. The proximal part was red, and the distal part was yellow. (C) Tumor mapping with final permanent fixed specimen.

### Follow-up surveillance

After NESS-EFTR, endoscopic evaluation was performed at 3, 6, and 12 months and biannually thereafter. At every follow-up endoscopic examination, the presence of ulcer, stenosis, or other abnormal lesions was evaluated. Abdominal computed tomography was performed every 6 months, and any recurrence or metastasis was evaluated.

### Measurements and statistical analysis

This was a feasibility pilot study that included 20 patients as the sample size. The primary outcome was complete resection rate, which was defined as successful en-bloc resection (tumor in a single piece) with a clear margin. Secondary outcome measurements were intraoperative perforation rates, procedure times, and complications such as leakage or stenosis.

Continuous values are presented as mean±standard deviation or median and interquartile range (IQR), while categorical variables are shown as proportions. The statistical analyses were performed using SAS version 9 (SAS Institute Inc., Cary, NC, USA) software. P-values less than 0.05 were considered statistically significant.

## RESULTS

### Baseline clinicopathological characteristics

From July 2017 to January 2018, 20 patients were enrolled in this study at the National Cancer Center of Korea. Median participant age was 54.5 years, and the male proportion was 52.4% (11/20). More than half of the tumors were located in the body (57.1%), and the median tumor size estimated by endoscopy was 16.5 mm (**Table 1**). Most of the tumors were undifferentiated (85%; 7 were poorly differentiated, 10 were signet ring cell).

### NESS-EFTR outcomes

Among the 20 enrolled patients, one dropped out because the tumor size was confirmed to be larger during the NESS-EFTR procedure; this patient received conventional surgery. One patient underwent conventional laparoscopic gastrectomy due to metastatic sentinel lymph nodes (**Fig. 3**). The surgical results of the 18 patients are described in **Table 2**, and all procedures of NESS-EFTR were performed in 17 (94.4%) patients without conversion.

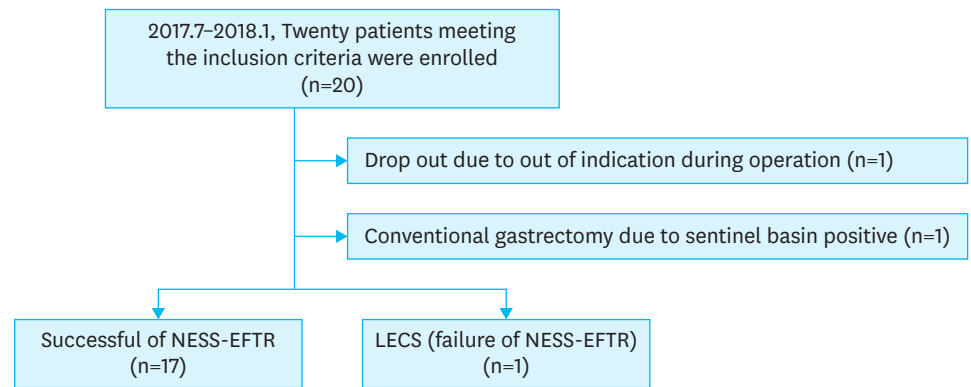
**Table 1.** Baseline characteristics

| Factor                               | Subgroup | No. of patients (n=20) |
|--------------------------------------|----------|------------------------|
| Age (yr)                             |          | 54.5 (51.0–62.0)       |
| Sex                                  | Male     | 11 (55.0)              |
|                                      | Female   | 9 (45.0)               |
| Body mass index (kg/m <sup>2</sup> ) |          | 23.8 (21–27.4)         |
| Tumor location                       | Antrum   | 5 (25.0)               |
|                                      | Body     | 14 (70.0)              |
|                                      | Fundus   | 1 (7.0)                |
| Endoscopic tumor size (mm)           |          | 16.5 (10.0–20.0)       |
| Histology by endoscopic biopsy*      | WD       | 1 (5.0)                |
|                                      | MD       | 2 (10.0)               |
|                                      | PD       | 7 (35.0)               |
|                                      | SRC      | 10 (50.0)              |

Values are presented as number (%) or median (interquartile range).

MD = moderately differentiated tubular adenocarcinoma; PD = poorly differentiated tubular adenocarcinoma; SRC = signet ring cell carcinoma; WD = well-differentiated tubular adenocarcinoma.

\*According to World Health Organization classification, 2010.



**Fig. 3.** CONSORT diagram. NESS-EFTR = non-exposure simple suturing endoscopic full-thickness resection.

**Table 2.** Surgical outcomes

| Factor                               | Subgroup                               | No. of patients (n=18) |
|--------------------------------------|--|------------------------|
| Operation                            | NESS-EFTR                              | 17                     |
|                                      | LECS                                   | 1                      |
| Procedure time (min)                 | Total procedure time                   | 179.5 (158.3–218.0)    |
|                                      | Surgical preparation                   | 12.5 (9.0–16.0)        |
|                                      | Endoscopic marking                     | 3.0 (2.0–5.0)          |
|                                      | Sentinel evaluation                    | 35.0 (31.8–43.5)       |
|                                      | Endoscopic precutting                  | 14.0 (11.0–23.5)       |
|                                      | Serosal marking & suture               | 30.5 (25.0–43.5)       |
|                                      | EFTR                                   | 28.5 (22.0–38.3)       |
|                                      | Additional procedure required*         | 19.5 (12.5–51.3)       |
|                                      | Endoscopic clipping                    | 20.0 (17.5–27.5)       |
|                                      | Wound closure                          | 11.5 (7.8–16.0)        |
| Operative time (min)                 |  | 264.5 (245.5–290.8)    |
| Perforation during EFTR              |  | 5 (27.8)               |
| Procedures for perforation site      | Serosal suture                         | 1                      |
|                                      | Serosal suture and endoscopic clipping | 2                      |
|                                      | Laparoscopic stapling                  | 2                      |
| Margin status of frozen specimen     | Free                                   | 15                     |
|                                      | Positive                               | 3                      |
| Further procedure after initial EFTR | Argon plasma coagulation               | 1                      |
|                                      | Further ESD required†                  | 3                      |
| Estimated blood loss (mL)            |  | 40 (28.8–212.5)        |
| Hospital stay (day)                  |  | 7 (7–8)                |
| Postoperative complication           | No                                     | 17                     |
|                                      | Rupture of mucosal suturing site       | 1                      |

Values are presented as number (%) or median (interquartile range).

EFTR = endoscopic full-thickness resection; ESD = endoscopic submucosal dissection; LECS = laparoscopic endoscopic cooperative surgery; NESS = non-exposure simple suturing.

\*Additional procedures, such as further ESD, argon plasma coagulation, and serosal suture, were required in 4 cases; †In one case, ESD was performed because atypical cells in the resection margin were seen on the frozen section. However, this was revealed as negative in the permanent report.

Continuous bleeding despite endoscopic hemostasis during EFTR occurred in 1 patient, and further resection and suturing were completed by LECS [11].

The complete resection rate as a primary outcome was 83.3% (15/18). Frozen examination of the resection margin revealed tumor-positive margins in 3 patients for which immediate additional ESD (n=2) or argon plasma coagulation (n=1) was performed. However, tumor cells were not found in the 2 additional ESD specimens using permanent pathological specimens. One patient had atypical glands on the frozen examination for which additional

ESD was performed. However, the atypical glands were confirmed as negative in the permanent examination, and no tumor cells were noted in the additional ESD specimens. The complete resection rate in the first half of cases was 66.7% (6/9), while that of the second half of cases was 100% (9/9).

Intraoperative perforation during EFTR developed in 27.8% (5/18) of patients, and further procedures, such as endoscopic clipping or laparoscopic suturing or stapling, were performed of the perforation site.

No intraoperative complications were observed. One patient complained of acute abdominal pain on the left upper quadrant of the abdomen on postoperative day 2. In the endoscopic evaluation, a 1-cm mucosal opening was observed at the mucosal suturing site of the previous NESS-EFTR and the serosal suture was intact. Endoscopic clipping for the mucosal opening was performed using an endoloop and clips, and the patient's symptoms subsided after esophagogastroduodenoscopy (EGD). The other patients were discharged without any postoperative complications, and there were no cases of delayed gastric emptying.

### Pathological results of sentinel nodes and tumors

**Table 3** shows the pathological results of the sentinel nodes and tumors. The median number of sentinel basins was 1, and the most common sentinel basin was lymph node station No. 3 (73.7%). The median number of lymph nodes in the dissected sentinel basin was 12 (IQR,

**Table 3.** Pathological results of sentinel basin and tumors

| Factor                           | Subgroup       | No. of patients  |
|----------------------------------|----------------|------------------|
| Results of sentinel basin (n=19) |                |                  |
| No. of basins                    |                | 1 (1-2)          |
| Location of the sentinel basin   | 1              | 1                |
|                                  | 3              | 14               |
|                                  | 4sa            | 1                |
|                                  | 4sb            | 1                |
|                                  | 4d             | 7                |
|                                  | 5              | 1                |
|                                  | 6              | 2                |
|                                  | 7              | 1                |
| No. of basin lymph nodes         |                | 12 (7.0-16.0)    |
| Tumor pathology results (n=18)   |                |                  |
| Specimen size, long (mm)         |                | 41.5 (36.5-43.5) |
| Specimen size, short (mm)        |                | 31.0 (25.0-36.3) |
| Tumor size (mm)                  |                | 14.0 (12.0-22.0) |
| Proximal margin (mm)             |                | 12.0 (6.0-15.0)  |
| Distal margin (mm)               |                | 9.0 (5.8-15.3)   |
| LC/AW margin (mm)                |                | 7.5 (3.0-12.5)   |
| GC/PW margin (mm)                |                | 6.0 (4.0-8.0)    |
| Histology                        | WD             | 1 (5.6)          |
|                                  | MD             | 5 (27.8)         |
|                                  | PD             | 3 (16.7)         |
|                                  | SRC            | 9 (50.0)         |
|                                  |                |                  |
| pT                               | Mucosa         | 14 (77.8)        |
|                                  | Submucosa      | 4 (22.8)         |
| No. of dissected lymph nodes     |                | 12.5 (6.8-16.8)  |
| Lymphatic invasion               | Not identified | 16 (88.9)        |
|                                  | Present        | 2 (11.1)         |

Values are presented as number (%) or median (interquartile range).

MD = moderately differentiated adenocarcinoma; PD = poorly differentiated adenocarcinoma; SRC = signet ring cell carcinoma; WD = well-differentiated adenocarcinoma; LC = lesser curvature; AW = anterior wall; GC = greater curvature; PW = posterior wall.

7.0–16.0), and the median tumor size was 14.0 mm. Twelve (66.7%) patients were diagnosed with the undifferentiated type.

In this study, sentinel basin node metastasis was identified in 1 patient. The patient had a 24×22 mm signet ring cell carcinoma with submucosal invasion in the lesser curvature of the lower body of the stomach. The sentinel basin was lymph node station no. 3, and frozen biopsy revealed that 4 of 10 lymph nodes had metastasis. Laparoscopic distal gastrectomy was then performed, and 4 additional metastatic lymph nodes were diagnosed in lymph node station No. 3. The final pathological report showed pT1bN3a (8/49), and the patient received adjuvant chemotherapy with TS-1.

### Short-term results

In the postoperative endoscopic evaluation at 3 months, incompletely healed ulcers at EFTR sites were observed in 4 patients. The incompletely healed ulcers were completely healed at 6 or 12 months postoperative. Neither stenosis nor delayed leakage was observed. Residual food was observed in the EGD at 3 months postoperative in 7 patients, but it disappeared at 1 year postoperative.

With a median follow-up period of 12.5 months (IQR, 10.4–12.9), there were no cases of recurrence or metastasis, and only 1 case of metachronous cancer was detected at 1 year postoperative. The initial tumor treated by LECS (a failure case of NESS-EFTR) was a well-differentiated adenocarcinoma located in the anterior wall of the mid body of the stomach. A new lesion was detected in the posterior wall of the high body of the stomach 1 year later for which ESD was performed. However, submucosal invasion (SM2) of the tumor with lymphatic invasion was confirmed by pathological examination for which total gastrectomy was performed. In the final pathological result, neither residual tumor nor lymph node metastasis was observed.

## DISCUSSION

This is the first clinical prospective study to evaluate the feasibility of EFTR with a non-exposure technique for EGC. The complete resection rate of the entire series was 83.3%, while that of the second half of the series was 100%. For patients with positive lateral margins on frozen section, an additional ESD was performed. No tumors were found in the additional specimens. As a result, the final lateral margins were negative. There were no severe complications to prolong hospital stay. NESS-EFTR combined with sentinel basin dissection may represent a feasible treatment option for EGC.

The application of EFTR combined with sentinel basin dissection for EGC has been reported in few studies. In one study, laparoscopy-assisted EFTR (LECS) was successfully performed in 9 patients without conversion or other adverse events [5]. However, in another study, conversion to curative gastrectomy was performed in 5 of 14 patients due to postoperative complications, such as leakage, stenosis, and ischemic changes to the stomach [4].

The LECS procedure has several limitations. First, there is the possibility of peritoneal cancer cell seeding [12]. A previous study showed that cancer cells in EGC are easily detached upon contact with the tumor surface (27.6%). This iatrogenic cancer cell seeding can be avoided using a non-exposure approach. Second, it is difficult to measure exact lateral margins in the



pathological evaluation. Edge tissues coming away by stapling can be included in the lateral margin. Stapling has limited ability to obtain a delicate resection margin around the tumor. Third, more normal tissue than necessary could be resected due to the linear nature of the stapling system.

The first introduced method of EFTR with a non-exposure approach is non-exposed endoscopic wall-inversion surgery (NEWS). In the NEWS technique, a laparoscopic circumferential seromuscular incision is performed and the gastric lesion is inverted into the gastric lumen after laparoscopic seromuscular sutures are placed along seromuscular incision lines. A surgical sponge is inserted into the space between the suturing plane and the serosal plane of the inverted lesion. The specimen is then resected using the ESD technique, and the mucosal edges can be closed using several endoscopic clips [13,14]. NEWS with sentinel node basin dissection has been successfully performed in both a porcine survival model and humans (case report) [15,16]. The other method of EFTR that uses a non-exposure approach is NESS-EFTR. The different point of NESS-EFTR from NEWS involves performing an endoscopic mucosal incision to mark the dissection line and then creating a laparoscopic simple seromuscular suture to invert the tumor. EGC is usually located in the mucosal layer, and the mucosal incision would be more effective than the serosal incision at identifying the borderline tumor. A tumor is directly observed on the mucosal side but invisible on the serosal side. Moreover, endoscopic mucosal incision is a common procedure in ESD and performed easily by an endoscopist. NESS-EFTR can be a technically easier method than NEWS and might reduce procedure time. This NESS-EFTR technique was successfully performed in a porcine model [7]. Complete resection was achieved in all 8 pigs, and no early deaths occurred due to complications. This study shows the next step, which is NESS-EFTR with sentinel basin dissection in patients with EGC.

In this study, there were 3 margin-positive cases on frozen section, for which further endoscopic procedures such as ESD or argon plasma coagulation were performed. Initially, we made the several marking dots 5 mm outside the margin of the EGC lesion based on the ESD procedure. However, EFTR specimens require additional safe margins because the frozen examination of resection margin requires wider tissue rather than the conventional pathologic examination in permanent fixed ESD specimen (**Fig. 2B**). After encountering the 3 cases of positive margins, we made the marking dots approximately 7–10 mm outside the EGC lesion margin; no positive margins were noted after the 11th case.

The incidence of intraoperative perforation was 27.8% (5/18) in this study, which is not negligible. Insufficient inversion or excessive endoscopic dissection can be performed and may lead to perforation. To reduce the incidence of perforation, laparoscopic seromuscular suturing should be performed with sufficient margins from the tumor border. Moreover, endoscopist experience is required to identify a proper dissection plane. As a result of this pilot study, we expect a lower incidence of intraoperative perforation in the next clinical trial. Moreover, the risk of tumor seeding due to perforation would be very small because immediate additional laparoscopic seromuscular suture or stapling was performed.

This study has several limitations. First, it was a single-center pilot study with a small sample size. Second, the overall procedure including the sentinel basin evaluation is somewhat complicated. And third, a skillful endoscopic technique and considerable experience are also required for successful NESS-EFTR.

In conclusion, NESS-EFTR with sentinel basin dissection is a technically challenging procedure for achieving safe margins and preventing intraoperative perforation. No cases of tumor-positive margins were observed in the second half of the study period. Curative resection was ultimately performed in all patients, and no severe complications were noted after NESS-EFTR. Therefore, NESS-EFTR may be a treatment option for EGC after the collection of additional experience.

## REFERENCES

1. Kinami S, Funaki H, Fujita H, Nakano Y, Ueda N, Kosaka T. Local resection of the stomach for gastric cancer. *Surg Today* 2017;47:651-659.  
[PUBMED](#) | [CROSSREF](#)
2. Hiki N, Yamamoto Y, Fukunaga T, Yamaguchi T, Nunobe S, Tokunaga M, et al. Laparoscopic and endoscopic cooperative surgery for gastrointestinal stromal tumor dissection. *Surg Endosc* 2008;22:1729-1735.  
[PUBMED](#) | [CROSSREF](#)
3. Kawahira H, Hayashi H, Natsume T, Akai T, Uesato M, Horibe D, et al. Surgical advantages of gastric SMTs by laparoscopy and endoscopy cooperative surgery. *Hepatogastroenterology* 2012;59:415-417.  
[PUBMED](#) | [CROSSREF](#)
4. Cho WY, Kim YJ, Cho JY, Bok GH, Jin SY, Lee TH, et al. Hybrid natural orifice transluminal endoscopic surgery: endoscopic full-thickness resection of early gastric cancer and laparoscopic regional lymph node dissection-14 human cases. *Endoscopy* 2011;43:134-139.  
[PUBMED](#) | [CROSSREF](#)
5. Hur H, Lim SG, Byun C, Kang JK, Shin SJ, Lee KM, et al. Laparoscopy-assisted endoscopic full-thickness resection with basin lymphadenectomy based on sentinel lymph nodes for early gastric cancer. *J Am Coll Surg* 2014;219:e29-e37.  
[PUBMED](#) | [CROSSREF](#)
6. Kim CG, Yoon HM, Lee JY, Cho SJ, Kook MC, Eom BW, et al. Nonexposure endolaparoscopic full-thickness resection with simple suturing technique. *Endoscopy* 2015;47:1171-1174.  
[PUBMED](#) | [CROSSREF](#)
7. Yoon HM, Kim CG, Lee JY, Cho SJ, Kook MC, Eom BW, et al. Non-exposure simple suturing endoscopic full-thickness resection (NESS-EFTR) versus laparoscopic wedge resection: a randomized controlled trial in a porcine model. *Surg Endosc* 2018;32:2274-2280.  
[PUBMED](#) | [CROSSREF](#)
8. Park JY, Kim YW, Ryu KW, Nam BH, Lee YJ, Jeong SH, et al. Assessment of laparoscopic stomach preserving surgery with sentinel basin dissection versus standard gastrectomy with lymphadenectomy in early gastric cancer-A multicenter randomized phase III clinical trial (SENIORITA trial) protocol. *BMC Cancer* 2016;16:340.  
[PUBMED](#) | [CROSSREF](#)
9. Edge SB, Compton CC, Fritz AG, Greene FL, Trotti A. *AJCC Cancer Staging Handbook*. 7th ed. New York (NY): Springer-Verlag; 2010.
10. Lee YJ, Jeong SH, Hur H, Han SU, Min JS, An JY, et al. Prospective multicenter feasibility study of laparoscopic sentinel basin dissection for organ preserving surgery in gastric cancer: quality control study for surgical standardization prior to phase III trial. *Medicine (Baltimore)* 2015;94:e1894.  
[PUBMED](#) | [CROSSREF](#)
11. Hiki N, Nunobe S, Matsuda T, Hirasawa T, Yamamoto Y, Yamaguchi T. Laparoscopic endoscopic cooperative surgery. *Dig Endosc* 2015;27:197-204.  
[PUBMED](#) | [CROSSREF](#)
12. Goto O, Shimoda M, Sasaki M, Kiguchi Y, Mitsunaga Y, Akimoto T, et al. Potential for peritoneal cancer cell seeding in endoscopic full-thickness resection for early gastric cancer. *Gastrointest Endosc* 2018;87:450-456.  
[PUBMED](#) | [CROSSREF](#)
13. Goto O, Mitsui T, Fujishiro M, Wada I, Shimizu N, Seto Y, et al. New method of endoscopic full-thickness resection: a pilot study of non-exposed endoscopic wall-inversion surgery in an ex vivo porcine model. *Gastric Cancer* 2011;14:183-187.  
[PUBMED](#) | [CROSSREF](#)

14. Mitsui T, Niimi K, Yamashita H, Goto O, Aikou S, Hatao F, et al. Non-exposed endoscopic wall-inversion surgery as a novel partial gastrectomy technique. *Gastric Cancer* 2014;17:594-599.  
[PUBMED](#) | [CROSSREF](#)
15. Goto O, Takeuchi H, Kawakubo H, Matsuda S, Kato F, Sasaki M, et al. Feasibility of non-exposed endoscopic wall-inversion surgery with sentinel node basin dissection as a new surgical method for early gastric cancer: a porcine survival study. *Gastric Cancer* 2015;18:440-445.  
[PUBMED](#) | [CROSSREF](#)
16. Goto O, Takeuchi H, Kawakubo H, Sasaki M, Matsuda T, Matsuda S, et al. First case of non-exposed endoscopic wall-inversion surgery with sentinel node basin dissection for early gastric cancer. *Gastric Cancer* 2015;18:434-439.  
[PUBMED](#) | [CROSSREF](#)