

Technical Note: Arthroscopic Rotator Cuff Repair with Patch Augmentation with Acellular Dermal Allograft



Tracy M. Tauro, B.S., B.A., Kyle R. Wagner, B.S., Steven F. DeFroda, M.D., M.Eng., Sarah Muth, Blake M. Bodendorfer, M.D., Nikhil N. Verma, M.D., and Brian J. Cole, M.D., M.B.A.

Abstract: Rotator cuff tears are one of the most common causes of shoulder pain and dysfunction seen by orthopaedic surgeons. Although rotator cuff repair (RCR) has been shown to provide optimal outcomes, retear rates average roughly 60% and have been reported to exceed 90%. Retear after RCR is especially prevalent in patients with large, multitendon tears with poor tissue quality. Allograft augmentation of RCR may reinforce anatomically reparable tears, particularly in patients with poor tissue quality. Although various techniques of patch augmented RCR have been described, the procedure remains challenging. This Technical Note describes RCR augmented with acellular dermal allograft using the CuffMend system (Arthrex Inc, Naples, FL), which significantly decreases surgeon demand and helps avoid the pitfalls common with this procedure.

The treatment of large multitendon rotator cuff tears remains an imposing challenge to orthopaedic surgeons. Despite numerous advances in repair devices and techniques, retear poses a significant burden in this

patient population.¹ Biologic augmentation of RCR has taken the forefront because of its potential to improve tendon integrity and healing of the tendon-bone interface after RCR.²⁻⁴ Patch augmentation has been shown to be a viable method of improving healing rates after RCR, with acellular dermal allograft being the safest and most frequently studied.^{3,5,6} Augmentation is indicated for patients with large, multitendon tears, particularly in the context of retear and revision surgery.² Additionally, older patients and those with poor tissue quality may be predisposed to have limited healing of the tendon-bone interface, in which a patch augmentation may help bridge the gap by reinforcing type III collagen formation.⁷ Despite promising outcomes of this procedure, its technical aspects are daunting and require not only physician patience but also multiple surgical assistants. Further considerations are listed in [Table 1](#).

Patch augmentation is generally indicated for those with large rotator cuff tears (3-5 cm), prior failed RCR, or chronic tears with poorer tissue quality.⁷ A thorough screening and examination is required to establish that patch augmentation is the most appropriate treatment for the patient; however, the decision is largely based on intraoperative assessment of tissue quantity and quality. Medical history, physical examination, and imaging should be obtained of the affected shoulder. A standard shoulder examination should be performed,

From Midwest Orthopaedics at Rush University Medical Center, Chicago, Illinois, U.S.A. (T.M.T., K.R.W., S.F.D., S.M., B.M.B., N.N.V., B.J.C.) and Department of Orthopaedic Surgery, University of Missouri, Columbia, Missouri, U.S.A. (S.F.D.).

The authors report the following potential conflict of interest or source of funding: N.N.V. reports royalties from Arthroscopy, Smith & Nephew, and Vindico Medical-Orthopedics Hyperguide; research support from Arthrex, Inc., Arthrosurface, DJ Orthopaedics, Ossur, Smith & Nephew, Athletico, ConMed Linvatec, Miomed, and Mitek; and stock or stock options from Cymedica, Minivasive, and Omeros. B.J.C. reports research support from Aesculap/B. Braun, Arthrex, Inc., National Institutes of Health (NIAMS & NICHD), and Regentis; royalties from Arthrex, Inc., Elsevier Publishing, and Operative Techniques in Sports Medicine; and stock or stock options from Bandgrip Inc, Ossio, Regentis; and he is a paid consultant for Arthrex, Inc., Regentis, and Samumed. Full ICMJE author disclosure forms are available for this article online, as [supplementary material](#).

Received August 12, 2021; accepted September 29, 2021.

Address correspondence to Brian J. Cole, M.D., M.B.A., Midwest Orthopaedics at Rush University Medical Center, 1611 W Harrison St, Chicago, IL 60612. E-mail: brian.cole@rushortho.com or cole.research@rushortho.com

© 2021 THE AUTHORS. Published by Elsevier Inc. on behalf of the Arthroscopy Association of North America. This is an open access article under the CC BY-NC-ND license (<http://creativecommons.org/licenses/by-nc-nd/4.0/>).

2212-6287/211176

<https://doi.org/10.1016/j.eats.2021.09.011>

Table 1. Advantages and Disadvantages

Advantages	
Improved tendon integrity	
Premeasured and sized graft	
Ease of graft insertion and placement	
Ease of suture management and equal tension on medial suture limbs	
Disadvantages	
Increased operating time	
Increased cost	
Increased need for surgical assistance	
Technically demanding	

and magnetic resonance imaging (MRI) should be used to examine the size of the tear, fatty infiltration, tendon retraction, and concomitant pathologies. This technique is not indicated for patients with irreparable massive rotator cuff tears (>5 cm) or those with significant glenohumeral osteoarthritis. In this technique article, we describe RCR augmentation with AFLEX acellular dermal allograft (Arthrex Inc, Naples, FL) using the CuffMend system containing the Graft Spreader and TissueTak devices (Arthrex Inc), which address technical concerns such as graft preparation, graft passage and placement, suture management, and surgical assistant demand.

Positioning and Preparation

We administer a regional block in preoperative holding for postoperative pain control, as well as intraoperative relaxation. After induction of general anesthesia, the patient is placed in beach chair positioning on the operating table. After sterile draping, incision sites are marked, and surgical plans are confirmed.

Surgical Technique

A detailed presentation of our technique can be seen in [Video 1](#). We establish the standard posterior viewing portal to perform diagnostic arthroscopy of the glenohumeral joint and establish an anteroinferior portal lateral to the coracoid, which is localized via outside-in technique with a spinal needle. We then transition to the subacromial space where we establish our working portals: a lateral viewing portal in line with posterior border of the clavicle and roughly 3 to 4 cm off the edge of the lateral acromion, posterior working portal (the previous viewing portal), and an anterolateral utility portal with screw-in 8.25 mm cannula (Arthrex Inc) just off the edge of the anterolateral acromion ([Fig 1](#)). Diagnostic arthroscopy is performed, and any concomitant pathology is addressed ([Fig 2](#); 0:09-0:17). Subacromial decompression is achieved with a bone cutting shaver as needed, and a thorough bursectomy is performed for optimal visualization (0:18-0:21). The rotator cuff is mobilized and repaired to the footprint using any one of a variety of techniques depending on

tear type and surgeon preference ([Fig 3](#)). The senior author's preference is a transosseous equivalent repair when possible; however, in the case of poor tissue quality or smaller tears single row repair may also be used with double-loaded anchors as was performed in [Video 1](#). Single-row repair can also leave additional room for lateral fixation of the patch augmentation device once the decision is made to proceed with this technique (0:22-1:10).

The premeasured medium (20 mm × 25 mm × 1 mm) or large (25 mm × 30 mm × 1 mm) AFLEX graft is removed from its packaging, and a marking pen is used to differentiate the articular side of the graft (reticular side of the patch) from the smooth bursal side (1:11-1:16). Two simple stitches are placed on the medial side of the graft using 0 FiberWire sutures (Arthrex Inc) or 0 polydioxanone (PDS) sutures (Ethicon, Inc., Somerville, NJ) in a simple stick fashion, and 2 luggage tag stitches are placed on the lateral side of the graft using 0.9 mm SutureTape TigerLink sutures (Arthrex Inc; 1:17-1:33). The medial PDS stitches are loaded onto the Graft Spreader in crisscross fashion, toggled to provide appropriate tension on the AFLEX graft, and secured to the Graft Spreader handle ([Fig 4](#); 1:34-2:10).

A 10 mm × 4 cm PassPort cannula (Arthrex Inc) is inserted into the lateral portal, and the closed, loaded Graft Spreader is introduced through the PassPort while viewing posteriorly (2:11-2:29). Once appropriate

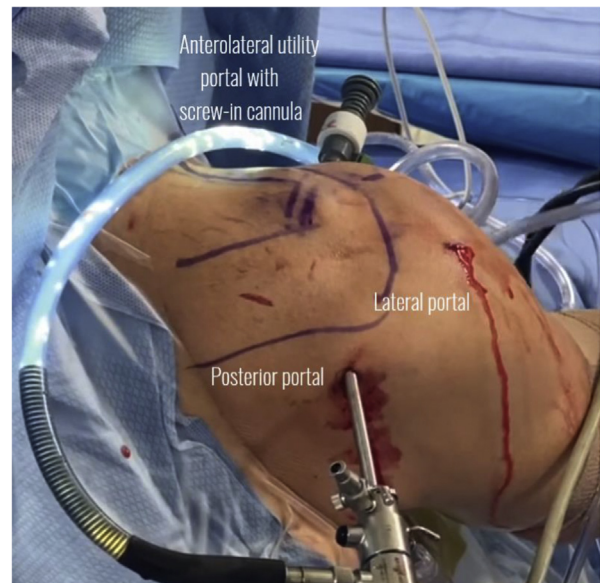


Fig 1. Outside posterior photo of the right shoulder prepped and draped in the beach chair position with diagnostic arthroscopy portals established. We use 3 portals for access to the subacromial space: lateral viewing portal in line with the back of the clavicle and roughly 3 to 4 cm off the edge of the lateral acromion, posterior working portal, and anterolateral utility portal with screw-in 8.25 mm cannula.

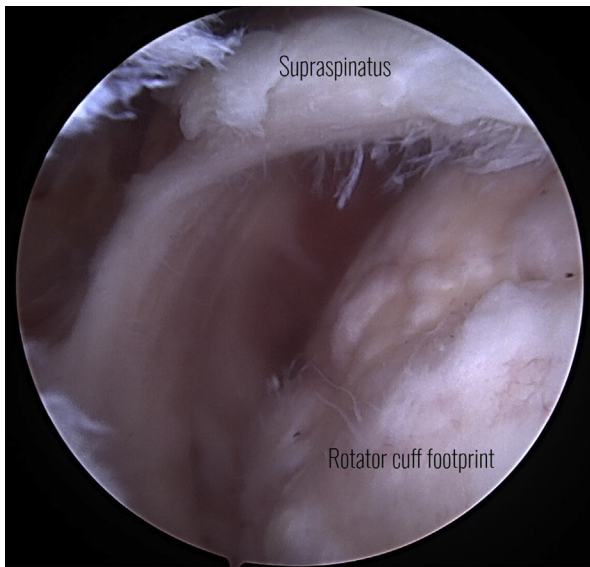


Fig 2. Arthroscopic photo of the right shoulder in the beach chair position viewing posteriorly. Full thickness tears of the supraspinatus and infraspinatus are seen that will be repaired before allograft placement.

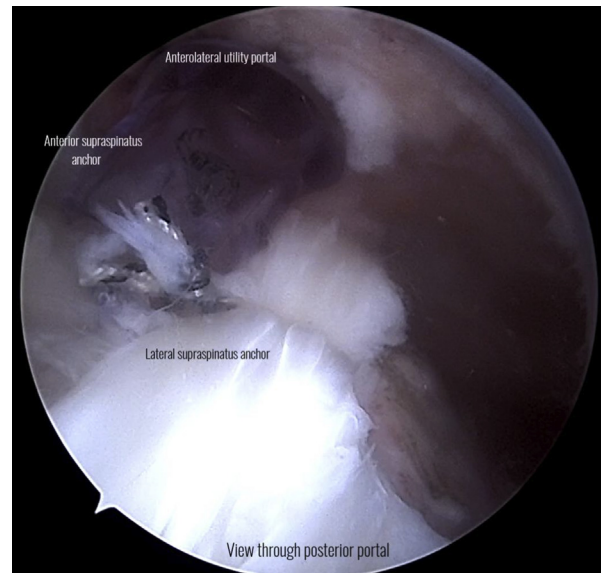


Fig 3. Arthroscopic photo of the right shoulder in the beach chair position displaying the final single row rotator cuff repair construct while viewing posteriorly. The anterolateral portal serves as a utility portal with screw-in 8.25 mm cannula. Anterior and lateral anchors are placed to repair the tendon to the footprint.

positioning of the graft has been achieved, the Graft Spreader is deployed (Fig 5; 2:30-2:56). Medial fixation is achieved using poly(lactic-co-glycolic acid) staples via the SpeedFlex system with TissueTak tendon staples (Arthrex Inc). The TissueTak device containing 10 soft tissue staples is introduced through the anterolateral cannula. An assistant may use a grasper to maintain placement of the graft while the TissueTak device is used to place 6 to 8 percutaneous suture staples medially and peripherally on the graft (Fig 6; 2:57-3:27) facilitated while maintaining the graft spreader in the subacromial space with the attached patch. The medial PDS sutures are cut and removed with the Graft Spreader in place. After medial fixation is achieved, the Graft Spreader may be closed and removed through the PassPort cannula (3:28-3:35). In a similar fashion to a transosseous equivalent repair, the lateral footprint is prepared and the corresponding SutureTape is loaded into 3.5 BioComposite Pushlock Anchors (Arthrex Inc) and tensioned to secure the graft over the rotator cuff footprint (Fig 7; 3:36-4:15). All instruments are removed, and the portals are closed in the standard fashion. Additional surgical technique recommendations are listed in Table 2.

Standard post RCR rehabilitation protocol is used. Patients remain in the sling at all times for 2 weeks, progress to daytime use only from 2 to 4 weeks, and are out of the sling by 4 weeks. Motion is restricted to pendulums and elbow/wrist movement for 2 weeks. Passive range of motion exercises begin at 2 weeks, active assist exercises at 4 weeks, endurance activities at 12 weeks, throwing exercises at 4 months, and return to full activity as tolerated at 6 months.

Discussion

Rotator cuff tears are one of the most common causes of shoulder pain, with an estimated incidence of over 50% in individuals over 80 years old.⁸ Although

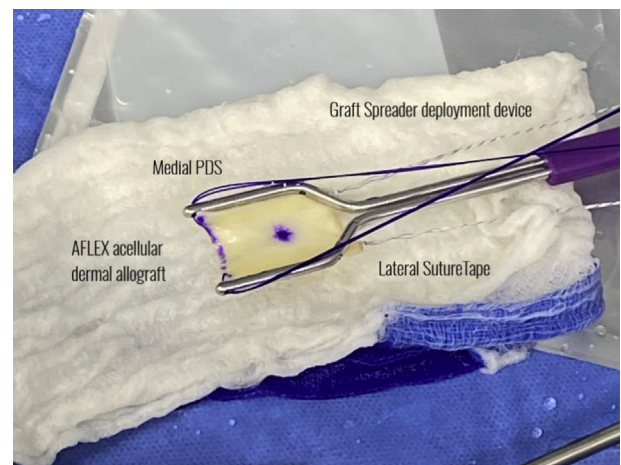


Fig 4. Intraoperative photo of the premeasured medium (20 mm × 25 mm × 1 mm) or large (25 mm × 30 mm × 1 mm) AFLEX acellular dermal allograft being prepared on the back table. The articular side of the graft is marked, and the graft is loaded articular side up. Two simple stitches are placed on the medial side of the graft using 0 FiberWire sutures or 0 PDS sutures in a simple stick fashion, and two luggage tag stitches are placed on the lateral side of the graft using 0.9 mm SutureTape TigerLink sutures. The medial PDS stitches are loaded onto the Graft Spreader in crisscross fashion, toggled to provide appropriate tension on the AFLEX graft, and secured to the Graft Spreader handle.

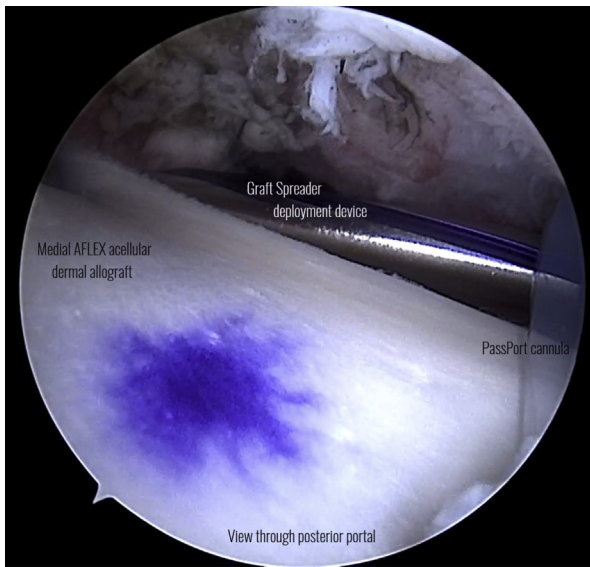


Fig 5. Arthroscopic photo of the right shoulder in beach chair position viewing posteriorly of the Graft Spreader device being deployed through a 10 mm × 4 cm PassPort cannula to be placed overlying the rotator cuff repair construct.

techniques such as double-row repair have been shown to improve outcomes, retear rates after RCR still average roughly 60%, posing a significant burden to orthopaedic surgeons and their patients.^{9,10}

Patch augmentation of RCR can be indicated for large, 2 tendon tears with poor tissue quality.¹¹ Various biologic scaffolds have been used, with xenografts and allografts being the most studied. Although initial

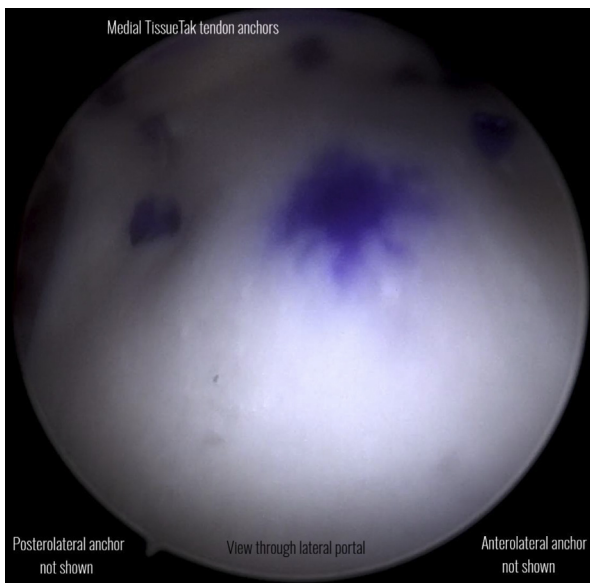


Fig 6. Arthroscopic photo of the right shoulder in beach chair position viewing laterally of the medial fixation of the AFLEX graft, including percutaneous poly(lactic-co-glycolic acid) TissueTak soft tissue staples along the medial edge and periphery.

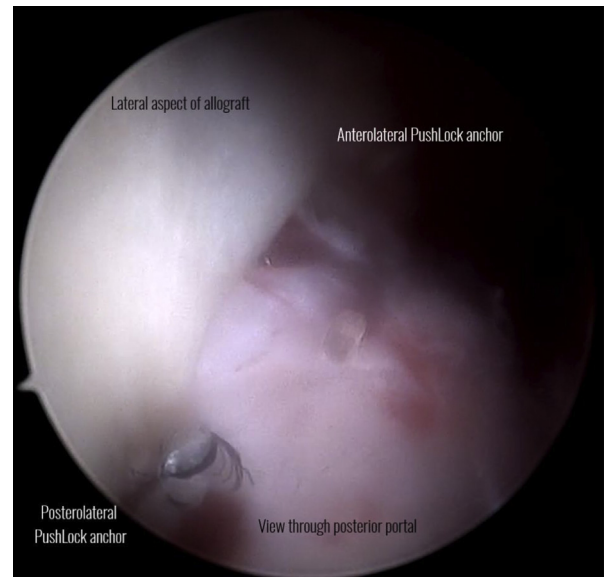


Fig 7. Arthroscopic photograph of the right shoulder in the beach chair position of the lateral fixation of the AFLEX graft, including anterolateral and posterolateral 3.5 mm Bio-Composite Pushlock Anchors tied with SutureTape.

experiments showed evidence of inflammatory response after xenograft augmentation, this adverse response has been greatly lessened in newer iterations.³ In a systematic review comparing RCR augmentation graft types and techniques, Steinhaus et al.⁴ found that allografts showed greater improvements in patient-reported outcomes (PROs) and lower retear rates compared to xenografts. In a case series of 23 patients undergoing RCR augmented with bioinductive collagen patch, Thon et al.¹² demonstrated no adverse outcomes to the patch, 96% healing rates, and new tendon formation via ultrasound scanning and MRI, and no significant differences in American Shoulder and Elbow

Table 2. Pearls and Pitfalls

Pearls

- Thorough subacromial bursectomy must be performed to adequately visualize and place the patch.
- Once the graft is loaded on the back table, trial the device to make sure it collapses and deploys correctly.
- Even spread of the TissueTak staples will ensure proper graft tension and contour.
- Do not over-tension the lateral row anchors and visualize the construct before final tensioning.

Pitfalls

- Inadequate bursectomy, especially medially, can make graft deployment and placement difficult.
- The graft deployment mechanism can stick, making deployment difficult; if this happens use a surgical clamp to fire the device.
- Failure to anchor the graft medially can cause it to sit proud in various areas.
- Overzealous tension of the lateral row can cause the luggage tag sutures to pull through the graft or can displace the medial fixation.

Surgeons (ASES) scores when comparing tear size or revision status.

In a systematic review analyzing outcomes of graft augmentation versus RCR alone, Bailey et al.¹³ found that graft augmentation decreased retear rate and significantly improved ASES scores in comparison to isolated RCR. Similarly, in a prospective, randomized trial of acellular human dermal matrix RCR augmentation, Barber et al.¹⁴ demonstrated no adverse outcomes related to the graft, as well as significantly improved ASES and Constant scores in the augmented group versus RCR alone. Additionally, they demonstrated intact repairs on gadolinium-enhanced MRI in 85% and 40% in the augmented group and isolated RCR group, respectively.¹⁴ In a case study of 9 patients who underwent augmented RCR with acellular dermal allograft, Hall et al.¹⁵ demonstrated intact repairs on ultrasound scanning in 100% of patients at 2-year follow-up. In a prospective case series analyzing clinical and radiographic outcomes of bioabsorbable patch augmented RCR, Burkhard et al.¹⁶ displayed high patient satisfaction, 6.7% retear rate and Sugaya score of 1.7 ± 0.9 on 1-year postoperative MRI.

Potential contraindications must be considered when deciding to use RCR patch augmentation. Increased operating time, cost, and assistant demand must all be considered. However, emerging technologies such as the CuffMend system can simplify the procedure and decrease surgeon demand, making it a safe and more viable option for a broader range of practices.

Conclusion

This article presents the senior author's method of patch-augmented RCR using AFLEX acellular dermal allograft and the CuffMend system. Although more long-term follow-up and randomized-controlled trials are needed in this area of study, preliminary results show RCR patch augmentation to be a safe procedure that demonstrates superior outcomes to RCR alone.

References

1. Le BT, Wu XL, Lam PH, Murrell GA. Factors predicting rotator cuff retears: An analysis of 1000 consecutive rotator cuff repairs. *Am J Sports Med* 2014;42:1134-1142.
2. Chalmers PN, Tashjian RZ. Patch augmentation in rotator cuff repair. *Curr Rev Musculoskelet Med* 2020;13:561-571.
3. Karuppaiah K, Sinha J. Scaffolds in the management of massive rotator cuff tears: Current concepts and literature review. *EFORT Open Rev* 2019;4:557-566.
4. Steinhaus ME, Makhni EC, Cole BJ, Romeo AA, Verma NN. Outcomes after patch use in rotator cuff repair. *Arthroscopy* 2016;32:1676-1690.
5. Seldes RM, Abramchayev I. Arthroscopic insertion of a biologic rotator cuff tissue augmentation after rotator cuff repair. *Arthroscopy* 2006;22:113-116.
6. Sunwoo JY, Murrell GAC. Interposition graft repair of irreparable rotator cuff tears: A review of biomechanics and clinical outcomes. *J Am Acad Orthop Surg* 2020;28(19):e829-e838.
7. Gillespie RJ, Knapik DM, Akkus O. Biologic and synthetic grafts in the reconstruction of large to massive rotator cuff tears. *J Am Acad Orthop Surg* 2016;24:823-828.
8. Tashjian RZ. Epidemiology, natural history, and indications for treatment of rotator cuff tears. *Clin Sports Med* 2012;31:589-604.
9. Shin YK, Ryu KN, Park JS, Jin W, Park SY, Yoon YC. Predictive factors of retear in patients with repaired rotator cuff tear on shoulder MRI. *Am J Roentgenol* 2018;210:134-141.
10. Sheehan AJ, Hartzler RU, Burkhardt SS. Arthroscopic rotator cuff repair in 2019: Linked, double row repair for achieving higher healing rates and optimal clinical outcomes. *Arthroscopy* 2019;35:2749-2755.
11. Thangarajah T, Pendegrass CJ, Shahbazi S, Lambert S, Alexander S, Blunn GW. Augmentation of rotator cuff repair with soft tissue scaffolds. *Orthop J Sports Med* 2015;3(6). 2325967115587495.
12. Thon SG, O'Malley L 2nd, O'Brien MJ, Savoie FH 3rd. Evaluation of healing rates and safety with a bioinductive collagen patch for large and massive rotator cuff tears: 2-year safety and clinical outcomes. *Am J Sports Med* 2019;47:1901-1908.
13. Bailey JR, Kim C, Alentorn-Geli E, et al. Rotator Cuff Matrix Augmentation and Interposition: A systematic review and meta-analysis. *Am J Sports Med* 2019;47:1496-1506.
14. Barber FA, Burns JP, Deutsch A, Labbe MR, Litchfield RB. A prospective, randomized evaluation of acellular human dermal matrix augmentation for arthroscopic rotator cuff repair. *Arthroscopy* 2012;28:8-15.
15. Hall T, Danielson K, Brandenburg S, Matelic T. A case series of recurrent myotendinous rotator cuff tears repaired and augmented with dermal allograft: Clinical outcomes at two years. *J Shoulder Elbow Surg* 2020;29:2264-2271.
16. Burkhard MD, Dietrich M, Andronic O, Nikolic N, Grueninger P. Arthroscopic repair of posterosuperior rotator cuff tears with bioabsorbable patch augmentation: A magnetic resonance-controlled case series with 1-year follow-up. *JSES Int* 2020;4:860-868.