



Correlation Between Cage Positioning and Lumbar Lordosis in Transforaminal Lumbar Interbody Fusion (TLIF)

Correlação entre posicionamento do cage e lordose lombar em fusão transforaminal minimamente invasiva (TLIF)

Emiliano Neves Vialle¹, Guilherme Zandavalli Ramos¹, Fabian Lopez Hinojosa², Alfredo Guiroy³
Luiz Gustavo Dal'Oglio da Rocha¹, André de Oliveira Arruda¹

¹ Spine Surgery Group, Orthopedics and Traumatology Department, Hospital Universitário Cajuru, Curitiba, PR, Brazil

² Spine Surgery Group, Orthopedics and Traumatology Department, Hospital Angeles Valle Oriente, Monterrey, Nuevo León, Mexico

³ Spinal Pathology Unit, Hospital Español de Mendoza, Mendoza, Argentina

Address for correspondence André de Oliveira Arruda, MD, MSc, Av. São José, 300, Curitiba, Paraná, 80050-350, Brazil (e-mail: aoa86@hotmail.com).

Rev Bras Ortop 2022;57(5):821–827.

Abstract

Objective The present study evaluates radiographic outcomes and the lumbar lordosis achieved with a transforaminal lumbar interbody fusion (TLIF) arthrodesis technique according to the positioning of an interbody device (cage) in the disc space.

Methods This is a retrospective radiographic analysis of single-level surgical patients with degenerative lumbar disease submitted to a TLIF procedure and posterior pedicle instrumentation. We divided patients into two groups according to cage positioning. For the TLIF-A group, the cages were anterior to the disc space; for the TLIF-P group, cages were posterior to the disc space. Considering the superior vertebral plateau of the lower vertebra included in the instrumentation, cages occupying a surface equal to the anterior 50% of the midline were placed in the TLIF-A group, and those in a posterior position were placed in the TLIF-P group. We assessed pre- and postoperative orthostatic lateral radiographs to obtain the following measures: lumbar lordosis (LL) (angle L1–S1), segmental lordosis (LS) (L4–S1), and segmental lordosis of the cage (SLC).

Results The present study included 100 patients from 2011 to 2018; 44 were males, and 46 were females. Their mean age was 50.5 years old (range, 27 to 76 years old). In total, 43 cages were “anterior” (TLIF-A) and 57 were “posterior” (TLIF-P). After surgery, the mean findings for the TLIF-A group were the following: LL, 50.7°, SL 34.9°, and SLC 21.6°; in comparison, the findings for the TLIF-P group were the following: LL, 42.3° ($p < 0.01$), SL 30.7° ($p < 0.05$), and SLC 18.8° ($p > 0.05$).

Keywords

- ▶ spondylolisthesis
- ▶ lordosis
- ▶ spinal fusion
- ▶ lumbosacral region

* Work developed in the Spine Surgery Group of the Department of Orthopedics and Traumatology, Hospital Universitário Cajuru, Curitiba, Brazil.

received
November 7, 2021
accepted after revision
June 27, 2022

DOI <https://doi.org/10.1055/s-0042-1756215>.
ISSN 0102-3616.

© 2022. Sociedade Brasileira de Ortopedia e Traumatologia. All rights reserved.

This is an open access article published by Thieme under the terms of the Creative Commons Attribution-NonDerivative-NonCommercial-License, permitting copying and reproduction so long as the original work is given appropriate credit. Contents may not be used for commercial purposes, or adapted, remixed, transformed or built upon. (<https://creativecommons.org/licenses/by-nc-nd/4.0/>)

Thieme Revinter Publicações Ltda., Rua do Matoso 170, Rio de Janeiro, RJ, CEP 20270-135, Brazil

Resumo

Conclusion Cage positioning anterior to the disc space improved lumbar and segmental lordosis on radiographs compared with a posterior placement.

Objetivo Avaliar os resultados radiográficos e comparar a lordose pós-operatória em técnica de artrodese intersomática lombar transforaminal (TLIF, na sigla em inglês), considerando como variável o posicionamento do dispositivo intersomático (*cage*) em relação ao espaço discal.

Métodos Análise retrospectiva radiográfica de pacientes cirúrgicos, em nível único, por doença lombar degenerativa, aplicando-se TLIF e instrumentação pedicular posterior. Os pacientes foram divididos, conforme a posição do *cage*, em 2 grupos: 1. TLIF-A – *cages* na posição anterior do espaço discal; e 2. TLIF-P, *cages* na posição posterior do espaço discal (considerando-se o platô vertebral superior da vértebra inferior incluída na instrumentação, *cages* que ocuparam a superfície correspondente a 50% anterior da linha média, compuseram o grupo TLIF-A; opostamente, *cages* em posicionamento posterior compuseram o grupo TLIF-P). Procedeu-se à avaliação dos exames radiográficos ortostáticos em perfil no pré- e pós-operatórios, com a tomada das seguintes medidas: lordose lombar (LL) (ângulo L1–S1); lordose segmentar (LS) (L4–S1) e lordose segmentar do *cage* (LSC).

Resultados Cem pacientes foram incluídos de 2011 a 2018, sendo 44 homens e 46 mulheres, com idade média de 50.5 anos (27–76 anos). Um total de 43 *cages* foram classificados como “anteriores” (TLIF-A) e 57, “posteriores” (TLIF-P); considerando o grupo TLIF-A, os resultados pós-operatórios médios foram: LL 50.7°, LS 34.9° e LSC 21.6°; para o grupo TLIF-P, comparativamente: LL 42.3° ($p < 0,01$), LS 30.7° ($p < 0,05$) e LSC 18.8° ($p > 0,05$).

Conclusão: O posicionamento anterior do *cage* em relação ao espaço discal correlaciona-se a melhora da lordose lombar e segmentar na radiografia em comparação com o posicionamento posterior do implante.

Palavras-chave

- ▶ espondilolistese
- ▶ lordose
- ▶ fusão vertebral
- ▶ região lombossacral

Introduction

Lumbar arthrodesis with instrumentation has become part of the daily practice of a spinal surgeon. Interbody device (*cage*) implant with a pedicle screw system increased arthrodesis rates;¹ however, the literature is not consistent regarding the ability of these devices to gain lumbar lordosis (LL) and eventually improve sagittal alignment.^{2,3} Today, posterior interbody arthrodesis is the most performed surgical procedure in absolute numbers, possibly due to the greater familiarity of surgeons with this approach compared with the anterior and lateral alternatives.

Transforaminal lumbar interbody fusion (TLIF) requires less dura mater and descending nerve root retraction, minimizing the risk of neurological injury compared with the traditional midline interbody arthrodesis.³ Considering the biomechanics, cage positioning within the disc space has a direct correlation with the construct stability. The anterior positioning is reportedly more stable than the central and posterior counterparts.⁴

Restoring the sagittal alignment of the spine is crucial for the success of arthrodesis. In addition, it correlates with optimized clinical outcomes.^{2–4} A cage allows load support by the anterior column, increases arthrodesis rates, and promotes indirect foraminal decompression due to the height gain

at the approached disc level.⁵ If a minimally invasive surgery (MIS) is feasible, procedures can result in lower tissue aggression and in a shorter, optimized surgical recovery.⁶ Minimally invasive surgery has significant advantages over traditional techniques; nevertheless, once the contralateral midline structures and facet joints remain intact, the potential for disc height gain and segmental lumbar lordosis is substantially reduced.⁷ The present study aims to compare a TLIF-type cage device implant to the center of the disc space, ascertaining the potential radiographical improvement of the LL correction by an anterior positioning.

Materials and Methods

Study Design

The present study compares sagittal alignment parameters before and after a MIS-TLIF in a single-disc level. For the retrospective data collection, we accessed a database with available radiographic measurements and evaluated lumbo-sacral spine tests. These analyses allowed a complete and clear identification from the upper plateau of L1 to the sacrum of patients undergoing this surgery due to degenerative conditions from January 2001 to January 2018. After an initial survey of the sample, we excluded nondegenerative cases, those with previous deformities of a different nature,

revision surgeries, and poor-quality radiographs that hindered proper measurements.

We divided the patients into two groups according to cage positioning: anterior (TLIF-A) and posterior (TLIF-P). We analyzed lateral lumbosacral spinal radiographs in orthostasis before and within the 1st week after surgery to obtain the required measurements.

The Fisher exact test, the chi-squared test, and the Student t-test described any differences between groups (TLIF-A versus TLIF-P). Statistical significance was set as $p < 0.05$. Data extraction and evaluation were performed in IBM SPSS Statistics for Windows, version 23.0 (IBM Corp., Armonk, NY, USA).

Demographics

The Institutional Ethics Committee reviewed and approved the present project. Next, we included patients with lumbar degenerative diseases, stenosis with instability, and degenerative spondylotic listhesis treated with a single-level TLIF (L3–L4, L4–L5, or L5–S1). We suggested dividing groups A and P into three subgroups because of their different levels, which can influence the biomechanics of the instrumented unit and of the lumbar region. The exclusion criteria were a positive history of previous spine surgery and patients undergoing multiple fusion levels. We included radiographs with Pfirrmann degeneration grades 3 or 4; however, we excluded those classified as Pfirrmann 5 to reduce internal variability, since the number of patients undergoing MIS-TLIF under this condition was expressively low.

Surgical technique

A single spinal surgeon operated on all patients included in the present study. Starting from the Wilson-type spine support position, the surgeon made a bilateral posterolateral lumbar incision up to the fascia level (Wiltse approach). Applying traditional or tubular retractors, the surgeon exposed the articular facets and bases of the transverse processes of the instrumented lumbar level. Then, the surgeon placed bilateral pedicle screws in the segment determined for arthrodesis and performed a unilateral facetectomy on the most symptomatic side, followed by a neural decompression according to the clinical picture. The surgeon prepared the disc space using curettes and dilators, inserting the interbody spacer (cage) by TLIF and applying heights from 9 to 13 mm. All devices consisted of poly-ether-ether-ketone (PEEK). Special attention was given to the surgical positioning of patients on the operating table, seeking hip extension and lordosis increase with a Wilson-type support.

Radiographic assessment

We evaluated preoperative and postoperative lateral radiographs in orthostasis using the Surgimap (Surgimap, Nova York, NY, EUA) software to obtain sagittal alignment parameters. The measurements were the following: LL – Cobb angle formed by the superior vertebral plateau of L1 and the sacral line (S1); segmental lordosis (SL) – Cobb angle formed by the superior plateau of L4 and the sacral line (S1); and segmental lordosis of the cage (SLC) – Cobb angle formed by the superior plateau of the superiorly fused vertebra and the

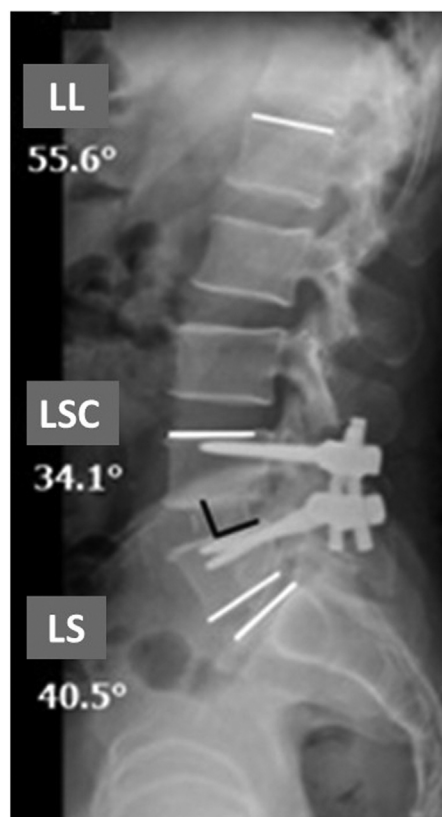

Fig. 1 Lateral spine radiograph demonstrating the angular measurements after cage introduction. LL, lumbar lordosis; SLC, segmental lordosis of the cage; SL, segmental lordosis.

inferior plateau of the inferiorly fused vertebra after cage implant (► **Figure 1**).³

The Surgimap software analyzed a lateral radiograph of the patient in orthostasis to determine cage positioning (anterior versus posterior). The space of the instrumented level was measured and divided in its center at a sagittal incidence. Cages positioned in $> 50\%$ of the anterior half of the superior vertebral plateau from the inferior instrumented vertebra were classified as anterior (TLIF-A), while the remaining cages composed the posterior group (TLIF-P) (► **Figures 1 and 2**).

Results

Demographics

Complying with the inclusion and exclusion criteria and with the study duration, the final sample had 100 patients ($n = 100$). From the 134 initially selected cases, we excluded 17 due to the low radiographic quality regarding the pre-established parameters; 10 subjects potentially had other previous diseases or a history of spinal surgery; and 7 patients did not adequately complete the documentation required for research participation, even though this was only an imaging analysis with no personal identification. Demographically, 54 patients were male and 46 were female, with a mean age of 50.5 years old (range: 27 to 76 years old). Females were significantly older than males (54 versus 47.5

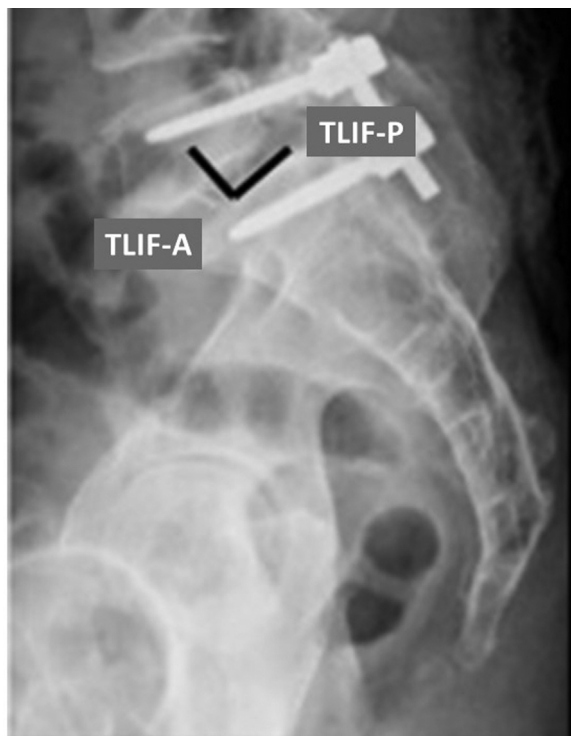


Fig. 2 Lateral spine radiograph demonstrating the criterium for cage positioning at the intervertebral space. TLIF-A, transforaminal lumbar interbody fusion with an anterior cage; TLIF-P, transforaminal lumbar interbody fusion with a posterior cage.

years old, respectively; $p < 0.05$). Degenerative spondylolisthesis was the most prevalent condition (45% of the cases). The most commonly addressed levels were L4–L5 (16% for TLIF-A and 39% for TLIF-P) (► **Tables 1 and 2**).

Radiographic analysis'

Patients who underwent TLIF-A presented the following results (mean values): preoperative LL, 53.93°; postoperative LL, 50.72°; preoperative SL, 35.9°; postoperative SL, 34.9°;

preoperative SLC, 21.3°; and postoperative SLC, 21.6°. For the TLIF-P group, results were the following: preoperative LL, 52.5°; postoperative LL, 43.5°; preoperative SL, 35.6°; postoperative SL, 31.6°; preoperative SLC, 20.6°; and postoperative SLC, 19.8° (► **Table 3**).

We calculated the differences between preoperative and postoperative assessments and compared them according to the positioning of the cage. Statistical significance was observed for LL, with a numerical advantage for the TLIF-A group (higher lordosis gain; $p < 0.01$); the same was true for SL ($p < 0.05$). There was no difference regarding SLC, although we observed a trend for favorable results in the TLIF-A group (► **Table 4**).

A joint group analysis revealed no statistical significance regarding sample stratification per age or gender. In addition, the analysis of the preoperative measurements showed no statistical difference between the TLIF-A and TLIF-P groups, indicating the homogeneity of the sample.

Patients with preoperative LL $< 50^\circ$ had the cage positioned anteriorly in 36% of the cases; the opposite occurred in those with a preoperative LL $> 50^\circ$ (45% had the device positioned anteriorly). Considering LL as lower or higher than 50° , there was a statistical significance regarding preoperative and postoperative LL, SL, and SLC parameters (► **Table 5**).

Discussion

Lumbar interbody arthrodesis using TLIF has become a popular procedure with good radiographic and clinical outcomes. In addition, it promotes direct and indirect foraminal decompression in cases of degenerative lumbar diseases. Cage positioning is crucial for an adequate sagittal alignment. The anterior placement corrects the fulcrum supported on the instrumented level, increasing lordosis with the insertion of posterior pedicle screws and arthrodesis system locking under compression.

Table 1 Demographic data from the TLIF-A and TLIF-P groups

		Group		Total
		TLIF-A	TLIF-P	
Gender	Male (n)	25	29	54
	Female (n)	18	28	46
Age	Mean (years)	52	49	
Surgical indication	Stenosis with instability (n)	16	13	29
	Degenerative spondylolisthesis (n)	16	29	45
	Lytic spondylolisthesis (n)	11	15	26
Instrumented level	L5–S1 (n)	26	11	37
	L4–L5 (n)	16	39	55
	L3–L4 (n)	1	7	8
Total (n)		43	57	100

Abbreviations: TLIF-A, transforaminal lumbar interbody fusion with an anterior cage; TLIF-P, transforaminal lumbar interbody fusion with a posterior cage.

Table 2 Preoperative and postoperative comparison of data from lateral radiographs in orthostasis

	Age (years old)	Preop LL (L1–S1)	Preop SL (L4–S1)	Preop SLC (variable)	Postop LL (L1–S1)	Postop SL (L4–S1)	Postop SLC (variable)	TLIF-A	TLIF-P
Mean	50.5	53.09	35.7	20.92	46.61	33.03	20.5	43	57
Male (n = 54)	47.5	52.26	35.98	21.80	47.17	33.31	20.69	25	29
Female (n = 46)	54	54.07	35.37	19.89	45.96	32.70	20.28	18	28
Comparative p-value	< 0.05	0.22	0.38	0.14	0.31	0.37	0.40		

Abbreviations: LL, Lumbar lordosis; Preop, preoperative; Postop, postoperative; SL, segmental lordosis; SLC, segmental lordosis of the cage; TLIF-A, transforaminal lumbar interbody fusion with an anterior cage; TLIF-P, transforaminal lumbar interbody fusion with a posterior cage.

Table 3 Comparison of preoperative and postoperative lordosis parameters according to cage positioning (TLIF-A versus TLIF-P)

	n	Age (years old)	Preop LL (L1–S1)	Preop SL (L4–S1)	Preop SLC (variable)	Postop LL (L1–S1)	Postop SL (L4–S1)	Postop SLC (variable)
TLIF-A	43	52	53.93	35.88	21.28	50.72	34.91	21.56
TLIF-P	57	49	52.46	35.56	20.65	43.51	31.61	19.70
Comparative p-value		0.05	0.26	0.43	0.36	0.001	0.03	0.12

Abbreviations: LL, Lumbar lordosis; Preop, preoperative; Postop, postoperative; SL, segmental lordosis; SLC, segmental lordosis of the cage; TLIF-A, transforaminal lumbar interbody fusion with an anterior cage; TLIF-P, transforaminal lumbar interbody fusion with a posterior cage.

Table 4 Statistical analysis comparing TLIF-A with TLIF-P

	Preop LL (L1–S1)	Preop SL (L4–S1)	Preop SLC (variable)	Postop LL (L1–S1)	Postop SL (L4–S1)	Postop SLC (variable)	Preop LL (L1–S1)	Preop SL (L4–S1)	p-value
TLIF-A (n = 43)	53.93	50.72	< 0.05	35.88	34.91	> 0.05	21.28	21.56	> 0.05
TLIF-P (n = 57)	52.46	43.51	< 0.01	35.56	31.61	< 0.05	20.65	19.70	> 0.05

Abbreviations: LL, Lumbar lordosis; Preop, preoperative; Postop, postoperative; SL, segmental lordosis; SLC, segmental lordosis of the cage; TLIF-A, transforaminal lumbar interbody fusion with an anterior cage; TLIF-P, transforaminal lumbar interbody fusion with a posterior cage.

Despite the surgical challenges for anterior cage positioning, this outcome is often not feasible because of the anatomical features of the vertebral plate, the complete collapse of the instrument disc space, or the cage format itself.

We identified an overall decrease in postoperative lumbar lordosis compared with the preoperative values regardless of cage positioning. This finding is consistent with a previous study performed by us on the same topic. Moreover, the literature reports that the posterior positioning of the cage, in this context, generates a significant loss of lumbar lordosis compared with the anterior positioning. Hsieh et al.⁸ published similar results, with decreased LL and segmental disc angle in the postoperative period. They attributed these findings to the challenges of anterior cage positioning and unilateral facetectomy to the detriment of a bilateral procedure.

Kepler et al.⁹ evaluated 45 patients undergoing a single-level TLIF. These authors reported a mean increase of 3.6° in LL and a mean final disc height gain of 4.5 mm. The latter was associated with the anterior positioning of the cage, with no repercussions for LL.

Our study revealed a postoperative improvement in lumbar and segmental lordosis for the TLIF-A group compared with the TLIF-P group. In some cases, the intraoperative

anterior positioning of the cage was a challenge, mostly because of the concavity of the superior vertebral plateau. As such, the cage went towards the center of the disc space, reducing its anteriorization. We only performed unilateral facetectomies, a potentially significant limiting factor for lordosis gain. Compared with the current practice, we adopted the bilateral facet approach as a standard, resulting in better lumbar lordosis gain.

In a retrospective cohort study, Tye et al.¹⁰ demonstrated that a bilateral facetectomy with a single-level TLIF improved clinical outcomes compared with the unilateral facet approach. In addition, they reported no negative impact on perioperative complications or final radiographic parameters. Considering the improvement in sagittal alignment because of the gain in lordosis, maybe we should perform bilateral facetectomies and, perhaps, more aggressive discectomies.³

In contrast to our findings, the literature shows that the anteroposterior positioning of the cage regarding the disc space has no direct influence over postoperative lumbar lordosis. For Faundez et al.,¹¹ neither positioning (TLIF-A and TLIF-P) could change the final SL, since the unilateral TLIF technique keeps the anterior and posterior longitudinal ligaments intact. Similarly, Salem et al.¹² reported that a

Table 5 Comparison of subjects with preoperative lumbar lordosis lower or higher than 50°

	Age (years old)	Gender (M/F)	Preop LL	Preop SL	Preop SLC	Postop LL	Postop SL	Postop SLC	Cage positioning	Δ LL	Δ SL	Δ SLC
LL < 50°	50.6	22M/16F	41.18	27.18	17.13	40.89	28.13	18.42	14 TLIF-A 24 TLIF-P	0.29	- 0.95	- 1.29
LL > 50°	50.5	32M/30F	52.97	35.62	20.88	46.55	32.98	20.48	28 TLIF-A 34 TLIF P	6.42	2.63	0.4
Valor de p	0.45		< 0.0001	< 0.0001	0.0002	< 0.0001	< 0.0001	0.01		< 0.0001	< 0.0001	0.06

Abbreviations: F, Female; LL, lumbar lordosis; M, male; Preop, preoperative; Postop, postoperative; SLC, segmental lordosis of the cage; TLIF-A, transforaminal lumbar interbody fusion with an anterior cage; TLIF-P; transforaminal lumbar interbody fusion with a posterior cage.

single-level TLIF had no impact on postoperative LL regarding variables such as approach type, instrumented level, the performance of facetectomies, and cage positioning to the disc space. These authors highlighted the absence of segmentar lumbar lordosis gain for the bilateral facet approach group compared with unilateral facetectomy alone.

The surgical outcomes from these authors led to the recommendation of a maximal anterior positioning for optimal lumbar lordotic potential gain, which consistent with the literature.^{13,14} Therefore, a lumbar interbody fusion using the TLIF technique may improve lumbar lordosis, reducing pelvic compensation. Alone, however, it may be unable to correct all sagittal alignment losses.¹⁵

We compared the results according to cage positioning (TLIF-A versus TLIF-P) using a preoperative LL cutoff value of 50°. There was a significant gain in the final LL for patients with an initial LL > 50°. However, this gain was not significant when the preoperative LL was < 50°, indicating that these subjects require additional techniques to improve sagittal alignment regardless of cage positioning.

We must also consider the potential subsidence of the cage in prolonged segments. Interbody arthrodesis using a single-level transforaminal technique resulted in a significant radiographic gain in LL in early postoperative evaluations. This gain, however, progressively decreased over 1 year of follow-up and reached a point of insignificance compared with the last assessment. Thus, to avoid this outcome, the literature recommends angled cages constructed to increase the anterior lordosis and their insertion as anteriorly as possible within the disc space.¹⁴

Conclusion

A TLIF with anterior cages has better radiographic outcomes regarding LL and SL compared with posterior devices in spinal fusion surgeries with a single-level approach. There was no significant difference regarding the SL of the arthrodesis segment and no preoperative variable correlated with the final positioning of the cage. We identified a general decreasing trend for LL and SL. A stratification for preoperative LL (50°) showed that the anterior positioning improved the final LL value in patients with a preoperative LL > 50°.

Financial Support

The present study received no financial support from either public, commercial, or not-for-profit sources.

Conflict of Interests

The authors have no conflict of interests to declare.

References

- Jalalpour K, Neumann P, Johansson C, Hedlund R. A Randomized Controlled Trial Comparing Transforaminal Lumbar Interbody Fusion and Uninstrumented Posterolateral Fusion in the Degenerative Lumbar Spine. *Global Spine J* 2015;5(04):322-328
- Vialle EN, Vialle LRG, Gusmão MS, et al. Discectomia lombar transforaminal: estudo quantitativo em cadáveres. *Coluna/Columna* 2009;8(02):134-138

- 3 Vialle E, Schleifer D, Carneiro A, Colina O, Vialle LR. Changes in radiographic parameters after minimally invasive lumbar interbody fusion. *Coluna/Columna* 2015;14(04):265–267
- 4 Polly DW Jr, Klemme WR, Cunningham BW, Burnette JB, Haggerty CJ, Oda I. The biomechanical significance of anterior column support in a simulated single-level spinal fusion. *J Spinal Disord* 2000;13(01):58–62
- 5 Tallarico RA, Lavelle WF, J Bianco A, Taormina JL, Ordway NR. Positional effects of transforaminal interbody spacer placement at the L5-S1 intervertebral disc space: a biomechanical study. *Spine J* 2014;14(12):3018–3024
- 6 Shunwu F, Xing Z, Fengdong Z, Xiangqian F. Minimally invasive transforaminal lumbar interbody fusion for the treatment of degenerative lumbar diseases. *Spine* 2010;35(17):1615–1620
- 7 Lee JC, Jang HD, Shin BJ. Learning curve and clinical outcomes of minimally invasive transforaminal lumbar interbody fusion: our experience in 86 consecutive cases. *Spine* 2012;37(18):1548–1557
- 8 Hsieh PC, Koski TR, O'Shaughnessy BA, et al. Anterior lumbar interbody fusion in comparison with transforaminal lumbar interbody fusion: implications for the restoration of foraminal height, local disc angle, lumbar lordosis, and sagittal balance. *J Neurosurg Spine* 2007;7(04):379–386
- 9 Kepler CK, Rihn JA, Radcliff KE, et al. Restoration of lordosis and disk height after single-level transforaminal lumbar interbody fusion. *Orthop Surg* 2012;4(01):15–20
- 10 Tye EY, Alentado VJ, Mroz TE, Orr RD, Steinmetz MP. Comparison of Clinical and Radiographic Outcomes in Patients Receiving Single-Level Transforaminal Lumbar Interbody Fusion With Removal of Unilateral or Bilateral Facet Joints. *Spine* 2016;41(17):E1039–E1045
- 11 Faundez AA, Mehbod AA, Wu C, Wu W, Ploumis A, Transfeldt EE. Position of interbody spacer in transforaminal lumbar interbody fusion: effect on 3-dimensional stability and sagittal lumbar contour. *J Spinal Disord Tech* 2008;21(03):175–180
- 12 Salem KMI, Eranki AP, Paquette S, et al. Do intraoperative radiographs predict final lumbar sagittal alignment following single-level transforaminal lumbar interbody fusion? *J Neurosurg Spine* 2018;28(05):486–491
- 13 Jagannathan J, Sansur CA, Oskouian RJ Jr, Fu KM, Shaffrey CI. Radiographic restoration of lumbar alignment after transforaminal lumbar interbody fusion. *Neurosurgery* 2009;64(05):955–963, discussion 963–964
- 14 Kim SB, Jeon TS, Heo YM, et al. Radiographic results of single level transforaminal lumbar interbody fusion in degenerative lumbar spine disease: focusing on changes of segmental lordosis in fusion segment. *Clin Orthop Surg* 2009;1(04):207–213
- 15 Ould-Slimane M, Lenoir T, Dauzac C, et al. Influence of transforaminal lumbar interbody fusion procedures on spinal and pelvic parameters of sagittal balance. *Eur Spine J* 2012;21(06):1200–1206