



Case report

Poorly differentiated, ovarian Sertoli-Leydig cell tumor with heterologous rhabdomyosarcoma and glandular elements: Diagnosis and management of a rare neoplasm



Charanjeet Singh^{a,*}, Sarfraz Ahmad^{b,*}, Fouad M. Hajjar^c, Robert W. Holloway^b

^a Department of Pathology & Laboratory Medicine, Florida Hospital, Orlando, FL 32804, USA

^b Department of Gynecologic Oncology, Florida Hospital, Orlando, FL 32804, USA

^c Department of Pediatric Hematology-Oncology, Florida Hospital, Orlando, FL 32804, USA

ARTICLE INFO

Keywords:

Sertoli-Leydig cell tumor
Rhabdomyosarcoma
AFP
Ovarian cyst
Literature review

ABSTRACT

Ovarian Sertoli-Leydig cell tumors (SLCT) represent < 2% of primary ovarian tumors, which range from benign to malignant; majority of the latter are low-grade. We present the case of a 12-year-old pre-pubertal female with poorly differentiated SLCT and heterologous rhabdomyosarcoma (FIGO stage-IA). She presented with worsening abdominal pain, pelvic mass, and elevated pre-operative serum Alpha-fetoprotein (AFP, 77.1 ng/mL). She underwent right salpingo-oophorectomy, omentectomy, and lymphadenectomy. The high-risk histology warranted 4-cycles of adjuvant BEP chemotherapy. There was no clinical evidence of recurrence at the 20-month follow-up. High-grade sex cord-stromal tumors are rare, present with low-stage disease, and have good progression-free survival following chemotherapy. Rarity of these tumors poses challenges in their diagnosis and treatment. Review of literature suggests that the presented case is youngest patient with dedifferentiated SLCT.

1. Introduction

Ovarian Sertoli-Leydig cell tumors (SLCT) are sex cord-stromal tumors that represent < 2% of all primary ovarian tumors, and their clinicopathologic behavior ranges from benign to malignant. Pathologically, SLCTs are sub-divided into ‘well’, ‘moderately’, and ‘poorly’ differentiated tumors depending on the degree of tubular differentiation of the Sertoli cell component. The “poorly differentiated” SLCTs are mostly spindle and tumors with dedifferentiation to glandular and sarcomatous areas have been reported.

Clinical course of these tumors may not always correlate with grade; the stage usually determines prognosis. The majority of tumors are well-to-moderately differentiated, and are successfully treated with surgery. Because of their scarcity, poorly differentiated SLCTs represent a challenge in both the diagnosis and the management, with limited case-report experience available. Herein, we present a rare case of a poorly differentiated SLCT containing heterologous rhabdomyosarcoma elements, and summarize the available literature including management.

2. Case presentation

A 12-year old pre-pubertal female patient presented with a history of slowly worsening abdominal pain of 2-weeks duration, and vomiting. A contrast enhanced computed tomography (CT)-scan of abdomen and pelvis showed an 11.7 × 10.1 × 7.9 cm heterogeneous cystic and solid mass, confined to the right adnexa [Fig. 1]. The radiologic differential diagnosis included a torsed and hemorrhagic ovarian cyst versus an ovarian malignancy.

Serological assessments revealed elevated levels of lactate dehydrogenase (LDH: 351 U/L), CA-125 (77 U/mL), Alpha-fetoprotein (AFP: 77.1 ng/mL), and Inhibin-beta (114 pg/mL). Beta-human chorionic gonadotrophin (β-HCG), free testosterone, and carcinoembryonic antigen (CEA) were normal.

Exploratory laparotomy, right salpingo-oophorectomy, peritoneal staging biopsies, infra-colic omentectomy, and right pelvic and infra-renal aortic lymphadenectomy were performed.

On gross examination of the specimen, the tumor involved ovarian parenchyma and had both cystic and solid areas. The ovarian capsule was intact and without surface involvement. Histopathologic examination showed an extensively necrotic tumor with focal areas of well-differentiated tubules of Sertoli cell component [Fig. 2A] admixed

* Corresponding authors at: Departments of Pathology & Laboratory Medicine, or Gynecologic Oncology, Florida Hospital Cancer Institute, 2501 N. Orange Ave., Suite 786, Orlando, FL 32804, USA.

E-mail addresses: charanjeet.singh.MD@flhosp.org (C. Singh), sarfraz.ahmad@flhosp.org (S. Ahmad).

<https://doi.org/10.1016/j.gore.2018.06.003>

Received 20 March 2018; Received in revised form 2 June 2018; Accepted 7 June 2018

Available online 12 June 2018

2352-5789/ © 2018 Published by Elsevier Inc. This is an open access article under the CC BY-NC-ND license

(<http://creativecommons.org/licenses/by-nc-nd/4.0/>).

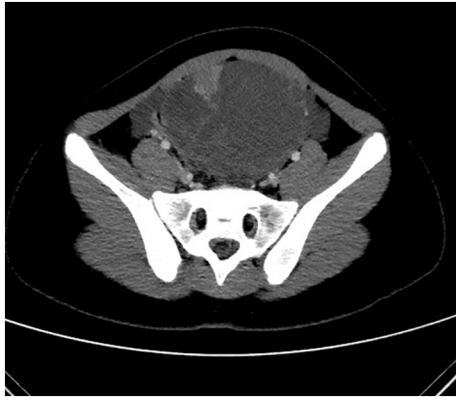

Fig. 1. Computed tomography (CT) scan abdominopelvic region showing heterogeneous hemorrhagic cystic and solid mass.

with Leydig cells with abundant eosinophilic cytoplasm. Both the Sertoli and Leydig cell components were positive for inhibin [Fig. 2A, right]. Leydig cells were positive for AFP, consistent with the increased serum levels (Fig. 3B). There was no associated yolk-sac component with AFP stain. Well-differentiated tubules and Leydig cells formed a minor component. The majority of the tumor was spindled and also stained for Inhibin. This component showed a high mitotic index of up to 32 per 10 high power fields and is consistent with poorly

differentiated Sertoli cell component. Areas of the spindled component showed punctate necrosis. Admixed with the poorly differentiated Sertoli component are bland, mucin-producing glandular elements [inhibin positivity focally, but AFP negative Fig. 2B]. An additional (5 to 10%) component of spindle cells show marked atypia, with increased eosinophilic cytoplasm and rare strap cells [Fig. 2C, hematoxylin & eosin (H&E), left]. These showed nuclear positivity for MyoD1 and myogenin [Fig. 2C, right], but negative for inhibin, consistent with heterologous rhabdomyosarcoma. Submitted lymph nodes, staging peritoneal biopsies and omentum showed reactive changes, but were negative for tumor.

The tumor was staged as FIGO stage IA. Post-operative CT-scan of the chest was normal and no metastatic disease was identified. Due to high-risk histology, 4-cycles of adjuvant chemotherapy were administered using cisplatin 33 mg/m² on days 1–3, etoposide 167 mg/m² on days 1–3, bleomycin 15 U/m² on day-1. The patient tolerated chemotherapy well, and no significant side-effects were noted during chemotherapy.

Patient's AFP levels measured 3.7, 4.3, and 6.5 (lab reference level AFP < 6.0 ng/mL) at the 3, 6, and 13 month follow-ups, respectively. Fig. 3 (A) shows a graphical trend of the AFP levels from post-operative day-zero to the most recent serologic follow-up. There was no clinical, and radiologic evidence of recurrence at 20-month follow-up. Patient started on regular menstrual cycles at 11 months since diagnosis.

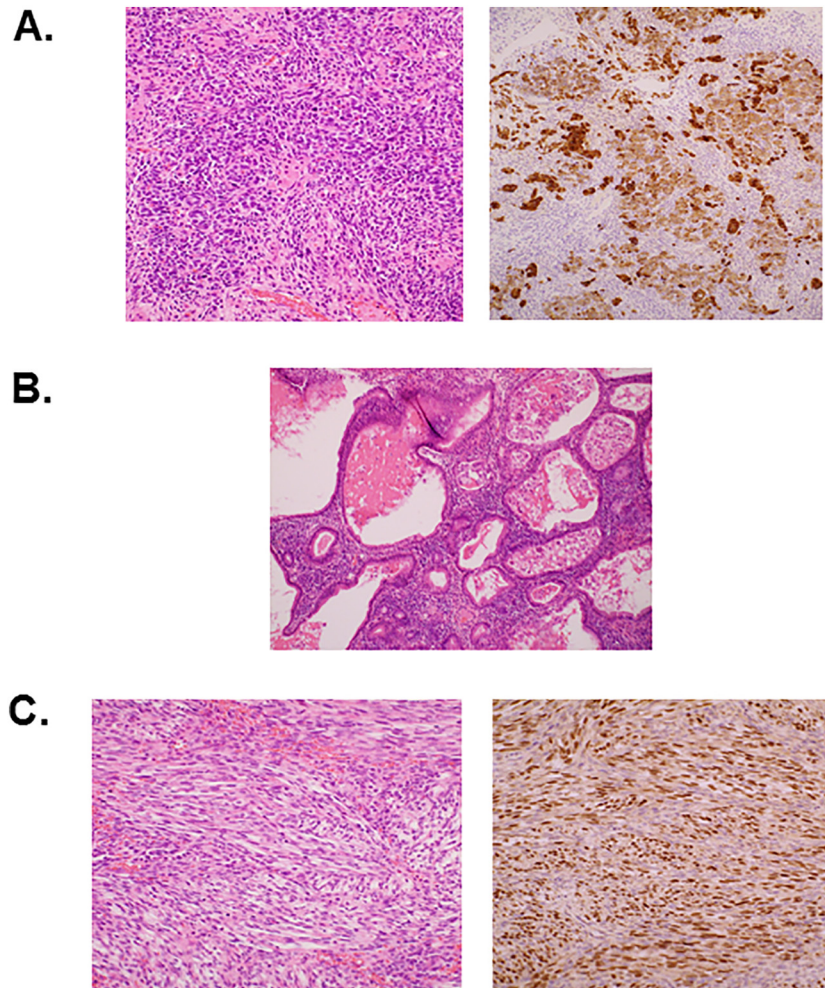


Fig. 2. (A) Tubules of well-differentiated Sertoli cell tumor (weak Inhibin) and single cells of Leydig tumor (dark Inhibin). (B) Spindled areas of poorly differentiated Sertoli cell tumor and heterologous glandular elements. (C) High-grade spindled rhabdomyoblastic cells, positive for nuclear myogenin expression.

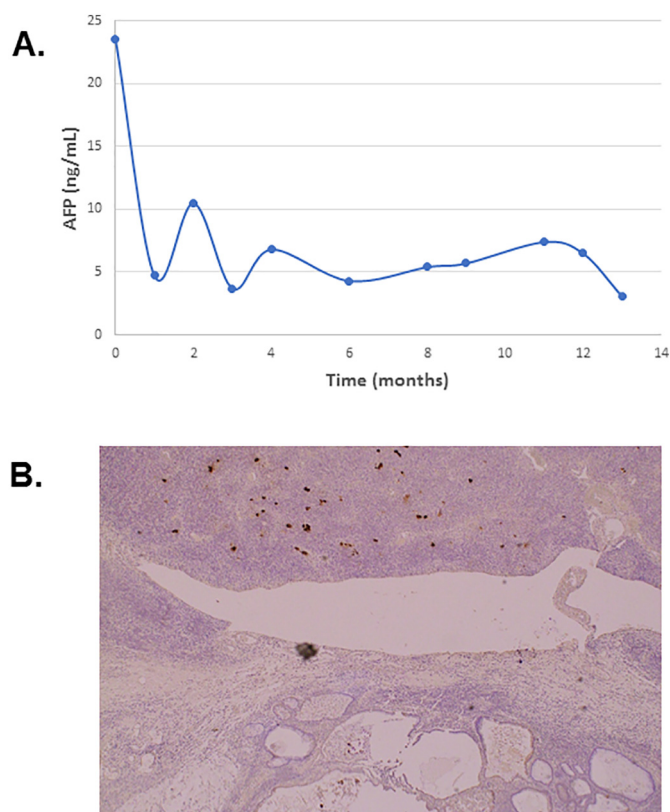


Fig. 3. (A) Follow-up of Alpha-fetoprotein (AFP) levels from day-zero (post-operative) to the most recent serologic follow-up. Not shown is pre-operative (at diagnosis) AFP level of 77.1 ng/ml; (B) AFP is secreted by Leydig cells (brown) in this tumor. (For interpretation of the references to colour in this figure legend, the reader is referred to the web version of this article.)

3. Comments/discussion

Ovarian neoplasms represent 1% of all solid tumors in adolescent females; most of them are benign or physiologic, and 10–20% are malignant. Clinically, they present with menstrual irregularities, pain and/or mass. Majority of malignant ovarian neoplasms in adolescent females are germ cell tumors (two-thirds), which can be evaluated with serologic markers and have a complex (solid and cystic) radiologic appearance (similar to that of case presented). An accurate diagnosis and classification, and exclusion of uncommon non-germ cell neoplasms requires histopathologic evaluation of excised tumor, with intra-operative evaluation of tumor grade to guide additional sampling such as of peritoneum and/or lymph nodes.

Sertoli-Leydig cell stromal tumors represent < 2% of all malignant ovarian tumors, with the poorly differentiated SLCTs containing dedifferentiated elements being exceedingly rare. In the peer-reviewed English language literature, 14 cases of poorly-differentiated SLCTs with heterologous elements have been documented [Table 1]. The majority of the patients were adolescents or young adults with low-stage disease who received adjuvant chemotherapy due to high-grade histology. Six of ten patients with the available follow-up died of disease in 7 to 84 months and were characterized by tumor rupture, adhesions or extra adnexal metastasis [Prat et al., 1982].

We describe the diagnosis and oncologic management of a rare poorly differentiated malignant Sertoli-Leydig cell tumor with dedifferentiated rhabdomyosarcoma. Ancillary immunoperoxidase stains aid in the diagnosis in areas of dedifferentiation. AFP is frequently elevated in these tumors due to Leydig cell component and care must be exercised in order to avoid the misdiagnosis of yolk-sac tumor. To the best of our knowledge, this case represents the youngest reported patient with poorly differentiated SLCT with rhabdomyosarcoma in the peer-reviewed literature.

Conflict of interest statement

The authors declare that there are no conflicts of interest associated with this manuscript.

Table 1

Literature review of previously reported cases of heterologous rhabdomyosarcoma arising in ovarian Sertoli-Leydig cell tumors (SLCT).

Authors	Year of publication	Number of cases	Age at initial diagnosis/surgery (Year)	Location	Tumor FIGO stage	Adjuvant therapy	Reported follow-up
Guerard, et al	1982	1	Not Available	Left Ovary	IC	Chemotherapy (Recurrence after 6 and 10 months)	Alive at 10 months
Prat, et al	1982	8	17–48	Right Ovary (n = 5) Left Ovary (n = 3)	DOD IA = 1, IIA = 1, IIB = 2, IC = 1 ALIVE IA = 1, IC = 1, Not Specified = 1	DOD No Therapy, Radiotherapy, Chemotherapy, No Therapy = 1, Radiotherapy = 1, No Chemo-/Radiotherapy ALIVE Chemotherapy, No Chemo-/Radiotherapy Not Specified	DOD 5–84 months (n = 5); Alive at 24 months (n = 1)
Kostopoulou and Talerman	2003	1	22	Left Ovary	Not Specified	No therapy offered	Alive at 10 months
Grove and Vestergaard	2006	1	29	Right Ovary	IC	Conservative (No therapy was given)	Alive at 48 months
Rekhi, et al	2009	1	17	Peritoneum & Right Ovary	Not Specified	Chemotherapy was planned, but the patient was lost to follow-up	Not Available
Chougule, et al	2016	1	23	Left Ovary	Not Specified	Not Specified	Not Available
Burnik Papler, et al	2016	1	70	Right Ovary	IA	No postoperative chemo- or radiotherapy offered	Died at 7 months
Current Study (Singh, et al)	2018	1	12	Right Ovary	IA	BEP × 4 cycles (with scans after 2 cycles)	Alive at 20 months

Abbreviations: FIGO = International Federation of Gynecology and Obstetrics; DOD = died of disease; chemo = chemotherapy; BEP = Bleomycin, Etoposide, platinum/cisplatin

Patient consent

This study was deemed exempt by our Florida Hospital Institutional Review Board.

Financial disclaimer

None.

References

- Burnik Papler, T., Frković Grazio, S., Kobal, B., 2016. Sertoli-Leydig cell tumor with retiform areas and overgrowth of rhabdomyosarcomatous elements: case report and literature review. *J. Ovarian Res.* 9, 46–52.
- Chougule, A., Singh, P., Saha, P.K., Dey, P., 2016. Ovarian Sertoli-Leydig cell tumor with rhabdomyosarcoma and borderline mucinous neoplasm. *Pathology* 48, 278–281.
- Grove, A., Vestergaard, V., 2006. Ovarian Sertoli-Leydig cell tumor of intermediate grade with heterologous elements of rhabdomyosarcoma: a case report and a review of the literature. *Ann. Diagn. Pathol.* 10, 288–293.
- Guérard, M.J., Ferenczy, A., Arguelles, M.A., 1982. Ovarian Sertoli-Leydig cell tumor with rhabdomyosarcoma: an ultrastructural study. *Ultrastruct. Pathol.* 3, 347–358.
- Kostopoulou, E., Talerman, A., 2003. Ovarian Sertoli-Leydig cell tumor of intermediate differentiation with immature skeletal muscle heterologous elements. *Acta Obstet. Gynecol. Scand.* 82, 197–198.
- Prat, J., Young, R.H., Scully, R.E., 1982. Ovarian Sertoli-Leydig cell tumors with heterologous elements. II. Cartilage and skeletal muscle: a clinicopathologic analysis of twelve cases. *Cancer* 50, 2465–2475.
- Rekhi, B., Karpate, A., Deodhar, K.K., Chinoy, R.F., 2009. Metastatic rhabdomyosarcomatous elements, mimicking a primary sarcoma, in the omentum, from a poorly differentiated ovarian Sertoli-Leydig cell tumor in a young girl: an unusual presentation with a literature review. *Indian J. Pathol. Microbiol.* 52, 554–558.