



Original Article


# Low-memory shape coils for intracranial aneurysm coiling: Initial and single-center experience with the i-ED coil

Maximilian Jeremy Bazil<sup>1</sup>, Johanna T. Fifi<sup>2</sup>, Kurt A. Yaeger<sup>2</sup>, Reade A. De Leacy<sup>2</sup>, Christopher Paul Kellner<sup>2</sup>, Tomoyoshi Shigematsu<sup>2</sup>

<sup>1</sup>Department of Neurological Surgery, Mount Sinai Hospital, <sup>2</sup>Department of Neurological Surgery, Mount Sinai Health System, New York City, United States.

E-mail: Maximilian Jeremy Bazil - maximilian.bazil@icahn.mssm.edu; Johanna T Fifi - johanna.fifi@mountsinai.org; Kurt A Yaeger - kurt.yaeger@mountsinai.org; Reade A De Leacy - reade.deleacy@mountsinai.org; Christopher Paul Kellner - christopher.kellner@mountsinai.org;

\*Tomoyoshi Shigematsu - tomoyoshi.shigematsu@mountsinai.org



**\*Corresponding author:**

Tomoyoshi Shigematsu,  
Department of Neurological  
Surgery, Mount Sinai Health  
System, New York City,  
United States.

tomoyoshi.shigematsu@  
mountsinai.org

Received : 13 December 2022

Accepted : 21 March 2023

Published : 21 April 2023

**DOI**

10.25259/SNI\_1116\_2022

**Quick Response Code:**



## ABSTRACT

**Background:** Endovascular aneurysmal coiling is a preventative alternative to clipping to avoid aneurysmal rupture. In the literature and our own experience, some common coiling challenges which arise include: (1) microcatheter kickback, (2) detachment zone rigidity, (3) intrasaccular compartmentalization of coils on deployment, and (4) attainability of high-density and effective packing with as few coils as possible.

**Methods:** We retrospectively reviewed a consecutive case series of 15 intracranial aneurysm patients who received Kaneka i-ED Coils since their initial use in our practice (December 2020) till May 2022.

**Results:** Of the 14 saccular aneurysm patients treated with i-ED coils, 2/14 (14.3%) achieved a Raymond-Roy (RR) score of 3A (internal remnant), 4/14 (28.6%) achieved RR 2 (slight neck remnant) and 8/14 (57.1%) achieved RR 1. One MoyaMoya patient (5.9%) with a fusiform aneurysm also achieved a complete occlusion by parent artery takedown in this series. Aneurysm volumes ranged from 8.15 mm<sup>3</sup> to 315.5 mm<sup>3</sup> with an average packing density of 36.23% and a standard deviation 8.87%. At 30 days, most of our cohort scored a 0 on the modified Rankin scale (mRS) (11/15), with two patients scoring at an mRS score of 1, one at an mRS score of 4, and one at an mRS score of 6. Low-memory shape, coil cases achieved a significantly higher packing density ( $P < 0.01$ ) and PD/Coils-used ratio ( $P < 0.05$ ) than other cases in our practice.

**Conclusion:** Our initial experience with i-ED coils has shown that they are a feasible strategy in a number of differently sized and shaped aneurysms. While fewer coils overall were not a statistically significant finding in this study, the future studies with larger cohorts are necessary and in progress.

**Keywords:** Aneurysm, Coiling, Low-memory, i-ED

## INTRODUCTION

Endovascular aneurysmal coiling is a preventative alternative to clipping to avoid aneurysmal rupture.<sup>[13]</sup> Technical advancements for coiling of aneurysms with complicated anatomy (such as an unfavorably wide neck or irregular shape) include balloon assistance, stent-assistance, and other neck-bridging devices.<sup>[2,16]</sup> In the literature and our own experience, some common challenges which

arise include: (1) microcatheter kickback, (2) detachment zone rigidity, (3) intrasaccular compartmentalization of coils on deployment, and (4) attainability of high-density, effective packing with as few coils as possible.<sup>[5,14]</sup> Microcatheter kickback may also occur due to push-back from a portion of the coil currently in contact with the wall or coils already deployed within the aneurysm. The stiffness of the detachment zone can also cause kickback at the end of coil deployment which we refer to as “detachment zone rigidity.” While there are numerous technologies available to combat these issues such as the low-profile, Target Nano Coil series (Stryker, Kalamazoo, Michigan) we recently reflected on our practice’s use of the Kaneka i-ED, low-memory shape, coil (LMSC) series (Kaneka; Osaka, Japan) [Supplemental Figure 1: Photos of Soft i-ED Infini Coil Deployment]. We believe we are the first practice to employ these aneurysm coils in the United States and our preliminary experience has shown early success, ease of use, and the freedom to employ fewer coils than usually required for such procedures. This technology was initially incorporated into our practice due to features such as the monopolar electrode detachment system, as well as the soft, flexible, and lengthy specifications of the coil (for minimal microcatheter perturbation).<sup>[8]</sup> While the Kaneka i-ED coils have been demonstrated in individual case reports with promising results, we believed that our series of 15 patients may offer some additional insight for neurointerventionalists considering low-memory shape coils for aneurysm treatment.<sup>[3,4,6,7,14,15]</sup> We outline our experience at a single center with these coils so that other neurointerventionalists might find use for it and incorporate them as an additional tool in their practice.

## MATERIALS AND METHODS

We retrospectively reviewed a consecutive case series of 15 intracranial aneurysm patients who received Kaneka i-ED Coils since their initial use in our practice (December 2020) and May 2022. While some of these cases used LMSCs in conjunction with more traditional coils, others relied entirely on LMSCs. We discuss the nature of the aneurysms treated, radiographic outcomes (packing density and Raymond-Roy, RR class), overall procedural outcomes at the end of treatment (complications and number of coils), and technical notes. Packing density was calculated by inputting the aneurysm dimensions, coil type, and coil length into the Angiosuite Calculator© application. Angiosuite Calculator© was selected due to its consideration of aneurysm size distribution/shape as well as differences in pitch across a variety of coils. RR class was assessed by the neurointerventionalist (TS). Complications and other demographic features were pulled from the hospital’s EPIC system. This study was approved by the appropriate institutional review board (IRB) under IRB study-21-00749.

## RESULTS

A specific selection criteria for use of Kaneka LMSCs were not employed during the study period; rather, if the coils were available and (at the interventionalist’s discretion) soft, LMSCs would be an effective choice for the aneurysm, they were used. Kaneka LMSCs were used in conjunction with other, more rigid, coils for framing, and/or finishing purposes at the interventionalist’s discretion. Five cases were performed in conjunction with other coils in the initial deployment (HydroFrame 10 and HydroSoft 3D; Microvention; Aliso Viejo, California) (Target 360 Standard; Stryker; Kalamazoo, Michigan) (Galaxy G3; Cerenovus; Irvine, California), while the remaining ten used only Kaneka i-ED coils. The aneurysms in this series were distributed among the middle cerebral artery (MCA) ( $n = 4$ , 2 along the vessel, 1 off a large moyo-moya collateral and another at the bifurcation), the posterior communicating artery (PComm) ( $n = 4$ ), the anterior communicating artery (AComm) ( $n = 4$ ), the anterior cerebral artery ( $n = 1$  between A2 and A3 segments), and the basilar artery ( $n = 2$ , one along the side-wall and another at the tip). Most aneurysms were saccular (14/15) with a single fusiform case. Nine cases (60%) involved stent-assistance. Overall, 5/15 cases were performed immediately post-rupture, 1/15 was previously ruptured, and 9/15 were unruptured. Of the five ruptured cases, 4 (80%) were performed within 24 h of symptom onset. The exception to this was a 48-h delay in the patient’s appearance in the emergency room post symptom onset. The majority of the saccular aneurysms took on a traditional and oblate-spheroid shape (10/14) with three additional bilobed cases and a single side-wall aneurysm. Of the 14 saccular aneurysm patients treated with i-ED coils, 2/14 (14.3%) achieved a RR score of 3A (internal remnant), 4/14 (28.6%) achieved RR 2 (slight neck remnant) and 8/14 (57.1%) achieved RR 1 [Table 1].<sup>[10]</sup> One Moya-Moya patient (5.9%) with a fusiform aneurysm also achieved a complete occlusion by parent artery takedown in this series. Aneurysm volumes ranged from 8.15 mm<sup>3</sup> to 315.5 mm<sup>3</sup> with an average packing density of 36.23% and a standard deviation 8.87%. At 30 days, most of our cohort scored a 0 on the modified Rankin scale (mRS) (11/15), with two patients scoring at an mRS score of 1, one at an mRS score of 4, and one at an mRS score of 6. Out of 15 cases, we report thirteen favorable outcomes overall with neurologically intact clinical outcomes. Case 4 had reduced visual acuity at baseline unrelated to the aneurysm, which led to a 30-day mRS score of 1. Case 6 had a high-grade subarachnoid hemorrhage complicated by hydrocephalus and symptomatic vasospasm which led to a 30-day mRS score of 4. By the time of the 6-month follow-up, Case 6 unfortunately succumbed to a high-grade subarachnoid hemorrhage. Case 12, which achieved effective coiling of the aneurysm, also unfortunately resulted in the same outcome

**Table 1:** Characteristics of coiling procedures for patients treated with Kaneka i-ED Coils: Patient demographics, aneurysm treatment course, and efficacy of treatment are shown.

Case #	Age	Sex	Aneurysm type	Parent Vessel	Rupture Status	Maximum Diameter (mm)	RR	Packing Density	Framing	Filling	Finishing	Total Length (cm)	30-Day mRS	6-Month Radiographic Outcome
1	12	Male	Fusiform	MCA	Ruptured	7.5	N/A	40.35%	C 7 mm × 30 cm	I 4-8 mm × 15 cm	CS 1 mm × 2 cm CS 1 mm × 2 cm	49	0	Occluded
2	71	Female	Saccular	PComm	Unruptured	6.15	1	27.19%	HS 3D 2.5 mm × 4 cm	CS 1.5 mm × 2 cm	CS 1.5 mm × 2 cm	6	0	RR1
3	65	Female	Saccular	PComm	Previously ruptured	5.58	2	31.02%		I 4-8 mm × 30 cm I 4-8 mm × 15 cm I 2-3 mm × 10 cm		90	0	RR2
4	28	Female	Saccular - Bilobed	AComm	Unruptured	7.4	2	39.53%	I 4-8 mm × 15 cm	I 2-3 mm × 6 cm I 2-3 mm × 6 cm	CS 1 mm × 2 cm	29	1	RR1
5	32	Female	Saccular	AComm	Ruptured	7.88	1	40.78%	HF 10 6 mm × 19 cm	I 3-5 mm × 15 cm	CS 1 mm × 2 cm	36	0	RR1
6	50	Male	Saccular	MCA	Ruptured	3.2	1	48.10%	C 5 mm × 10 cm	I 2-3 mm × 10 cm	CS 1.5 mm × 2 cm	22	4	×
7	54	Male	Saccular	AComm	Unruptured	5.9	1	31.50%	C 6 mm × 20 cm	I 3-5 mm × 15 cm	CS 1 mm × 3 cm	38	0	RR1
8	55	Female	Saccular	PComm	Ruptured	8.5	3A	26.00%	TS 7 mm × 15 cm	I 3-5 mm × 15 cm I 3-5 mm × 15 cm	TN 1.5 mm × 3 cm	48	0	RR1
9	72	Female	Saccular	PComm	Unruptured	5.3	1	36.00%	G 5 mm × 10 cm	I 3-5 mm × 15 cm	CS 1 mm × 2 cm	27	0	RR1
10	51	Female	Saccular	Basilar	Unruptured	9.1	1	54.00%	HF 10 mm × 36 cm	I 4-8 mm × 30 cm I 4-8 mm × 30 cm I 4-8 mm × 10 cm I 3-5 mm × 15 cm	I 2-3 mm × 10 cm I 2-3 mm × 10 cm	141	0	×

(Contd...)

**Table 1: (Continued).**

Case #	Age	Sex	Aneurysm type	Parent Vessel	Rupture Status	Maximum Diameter (mm)	RR	Packing Density	Framing	Filling	Finishing	Total Length (cm)	30-Day mRS	6-Month Radiographic Outcome
11	62	Female	Saccular - Bilobed	MCA	Unruptured	5	1	43.00%		I 3-5 mm × 15 cm	CS 2 mm × 3 cm CS 1.5 mm × 2 cm	22	0	RR1
12	84	Female	Saccular	AComm	Ruptured	6.1	1	26.00%	C 6 mm × 20 cm	I 3-5 mm × 15 cm	CS 2 mm × 2 cm CS 1 mm × 2 cm	43	6	×
13	62	Female	Saccular	ACA	Unruptured	7.5	2	23.00%	I 5 mm × 10 cm	I 2-3 mm × 6 cm I 2-3 mm × 6 cm	CS 2 mm × 3 cm CS 1.5 mm × 3 cm	31	0	×
14	68	Male	Saccular - Sidewall	Basilar	Unruptured	6.9	2	55.00%	I 4-8 mm × 30 cm	I 3-5 mm × 15 cm	CS 1.5 mm × 3 cm	45	0	×
15	65	Female	Saccular - Bilobed	MCA	Unruptured	5.75	3A	42.00%	I 3 mm × 6 cm	I 2-3 mm × 6 cm	CS 2 mm × 3 cm CS 1 mm × 2 cm	20	1	×

I: Infimi, C: Complex, CI: Complex infimi, CS: Complex silky soft, HS: Hydro soft, HF: Hydro frame, TS: Target 360 standard, TN: Target 360 nano, G: Galaxy G3, mRS: Modified Rankin scale, RR: Raymond Roy, AComm: Anterior communicating artery, ACA: Anterior cerebral artery, MCA: Middle cerebral artery

by the 6-month follow-up. At this time, we report no cases of recurrence and continued stability of the coil mass in all cases with post 6-month radiographic follow-up.

We compared the number of coils required for treatments using i-ED coils to total coils for treatment of the 50 most recent, non-i-ED coiling patients at our practice [Supplemental Figure 2: List of Non-i-ED Coils]. Cases were selected if they had not been previously embolized or clipped and only the first coiling treatment (if multiple) was assessed. Of the 50 cases reviewed, 92% (46/50) were saccular and 8% (4/50) were fusiform with volumes ranging between 14.1 mm<sup>3</sup> and 1334.12 mm<sup>3</sup>. In this cohort, 11 patients scored a RR of 1, 19 scored a RR of 2, and 16 scored a RR of 3. A student's one-tailed *t*-test did not achieve significance ( $P = 0.109$ ) for the result of fewer coils used in i-ED cases (median: 4 coils, average: 3.87 coils SD: 1.41 coils) than others in our practice (median 4 coils, average 4.5 coils SD: 2.49 coils), but this finding should be re-investigated with a larger cohort of i-ED cases. We also compared the packing density at the end of each initial treatment for this cohort to the i-ED cohort. We found that cases which used i-ED coils (average: 36.23% packing density SD: 8.87%) achieved a significantly higher packing density ( $P < 0.01$ ) than other cases in our practice (average: 24.8% packing density SD: 12.09%). The ratio of percent packing density achieved to coils used was significantly higher ( $P < 0.05$ ) in the i-ED coil cases (average PD%/Coils: 10.9 SD: 5.91) than in the non-i-ED cohort (average PD/Coils: 7.35 SD: 5.62).

### Illustrative cases

We identified seven cases in our series with representative imaging of microcatheter kickback control and use for anatomically complex aneurysms which we describe below.

#### Kickback control

Two members of our series (Cases 1 and 2) demonstrated the LMSCs' usefulness in controlling kickback when placing finishing coils into a densely packed environment [Figure 1]. In both cases shown, a well-packed filling/framing coil combination was successfully supplemented with finishing coils without microcatheter kickback. Kickback may occur as a result of resistance from extant coils within the sac of the aneurysm, but due to the softness of the finishing coils (and that of the detachment zone), this was avoided. One case presented as a ruptured, fusiform aneurysm of a collateralized vessel off the M1 branch of the MCA [Figure 1a-c]. This case presented with a largest visible diameter of 7.5 mm (Volume: 93.9 mm<sup>3</sup> Neck: 2 mm, W: 7.5 mm, H: 4.9 mm, D: 5 mm) and was coiled with four coils in a combination of complex (framing ×1), Infini (filling ×1),

and complex Infini (finishing ×2) for a total length of 49 cm and a packing density of 39%. Another patient with a small, left PComm aneurysm tolerated an additional i-ED SilkySoft coil very well [Figure 1d-f]. This case presented with a largest diameter of 3.2 mm (Volume: 8.5 mm<sup>3</sup> Neck: 2.6 mm, W: 3.2 mm, H: 2.9 mm, D: 1.9 mm) and was coiled with two coils in a combination of Hydrosoft 3D (framing) and Complex SilkySoft (finishing) for a total length of 6 cm and a packing density of 41.0%.

#### Irregular aneurysms

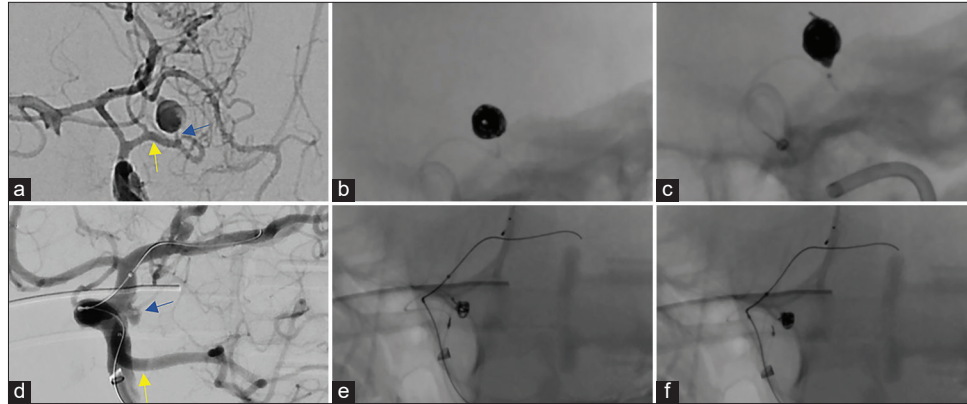
Two irregular aneurysm cases (Cases 3, 4) were selected, based on the experience of the attending physician, to outline in greater detail [Figure 2]. One patient with a saccular PComm aneurysm was a particularly challenging case, as multiple imaging attempts revealed very little about the structure of the residual aneurysm which had a maximum diameter of approximately 8.3 mm (Volume: 184.2 mm<sup>3</sup>, Neck: 7.8 mm, W: 6.8 mm, H: 6.8 mm, D: 8.3 mm) [Figures 2a-c]. This structure was difficult to ascertain due to compaction of previously placed coils which hid much of the neck and body of the aneurysm. With stent-assistance, the aneurysm was coiled with three Infini coils (rather than the traditional nesting-doll technique) for a total length of 55 cm and an approximate additional packing density of 26.0%. We elected to perform stent-assisted coiling rather than use flow diverter since the fetal type PCA originated from the neck of the aneurysm. The low-memory shaped i-ED Infini coils were observed to expand well within the fusiform aneurysm. The other patient presented with a bi-lobular aneurysm of the AComm [Figures 2d-f]. This case presented with a maximum diameter of 8.36 mm (Volume: 60.6 mm<sup>3</sup>, Neck: 3.42 mm, W: 8.36 mm, H: 3.68 mm, D: 3.68 mm) and was coiled with four coils in a combination of Infini (framing ×1), complex Infini (filling ×2), and complex SilkySoft (finishing ×1) for a total length of 29 cm and a packing density of 41%. Importantly, a single Infini coil was able to expand to both lobes of the aneurysm without difficulty.

#### Minimal coil usage

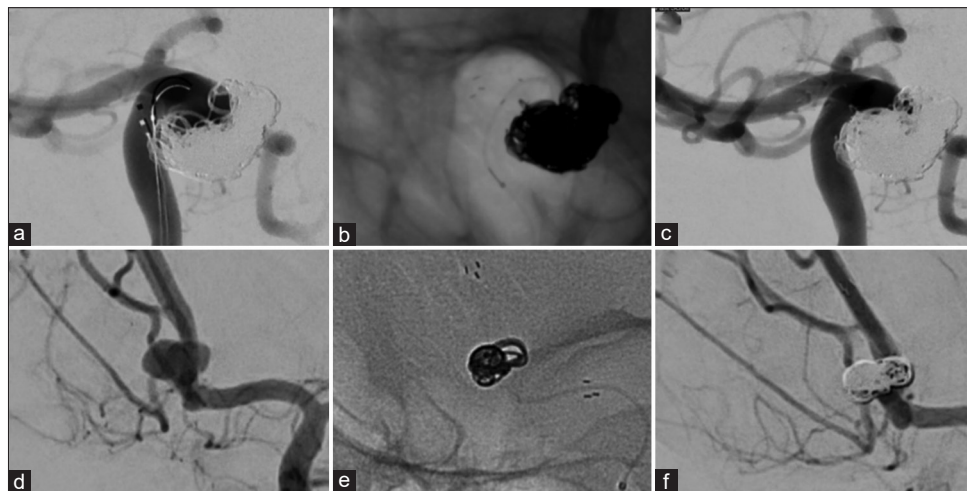
Finally, we present Case 5, Case 6 and Case 7 which received just one low-memory shaped Complex Infini coil as a filling coil, one as a finishing coil, with a single coil from either i-ED or the Hydroframe 10 as a framing coil. These cases achieved a high packing density in each case (31.0%, 33.0% and 31.5%, respectively; Figure 3).

## DISCUSSION

Our practice examined the initial experience of Kaneka i-ED coils in the United States in a series of 15 patients treated



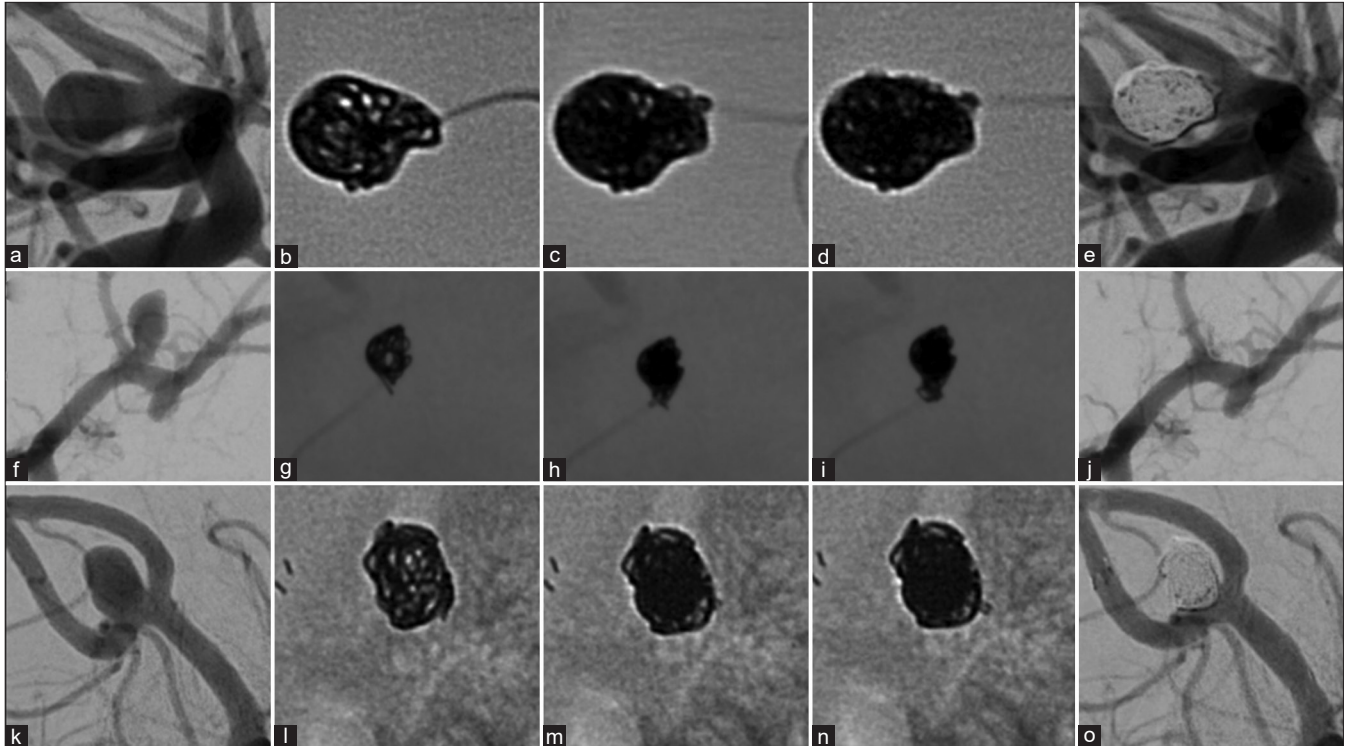
**Figure 1:** Kickback control with i-ED coils. A ruptured fusiform aneurysm on a collateralizing vessel (blue arrow) took a sharp turn from left M1 (yellow arrow) (a). The aneurysm was catheterized with a microcatheter and coiled densely with two i-ED coils (b). To achieve tighter packing at the orifice of the aneurysm where the microcatheter was likely to be kicked out, two small i-ED SilkySoft coils were added without microcatheter kickback (c). During the balloon-assisted coiling of a small, left PComm (yellow) aneurysm (blue) (d), after placing one HydroSoft coil (e), another i-ED SilkySoft coil was added to achieve tighter packing of the aneurysm without interventionalist-noted kickback of the microcatheter (f).



**Figure 2:** Anatomically complex aneurysm coiling with i-ED Coils: A previously coiled right posterior communicating artery aneurysm with an uncertain neck diameter (a) experienced coil compaction and required stent-assisted coiling. Coiling was performed with low-memory shaped i-ED Infini coils which filled the unclear residual space (b). The patient achieved a RR2 obliteration of the residual aneurysm (c). In the irregularly shaped, bi-lobulated, anterior communicating artery aneurysm (d), the low-memory shaped i-ED Infini coil expanded into both lobes quite well to create a durable frame in a stent-assisted coiling procedure (e). With two filling coils and a finishing coil, the aneurysm was completely obliterated (f).

either entirely with Kaneka coils or in combination with other coiling products. The i-ED coil series is distinct from Kaneka “ED” coils which also demonstrated highly effective coiling in a 92-member cohort and a 345-member cohort in Japan.<sup>[1,11]</sup> Compared to the last 50 aneurysm patients treated with coils at our practice, the i-ED cohort used fewer coils on average, but this did not achieve significance; however, there was a significantly greater packing density achieved in the i-ED cohort as well as a higher ratio of percent packing density achieved to coils used compared to other cases from

our practice for a given procedure. While i-ED coil use has not yet shown significance as a method to limit the number of coils used in a given procedure, preliminary results suggest i-ED coils were more efficient compared to other coils used in our case series. While coil detachment and microcatheter kickback are relatively minor factors that affect usability of coiling technology for neurointerventionalists, a higher coil packing density has been associated with successful angiographic outcome. Kaneka i-ED coils are compartmentalized into traditional complex structure and



**Figure 3:** Efficient packing with Kaneka i-ED coils. Three aneurysms (an anterior communicating artery [AComm] aneurysm [a], a left MCA bifurcation aneurysm [f], and another AComm aneurysm [k]) were each coiled using one framing coil (b, g, l), one filling i-ED low memory shaped Infini coil (c, h, m) and one small finishing i-ED SilkySoft coil (d, i, n). Favorable angiographic results were achieved (RR = 1 [e], RR = 2 [j], and RR = 1 [o]).

the novel Infini. Moreover, each of these subtypes can be further categorized by softness, ranging from standard to SilkySoft. We examined the use of the Infini coil and its SilkySoft subtype.

The i-ED Infini and Complex Infini coils are low-memory shape coils with a relatively long length (between 6 cm and 50 cm). Traditional coils have a pre-shaped structure which may create loops within the aneurysm rather than along the edges or on the wall. This may further cause microcatheter kickback when attempting to deploy additional coils or may create strain on the overall aneurysm structure. We have found that in certain aneurysms, dense packing is achievable with as little as two or even one coil. The impact of this technology is especially visible in cases of irregular anatomy, as we have observed the Infini coils to fill up any space they occupy regardless of the shape. We believe that this feature makes the coils far less likely to compartmentalize. Regarding compartmentalization, LMSCs extrude to occupy (“find”) whatever space is available, laying flush against wall of the aneurysm and avoiding formation of internal loops/shapes. Thus, we expected i-ED Infini coils to be relatively versatile as the main consideration is length rather than coil diameter, especially for the filling coils. This helps to simplify coil selection intraprocedurally.

We find that the coils packed and detached as expected without issue. The detachment system of the Kaneka i-ED coils is a monopolar system, based on placement of a hypodermic needle as the ground for an “electro-detach generator” which sends current through the main deployment wire to melt the PVC that attaches the coils to the catheter. While this system is rather outdated, we believe that the softness of the detachable component makes up for this. The softness of both the detachment and the coils themselves allow for excellent microcatheter kickback control. In this way, the SilkySoft technology introduced in the i-ED coil series has shown promise to become a highly effective treatment. In our initial experience, there was no issue in i-ED Infini coils’ compatibility with any framing coil on the market. A notable issue we have yet to experience with the i-ED coils, but believe should be examined more closely, is the risk for coil compaction. The softness of the coil may pose an increased risk of turbulent blood flow, undoing the structure of the coils which may lead to rupture and/or the necessity for retreatment. The softness of the coils may be made up for by achieving a high packing density; the literature has shown that achieving higher packing density is the key to fewer instances of recanalization,<sup>[9]</sup> even when using hydrogel coils.<sup>[12]</sup> In addition to this, another important future direction may be to examine the Infini coils as effective

framing coils; however, at present, it is crucial for the neck to be sealed by a complex coil or other framing technology (such as balloon or stent intra-procedurally) to avoid coil protrusion into the parent vessel. Most of the cases in this series were stent-assisted, though the difference between stent-assisted and non-stented cases was not assessed, but in our experience, coiling works effectively in both cases. With simple coiling, the catheter position can be adjusted freely to guide the LMSCs in a way that best fills the aneurysm. On the other hand, stent-assisted coiling with the jailing/semi-jailing technique is fixed, but the neck will be well-covered allowing for minimal catheter control. As long as the neck is sealed well, we believe that the low-memory shape of the Infini coils makes it a good choice to achieve high packing density after securing the neck (especially in an irregularly shaped or large aneurysm). Further analysis is warranted to determine whether Kaneka i-ED coils may effectively reduce the number of coils a patient receives for a given aneurysm in the form of a randomized and clinical trial.

## CONCLUSION

Our initial experience with i-ED coils has demonstrated their feasibility in aneurysm treatment and a trend, though not significant, of using fewer coils to achieve a higher packing density. Moreover, the i-ED coils seem to simplify the coiling procedure by allowing for selection of filling coils based only on the length of the low-memory shaped Infini coils and by preventing microcatheter kickback on deployment due to the softness of the coils. We are not able to effectively assess safety differences between LMSCs and traditional coils at this time. The i-ED coils have shown preliminary success in our cohort. We are currently performing a larger case series to investigate these findings more rigorously.

## Declaration of patient consent

Institutional review board (IRB) permission obtained for the study.

## Financial support and sponsorship

Nil.

## Conflicts of interest

There are no conflicts of interest.

## REFERENCES

- Bendok BR, Abi-Aad KR, Ward JD, Kniss JF, Kwasny MJ, Rahme RJ, *et al.* The hydrogel endovascular aneurysm treatment trial (HEAT): A randomized controlled trial of the second-generation hydrogel coil. *Neurosurgery* 2020;86:615-24.
- Cottier JP, Pasco A, Gallas S, Gabrillargues J, Cognard C, Drouineau J, *et al.* Utility of balloon-assisted Guglielmi detachable coiling in the treatment of 49 cerebral aneurysms: A retrospective, multicenter study. *AJNR Am J Neuroradiol* 2001;22:345-51.
- Currie S, Mankad K, Goddard A. Endovascular treatment of intracranial aneurysms: Review of current practice. *Postgrad Med J* 2011;87:41-50.
- Fukutome K, Aketa S, Fukumori J, Mitsui T, Nakajima T, Hayami H, *et al.* Cerebral vasospasm after coil embolization for unruptured anterior communicating artery aneurysm: Illustrative case. *J Neurosurg Case Lessons* 2022;3:CASE2288.
- Gross BA, Smith ER, Scott RM, Orbach DB. Intracranial aneurysms in the youngest patients: Characteristics and treatment challenges. *Pediatr Neurosurg* 2015;50:18-25.
- Harada K, Morioka J. Initial experience with an extremely soft bare platinum coil, ED coil-10 Extra Soft, for endovascular treatment of cerebral aneurysms. *J Neurointerv Surg* 2013;5:577-81.
- Imahori T, Mizobe T, Fujinaka T, Miura S, Sugihara M, Aihara H, *et al.* An aneurysm at the origin of a duplicated middle cerebral artery treated by stent-assisted coiling using the "Wrapped-Candy" Low-Profile Visualized Intraluminal Support (LVIS) technique: A technical case report and review of the literature. *World Neurosurg* 2020;143:353-9.
- Ishibashi T, Maruyama F, Kan I. Four-dimensional digital subtraction angiography for exploration of intraosseous arteriovenous fistula in the sphenoid bone. *Surg Neurol Int* 2021;12:85.
- Kimura S, Yagi R, Kishi F, Ogawa D, Yamada K, Taniguchi H, *et al.* Subarachnoid hemorrhage due to ruptured cerebral aneurysm at the distal part of anterior inferior cerebellar artery-posterior inferior cerebellar artery variant after  $\gamma$ -knife irradiation. *Interdiscipl Neurosurg* 2022;29:101533.
- Mascitelli JR, Oermann EK, De Leacy RA, Moyle H, Mocco J, Patel AB. Predictors of treatment failure following coil embolization of intracranial aneurysms. *J Clin Neurosci* 2015;22:1275-81.
- Mascitelli JR, Moyle H, Oermann EK, Polykarpou MF, Patel AA, Doshi AH, *et al.* An update to the Raymond-Roy occlusion classification of intracranial aneurysms treated with coil embolization. *J Neurointerv Surg* 2015;7:496-502.
- Mizutani K, Akiyama T, Tomita H, Toda M. Role of endovascular treatment for ruptured aneurysms involving the anterior spinal artery at the craniocervical junction. *J Neuroradiol* 2022;50:44-9.
- Molyneux A, Kerr R, International Subarachnoid Aneurysm Trial (ISAT) Collaborative Group. International Subarachnoid Aneurysm Trial (ISAT) of neurosurgical clipping versus endovascular coiling in 2143 patients with ruptured intracranial aneurysms: A randomized trial. *J Stroke Cerebrovasc Dis* 2002;11:304-14.
- Parkinson RJ, Eddleman CS, Batjer HH, Bendok BR. Giant intracranial aneurysms: Endovascular challenges. *Neurosurgery* 2006;59 Suppl 5:S3-103.
- Sadato A, Hayakawa M, Adachi K, Hirose Y. Relationship between the volume rate of Ed coil (Ed Ratio) and packing density in endosaccular embolization of cerebral aneurysms. *Asian J Neurosurg* 2018;13:619-25.



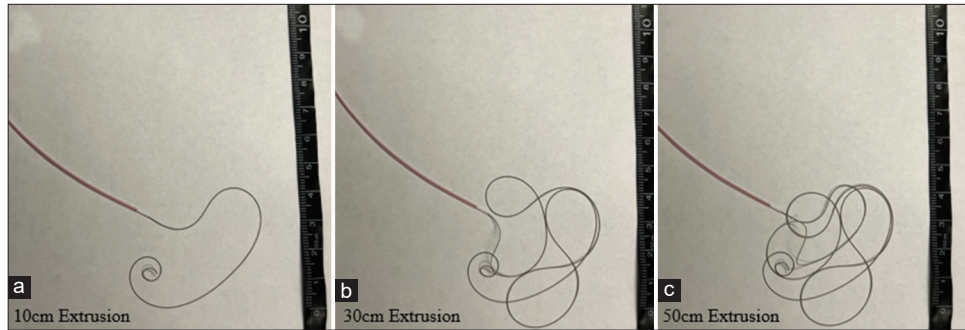
16. Wang F, Chen X, Wang Y, Bai P, Wang HZ, Sun T, *et al.* Stent-assisted coiling and balloon-assisted coiling in the management of intracranial aneurysms: A systematic review and meta-analysis. *J Neurol Sci* 2016;364:160-6.

**How to cite this article:** Bazil MJ, Fifi JT, Yaeger KA, De Leacy RA, Kellner CP, Shigematsu T. Low-memory shape coils for intracranial aneurysm coiling: Initial and single-center experience with the i-ED coil. *Surg Neurol Int* 2023;14:142.

### **Disclaimer**

The views and opinions expressed in this article are those of the authors and do not necessarily reflect the official policy or position of the Journal or its management. The information contained in this article should not be considered to be medical advice; patients should consult their own physicians for advice as to their specific medical needs.

SUPPLEMENTAL FIGURES



**Supplemental Figure 1:** Kaneka i-ED infini soft coil deployment for reference: To assist in reader visualization of the “shapeless” i-ED Infini coil extrusion, varying degrees of extrusion are pictured at 10 cm (a), 30 cm (b), and 50 cm (c) for a 5–12 mm × 50 cm coil are shown.

Coils	Manufacturer
Hydroframe 10/18, HydroSoft, Hypersoft	Microvention
Target XL, Target 3D, Target 360, Target Nano	Stryker
Micrusframe S10/S18, Galaxy G3/G3 XSFT/G3 Mini	Cerenovus
Smart Coil WAVE Extra Soft /Extra Soft/Soft	Penumbra

**Supplemental Figure 2:** List of coils utilized in the non-i-ED-treated cohort: A list of all manufacturers and models (with diameters and lengths omitted) for coils used to treat patients assessed in the non-i-ED cohort is shown.