



ELSEVIER

Contents lists available at ScienceDirect

## Journal of Cardiology Cases

journal homepage: [www.elsevier.com/locate/jccase](http://www.elsevier.com/locate/jccase)

## Case Report

## Intentional switch between 1.5-mm and 1.25-mm burrs along with switch between rotawire floppy and extra-support for an uncrossable calcified coronary lesion



Yousuke Taniguchi (MD), Kenichi Sakakura (MD)\*, Yasuhiro Mukai (MD), Kei Yamamoto (MD), Shin-ichi Momomura (MD, FJCC), Hideo Fujita (MD, FJCC)

Division of Cardiovascular Medicine, Saitama Medical Center, Jichi Medical University, Saitama, Japan

## ARTICLE INFO

## Article history:

Received 9 January 2019

Received in revised form 31 January 2019

Accepted 10 February 2019

## Keywords:

Rotational atherectomy

Rotablator

Percutaneous coronary intervention

Burr entrapment

Perforation

## ABSTRACT

Rotational atherectomy (RA) is considered to be the last resort for a severely calcified coronary artery lesion. Severe complications such as vessel perforation or burr entrapment is closely associated with forceful burr manipulation during RA. The instructions for use of Rotablator (Boston Scientific, Marlborough, MA, USA) prohibit forceful burr manipulation when rotational resistance occurs. Nevertheless, RA operators tend to forcefully manipulate the burr if it cannot cross the lesion, because there has been no established strategy for an uncrossable lesion. We present a case with a severely calcified coronary lesion, which was uncrossable by a burr 1.5 mm with RotaWire Floppy (Boston Scientific). We intentionally switched 2 burrs (1.5-mm and 1.25-mm) and 2 RotaWires (Floppy and Extra-support) to cross the lesion. Uniquely, we downsized the burr (from 1.5-mm to 1.25-mm) initially for better penetration force, and upsized the burr (from 1.25-mm to 1.5-mm) finally for better contact to the calcification within the lesion. Our case suggests that 4 different types of combinations might work in a mutually complementary manner for an uncrossable calcified lesion.

**<Learning Objective:** In rotational atherectomy, severe complications such as vessel perforation or burr entrapment are closely associated with forceful burr manipulation. We present a case with a severely calcified coronary lesion, which was uncrossable by a burr 1.5 mm with RotaWire Floppy. We intentionally switched 2 burrs and 2 RotaWires to cross the lesion. Our case suggests that 4 different types of combinations might work in a mutually complementary manner for an uncrossable calcified lesion.>

© 2019 Japanese College of Cardiology. Published by Elsevier Ltd. This is an open access article under the CC BY-NC-ND license (<http://creativecommons.org/licenses/by-nc-nd/4.0/>).

## Introduction

Rotational atherectomy (RA) is generally considered to be the last resort for a severely calcified coronary artery lesion. However, the incidence of complications such as cardiac tamponade is greater in RA than in conventional percutaneous coronary interventions (PCI) [1]. Moreover, unique complications such as burr entrapment have been observed in RA [2–4]. Of those complications, severe complications such as vessel perforation or burr entrapment are closely associated with forceful burr manipulation during RA. The instructions for use of Rotablator

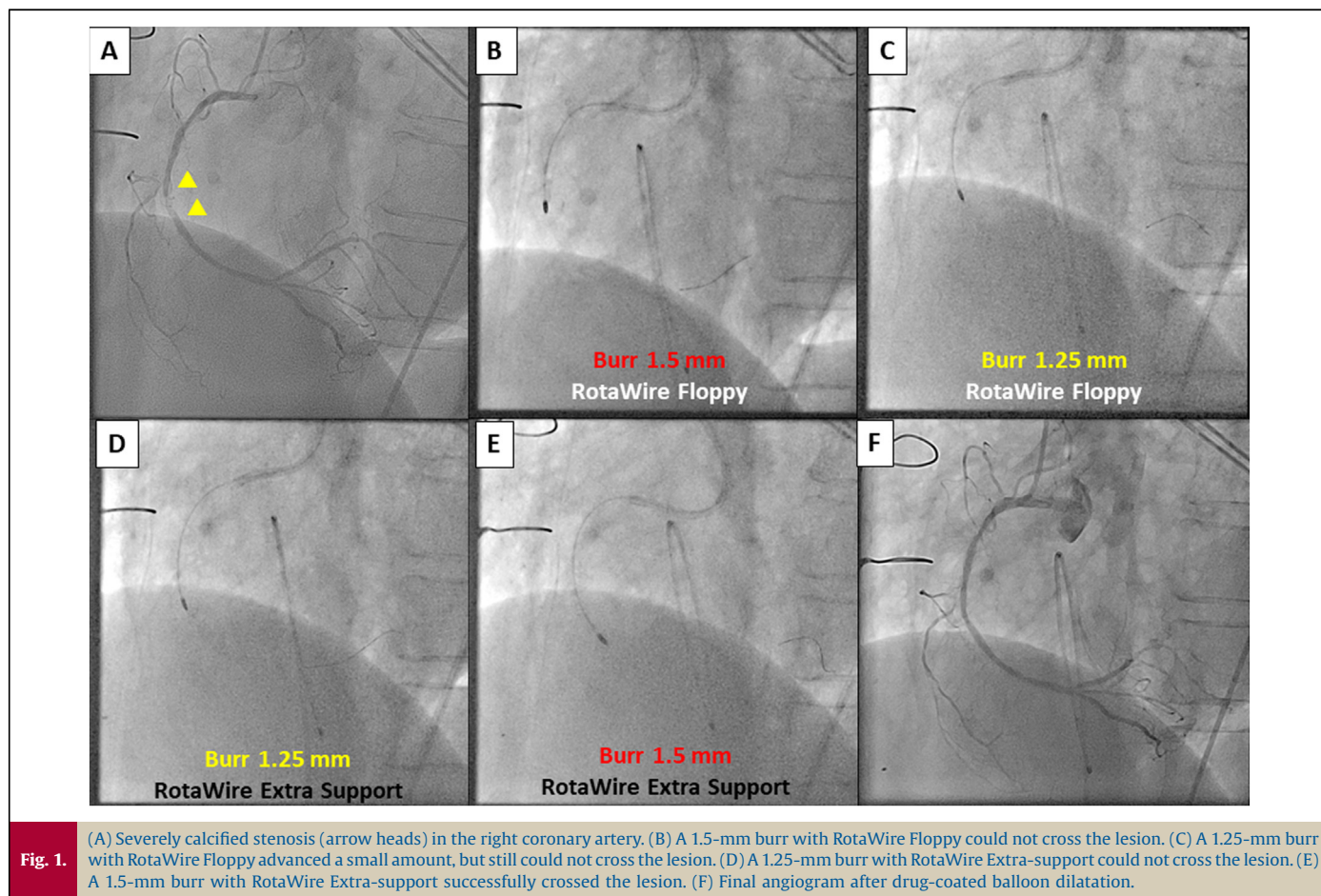
(Boston Scientific, Marlborough, MA, USA) prohibit forceful burr manipulation when rotational resistance occurs [5]. Nevertheless, RA operators tend to forcefully manipulate the burr if it cannot cross the lesion, because there has been no established strategy for an uncrossable lesion. We present a case with a severely calcified coronary lesion, which was uncrossable by a burr 1.5-mm with RotaWire Floppy (Boston Scientific, Marlborough, MA, USA). We intentionally switched 2 burrs (1.5-mm and 1.25-mm) and 2 RotaWires (RotaWire Floppy and RotaWire Extra-support) for an uncrossable coronary lesion.

## Case report

A 69-year-old woman underwent RA of a severely calcified stenosis in the right coronary artery (Fig. 1A). A 7 Fr AL1SH guide catheter was inserted via her right femoral artery. An intravascular

\* Corresponding author at: Division of Cardiovascular Medicine, Saitama Medical Center, Jichi Medical University, 1-847 Amanuma-cho, Omiya-ku, Saitama-city, Saitama, 330-8503, Japan.

E-mail address: [ksakakura@jichi.ac.jp](mailto:ksakakura@jichi.ac.jp) (K. Sakakura).



ultrasound catheter could not cross the lesion due to severe calcification. We started RA with a 1.5-mm burr and a RotaWire Floppy. Although we performed 5 RA sessions (rotational speed,  $180,400 \pm 6151$  rpm; total duration, 69 s), the 1.5-mm burr did not cross the lesion (Fig. 1B). We switched from a 1.5-mm to a 1.25-mm burr for better penetration force. The 1.25-mm burr advanced a small amount after 4 RA sessions (rotational speed,  $190,750 \pm 1479$  rpm; total duration, 64 s), but still could not cross the lesion (Fig. 1C). We switched from the RotaWire Floppy to the RotaWire Extra-support to obtain a different guidewire bias. Although we performed 4 RA sessions (rotational speed  $186,250 \pm 5166$  rpm, total duration, 76 s), the 1.25-mm burr could not cross the lesion (Fig. 1D). Because the diamond coating of the 1.25-mm burr might not contact the area of calcification, we switched from the 1.25-mm to a 1.5-mm burr to increase the diamond coating area. The 1.5-mm burr along with RotaWire Extra-support successfully crossed the lesion (rotational speed  $190,750 \pm 1785$  rpm; total duration, 51 s) (Fig. 1E). After RA, we used a  $2.0 \times 20$  mm drug-coated balloon and obtained an optimal result (Fig. 1F). The summary of procedures is shown in online Video 1.

## Discussion

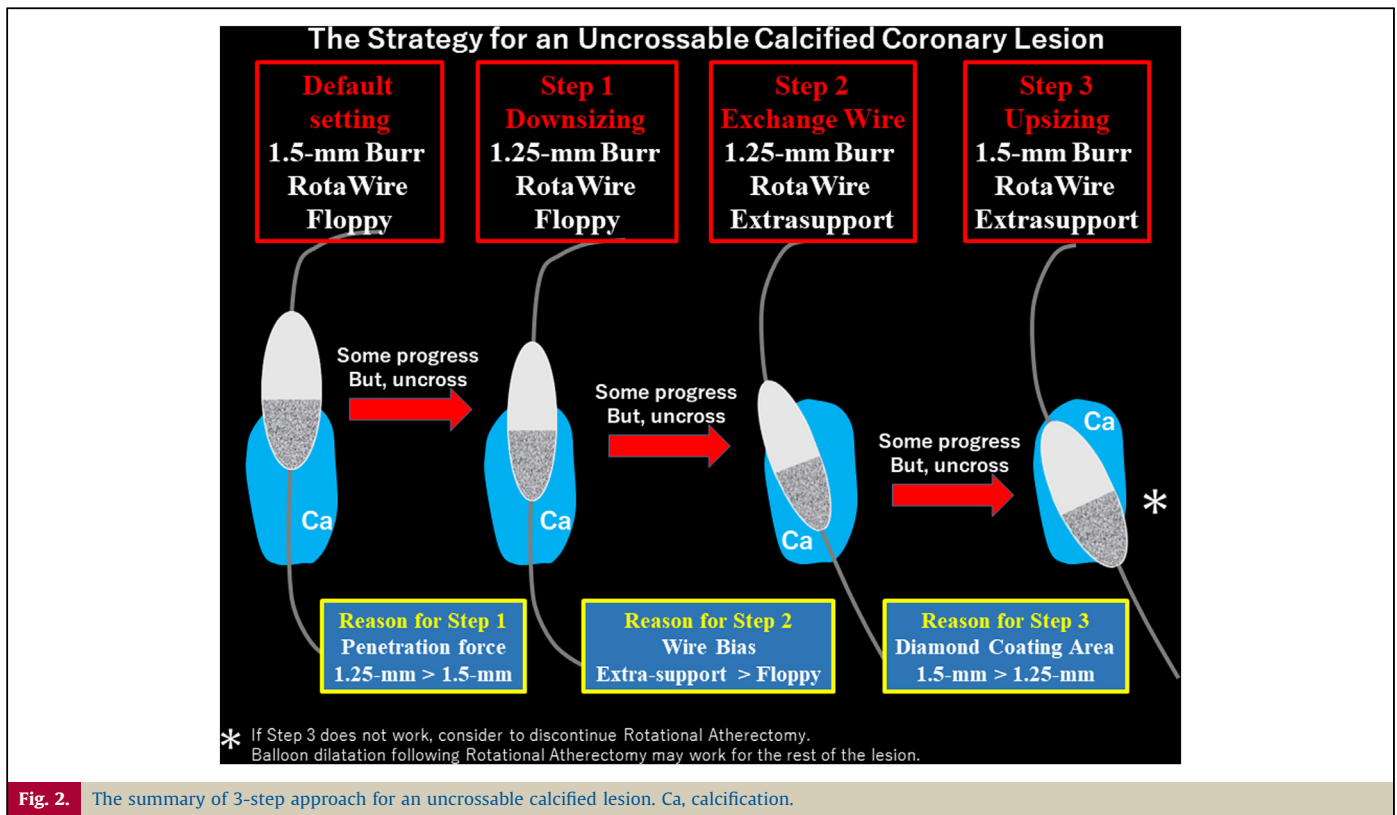
The present case shows the usefulness of the intentional switch of 2 burrs and 2 RotaWires. Although the 1.25-mm burr is considered to have greater penetration force than the 1.5-mm burr, the 1.25-mm burr has a smaller diamond coating area. Furthermore, a RotaWire Extrasupport would yield a different guidewire bias from a RotaWire Floppy, which may allow RA burrs to contact the calcified lesion more efficiently. Therefore, 4 different types of

combinations may work in a mutually complementary manner for an uncrossable calcified lesion.

Expert consensus reports recommend downsizing of the burr, when the burr cannot cross the lesion after several attempts [6]. Expert consensus reports also recommend the burr 1.5-mm as the default burr size for various lesions [6]. However, the optimal timing of downsizing of the burr has not been described in the literature including expert consensus reports. From our experience, we consider to downsize the burr, when the burr is not moving at all after several sessions in spite of better contact to the calcification (optimal speed reduction such as 3000–5000 rpm). Since we started a burr 1.5-mm, downsizing to a 1.25-mm burr from the 1.5-mm burr should be the first step for the uncrossable lesion. However, there has not been any established strategy after downsizing the burr.

The exchange of RotaWires from Floppy to Extra-support may be an alternative option for the uncrossable lesion [7], although the exchange of RotaWires was not officially recommended. When the burr 1.25-mm with the RotaWire Floppy could not cross the lesion, we considered that the burr 1.25-mm might not contact the calcification within the lesion adequately. If we use the RotaWire Extra-support instead of the RotaWire floppy, a different guidewire bias may help the burr 1.25-mm to contact the calcification within the lesion adequately. Therefore, the exchange from RotaWire Floppy to RotaWire Extra-support would be the second step for the uncrossable lesion. Some operators may prefer to exchange RotaWires before downsizing of the burr, because the cost for an additional RotaWire is much cheaper than that for an additional burr.

The upsizing of the burr may be a unique option for the uncrossable lesion. We previously reported that the burr 1.5-mm



could cross the lesion that the burr 1.25-mm could not cross [8]. The burr 1.5-mm has an advantage over 1.25-mm for crossing some calcified lesions, partly because the shape of the burr 1.25-mm is sharper than that of the burr 1.5-mm [8]. Moreover, the diamond coating area is smaller in the 1.25-mm burr than in the 1.5-mm burr, indicating that the burr 1.5-mm may contact the calcification within the lesion more efficiently. Therefore, upsizing to the 1.5-mm burr from the burr 1.25-mm would be the third step for the uncrossable lesion. The optimal timing of upsizing of the burr as well as that of downsizing of the burr has not been described in the literature. From our experience, we consider to upsize of the burr, when the burr is not moving at all after several sessions without optimal speed reduction (typically no speed reduction or 1000 speed reduction). Although we tried 4 different types of combination, each combination played a certain role for the uncrossable lesion. The summary of 3-step approach is shown in Fig. 2.

Our 3-step approach has a significant advantage over the conventional approach for the uncrossable lesion. Each combination would not require forceful manipulation of the burr, because RA operators tend to push the burr forcefully when there are no alternative options for crossing the lesion. The 3-step approach would help operators to be calm during RA, which should be the most important factor during complex PCI. On the other hand, the 3-step approach has some limitations. First, since the 3-step approach requires 2 burrs and 2 RotaWires, the total cost for RA would be greater in the 3-step approach than in the conventional RA. Although the combination of RotaWire floppy and burr 1.5-mm was used as the default setting in our case, the combination of RotaWires and burrs should be adjusted according to the lesion. If the initial combination of RotaWires and burrs successfully cross the lesion, the total cost would be the lowest. It would be helpful for the selection of appropriate RotaWires to check the conventional guidewire bias before proceeding to RA. Second, the

exchange of RotaWires from Floppy to Extra-support requires attention regarding the guidewire bias, which may be associated with vessel perforation during RA [9]. We should not use the RotaWire Extra-support for severely angulated lesions. Therefore, the 3-step approach may be contraindicated for severely angulated lesions. Third, if the third step (the burr 1.5-mm with RotaWire Extra-support) does not work, it would be difficult to cross the lesion by RA. Balloon dilatation following RA may work for such uncrossable lesions if the reason for uncrossing is an angulation within the lesion [10]. An intravascular ultrasound may help operators to decide how they manage the calcified lesion, while it would be difficult to bring the intravascular ultrasound catheter to the uncrossable lesion. It should be important to accept there are cases in which RA is unable to penetrate [6].

In conclusion, intentional switch between 1.5-mm and 1.25-mm burrs along with switch between RotaWire floppy and Extra-support was effective for an uncrossable coronary lesion. Four different types of combinations may work in a mutually complementary manner without sacrificing the safety in RA.

#### Funding

This work was supported by Grants-in-Aid for Scientific Research (C) (Kenichi Sakakura, JSPS KAKENHI Grant Number 17K09521).

#### Conflict of interest

Dr Sakakura has received speaking honoraria from Abbott Vascular, Boston Scientific, Medtronic Cardiovascular, Terumo, OrbusNeich, Japan Lifeline, and NIPRO; he has served as a proctor for Rotablator for Boston Scientific; and he has served as a consultant for Abbott Vascular and Boston Scientific. Prof. Fujita has served as a consultant for Mehergen Group Holdings, Inc.

## Acknowledgment

The authors acknowledge all staff in the catheter laboratory in Saitama Medical Center, Jichi Medical University for their technical support in this study.

## Appendix A. Supplementary data

Supplementary material related to this article can be found, in the online version, at doi:<https://doi.org/10.1016/j.jccase.2019.02.005>.

## References

- [1] Sakakura K, Inohara T, Kohsaka S, Amano T, Uemura S, Ishii H, et al. Incidence and determinants of complications in rotational atherectomy: insights from the national clinical data (J-PCI registry). *Circ Cardiovasc Interv* 2016;9:e004278.
- [2] Sakakura K, Funayama H, Taniguchi Y, Tsurumaki Y, Yamamoto K, Matsumoto M, et al. The incidence of slow flow after rotational atherectomy of calcified coronary arteries: a randomized study of low speed versus high speed. *Catheter Cardiovasc Interv* 2017;89:832–40.
- [3] Sakakura K, Taniguchi Y, Tsukui T, Yamamoto K, Momomura SI, Fujita H. Successful removal of an entrapped rotational atherectomy burr using a soft guide extension catheter. *JACC Cardiovasc Interv* 2017;10:e227–9.
- [4] Sakakura K, Ako J, Momomura S. Successful removal of an entrapped rotablation burr by extracting drive shaft sheath followed by balloon dilatation. *Catheter Cardiovasc Interv* 2011;78:567–70.
- [5] Boston\_Scientific\_Corporation. Rotablator, product document; 2016, [https://www.bostonscientific.com/content/dam/Manuals/us/current-rev-en/91119961-01A\\_Rotablator\\_eDFU\\_en-US\\_s.pdf](https://www.bostonscientific.com/content/dam/Manuals/us/current-rev-en/91119961-01A_Rotablator_eDFU_en-US_s.pdf).
- [6] Barbato E, Carrie D, Dardas P, Fajadet J, Gaul G, Haude M, et al. European expert consensus on rotational atherectomy. *EuroIntervention* 2015;11:30–6.
- [7] Kimura M, Shiraishi J, Kohno Y. Successful retrieval of an entrapped rotablator burr using 5 Fr guiding catheter. *Catheter Cardiovasc Interv* 2011;78:558–64.
- [8] Sakakura K, Taniguchi Y, Yamamoto K, Wada H, Momomura SI, Fujita H. When a burr cannot penetrate the calcified lesion, increasing burr size as well as decreasing burr size can be a solution in rotational atherectomy. *Int Heart J* 2017;58:279–82.
- [9] Yamamoto S, Sakakura K, Funayama H, Wada H, Fujita H, Momomura S. Percutaneous coronary artery bypass for type 3 coronary perforation. *JACC Cardiovasc Interv* 2015;8:1396–8.
- [10] Sakakura K, Taniguchi Y, Matsumoto M, Wada H, Momomura SI, Fujita H. How should we perform rotational atherectomy to an angulated calcified lesion? *Int Heart J* 2016;57:376–9.