

Isolated Hypoglossal Nerve Palsy Due to an Osteophyte with Atlantoaxial Dislocation

Ko Ozaki,¹ Iwao Yamakami,² Yoshinori Higuchi,³ and Toshio Fukutake⁴

Isolated hypoglossal nerve palsy (IHP), or hypoglossal nerve palsy without any other neurological signs, is rare. We report a woman with atlantoaxial dislocation (AAD) who presented with IHP due to hypoglossal nerve compression by an osteophyte at the hypoglossal canal. A 77-year-old woman presented with speech difficulties and the feeling of a swollen tongue on the left side for 3 days. Her only neurological feature was left hypoglossal nerve palsy. She had been diagnosed with AAD 2 years before. Computed tomography (CT) and high-resolution magnetic resonance imaging (MRI) revealed the compression of the basicranial hypoglossal nerve at the external orifice of the hypoglossal canal by an AAD osteophyte which was causing IHP. IHP can develop due to hypoglossal nerve compression by an osteophyte from AAD. CT and high-resolution MRI revealed this rare mechanism of IHP.

Keywords: hypoglossal nerve, atlantoaxial dislocation, craniovertebral junction, cranial nerve palsy

Introduction

Hypoglossal nerve palsy is mostly caused by tumors and trauma in the craniovertebral junction and is commonly associated with either other cranial nerve palsies or corticospinal signs. Isolated hypoglossal nerve palsy (IHP), or hypoglossal nerve palsy without any other neurological signs, is rare. Atlantoaxial dislocation (AAD) is a loss of stability between the atlas and axis (C1-C2) and can occur in any age group from various causes including trauma, inflammation, congenital abnormalities, or unknown origins. AAD presents various clinical features ranging from neck pain to fatal outcomes, and the instability of C1-C2 often forms an osteophyte. We report an AAD patient who

presented with left IHP due to hypoglossal nerve compression in the hypoglossal canal by an atlanto-occipital joint osteophyte.

Case Report

A 77-year-old woman presented with left neck pain for 1 month, followed by speech difficulties and the feeling of a swollen tongue on the left side for 3 days. She had been diagnosed with AAD without rheumatoid arthritis (RA) 2 years prior, and had no history of trauma (Fig. 1). Her medical history was not significant, except for hypertension. Physical examination showed a mild tongue deviation to the left when it extended. The tongue movement to the right was impaired, though the movement to the left was not. Her soft palate movement was normal with no hoarseness, swallowing disturbances, or other neurological signs. The neurological diagnosis was left IHP. A computed tomography (CT) scan showed the AAD and moreover, that an osteophyte involving the atlanto-occipital joint obstructed the external orifice of the left hypoglossal canal (Fig. 2). Magnetic resonance imaging (MRI) showed no mass lesions either intracranially or extracranially along the hypoglossal

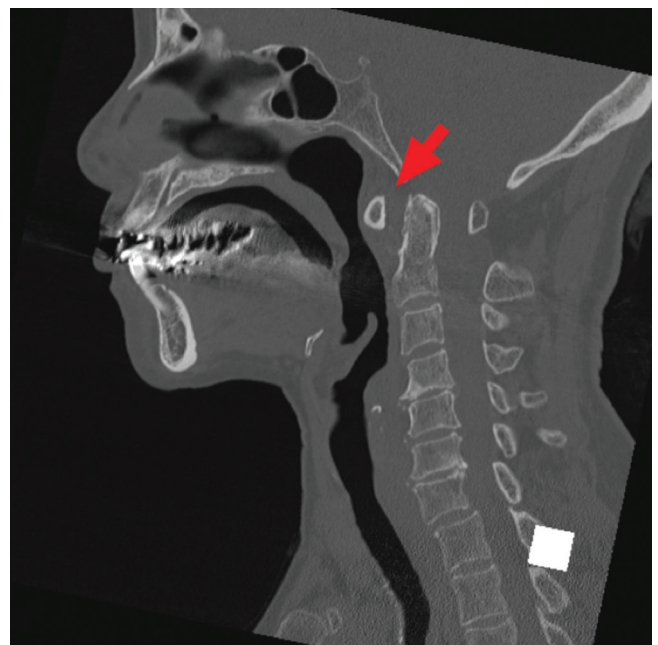


Fig. 1 Abnormal atlantodental interval revealed by sagittal bone CT. CT: computed tomography.

¹Narita Red Cross Hospital, Department of Neurosurgery, Narita, Chiba, Japan

²Seikeikai Chiba Medical Center, Department of Neurosurgery, Chiba, Chiba, Japan

³Chiba University Graduate School of Medicine, Department of Neurological Surgery, Chiba, Chiba, Japan

⁴Kameda Medical Center, Department of Neurology, Kamogawa, Chiba, Japan

Received: January 14, 2020; Accepted: March 9, 2020
Online September 16, 2020

Copyright© 2020 by The Japan Neurosurgical Society
This work is licensed under a Creative Commons Attribution-NonCommercial-NoDerivatives International License.

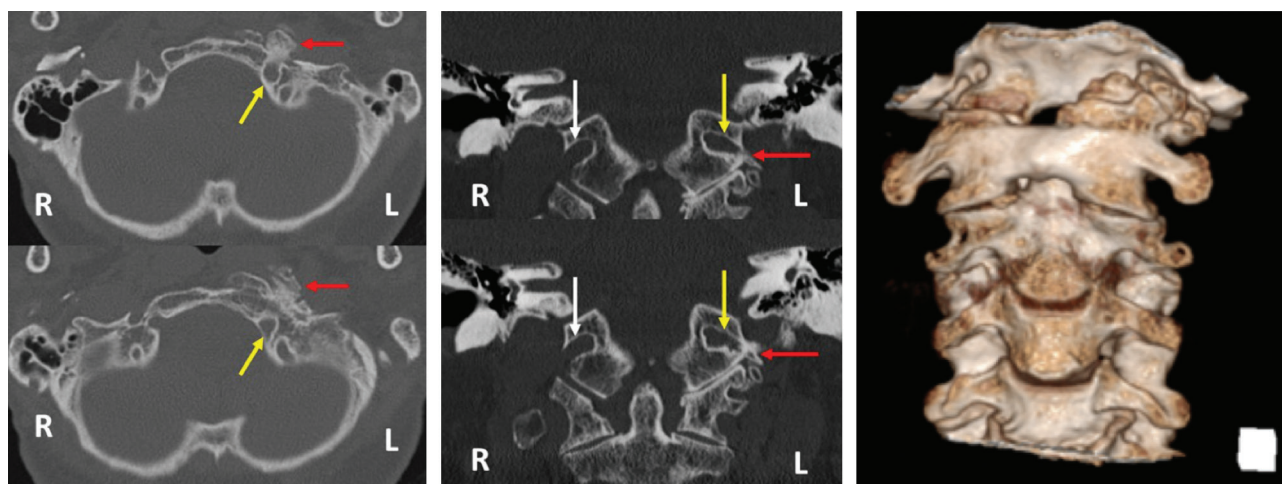


Fig. 2 Axial bone CT (left panel) shows the osteophyte (red arrow) facing the external orifice of the left hypoglossal canal (yellow arrow). Coronal bone CT at the hypoglossal canal (mid panel) shows that the right hypoglossal canal (white arrow) was widely open, while the external orifice of the left hypoglossal canal (yellow arrow) was obstructed by the osteophyte (red arrow). 3D-CT shows the large osteophyte on the external orifice of left hypoglossal canal (right panel). 3D-CT: three-dimensional computed tomography.

nerve. High-resolution MRI (balanced fast field echo; Philips Healthcare, Best, Netherlands) revealed a discontinuity in the basicranial segment of the left hypoglossal nerve at the external orifice of the hypoglossal canal (Fig. 3). The radiologic diagnosis was IHP due to AAD osteophyte compression of the hypoglossal nerve. Surgical intervention to decompress the hypoglossal nerve was not performed after weighing its invasiveness and effectiveness. Her symptoms and signs were stable during the 1-year follow-up period.

Discussion

The trajectory of the hypoglossal nerve, from the brainstem to the lingual muscles, comprises five segments: medullary (nuclear), cisternal, basicranial, retro- and prestyloid, and submandibular. Intracranially, the hypoglossal nerve arises from the hypoglossal nucleus in the medulla, travels along the dorsal side of the vertebral artery, penetrates the dura mater, and runs into the hypoglossal canal. Extracranially, this nerve runs near the internal carotid artery, the vagus and accessory nerves, and communicates to the vagus, first, and second cervical nerves.¹⁾ Damage to any point along this trajectory from the medulla to the lingual muscles causes a hypoglossal nerve palsy, and in the present case, the compression of the hypoglossal nerve at the hypoglossal canal by an osteophyte caused hypoglossal nerve palsy. Because of the anatomical characteristics of the hypoglossal nerve, hypoglossal nerve palsy is usually associated with other cranial nerve palsies (IX, X, and XI) and/or pyramidal signs,²⁾ and IHP is rare.

The most frequent cause of IHP is skull base tumors including metastases, meningiomas, and malignant tumors. Less frequently, IHP develops due to trauma, vascular pathologies, and inflammatory etiologies, among

others.³⁾ Except for the present case, two cases of IHP due to osteophytes have been reported.^{4,5)} One case was of a 92-year-old woman without any AAD history; the other case was of an 86-year-old woman with a history of cervical spondylotic myelopathy requiring C2-4 laminectomy 2 years previously. Both cases were of elderly patients with no AAD history. This is the first case report of IHP due to an osteophyte from AAD. AAD resulted in the development of an osteophyte involving the atlanto-occipital joint, which resulted in mechanical compression of the basicranial segment of the hypoglossal nerve in the hypoglossal canal. RA often leads to AAD. Hypoglossal nerve palsy caused by AAD with RA was bilateral in the three cases which Blankenship et al. reported.⁶⁾ The unilateral IHP in the present case was caused by an osteophyte without RA.

Diagnosing the exact mechanism of IHP is often challenging. In the present case, CT and high-resolution MRI diagnosed the osteophyte compression of the basicranial segment of the hypoglossal nerve in the external orifice of the hypoglossal canal.

The hypoglossal canal area can be approached surgically via either a transnasal, transoral, or a transcranial approach. At present, any approach to the hypoglossal canal is associated with considerable invasiveness and major risk and may not lead to recovery from hypoglossal palsy by the surgical removal of an osteophyte. Further advances in surgical techniques may be more effective and less invasive in decompressing the hypoglossal nerve at the hypoglossal canal. Local steroid injection is recommended as a non-surgical treatment for the entrapment neuropathy.⁷⁾ However, the effect is transient and local steroid injection into the hypoglossal canal is difficult and dangerous because of anatomical characteristics of the canal.

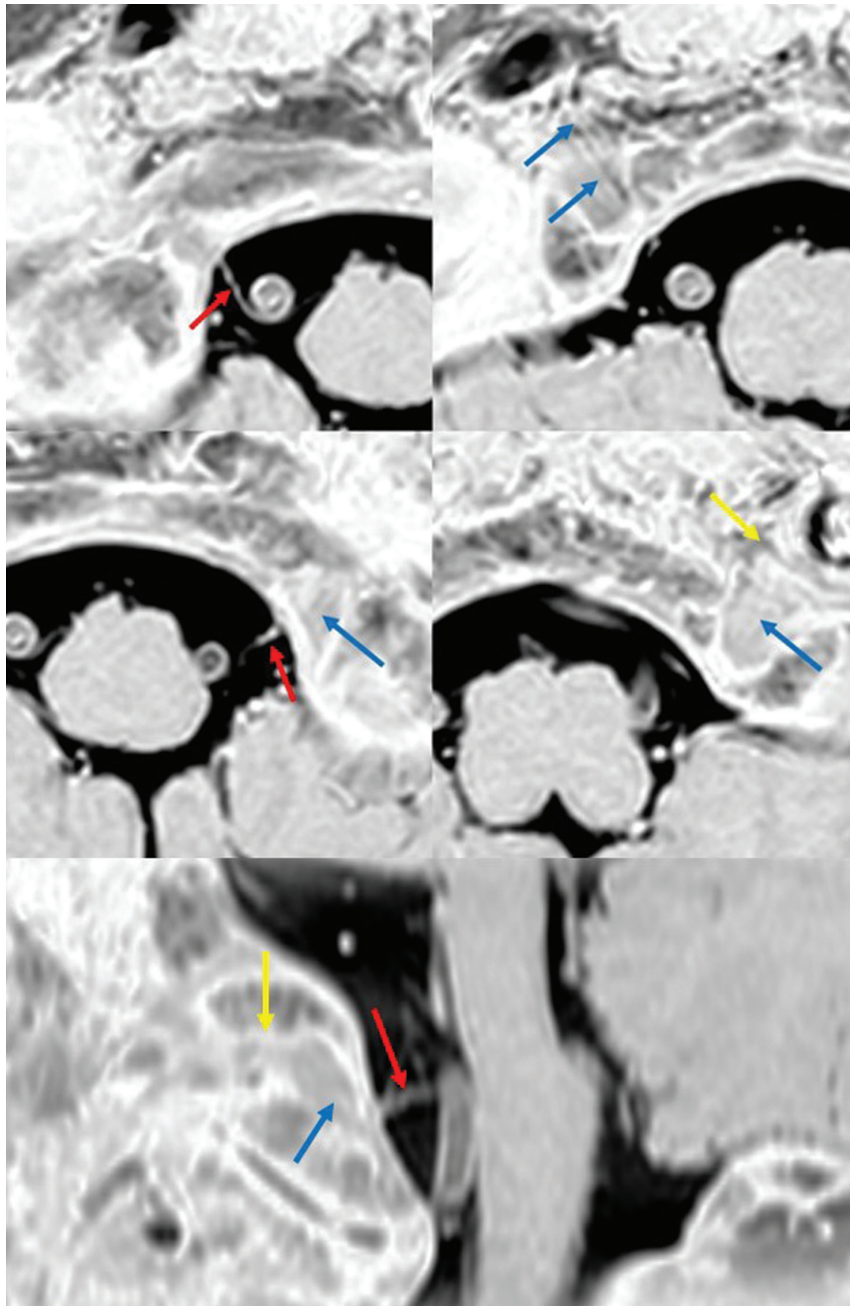


Fig. 3 High-resolution MRI of the bilateral hypoglossal nerves. Upper panel: The right hypoglossal nerve, the cisternal segment (red arrow), and the basicranial segment are visible in the hypoglossal canal (blue arrow); isointense nerve surrounded by the hypointense cerebrospinal fluid.⁹⁾ The right hypoglossal nerve is intact the whole way through the hypoglossal canal. Mid panel: The left hypoglossal nerve, the cisternal segment (red arrow), and the basicranial segment are visible in the hypoglossal canal (blue arrow). The proximal basicranial segment was intact, while the continuity in the distal segment was lost in the external orifice of the canal (yellow arrow). Lower panel: Oblique sagittal image of the left hypoglossal nerve shows the cisternal segment (red arrow), and the basicranial segment are visible in the hypoglossal canal (blue arrow), but the external orifice of hypoglossal canal is obstructed by osteophyte (yellow arrow). MRI: magnetic resonance imaging.

Conclusion

This is the first case report of IHP due to AAD osteophyte compression of the hypoglossal nerve at the hypoglossal canal, which was diagnosed by CT and high-resolution MRI.

Conflicts of Interest Disclosure

The authors declare no conflicts of interest associated with this manuscript.

References

- 1) Iwanaga J, Fisahn C, Alonso F, et al.: Microsurgical anatomy of the hypoglossal and C1 nerves: description of a previously undescribed branch to the Atlanto-occipital joint. *World Neurosurg* 100: 590–593, 2017
- 2) Combarros O, Alvarez de Arcaya A, Berciano J: Isolated unilateral hypoglossal nerve palsy: nine cases. *J Neurol* 245: 98–100, 1998
- 3) Keane JR: Twelfth-nerve palsy. Analysis of 100 cases. *Arch Neurol* 53: 561–566, 1996
- 4) Patro SN, Torres C, Riascos R: An unusual case of isolated hypoglossal nerve palsy secondary to osteophytic projection from the atlanto-occipital joint. *Neuroradiol J* 27: 361–364, 2014
- 5) Patron V, Roudaut PY, Lerat J, et al.: Isolated hypoglossal palsy due to cervical osteophyte. *Eur Ann Otorhinolaryngol Head Neck Dis* 129: 44–46, 2012
- 6) Blankenship LD, Basford JR, Strommen JA, Andersen RJ: Hypoglossal nerve palsy from cervical spine involvement in rheumatoid arthritis: 3 case reports. *Arch Phys Med Rehabil* 83: 269–272, 2002
- 7) Arnold WD, Elsheikh BH: Entrapment neuropathies. *Neurol Clin* 31: 405–424, 2013
- 8) Linn J, Peters F, Moriggl B, et al.: The jugular foramen: imaging strategy and detailed anatomy at 3T. *AJNR Am J Neuroradiol* 30: 34–41, 2009

Corresponding author:

Ko Ozaki, MD, Department of Neurological Surgery, Chiba University Graduate School of Medicine, Inohana 1-8-1, Chuo-ku, Chiba, Chiba 260-8670, Japan.

✉ ozako.1115@gmail.com