



Original Article

Magnetic resonance assessment of medial plica syndrome of knee from child to adult with arthroscopic correlation: A single center experience and literature review

Reddy Ravikanth^{a*}, Anoop Pilar^b, Pooja Majumdar^c

^aDepartment of Radiology, Holy Family Hospital, Thodupuzha, Kerala, India, ^bDepartment of Orthopedics, St. John's Medical College Hospital, Bengaluru, Karnataka, India, ^cDepartment of Medicine, INHS Kalyani, Visakhapatnam, Andhra Pradesh, India

ABSTRACT

Objective: Synovial plicae are mesenchymal tissue remnants invaginating into the knee joint. Their classification is based on the location as lateral, mediopatellar, suprapatellar, and infrapatellar. Mediopatellar plica is commonly symptomatic. The purpose of this study was to identify magnetic resonance (MR) characteristics of the medial plica and to correlate with arthroscopy for cause confirmation in patients with painful knee. **Materials and Methods:** The current study was undertaken over a 2-year period between July 2017 and June 2019 in the department of radiology at a tertiary care hospital in India. MR examinations of the knee joint were performed using QUADKNEE coil on a 1.5-T scanner (Signa, General Electric Medical Systems, Milwaukee, WI, USA). The criteria studied were: presence of the plica, interposition into the femoropatellar joint, intraarticular effusion, and fenestrated aspect. Twenty-two knees (20 patients) diagnosed with mediopatellar plica syndrome on MR imaging (MRI), and with no other knee pathology, were treated with arthroscopic division of plicae. **Results:** Only two (20.0%) of the ten knees in which the plicae had not been divided have shown improvement and six (85.7%) of the seven knees in which plica had been divided ($P < 0.05$) have shown improvement. Subsequent division of the plicae resulted in improvement in seven of the eight knees (87.5%) ($P < 0.01$). Patients presented with crepitus in 9% of cases (2 of 22), instability in 13.6% (3 of 22), pseudo-locking in 45.4% (10 of 22), and quadriceps atrophy in 54.5% (12 of 22). Fourteen knees (63.6%) had Grade 2 plica based on thickness. Twelve knees demonstrated (54.5%) Grade 2 intermediary effusion. Plica was fenestrated in three patients (13.6%). All patients regained full range of motion. Lysholm knee scale scores were compared prior to and postsurgery (preoperative status, 65.22 ± 7.41 vs. postoperative status, 89.43 ± 8.72) which revealed a significant clinical improvement ($P < 0.001$). Average visual analog scale (VAS) scores (0 – no pain, 10 – excruciating pain) when compared demonstrated a mean improvement was 4 points; from 6 points before surgery and 2 points' postsurgery after a mean follow-up of 3 months. About 68% of patients after arthroscopic resection had an average VAS score of 0 point and were totally pain free. **Conclusion:** Noninvasive capability of MRI can be used as a screening method in the diagnosis of mediopatellar plica syndrome and should be included in the differential diagnosis of internal derangement of the knee.

KEYWORDS: Arthroscopy, Lysholm knee scale score, Magnetic resonance imaging, Painful knee, Synovial plica

Submission : 10-Jul-2019
Revision : 30-Aug-2019
Acceptance : 18-Sep-2019
Web Publication : 31-Dec-2019

INTRODUCTION

Synovial plicae are mesenchymal tissue remnants invaginating into the knee joint between the distal femoral and proximal tibial epiphyses in the 8-week-old embryo. Synovial plicae in the knee are the result of incomplete resorption of embryological remnants. Their classification is based on the


*Address for correspondence:

Dr. Reddy Ravikanth,
Department of Radiology, Holy Family Hospital,
Thodupuzha - 685 605, Kerala, India.
E-mail: ravikanthreddy06@gmail.com

This is an open access journal, and articles are distributed under the terms of the Creative Commons Attribution-NonCommercial-ShareAlike 4.0 License, which allows others to remix, tweak, and build upon the work non-commercially, as long as appropriate credit is given and the new creations are licensed under the identical terms.

For reprints contact: WKHLRPMedknow_reprints@wolterskluwer.com

How to cite this article: Ravikanth R, Pilar A, Majumdar P. Magnetic resonance assessment of medial plica syndrome of knee from child to adult with arthroscopic correlation: A single center experience and literature review. Tzu Chi Med J 2020; 32(4): 351-6.

Access this article online	
Quick Response Code: 	Website: www.tcmjmed.com
	DOI: 10.4103/tcmj.tcmj_150_19

location as lateral, mediopatellar, suprapatellar, and infrapatellar. The prevalence of synovial plicae ranges from 3% to 30% in western populations with most studies citing approximately 10% [1]. The inferior and superior plicae are the most common (50%–65%) with very little clinical relevance [2]. Mediopatellar plica is commonly symptomatic and is present at autopsies in one of the every three or four knees. The lateral plica is rare (1%–3%), wide and thick and has a prevalence in one of every 15 knees [3]. Chondromalacia patellae and medial impingement against the patellofemoral articular surfaces are often incidentally associated other knee pathologic conditions. Medial plica may become symptomatic in circumstances such as blunt trauma and overuse of the knee. Ultrasonography, conventional arthrography, conventional computed tomography (CT), and magnetic resonance imaging (MRI), CT and MR arthrography can demonstrate the presence of synovial plica and measure their size with good accuracy. Gold standard is arthroscopy which allows for dynamic examination and very precise assessment of the plica [4].

Embryology and anatomy

The synovial membrane of the knee is a complex structure, and synovial plicae are formed as remnant invaginations of the synovial membrane. Mesenchymal condensations representing menisci and cruciate ligaments emerge and a joint cavity proper separating the three cartilaginous anlagen can be identified at around the 8th week of fetal development. Over the next 2 weeks, the synovial septa undergo partial resorption and the meniscotibial, femoro-meniscal, and patellofemoral regions unite to form a larger cavity which becomes the knee joint. In regions of the knee joint where mesenchymal cavitation does not coalesce, the remnant mesenchymal tissue differentiates into folds of synovium, and when large enough, are considered as synovial plicae.

Clinical examination

Plicae are synovial remnants during the embryological development of the knee and have a potential to become inflamed. Knee pain is a very common complaint seen in the clinical setting of plica. Inflammation, osteochondral defects, medial meniscal tear, or medial patellar plica form the differential diagnosis of medial knee pain. The diagnosis of medial plica syndrome is made on the basis of physical examination and radiological imaging, but the current gold standard investigation is arthroscopy. Clinical examination is aimed at reproducing the patient's symptoms if the snapping plica is palpated at the medial edge of the patella. However, a definitive diagnosis is possible after surgery. Symptoms are often related to patellofemoral joint motion such as popping or snapping, pain, crepitus or effusion, and the clinical picture mimics a medial meniscal tear or transient patellar subluxation. Relief of chronic symptoms due to plicae is with physiotherapy, non-steroidal, anti-inflammatory drugs (NSAIDs), local steroidal injections, and electrophoresis. However, mainstay of treatment is surgical resection.

Imaging appearances

Proton density, T2-weighted and fat-suppressed T2-weighted, or gradient-echo images are routinely used for the plica evaluation and can be seen as low-signal

intensity bands in the background of high-signal intensity joint fluid [5]. MR arthrography is a useful technique when a clinically significant plica is suspected and performed with T1 weighting and fat suppression with injection of intraarticular gadolinium-based contrast agents when there is minimal articular fluid. The contrast agents distend the capsule and highlight the joint surfaces and provide excellent visualization of the plicae. Symptomatic plicae appear thickened with presence of synovitis and may cause erosion of the patellar cartilage and condylar surfaces. The relevance of a given plica seen on MRI is not necessarily based on morphologic features and size and do not indicate the clinical significance of plica. Mediopatellar plica is the most studied plica because it is commonly symptomatic. The suprapatellar and infrapatellar plicae have little clinical relevance but have the most common prevalence, and lateral patellar plica is a rarity [6].

Sakakibara [7] classified mediopatellar plicae into four types based on the size criteria. The classification scheme is simple to use and is routinely used in reporting. Types A and B are not symptomatic plicae. Types C and D are symptomatic plicae as they become hard and thickened and can lead to entrapment between the patella and medial condyle causing symptoms similar to internal derangement of the knee. Fenestrated plicae (Type D) have more clinical relevance and are more likely to be symptomatic than Type C plica. Fenestrated plica can cause symptoms by causing impingement on the cartilage of the medial femoral condyle in extension and articular cartilage of the medial patellar facet in flexion. Arthroscopic resection is the gold standard treatment for symptomatic plicae.

MR images demonstrate plicae of varying sizes as low-signal-intensity bands found in the suprapatellar, infrapatellar, mediopatellar, and lateral regions. The mediopatellar plica is also referred to as plica synovialis patellaris, patellar meniscus, synovial shelf, lino band, or plica alaris. The mediopatellar plica arises from the medial wall of the knee joint, runs obliquely downward, and inserts into the synovium covering the infrapatellar fat pad and frequently has a separate attachment or may be connected with the suprapatellar plica. The free border of a large mediopatellar plica can run under the medial facet of the patella or may extend over the medial facet of the trochlea.

Mediopatellar plicae demonstrate low-signal intensity on both T1- and T2-weighted images. Plicae can be easily identified with minimal joint distension, and moderate-to-severe distension could pull the medial plica away from the medial condyle, making a Type C plica to look like a Type B plica. Axial and sagittal sections of T2-weighted MR images are obtained with or without fat suppression for optimal visualization of mediopatellar plicae. Mediopatellar plica when large in size might interfere with arthroscopic visualization of the medial compartment of the knee.

Management

Arthroscopy is the gold standard to confirm the diagnosis [8]. After a diagnosis of mediopatellar, plica syndrome has been made based on clinical examination findings and further confirmation on imaging studies, patients were initiated

with conservative treatment that included NSAIDs or steroid cortisone injections and quadriceps strengthening exercises. Response to conservative treatment is mostly dependent on the duration of symptoms and age of patients. Sakakibara [7] classified mediopatellar plica into four Types (A, B, C, and D). Type C and D are considered symptomatic when the plica is trapped between patella and the medial condyle. Treatment is first conservative with drugs, and physical therapy and response are greatest in younger patients with a shorter duration of symptoms. Surgical management includes division and excision of pathological plica through arthroscopy. Excision of pathological plica involves the use of shaver, punch, scissor, or diathermy devices to resect the plica back to a level where it no longer impinges. Breaking the continuity of the plica is termed division. There may be a risk of the two cut ends re-joining through scar tissue in patients in whom the plica is divided resulting in return of their symptoms; excision of the plica has been suggested to be preferential for the above reason. A standardized and complete arthroscopy of the knee through the standard anteromedial and anterolateral arthroscopy portals is crucial for accurate diagnosis. Probing of the menisci should be performed and visualization of all compartments of the knee to ensure that all pathological causes of pain present within the knee are excluded.

Aim of the study

The purpose of this study was to identify MR characteristics of the medial plica and to correlate with arthroscopy for cause confirmation in patients with painful knee.

MATERIALS AND METHODS

This study was undertaken in the department of radiology at a tertiary care hospital in India over the 2-year between July 2017 and June 2019. The study protocol was approved by the institutional ethics committee of Holy Family Hospital (approval no: IEC/1/972/2017 dated 23rd July, 2017). and informed and written consent was obtained from all patients in accordance with the ethical principles for human investigation outlined by the Second Declaration of Helsinki. Clinical features such as intermittent pain in the anterior aspect of the knee, palpable tender plica, painful clicking with activity and giving-way were considered in the diagnosis of synovial plica syndrome. MR examinations were performed using QUADKNEE coil on a 1.5-T scanner (Signa, General Electric Medical Systems, Milwaukee, WI, USA). The criteria studied were: the presence of the plica, interposition into the femoropatellar joint, intraarticular effusion and fenestrated aspect. Twenty-two knees (20 patients) diagnosed with mediopatellar plica syndrome on MRI, and with no other knee pathology, were treated with arthroscopic division of plicae [Figures 1a and b and 2-4].

We considered a medial plica present when we found a linear structure floating but also when there was a thickening or a bulge of the joint capsule back the retro patellar fat pad, supposing that this thickening is composite of the joint capsule and the medial plica collapsed against the capsule. The medial plica was considered floating when we could individualize a linear band with local effusion. The interposition was defined

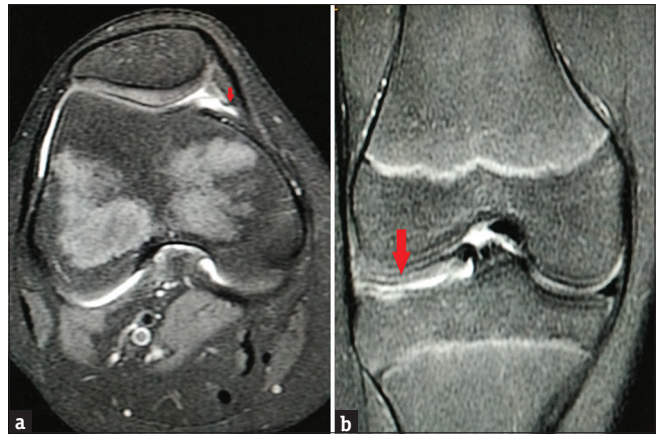


Figure 1: (a) Axial fat-sat spine-cho proton density magnetic resonance image of the right knee (3000/50) in a 14-year-old female demonstrating a cord-like elevation (arrow) in the medial synovial wall consistent with mediopatellar plica (Sakakibara type A). (b) Associated discoid lateral meniscus (arrow) in the same patient as in (a). Coronal fat-sat spine-cho proton density magnetic resonance image of the right knee (4136/50) demonstrating lateral meniscal body width of more than 15 mm with absent bow tie sign

as a medial plica crossing the interposition line. The interposition line was defined as a line extended between the medial tip of the patella and the point X. This point X was variable on each slice and was defined as the intersection of the tangents of the medial condylar facet and the medial trochlear facet [Figure 3]. The grading of plica thickness was done in four levels: the absence of plica is Grade 0, <1 mm is Grade 1, <2 mm is Grade 2, <3 mm is Grade 3. Intra-articular effusion was also graded in 4 levels: grade 0 was no effusion or physiological effusion, Grade 1 small effusion, Grade 2 intermediary effusion, and Grade 3 important effusion. The plica was considered fenestrated when there had fluid inside.

In all patients, clinical examination findings, radiological, and intraoperative findings were evaluated. Parameters such as pain, range of motion, quadriceps atrophy, and patellar stability and were evaluated using preoperative status and 3rd week follow-up. Based on the information obtained from medical records, preoperative and postoperative Lysholm Knee Scale scores were assessed and patients were scaled (0–100) related with their complaints during activity. Lysholm scores below 70 were considered as poor, between 70 and 79 as fair, between 80 and 89 as good, between 90 and 94 as very good, and between 95 and 100 were considered as excellent results. After the 1st day of surgery, patients are allowed mobilization, and physical therapy was begun. Postoperative scores were calculated on the 3rd week follow-up (18–29 days). The average follow-up was 3 months for postoperative cases of synovial plicae. MRI findings of pathological plicae were reviewed retrospectively and documented.

Statistical analysis

Descriptive statistics were reported using numbers and percentages for categorical variables. The analysis was done using Microsoft Excel 2013, Microsoft Corp., Redmond, WA, USA and SPSS Statistical Package Version 20.0, IBM Corp., Armonk, New York, USA. $P < 0.05$ was considered statistically significant.

RESULTS

This study was undertaken on 22 patients with a clinical diagnosis of synovial plica syndrome referred for MRI at a tertiary care hospital over the 2-year period. Only two (20.0%) of the ten knees in which the plicae had not been divided have shown improvement and six (85.7%) of the seven knees in which plica had been divided ($P < 0.05$) have shown improvement. Subsequent division of the plicae resulted in improvement in seven of the eight knees (87.5%) ($P < 0.01$).

The mean age was 14.2 years for the study group (14 females and 6 males; range age: 8–20). The medial plica syndrome predominantly affected females (Sex Ratio = 2.66). Two patients presented a bilateral plica syndrome (10%). In the current study, a frequent sporting activity was present in 33.3% of cases (6 of 18) and a triggering trauma in 55.5% (10 of 18). Patients presented with crepitus in 9% of cases (2 of 22), instability in 13.6% (3 of 22), pseudo-locking in 45.4% (10 of 22), and quadriceps atrophy in 54.5% (12 of 22). Fourteen knees (63.6%) had Grade 2 plica based on thickness. Twelve knees demonstrated (54.5%) Grade 2 intermediary effusion. Plica was fenestrated in 3 patients (13.6%). Arthroscopic plica resection was undertaken in eighteen knees with complete regression of the pain at 6 months in 77.7% of cases (14 of 18 patients).

The diagnosis of symptomatic mediopatellar plica on arthroscope was due to range of findings such as (A) plica edema and hyperemia; (B) hypertrophy of plica breadth over 1/2–1/3 of the femoral condyle width; (C) thickening, stiffening, and fibrillation with loss of elasticity leading to Plica ischemia; and (D) plica reaching into the joint space in movement; softening of cartilage with exfoliation and indentation-like wear. Arthroscopic classification criteria for mediopatellar plica used in the current study was: Type A: Plica forming a membrane-like or cord-like bulge on the medial wall, Type B: Shelf-like enlargement of plica, with its breadth exceeding 1/2–1/3 of medial femoral condyle, Type C: A large shelf-like enlargement covering the anteromedial femoral condylar surface; and Type D: Retains the same shape as Type C, with bucket handle tears in the middle of the plica associated with a double insertion on the medial wall.

Four knees had hypertrophic plica with no intra-articular degenerative findings. Three knees demonstrated softening of the patellar cartilage. In the current study, all medial menisci were intact with no additional intra-articular lesions which would have resulted as the source of symptoms; three patients had restriction in the range of motion because of effusion, but resolved within 2 weeks in the early postoperative period; eighteen patients showed satisfactory functional outcome; three knees of two patients with a Lysholm Knee Scale score below 75 complained of pain and was defaulted on physical therapy. In the current study, none of the patients demonstrated degenerative changes in the medial femoral compartment. All of the patients regained a full range of motion. Comparative scores before and after surgery revealed a significant clinical improvement (preoperative status, 65.22 ± 7.41 vs. postoperative status, 89.43 ± 8.72 ; $P < 0.001$). Average visual analog scale (VAS) scores (0 – no pain, 10 – excruciating pain)

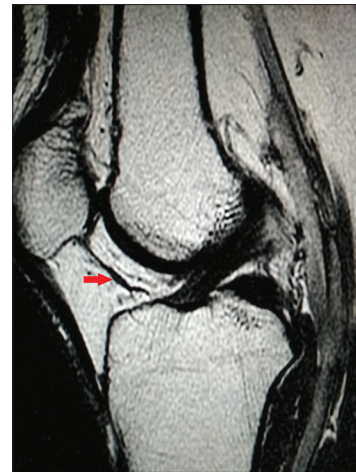


Figure 2: Sagittal T2-weighted image (3400/103) demonstrating a band-like hypointense structure (arrow) traversing through the infrapatellar fat pad consistent with a diagnosis of infrapatellar plica

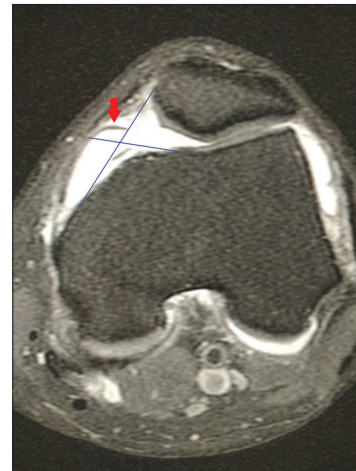


Figure 3: Axial fat-sat spin-echo proton density (3000/50) magnetic resonance image demonstrate a thin, hypointense line (arrow) originating from the medial wall of the left knee joint consistent with mediopatellar plica (Sakakibara type B). Intersection point defining the point X

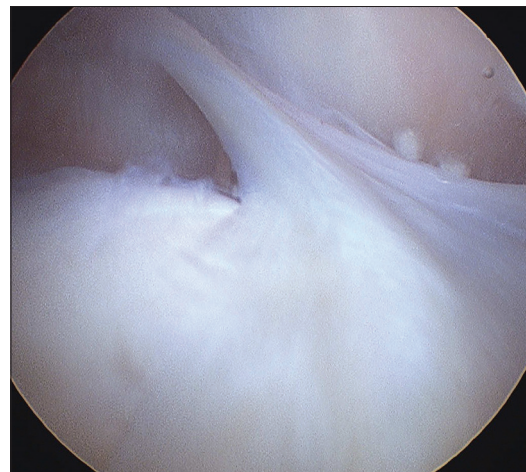


Figure 4: Medial patellar plica on arthroscopy

when compared demonstrated a mean improvement was 4 points; from 6 points before surgery and 2 points postsurgery

after a mean follow-up period of 3 months. Sixty-eight percent of patients after arthroscopic resection had an average VAS score of 0 point and were totally pain free.

DISCUSSION

The prevalence of mediopatellar plica is the most common in young adults with sports and repetitive activities. Medial patellar pain during physical activity or rest is the commonest symptom with a cord-like tender structure palpable medial to the patella. Axial and sagittal proton density or T2-weighted images with or without fat suppression are most valuable in demonstrating mediopatellar plica, as they appear as low signal intensity bands on both T1- and T2-weighted images, pronounced against the background of high signal fluid intensity within the joint cavity.

The mediopatellar plica is frequently considered to be pathological and is most commonly symptomatic [9]. Most studies that have described mediopatellar plica were retrospective studies series with relatively small numbers of patients [10]. Studies have even reported the infrapatellar plica as pathological [11]. Demirag *et al.* [2] reported a series of 14 patients with anterior knee pain and a thickened infrapatellar plica. In the series, the post excision of plica all patients improved but for three patients who developed recurrent symptoms later. Kinnard and Levesque [12] implicated suprapatellar plica as a common pathology and reported a series of 18 patients with suprapatellar plica who underwent arthroscopic excision. In the series, 10 patients showed complete resolution of symptoms, three showed improvement, five had no improvement and one reported being worse. Reports of symptomatic lateral patellar plica are rare [13]. Dorchak *et al.* [14] in a series of 51 cases had reported four pathological lateral plicae. In the series, two patients had complete relief following arthroscopic excision, one patient showed improvement and one patient showed no improvement at 4 years' postsurgery.

Knee plicae are embryological remnants in the development of the synovial membrane which are synovial invaginations into the joint cavity. Mediopatellar plica typically involves the young patients involved in repetitive athletic activity. Plicae ≥ 1 mm are mostly asymptomatic and may be prevalent in over 70% of young population. However, plicae may become inflamed and symptomatic, with fibrosis occurring in chronic cases rendering the plicae painful and inflexible. We have described the medial plica shelf syndrome as a clinical entity in a female child of 8 years age who presented with chronic medial knee pain with symptoms suggesting a possible cause of internal derangement of the knee. It most frequently mimicked chondromalacia of the patella and may also lead to it [Figure 5a and b]. The results of patellar division not only have been gratifying over the period of follow-up (3 months) but in all probability have prevented further serious damage to the knee. In the current study, good to excellent pain relief has been demonstrated in majority of patients at final follow-up following arthroscopic excision. This finding came to light regardless of the duration of symptoms or size of the plica. The current study focuses on the adolescent population (10–19

years), and we demonstrated a high rate of female prevalence [Figure 6a and b]. According to the findings of the current study, we hypothesize the fact that in children to adults, mediopatellar plica syndrome represents a component of the abnormal patellofemoral biomechanics due to repetitive activity. In the current study, we had a 20-year-old young adult female patient with symptoms relating to mediopatellar plica and did not show improvement postsurgery [Figure 7a and b]. Physiotherapy, NSAIDs and steroid injection did not better her condition and her symptoms were relieved following a second

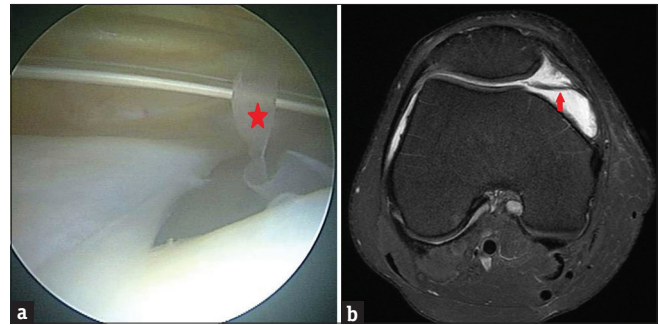


Figure 5: (a) The Diagnosis of mediopatellar plica (star) on arthroscopy demonstrating plica ischemia with thickening, stiffening and elasticity loss. (b) Medial patellar plica (Sakakibara type B) in an 8-year-old female child. Axial fat-sat spine-cho proton density-weighted magnetic resonance image of the right knee (3000/50) demonstrating a cord-like elevation (arrow) originating from the medial synovial wall

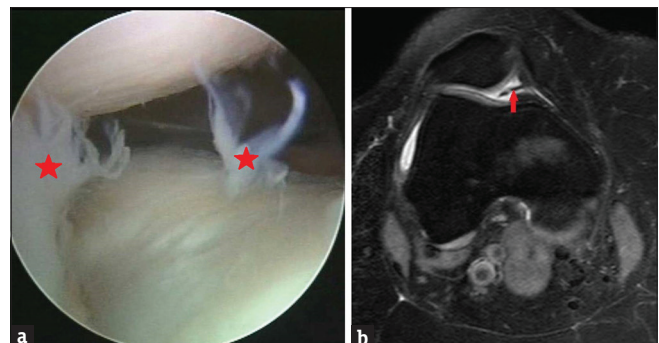


Figure 6: (a) Hypertrophic medial plica tissue (arrow) extending intra-articularly (Sakakibara type C) in a 14-year-old adolescent female. (b) Diagnosis of mediopatellar plica (star) on arthroscopy demonstrating plica hyperemia and edema

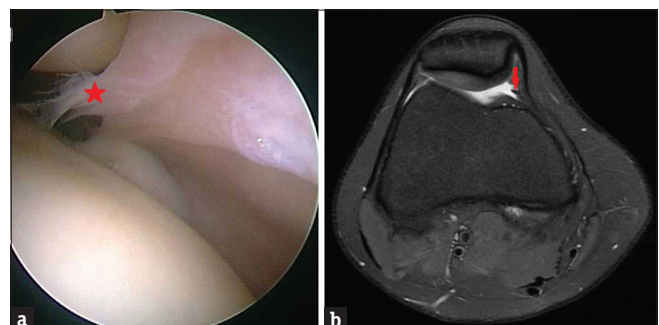


Figure 7: (a) Medial patellar plica (Sakakibara type A) in a 20-year-old young adult male. Axial fat-sat spin-echo proton density (3000/50) magnetic resonance image demonstrating a thin, hypointense line (arrow) originating from the medial wall of the right knee joint. (b) Diagnosis of mediopatellar plica (star) on arthroscopy demonstrating plica reaching the joint space, exfoliates, or an indentation like wear

arthroscopic excision in which retinacular bands and synovial plicae were removed.

The prevalence of synovial plica is variable based on different imaging modalities. Only few prior imaging studies are available in literature which highlight the importance of plicae detection on MRI detected as low-signal intensity bands against high-signal fluid intensity in the joint space. Arthroscopy is the gold standard procedure and is also more prevalent to diagnose the synovial plica. Suprapatellar plicae were classified into four types by Zidorn [15] based on the plicae morphology. Series on infrapatellar plica injury reported by Cothran *et al.* [16] is the only available study. Mediotatellar plicae categorization into four groups by Sakakibara [7] is the simplest and is based on size criteria. Rare correlation of lateral plica with lateral subluxation of patella was reported by Ogata and Uthoff [17].

The findings of the current study are compliant with earlier studies. Barber [18] demonstrated complete resolution of symptoms in 18/18 patients following arthroscopic excision of plica. Koshino and Okamoto [19] demonstrated improvement in 26/32 patients after medial plica excision. Muse *et al.* [20] demonstrated resolution of symptoms in 38/42 patients following excision of plica. Munzinger *et al.* [21] demonstrated good improvement in 12/15 patients and fair improvement in 3/15 patients postexcision of medial plica.

CONCLUSION

Synovial plica syndrome is diagnosed based on findings such as diffusely thickened plica with nonspecific findings on MRI in the clinical setting of trauma and pain. Noninvasive capability of MRI can be used as a screening method in the diagnosis of mediotatellar plica syndrome and should be included in the differential diagnosis of internal derangement of the knee. The current study based on VAS scores concludes that synovial plicae of the knee may have a definite correlation with painful knee. Associated lesions of the knee make synovial plica evaluation often difficult to analyze.

Limitations of the study

The limitation of our study includes relatively small number of cases. Further prospective and retrospective studies must be undertaken on a large scale to identify parameters on imaging and arthroscopy for easily missed and neglected diagnosis of synovial plica syndrome. The significance of the plica diagnosis can avoid uncertainty, unnecessary arthroscopies, and can alter the patient management.

Financial support and sponsorship

Nil.

Conflicts of interest

There are no conflicts of interest.

REFERENCES

1. Al-Hadithy N, Gikas P, Mahapatra AM, Dowd G. Review article: Plica syndrome of the knee. *J Orthop Surg (Hong Kong)* 2011;19:354-8.
2. Demirag B, Ozturk C, Karakayali M. Symptomatic infrapatellar plica. *Knee Surg Sports Traumatol Arthrosc* 2006;14:156-60.
3. Vassiou K, Vlychou M, Zibis A, Nikolopoulou A, Fezoulidis I, Arvanitis D. Synovial plicae of the knee joint: The role of advanced MRI. *Postgrad Med J* 2015;91:35-40.
4. Weckström M, Niva MH, Lamminen A, Mattila VM, Pihlajamäki HK. Arthroscopic resection of medial plica of the knee in young adults. *Knee* 2010;17:103-7.
5. García-Valtuille R, Abascal F, Cerezal L, García-Valtuille A, Pereda T, Canga A, et al. Anatomy and MR imaging appearances of synovial plicae of the knee. *Radiographics* 2002;22:775-84.
6. Kim SJ, Shin SJ, Koo TY. Arch type pathologic suprapatellar plica. *Arthroscopy* 2001;17:536-8.
7. Sakakibara J. Arthroscopic study on lino's band (plica synovialis mediotatellaris). *J Jpn Orthop Assoc* 1976;17:279-81.
8. Dandy DJ. Anatomy of the medial suprapatellar plica and medial synovial shelf. *Arthroscopy* 1990;6:79-85.
9. Ieda Y, Kotani A, Ishii Y. Bilateral plica synovialis mediotatellaris syndrome: A case report. *J Orthop Sci* 2003;8:218-21.
10. Lee PY, Nixion A, Chandratreya A, Murray JM. Synovial plica syndrome of the knee: A commonly overlooked cause of anterior knee pain. *Surg J (N Y)* 2017;3:e9-16.
11. Yuan HF, Guo CA, Yan ZQ. Mediotatellar plica as a risk factor for knee osteoarthritis? *Chin Med J (Engl)* 2015;128:277-8.
12. Kinnard P, Levesque RY. The plica syndrome. A syndrome of controversy. *Clin Orthop Relat Res* 1984;183:141-3.
13. Kurosaka M, Yoshiya S, Yamada M, Hirohata K. Lateral synovial plica syndrome. A case report. *Am J Sports Med* 1992;20:92-4.
14. Dorchak JD, Barrack RL, Kneisl JS, Alexander AH. Arthroscopic treatment of symptomatic synovial plica of the knee. Long-term followup. *Am J Sports Med* 1991;19:503-7.
15. Zidorn T. Classification of the suprapatellar septum considering ontogenetic development. *Arthroscopy* 1992;8:459-64.
16. Cothran RL, McGuire PM, Helms CA, Major NM, Attarian DE. MR imaging of infrapatellar plica injury. *AJR Am J Roentgenol* 2003;180:1443-7.
17. Ogata S, Uthoff HK. The development of synovial plicae in human knee joints: An embryologic study. *Arthroscopy* 1990;6:315-21.
18. Barber FA. Fenestrated medial patella plica. *Arthroscopy* 1987;3:253-7.
19. Koshino T, Okamoto R. Resection of painful shelf (plica synovialis mediotatellaris) under arthroscopy. *Arthroscopy* 1985;1:136-41.
20. Muse GL, Grana WA, Hollingsworth S. Arthroscopic treatment of medial shelf syndrome. *Arthroscopy* 2010;26:391-2.
21. Munzinger U, Ruckstuhl J, Scherrer H, Gschwend N. Internal derangement of the knee joint due to pathologic synovial folds: The mediotatellar plica syndrome. *Clin Orthop Relat Res* 1981;155:59-64.