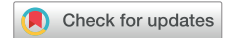

Pulmonary Alveolar Proteinosis and *Scedosporium aurantiacum* Lung Infection in a Kidney Transplant Recipient



Sneha Amin¹, Prianka Puri¹, Sharon C.A. Chen^{2,3}, Hema Mahajan^{3,4,5}, Levina Neill³ and Germaine Wong^{1,6,7}

¹Department of Renal and Transplantation Medicine, Westmead Hospital, Western Sydney Local Health District, New South Wales, Australia; ²Centre for Infectious Diseases and Microbiology Laboratory Services, Institute of Clinical Pathology and Medical Research, New South Wales Health Pathology, Westmead Hospital, Westmead, New South Wales, Australia; ³NSW Health Pathology, ICPMR-Tissue Pathology, Westmead Hospital, Westmead, New South Wales, Australia; ⁴School of Medicine, University of Sydney, New South Wales, Australia; ⁵School of Medicine, Western Sydney University, New South Wales, Australia; ⁶The School of Public Health Sydney Medical School, The University of Sydney, New South Wales, Australia; and ⁷Centre for Kidney Research, Children's Hospital, Westmead, New South Wales, Australia

Correspondence: Sneha Amin, Department of Renal and Transplantation Medicine, Westmead Hospital, Corner of Hawkesbury Road and Darcy Road, Westmead, NSW 2145, Australia. E-mail: sneha.amin@health.nsw.gov.au

Received 21 March 2021; revised 1 May 2021; accepted 3 May 2021; published online 15 May 2021

Kidney Int Rep (2021) 6, 2232–2236; <https://doi.org/10.1016/j.ekir.2021.05.002>

Crown Copyright © 2021, Published by Elsevier Inc. on behalf of the International Society of Nephrology. This is an open access article under the CC BY-NC-ND license (<http://creativecommons.org/licenses/by-nc-nd/4.0/>).

INTRODUCTION

Pulmonary alveolar proteinosis (PAP) is a rare condition characterized by accumulation of lung surfactant and debris within the alveoli.^{1–3} The loss of surfactant homeostasis and resultant impaired surfactant clearance by alveolar macrophages may lead to reduced gas exchange and the loss of barrier defense against infection.^{1–3} The overall prevalence of PAP is estimated to be seven cases per million.¹ There are three different categories of PAP: congenital, primary, and secondary. Congenital PAP is associated with gene mutations leading to abnormal surfactant production and metabolism. Primary PAP, which is due to disruption of granulocyte-macrophage colony stimulating factor (GM-CSF) signaling, is further categorized into hereditary and autoimmune PAP. Hereditary PAP is attributed to genetic mutations in colony stimulating factor 2 receptor subunit alpha or beta (CSF2RA or CSF2RB), which encode the GM-CSF receptor subunits.^{1,2,3} Autoimmune PAP, accounting for the majority (90%) of cases of primary PAP, is caused by autoantibodies against GM-CSF.^{2,3}

GM-CSF is the key cytokine in surfactant homeostasis, alveolar function, and immune response.³ GM-CSF activates macrophages, which then lead to clearance and catabolism of the surfactant by degrading the phospholipids and promoting reverse transport of cholesterol to the liver. Pathologically, if the cycle is impaired, there is a reduction in

cholesterol efflux by alveolar macrophages and impaired surfactant clearance from the alveolar surface.² The dysfunctional macrophages then accumulate lipid droplets containing esterified cholesterol and become defective in antimicrobial functions such as phagocytosis, chemotaxis, and pathogen-recognition receptor expression.²

Approximately 7.5% of all PAP cases are attributed to secondary PAP.³ In turn, secondary PAP is due to a reduction in number or function of alveolar macrophages, and is associated with hematological malignancies, immunosuppressed states, and chronic infection.^{1,2} The immunosuppression agents documented to cause PAP in solid organ transplant recipients include: sirolimus, everolimus, and cyclosporine. Although the underlying mechanism is unknown, a relationship has been established based on the resolution of symptoms with replacement with alternative immunosuppressive agents.⁴ There have been a few case reports of PAP associated with sirolimus and one with everolimus in kidney transplant recipients which recovered with conversion to tacrolimus,⁴ and one report with cyclosporine, which subsequently improved with conversion to azathioprine.⁵ Infections include those caused by *Nocardia* spp., atypical mycobacteria and fungi such as *Aspergillus* and *Cryptococcus* spp., especially in the setting of immunocompromise.² Here, we report a case of PAP

associated with *Scedosporium* infection in a kidney transplant recipient.

CASE REPORT

A 52-year-old female of Southeast Asian background presented with a month's history of exertional dyspnea, fatigue, and peripheral edema after recent travel. The patient's primary kidney disease was microscopic polyangiitis glomerulonephritis and she progressed to kidney failure in 1997. She received a deceased donor kidney transplant in 2007 which was complicated by early T-cell mediated rejection and treated with methylprednisolone and antithymocyte globulin. She was maintained on tacrolimus, prednisolone, and mycophenolate. Her other concurrent illnesses included chronic bronchiectasis which was diagnosed in 2005 after recurrent bacterial pneumonia often with *Pseudomonas aeruginosa*, *Pneumocystis jirovecii* pneumonia (previously known as pneumocystis carini pneumonia) in 2010, and invasive pulmonary aspergillosis in 2007.

On admission, the baseline blood tests showed progressive impairment of her kidney function and severe macrocytic anemia (Table 1). The chest x-ray showed multiple nodular opacities throughout the right lung and left upper lobe, alveolar opacities in the right mid-lower lung and consolidation left lung base (Figure 1). The high-resolution computer tomography indicated nonspecific diffuse ground glass changes with subpleural sparing, with ground glass changes being least apparent where the bronchiectasis was most marked; the diffuse bronchiectasis changes were most severe in the left lower lobe (Supplementary Figure S1). Extensive investigations were conducted, including diagnostic bronchoscopy and bronchoalveolar lavage (BAL)

of the right middle lobe. The BAL fluid was cultured for all common pathogens including for *Aspergillus* spp and pneumocystis (Table 2). On microscopy, the BAL fluid was suggestive of PAP, showing periodic acid-Schiff and oil red O stains positive for large foamy macrophages, confirmed on electron microscopy, which showed concentrically arranged lamellated myelin-like bodies indicative of surfactant found in the extracellular spaces (Figure 2). Serum anti-GM-CSF antibodies (via enzyme-linked immunosorbent assay binding recombinant human GM-CSF [Leukine]) were not detected. At the same time, BAL fluid and sputum cultures grew *P. aeruginosa*, and microscopy-examination showed cytomegalovirus-type inclusions; however, immunostaining was negative for cytomegalovirus. The patient was treated for 1 week with piperacillin-tazobactam 4.2 g twice daily, followed by nebulized tobramycin 80 mg twice per day and ciprofloxacin 400 mg oral daily for 7 days. However, the patient continued to experience exertional dyspnea despite antibiotic therapy.

Hematological causes of PAP were excluded based on findings of a normal bone marrow biopsy. She then proceeded to therapeutic right-lung lavage with 17 litres of 0.9% of warmed normal saline washed over 26 cycles. The whole lung lavage fluid grew *Scedosporium aurantiacum* with fungal forms seen in on microscopy; the fungus was identified by conventional mycological approaches and by sequencing of the fungal internal transcribed spacer region (Table 2). The patient was commenced on oral voriconazole 200 mg daily (renally adjusted dose) with trough drug levels within the therapeutic range (Table 1). The treatment regime was supported by *S. aurantiacum* susceptibility results (the

Table 1. Blood tests

Test	Baseline 6 months before presentation	Presentation day 0	Pre-lavage day 15	Post-lavage day 16	Discharge day 24	Re-admission day 50	Pre-terminal day 56
Na, mmol/l	140	135	141	145	136	143	141
K, mmol/l	4.6	4.9	4.9	4.0	5.0	6.3	4.5
HCO ₃ , mmol/l	24	26	21	19	16	17	14
Urea, mmol/l	15.3	20.4	29.7	22.1	23.8	38.9	16.8
Creatinine, μmol/l	244	309	352	295	337	324	259
Albumin, g/l	36	39	31	28	31	37	22
Bilirubin, μmol/l	12	13	5	8	7	<3	<3
ALT/AST, unit/l	40/33	25/26	25/24	22/13	22/19	22/46	29/35
INR		0.8	0.9			0.8	1.0
Hb, g/l	100	62	80	96	104	55	68
WBC, ×10 ⁹ /l	6.0	5.4	5.4	7.0	4.8	0.4	0.8
Platelets, ×10 ⁹ /l	291	344	223	164	219	195	32
MCV, fl	114	116	101	96	97	98	94
MCH, pg	38	41	34	33	33	32	32
Tacrolimus level, ng/ml	6.4	5.5	8.8	6.2	5.9	6.7	
Voriconazole level, ng/ml					5.4	7.6	>10

ALT, alanine aminotransferase; AST, aspartate aminotransferase; Hb, hemoglobin; HCO₃, bicarbonate; INR, international normalized ratio; K, potassium; MCH, mean corpuscular hemoglobin; MCV, mean corpuscular volume; Na, sodium; WBC, white blood cell.

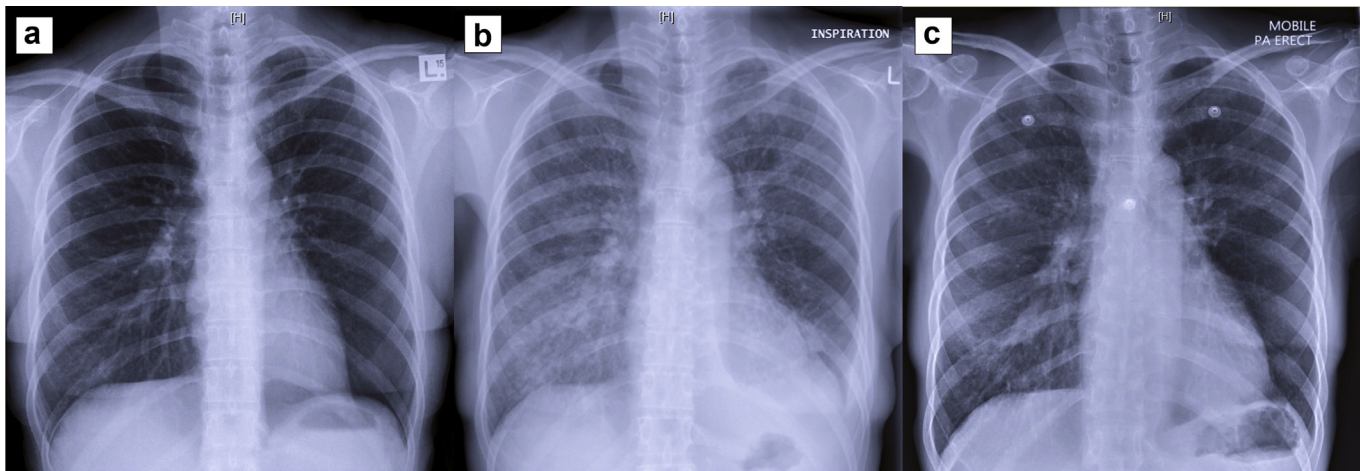


Figure 1. Three comparative chest x-rays at (a) baseline, (b) first presentation, (c) and 5 weeks after the lung lavage.

minimum inhibitory concentration of voriconazole was 1 mg/l, posaconazole >8 mg/l, and amphotericin B >8 mg/l). Five weeks after the lung lavage, she presented with febrile neutropenia and was found to have *Escherichia coli* bacteremia (Table 2). Despite antibiotic therapy and vasopressor support, she progressed to multiorgan failure and died 2 days later from *E. coli* sepsis.

DISCUSSION

This case highlights the diagnostic challenges and management dilemma of opportunistic infections in an immunosuppressed kidney recipient who also had chronic lung disease and the new finding of secondary PAP. Secondary PAP has been attributed to hematological malignancy, immunodeficiency states such as transplantation, HIV/AIDS, and chronic lung infections such as tuberculosis and *Pneumocystis jirovecii* pneumonia.¹ Although co-infection is not uncommon in secondary PAP, we here report a case of *Scedosporium* infection associated with PAP, adding to the list of fungal pathogens associated with PAP.

The exact cause of secondary PAP is unclear, but patients with secondary PAP often have relative deficiency of GM-CSF, leading to macrophage dysfunction and impaired surfactant clearance. In renal transplant recipients, neither tacrolimus nor mycophenolate has been associated with PAP. Moreover, chronic infection has been noted to be associated with PAP. In a small retrospective study, the infection preceded the diagnosis of PAP in 40%; conversely, the infection was diagnosed on autopsy in 28% of patients.⁶

The presentation of PAP is often nonspecific, with exertional dyspnea being the most common complaint⁶ along with associated vague respiratory complaints.¹ Computer tomography may reveal intralobular thickening and diffuse ground-glass opacities, often referred

to as “crazy paving,” which is suggestive but not diagnostic of PAP.^{1–3} If PAP is suspected, bronchoscopy and BAL fluid examination is required for diagnosis.^{1–3} BAL fluid is often milky and opaque; cytological examination of BAL fluid shows foamy macrophages which contain amorphous material that is shown using periodic acid-Schiff staining.² Electron microscopy shows concentric lamellar bodies.² Transbronchial biopsy specimens are no longer the gold standard of diagnosis, and they are not recommended because of the substantial false-negative rate.^{1,2} Treatment for PAP is directed at symptom control and management of the underlying etiology.¹ The current standard of care for PAP is whole lung lavage to improve symptoms for patients by actively removing accumulated surfactant debris, with symptomatic improvement in 95% of cases.³

Infection is a common complication of PAP (occurring in 13% of cases) which may be present from disease onset; it accounts for 18% to 20% of deaths related to PAP.¹ The most common infections are those due to *Nocardia*, *Mycobacteria*, and fungi⁶; however, infections due to *Aspergillus*, *Cryptococcus* and *Histoplasma* are well described.⁶ Ubiquitous in the environment, *Scedosporium* spp typically enter through the upper respiratory tract, and from aspiration of contaminant water.⁷ If the infections are not cleared by alveolar macrophages, they will colonize and infect the lower respiratory tract.⁷ There have been multiple case reports of *Scedosporiosis* in solid organ transplant recipients, and the majority of the infections are *S.apiospermum*.⁹ *S. aurantiacum* has been isolated in patients with solid organ donors who died of near-drowning events.⁹ The *S. aurantiacum* infections may be cutaneous, respiratory, in the central nervous system, or disseminated.⁹ *S. aurantiacum* is inherently resistant to amphotericin; therefore, use of voriconazole represents first-line treatment.⁷

Table 2. Infection testing

Specimen	Test	Results
First admission		
COVID-19 (SARS-CoV-2 RNA)	PCR — nasopharyngeal swab and RML bronchoalveolar lavage	Negative
Other viruses: viral — respiratory syncytial virus, influenza, parainfluenza, rhinovirus, enterovirus, metapneumovirus, adenovirus	PCR — nasopharyngeal swab, RML, and RL bronchoalveolar lavage	Negative
Cryptococcal neoformans antigen	Lateral flow assay — serum	Negative
Bacterial culture	Culture — RML bronchoalveolar lavage	<i>Pseudomonas aeruginosa</i>
Fungi	Culture — RML bronchoalveolar lavage	Negative
<i>Mycobacteria</i>	Culture and microscopy — RML and RL bronchoalveolar lavage	Negative
<i>Legionella</i>	Culture — RML and RL bronchoalveolar lavage	Negative
<i>Pneumocystis</i>	PCR — RML bronchoalveolar lavage	Negative
Pan-fungal	PCR — RML bronchoalveolar lavage	Negative
Cytomegalovirus	PCR — RML and RL bronchoalveolar lavage	Negative
Aspergillosis	PCR — RML bronchoalveolar lavage	Negative
<i>Pneumocystis</i>	PCR — RML bronchoalveolar lavage	Negative
Pan-fungal	PCR — RML bronchoalveolar lavage	Negative
<i>Legionella pneumophila</i> sag1 Ag	Rapid antigen test — urine	Negative
<i>Streptococcus pneumoniae</i> antigens	Rapid antigen test — urine	Negative
Melioidosis	IgG serum	Negative
Bacterial and fungal	Culture — RL bronchoalveolar lavage	<i>Scedosporium aurantiacum</i>
Representation		
Blood	Culture — serum	<i>Escherichia coli</i>
Fungal culture	Culture — nasobronchial bronchoalveolar lavage	Negative
Bacterial culture	Culture — nasobronchial bronchoalveolar lavage	Negative
<i>Chlamydia pneumoniae</i>	PCR — nasobronchial bronchoalveolar lavage	Negative
Cytomegalovirus	PCR — nasobronchial bronchoalveolar lavage	Negative
<i>Pneumocystis</i>	PCR — nasobronchial bronchoalveolar lavage	Negative

COVID-19, coronavirus disease 2019; IgG, immunoglobulin G; PCR, polymerase chain reaction; RL, right lung, whole lung lavage; RML, right middle lobe, bronchoalveolar lavage; SARS-CoV-2, severe acute respiratory syndrome coronavirus 2.

Co-infection and co-colonization of *scedosporium* species and *P. aeruginosa* has been well documented, but the presence of *S. aurantiacum* was not detected until later in the patient's illness. This may be explained by sampling bias, or alternatively, *in vitro* studies have reported a mutually antagonistic relationship between *S. aurantiacum* and *P. aeruginosa*.⁸ A direct antifungal activity of *pseudomonas aeruginosa* on solid media has been reported in an experimental study.⁸ Furthermore, the treatment of the *P. aeruginosa* infection occurred before whole lung lavage and did

not improve our patient's symptoms. Thus, it was speculated that the infection was more likely concurrent than causative of the PAP.

The overall survival of patients with secondary PAP is poor, with a median survival of less than 20 months and a 2-year survival rate of 40%.³ Most patients with secondary PAP died from complications of their underlying disease such as malignancy and overwhelming sepsis from the chronic infections.³ In this case, our patient suffered from multiple sources of sepsis including opportunistic and co-existing

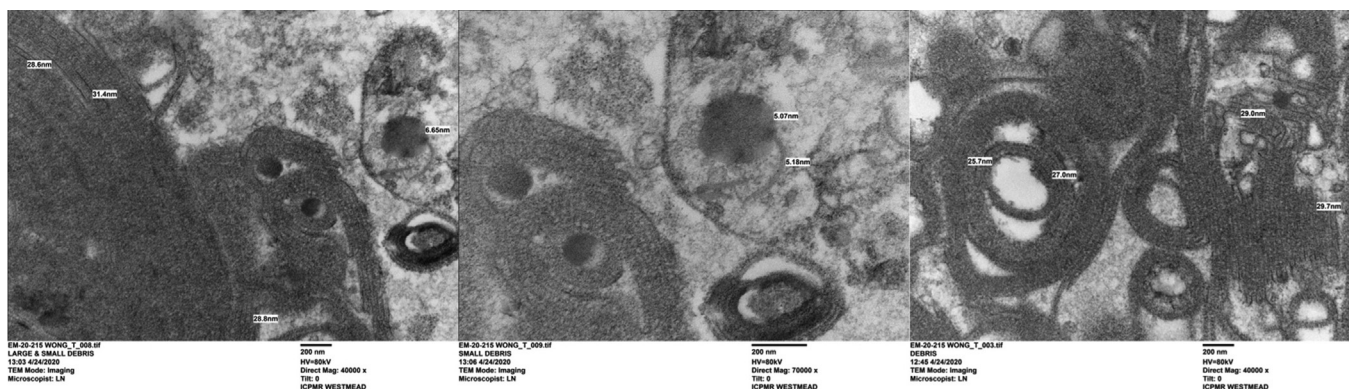


Figure 2. Electron microscopy. Concentrically arranged lamellar structure smooth and regularly spaced, sometimes irregular and wavy. The center of the lamellar bodies is an amorphous structure.

bacterial infections. The prognosis of *scedosporium* infection is generally poor, with an expected overall survival of less than 50% in solid organ transplant recipients.⁹

Further research into the underlying mechanism of immunosuppressive agent-related PAP is required to deepen our understanding of PAP and improve treatment options. Moreover, *in vitro* studies have shown that GM-CSF may augment the antifungal function of macrophages against fungal infections,⁹ possibly indicating a shared underlying pathophysiology of PAP and fungal infections.

CONCLUSION

We report a rare case of PAP and *S. aurantiacum* infection in a kidney transplant recipient with longstanding bronchiectasis. The differential diagnoses of transplant recipients with chronic lung disease require extensive and thorough investigations. Although it is a rare occurrence, PAP should be considered in immunosuppressed patients with progressive dyspnea and that shows a crazy paving pattern on computer tomography. Prompt investigations with definitive diagnostic procedures including BAL and biopsy should be considered in patients with abnormal alveolar infiltrates and unclear etiology. Health care professionals should also have a high index of suspicion of co-infection with opportunistic pathogens particularly fungal in immunosuppressed individuals even in the absence of fever, respiratory signs or purulent sputum, particularly if they are neutropenic. Timely diagnoses and early interventions with appropriate antimicrobials and whole lung lavage are crucial in this setting (Table 3).

PATIENT CONSENT

Verbal informed consent was obtained from the patient for publication of this case report and any accompanying images. The patient understood that their name and initials would not be published.

ACKNOWLEDGMENTS

Electron microscopy techniques were performed at the Westmead Scientific Platforms, which are supported by the Westmead Research Hub, the Cancer Institute New South Wales, the National Health and Medical Research Council, and the Ian Potter Foundation.

SUPPLEMENTAL MATERIAL

Supplementary File (JPEG)

Figure S1. Three high-resolution computed tomography scan taken (A) at presentation, (B) 3 weeks post-lavage, and (C) 7 weeks post lung lavage.

Table 3. Teaching points

PAP occurs due to the accumulation of surfactant within alveoli, compromising ventilation and leading to impairment of respiratory function. The pathophysiology includes a disruption of GM-CSF signaling and reduction of alveoli macrophage mediated clearance of surfactant.

Congenital PAP occurs due to disorders of surfactant production and metabolism. Primary PAP includes disorders of GM-CSF function, from either hereditary GM-CSF receptor abnormality or auto-antibodies against GM-CSF. Secondary PAP is associated with immune deficient states and occurs due to a reduction in function or number of alveolar macrophages.

BAL is required for the diagnosis of PAP. The BAL fluid typically has a "milky" appearance, and microscopic examination reveals acellular globules that appear basophilic with PAS staining and alveolar macrophages that appear foamy and red with oil-red-O staining. Electron microscopy examination of BAL fluid may show pseudo myelin structures consisting of concentrically laminated phospholipid structures (lamellar bodies) centered on dense bodies.

Whole lung lavage is the current gold standard of treatment in PAP.

Patients with bronchiectasis have chronic bronchial infection, with a complex microbiome of bacteria, commonly including *Pseudomonas*, and fungi (e.g., *Aspergillus* spp).

Scedosporium infection should be suspected in patients with chronic pulmonary conditions, solid organ transplant or hematological disease. The definitive diagnosis is based on culture of pathogen from infective tissue samples or body fluids, and voriconazole is first-line treatment.

Clinicians should consider rare pulmonary disease in patients who are immunosuppressed and have chronic lung disease, with consideration of extended microbiological investigation and histology.

Clinicians should have a high level of suspicion for rare diagnoses in immunocompromised hosts. The diagnostic process in patients who are immunocompromised is complex and collaborative activities including intuition, analytical process coupled with evidence and lateral thinking are needed.

BAL, bronchoalveolar lavage; GM-CSF, granulocyte macrophage colony stimulating factor; PAP, pulmonary alveolar proteinosis; PAS, periodic acid-Schiff.

REFERENCES

1. Salvaterra E, Campo I. Pulmonary alveolar proteinosis: from classification to therapy. *Breathe (Sheff)*. 2020;16:200018.
2. Jouneau S, Ménard C, Lederlin M. Pulmonary alveolar proteinosis. *Respirology*. 2020;25:816–826.
3. Trapnell BC, Nakata K, Bonella F, et al. Pulmonary alveolar proteinosis. *Nat Rev Dis Primers*. 2019;5:16.
4. Hinojosa-González D, Dávila-González D, Salgado-Garza G, Flores-Villalba E. Reversible sirolimus-induced pulmonary alveolar proteinosis in a renal transplant patient. *Lung India*. 2020;37:252–256.
5. Hasan A, Ram R, Swamy T. Pulmonary alveolar proteinosis due to mycophenolate and cyclosporine combination therapy in a renal transplant recipient. *Lung India*. 2014;31:282.
6. Punatar AD, Kusne S, Blair JE, Seville MT, Vikram HR. Opportunistic infections in patients with pulmonary alveolar proteinosis. *J Infect*. 2012;65:173–179.
7. Ramirez-Garcia A, Pellon A, Rementeria A, et al. *Scedosporium* and *Lomentospora*: an updated overview of underrated opportunists. *Med Mycol*. 2018;56(suppl 1):S102–S125.
8. Chen SC-A, Patel S, Meyer W, et al. *Pseudomonas aeruginosa* inhibits the growth of *Scedosporium* and *Lomentospora* in vitro. *Mycopathologia*. 2018;183:251–261.
9. Leek R, Aldag E, Nadeem I, Gunabushanam V, et al. *Scedosporiosis* in a combined kidney and liver transplant recipient: a case report of possible transmission from a near-drowning donor. *Case Rep Transplant*. 2016;2016:1879529.