

## STANDARD ARTICLE

# Use of video capsule endoscopy to identify gastrointestinal lesions in dogs with microcytosis or gastrointestinal hemorrhage

Kasey Mabry<sup>1</sup> | Tracy Hill<sup>1</sup>  | Stanley L. Marks<sup>2</sup>  | Brian T. Hardy<sup>2</sup>

<sup>1</sup>Department of Small Animal Medicine and Surgery, College of Veterinary Medicine, The University of Georgia, Athens, Georgia

<sup>2</sup>Department of Medicine and Epidemiology, School of Veterinary Medicine, University of California-Davis, Davis, California

## Correspondence

Tracy Hill, Department of Small Animal Medicine and Surgery, College of Veterinary Medicine, University of Georgia, 2200 College Station Road, Athens, GA 30602.  
 Email: tracy.hill@uga.edu

## Abstract

**Background:** Video capsule endoscopy (VCE) is a noninvasive imaging modality that can identify mucosal lesions not detected with traditional endoscopy or abdominal sonography. In people, VCE is used in diagnostic and management protocols of various gastrointestinal (GI) disorders, particularly in GI bleeding of obscure origin or unexplained iron deficiency anemia (IDA).

**Objective:** To evaluate the utility of VCE in the identification of mucosal lesions in dogs with evidence of GI hemorrhage.

**Animals:** Sixteen client-owned dogs that underwent VCE.

**Methods:** Retrospective case-control study. Medical records were reviewed to include dogs with microcytosis, low normal mean corpuscular volume, or clinical GI bleeding that received VCE.

**Results:** Median age of dogs was 8.7 years (range, 8 months to 15 years) with a median weight of 21.7 kg (range, 6.9–62.5 kg). Abdominal ultrasound (16), abdominal radiography (4), and abdominal CT (1) did not identify a cause for GI blood loss. Gastric mucosal lesions were identified by VCE in 15 of 16 dogs and small intestinal lesions in 12 of 14 dogs, with 2 capsules remaining in the stomach. Endoscopy was performed in 2 dogs before VCE; 1 dog had additional small intestinal lesions identified through the use of VCE.

**Conclusions and Clinical Importance:** Video capsule endoscopy is a minimally invasive diagnostic tool that can identify GI lesions in dogs presenting with microcytosis with or without GI hemorrhage when ultrasonography is inconclusive; however, the majority of lesions identified would have been apparent with conventional endoscopy.

## KEYWORDS

anemia, canine, gastrointestinal, hemorrhage, microcytosis, video capsule endoscopy

**Abbreviations:** CT, computerized tomography; GI, gastrointestinal; GIT, gastrointestinal tract; IDA, iron deficiency anemia; MCV, mean corpuscular volume; NSAID, nonsteroidal anti-inflammatory drug; OGIB, obscure GI bleeding; PPI, proton pump inhibitor; RI, reference interval; TLI, trypsinogen-like immunoreactivity; TT, transit time; VCE, video capsule endoscopy.

This is an open access article under the terms of the Creative Commons Attribution-NonCommercial License, which permits use, distribution and reproduction in any medium, provided the original work is properly cited and is not used for commercial purposes.

© 2019 The Authors. *Journal of Veterinary Internal Medicine* published by Wiley Periodicals, Inc. on behalf of the American College of Veterinary Internal Medicine.

## 1 | INTRODUCTION

Video capsule endoscopy (VCE) is a minimally invasive imaging modality used in human and veterinary medicine in the diagnosis of various upper and lower gastrointestinal (GI) disorders.<sup>1</sup> In people, VCE remains a useful modality in the diagnosis of both obscure GI bleeding (OGIB) and unexplained iron deficiency anemia (IDA) when upper and lower GI conventional endoscopy have failed to identify a cause of GI bleeding.<sup>2-5</sup> Prognosis of small bowel disease, particularly those resulting in OGIB, is enhanced by VCE more so than by conventional diagnostic modalities such as radiology, conventional endoscopy, ultrasound, or computerized tomography (CT) imaging, with double-balloon enteroscopy having equal sensitivity in identification of such lesions.<sup>6-13</sup> In veterinary medicine, VCE has been used to evaluate GI transit time (TT), to evaluate anthelmintic efficacy, and to identify abnormal mucosal lesions in the GI tract of dogs with GI hemorrhage.<sup>14-18</sup> More specifically, VCE identified mucosal bleeding, erosions, a gastric mass, intestinal parasites, and healing duodenal ulcers in the stomach and small intestines of dogs with GI hemorrhage. These lesions were considered a significant source of hemorrhage in 4 of 7 dogs with active bleeding, although the importance of gastric erosions to blood loss was unclear.<sup>14</sup>

Microcytosis associated with GI bleeding is a direct consequence of iron deficiency, with or without evidence of hyposideremia,<sup>19</sup> anemia, or other pathophysiological conditions, such as chronic liver disease (portosystemic shunts), lead poisoning, or copper deficiency.<sup>20-23</sup> Microcytosis is well characterized in specific canine breeds, including the Akita and Shiba Inu.<sup>23</sup> Microcytosis due to iron deficiency in a mature dog or cat is most commonly a result of chronic blood loss due to chronic hematuria, chronic GI bleeding, portal vein hypertension, or severe flea infestation.<sup>24-26</sup>

The most common causes of chronic GI bleeding are vascular or inflammatory lesions and tumors, which might be difficult to diagnose, particularly in the mid- to distal small intestines, with conventional diagnostic modalities such as ultrasonography, CT, and bidirectional endoscopy.<sup>6-8</sup> In people with OGIB, VCE is superior to push enteroscopy and small bowel barium radiography in identifying lesions in the small bowel. VCE identified 63% of vascular and inflammatory small bowel lesions as compared to 28% via push enteroscopy. Video capsule endoscopy detected 42% of small bowel lesions compared to 6% with small bowel barium radiography.<sup>6</sup> In dogs, the sensitivity and specificity for detection of small bowel lesions was 64% and 92% for VCE and 37% and 97% for push enteroscopy, respectively.<sup>9</sup>

As VCE has the ability to examine the entire GI tract, this could provide a useful imaging modality to explore the most common causes of microcytosis or GI hemorrhage in dogs when other diagnostic tests have failed to identify such lesions. This study evaluated the utility of VCE as a noninvasive diagnostic tool for the identification of GI lesions in dogs with microcytosis or low-normal mean corpuscular volume (MCV) or clinical GI bleeding.

## 2 | MATERIALS AND METHODS

### 2.1 | Criteria for selection of cases

Medical records were reviewed from Infiniti Medical, LLC, in Redwood City, California, and The University of California, Davis, Veterinary Medical Teaching Hospital, to identify dogs with GI hemorrhage either evidenced by microcytosis (MCV < 63.9 fL), low normal MCV (64.0-68.0 fL), or clinical GI hemorrhage in the form of hematemesis, hematochezia, or melena that received VCE (ALICAM, Infiniti Medical LLC, Redwood City, California) between June 2015 and March 2018. Dogs receiving corticosteroids (ie, prednisone, prednisolone, and dexamethasone), nonsteroidal anti-inflammatory drugs (NSAIDs), gastroprotectants (ie, proton pump inhibitors [PPIs], histamine-2 receptor antagonists, sucralfate, and anti-nausea medication), antibiotics, prokinetic medications, or a combination of these medications as empirical treatment for their GI disease were eligible for inclusion. Dogs were excluded if there was biochemical or histologically confirmed evidence of hepatic disease. Data recorded from the medical record included signalment, history (including diet and medical therapy), clinical signs, clinicopathologic test results (ie, hematologic, biochemical, GI panel (ie, cobalamin, folate, trypsinogen-like immunoreactivity [TLI]), fecal centrifugation flotation, additional imaging (ie, ultrasound, radiography, CT), video endoscopic findings, VCE findings, and details of capsule endoscopy (ie, total images, esophageal TT, gastric TT, and small intestinal TT if applicable). Ultrasounds and radiographs performed were interpreted individually by a board-certified veterinary radiologist, an internal medicine veterinary specialist, a general practitioner, or unknown. Computerized tomography was interpreted by a board-certified veterinary radiologist.

Images from the video capsule were downloaded and analyzed by a board-certified veterinary internist, employed and trained by Infiniti Medical, LLC. Images of normal segments and any abnormal lesions within the GI system were saved and reported on a document after careful review and provided to the primary veterinarian and owner of the dog tested. Recommendations for treatment were additionally provided on the document based on the dog's history and clinical presentation.

## 3 | RESULTS

Medical records of 16 client-owned dogs that underwent VCE for further investigation of microcytosis, a low-normal MCV, or evidence of GI hemorrhage were retrospectively evaluated. The median age of dogs was 8.7 years (range, 8 months to 15 years) with a median body weight of 21.7 kg (range, 6.9-62.5 kg). A mix of sex (8 female spayed, 1 female intact, 6 male castrated, 1 unknown) was included, and the following breeds were represented: mixed-breed dogs (4), Boston Terrier (2), Golden Retriever (1), Samoyed (1), Great Pyrenees (1), Cocker Spaniel (1), Schipperke (1), Whippet (1), German Shepherd (1), Gordon Setter (1), Shetland Sheepdog (1), and Bernese Mountain dog (1). Data for the 16 cases are summarized in Table S1.

Abnormal clinical signs were reported in 15 of 16 dogs (1 unknown) consisting of diarrhea (7), weight loss (7), vomiting (6), hyporexia (5), melena (5), hematochezia (2), pica (1), hematemesis (1), and regurgitation (1).

Microcytosis was observed in 14 of 16 dogs with a median MCV of 53.6 fL (range, 40.1-63.2 fL; reference interval [RI], 64-76 fL) with the remaining 2 dogs having a low-normal MCV of 66.4 and 67.6 fL, respectively. Anemia was documented in 11 of 16 dogs, with a median hematocrit of 26.1% (range, 11.9%-36.0%; RI, 41%-58%). The anemia of 2 dogs was further characterized as nonregenerative (reticulocyte count 31 000 and 38 300/ $\mu$ L, respectively), 7 dogs characterized as regenerative (range 90 000-176 000/ $\mu$ L; RI, >80 000/ $\mu$ L), and 7 dogs did not have a reticulocyte count reported. Hypoalbuminemia was present in 5 dogs, with a median albumin concentration of 2.6 g/dL (range, 1.6-3.1 g/dL; RI, 3.2-4.1 g/dL). Four dogs had an increased blood urea nitrogen (31-155 mg/dL; RI 9-26 mg/dL) concentration. A GI panel (TLI, cobalamin [B12], folate) was performed in 7 of 16 dogs with the following results: normal (3), hypcobalaminemia only (2), hypcobalaminemia and low TLI (1), and increased folate only (1). Endoparasitic testing via fecal centrifugation flotation was performed in 3 of 16 dogs and was negative in all dogs tested.

All 16 dogs were evaluated via abdominal ultrasound before assessment with VCE, and the procedures were interpreted individually by a board-certified radiologist ( $n = 12$  cases), a board-certified internal medicine specialist ( $n = 1$  case), and 1 veterinarian of unknown specialty status ( $n = 1$  case). Four dogs had an abnormal gastrointestinal tract (GIT) on ultrasound, which included thickened gastric mucosa or submucosa (3 dogs), hyperechoic GI mucosa (3 dogs). Two dogs had both thickened and hyperechoic mucosa. The remainder of the dogs had an "apparently normal" GIT with additional findings as gallbladder mucosal hyperplasia (1), echogenic biliary debris (3), possible mild cystitis (1), mildly hypoechoic pancreas (1), and mass effect in the right adrenal gland (1). Four dogs were evaluated via abdominal radiography before their VCE study, in which reports were interpreted individually by a board-certified radiologist ( $n = 1$  case), a board-certified internal medicine specialist ( $n = 1$  case), and 2 veterinarians of unknown specialty status ( $n = 2$  cases). One dog was additionally evaluated with thoracic and abdominal CT and interpreted by a board-certified radiologist. No remarkable findings were observed with radiography or CT in any of those dogs evaluated.

Treatment before assessment with VCE consisted of prednisone (median dosage 1.6 mg/kg/day [range, 0.35-2.2 mg/kg/day]) (5), antibiotics (3), gastroprotectants (10), maropitant (1), and metoclopramide (1). No dogs enrolled in the study were administered NSAIDs. Antibiotics consisted of either PO metronidazole (2) or PO amoxicillin (1). Orally administered gastroprotectants were used in 10 of 16 dogs, with 3 dogs receiving omeprazole only and the remaining 7 dogs receiving a combination of PO gastroprotectants, including omeprazole with a dosage ranging from 0.64-2 mg/kg/day (9), sucralfate (6), ranitidine at 2.7 mg/kg (1), and famotidine at 1 mg/kg/day (1). Combination treatment with PPIs and prednisone was instituted in 4 of 16 dogs.

The capsule endoscope traversed the entire length of the GI tract in 14 of 16 dogs, with gastric retention occurring in 2 dogs of >9.6 and

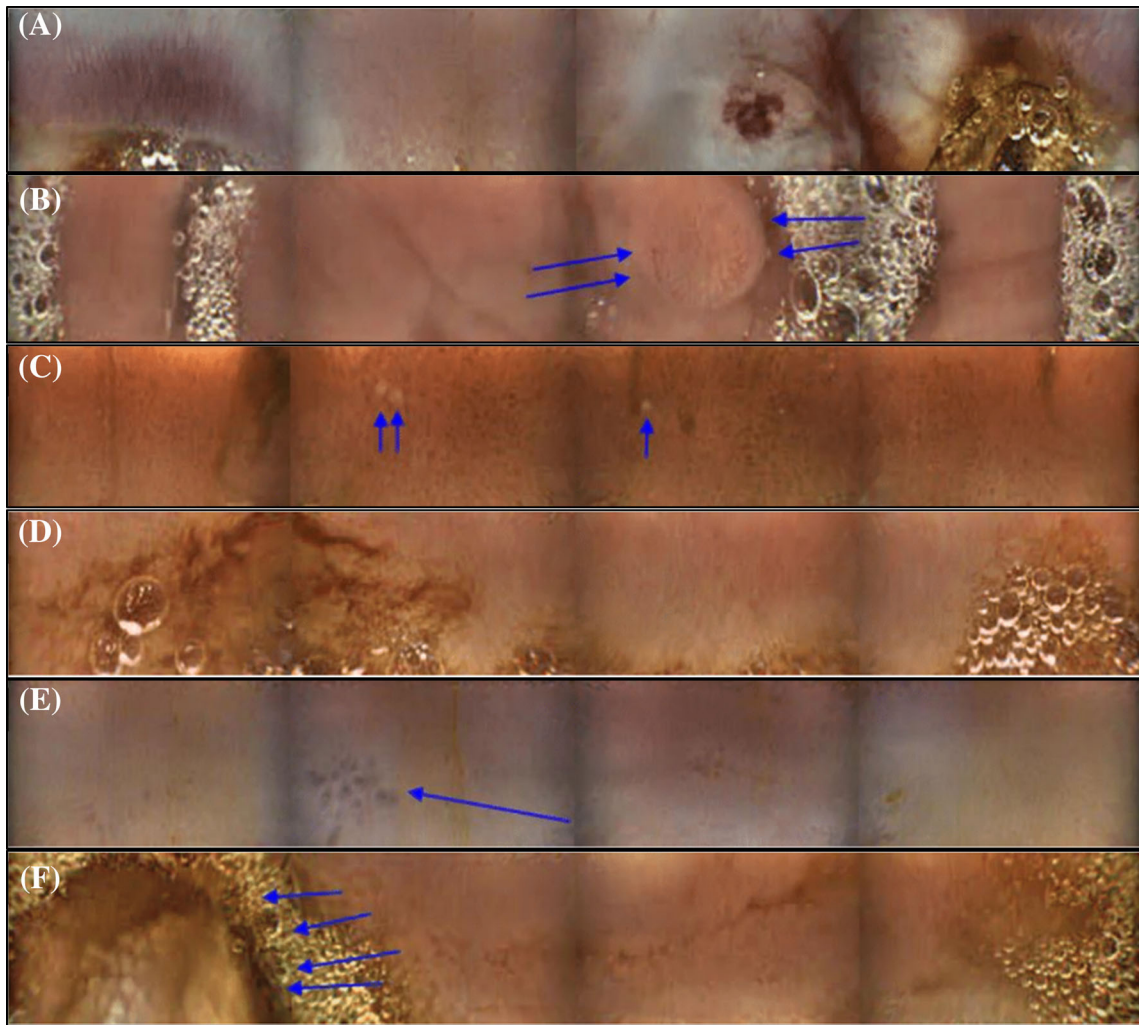
14.5 hours, respectively. The retained capsules were removed from the stomach shortly thereafter by induced emesis with no complications after emesis. For dogs in which the entire GI tract was traversed, the mean imaging time and the number of images of VCE were 14.9 hours (SD, 4.3-18.0) and 19 349 images (SD, 6055-34 841), respectively. The mean esophageal TT, gastric TT, and small intestinal TT of the capsule were 11.8 seconds (SD, 4-14), 152.1 minutes (SD, 3.9-451.30), and 129.9 minutes (SD, 59-228), respectively. The shortest gastric TT documented was 3.9 minutes in a dog with a solitary ulcer, which might have caused additional lesions to have been missed.

Multiple gastric abnormalities were detected via VCE in 15 of 16 dogs, which included erosions or ulcerations (15), areas of irregular mucosa and hyperemia (5), a polypoid lesion (2, Figure 1B), and a possible gastric mass (1). The small intestine was abnormal in 12 of 14 dogs in which the capsule traversed the entire GI tract. Lesions were present in the duodenum and proximal jejunum (proximal 1/3 SI) in 8 of 12 dogs, including ulcers or erosions (5), irregular mucosa (4), and a duodenal mass (1; Figure 1F). Lesions were present in the mid-jejunum in 6 of 12 (50%) dogs, representing ulcers or erosions (3, Figure 1D), irregular mucosa (3), active hemorrhage from an ulcer (1), multiple mass-like effects (1, Figure 1A), and dilated lacteals (2, Figure 1C). The distal jejunum and ileum revealed irregular mucosa (3) with 1 ulcer identified (Figure 1E). Irregular colonic mucosa was identified in 1 dog.

The most severe lesions were visualized in the stomach and proximal SI in 10 of 14 dogs, which would have been identifiable with conventional video endoscopy. The remaining 4 dogs had the most severe lesions identified in the mid- to distal jejunum, and abnormal findings included: (1) normal stomach with irregular SI mucosa of varying severity throughout its length; (2) small multifocal gastric erosions and irregular mucosa in the stomach and duodenum with multiple bleeding ulcerations and a mass effect in the mid-jejunum; (3) suspect focal gastric ulcer with marked mucosal irregularity and erosions throughout the SI; and (4) numerous small gastric erosions with larger small intestinal ulcerations throughout the SI.

Two dogs underwent conventional video endoscopy before their VCE study. In both dogs, histopathology demonstrated lymphoplasmacytic enteritis. Video capsule endoscopy was used in these 2 dogs to monitor response to treatment, which showed stable to progressive lesions including additional erosions.

Of the 10 dogs receiving PPIs before their VCE study, 8 dogs had evidence of gastric lesions consistent with erythema (1), pinpoint ulcers or erosions (7), irregular mucosa (1), a polypoid lesion, and a possible mass (1). The findings in the remaining 6 dogs that did not receive PPIs ranged in severity and included ulcers or erosions (6) with active bleeding (1), a gastric polyp (1), and irregular mucosa (1). Of the 5 dogs receiving prednisone, 4 had evidence of gastric lesions consisting of erosions or ulcerations, mucosal irregularity, or a gastric polyp. One dog had normal stomach, and another dog had the capsule remain in the stomach for the duration of the study. Mild (2) to marked (1) mucosal irregularity was visualized in 3 of 4 dogs with passing capsules, along with rare dilated lacteals (1/4), few erosions (1/4), and



**FIGURE 1** Video capsule endoscopy captured images of important lesions throughout the stomach and small intestines. A, Jejunal lesion with ulcerated mass effect. B, Polypoid lesion with small erosion in the stomach. C, Dilated lacteals in the jejunum. D, Fissure-like area in mid-jejunum. E, Small intestinal ulceration. F, Duodenal mass

a jejunal mass (1/4). An irregular colon was visualized in 1 dog with prednisone administration.

#### 4 | DISCUSSION

Gastrointestinal lesions were identified by VCE in all 16 dogs with unexplained microcytosis for which causative abnormalities were not detected with other diagnostic imaging modalities. Two of 14 dogs had the most severe lesions identified in the mid- to distal jejunum beyond the visualization of conventional endoscopy, consisting of diffuse irregular mucosa, large ulcerations with or without bleeding, and a mid-jejunal mass effect. Lesions were present within the stomach and proximal intestines in 15 of 16 dogs that could be visualized with conventional endoscopy, and capsule retention occurred in 2 dogs.

The lesions identified were similar to those detected in dogs with GI hemorrhage<sup>14</sup> that utilized a forward-facing capsule endoscope system. Our study used a capsule endoscope with 4 lateral-facing cameras, producing a 360° panoramic image. In humans, studies have

been performed comparing the diagnostic yield and complication rates between lateral- and axial-viewing capsules. Lateral-viewing capsules have been shown to document more lesions and have a similar number of adverse effects.<sup>27,28</sup> This comparison has not yet been performed in animals.

The present study demonstrated marked variation in esophageal TT, gastric TT, and small intestinal TT, comparable to a recent study revealing no significant relationship between gastroenteropathy and GI motility in dogs that underwent CE,<sup>14</sup> as well as a study comparing GI motility in healthy dogs.<sup>29</sup> The capsule traversed the length of the GI tract in all but 2 dogs, for which the capsule remained in the stomach for the duration of the study. The abnormal findings in these 2 dogs included severe gastric erosions and numerous pinpoint to large gastric ulcerations, respectively. Capsule retention has been previously documented in the dog, and a similar VCE study in dogs documented capsule retention in 3 of 8 dogs (37.5%) resulting in an incomplete study.<sup>14</sup> The incidence of capsule retention appears higher in dogs compared to people, in which the overall pooled retention rate

was 1.4% in patients with OGIB, Crohn's disease, and neoplastic diseases.<sup>30</sup>

There were several limitations to the present descriptive study, including the retrospective design. The duration of medical therapy before or after VCE was not reported in all dogs. VCE performed 2- and 9-months after conventional endoscopy in 2 dogs demonstrated static to progressive lesions after medical therapy. VCE could be used as an initial screening modality for cases with unexplainable microcytosis or GI hemorrhage, as well as to monitor for treatment response after a diagnosis has been made with conventional video endoscopy and biopsies. It is unknown whether the VCE findings altered case management for the remainder of the dogs.

The aim of this study was to evaluate the utility of VCE in detecting GI lesions in dogs with evidence of GI hemorrhage, not to determine causality of the lesions. Prior or concurrent administration of corticosteroids might have precipitated GI hemorrhage in some dogs. VCE could be used in future studies to identify risk factors for the development of hemorrhagic mucosal lesions with various pharmacologic agents.

One board-specialized veterinary internist (B.H.) trained by Infiniti Medical, LLC, for assessment of VCE analyzed and interpreted the study images. The clinical history was included in the analysis, which might have impacted interpretation of study images by the trained internist. The interobserver variability with VCE has not been established, and that was not the aim of the current study. Additionally, the sensitivity of VCE for the detection of hemorrhagic mucosal lesions in dogs has not been established. As such, it is possible that lesions within the GI tract could be under- or over-interpreted; however, all dogs with microcytosis or GI hemorrhage did have lesions detected with VCE.

In people with suspected small bowel hemorrhage manifested as melena or severe IDA, VCE detected lesions in the small bowel and non-small bowel (ie, stomach, colon, or both) after negative bidirectional endoscopy.<sup>4,31</sup> In dogs, VCE revealed a source of hemorrhage within the GIT of 4 of 7 dogs, although the relevance of pinpoint gastric mucosal erosions to blood loss was unclear.<sup>14</sup> In the present study, the degree of microcytosis does not appear to correlate with the degree of anemia or clinical signs. For example, the 6-year-old NM German Shepherd dog with the most severe anemia of 11.9% and a normal MCV 67.6 fL had marked evidence of gastric erosions with gastric capsule retention throughout the duration of the study, which could explain at least a part of this dog's clinical signs involving hematemesis, hyporexia, and diarrhea with melena and hematochezia, among others. Contrastingly, the 8-year-old SF Whippet with a severe anemia of 15% and severe microcytosis (MCV 47 fL) with a (resolved) history of melena had a focal gastric erosion visualized on VCE, as well as marked SIT mucosal irregularity and pinpoint erosions throughout the SIT. As VCE's ability to detect 3D-captured images can only detect lesions on the mucosal surface, it is therefore unable to identify the depth to which a lesion is present and might be poorly correlated to the severity of an identified lesion.

No adverse effects or complications of the present VCE study were noted, with the exception of 2 dogs that had gastric capsule retention. High-quality images were obtained in the stomach, small

intestines, and proximal portion of the colon, detailing abnormal findings as erosions or ulcerations with or without hemorrhage, irregular mucosa, polypoid lesions, a gastric mass, a duodenal mass, and a jejunal mass. Video capsule endoscopy shows promise as a diagnostic modality for the assessment of GI lesions in dogs with microcytosis with or without OGIB with otherwise normal diagnostic imaging. Video capsule endoscopy represents a complementary tool to conventional endoscopy, particularly in dogs with small intestinal lesions that are beyond the reach of conventional endoscopy. Conventional endoscopy has the additional benefit of sample collection for histopathology, and, as the majority of lesions would have been identified by this technique, VCE could be most useful when conventional endoscopy has already been performed with negative findings as in human medicine.

## ACKNOWLEDGMENTS

The authors thank Infiniti Medical for their contribution of 9 cases used in this study. Study was presented at the Comparative Gastroenterology Society (CGS), Winter Park, Colorado, 2018, and the 2019 American College of Veterinary Internal Medicine (ACVIM) Forum, Seattle, Washington.

## CONFLICT OF INTEREST DECLARATION

Tracy Hill and Brian Hardy are employees of Infiniti Medical.

## OFF-LABEL ANTIMICROBIAL DECLARATION

Authors declare no off-label use of antimicrobials.

## INSTITUTIONAL ANIMAL CARE AND USE COMMITTEE (IACUC) OR OTHER APPROVAL DECLARATION

Authors declare no IACUC or other approval was needed.

## HUMAN ETHICS APPROVAL DECLARATION

Authors declare human ethics approval was not needed for this study.

## ORCID

Tracy Hill  <https://orcid.org/0000-0001-5701-9704>

Stanley L. Marks  <https://orcid.org/0000-0001-7991-702X>

## REFERENCES

1. Iddan G, Meron G, Glukhovskiy A, Swain P. Wireless capsule endoscopy. *Nature*. 2000;405:417.
2. Gerson LB. Use and misuse of small bowel video capsule endoscopy in clinical practice. *Clin Gastroenterol Hepatol*. 2013;11:1224-1231.
3. Enns RA, Hookey L, Armstrong D, et al. Clinical practice guidelines for the use of video capsule endoscopy. *Gastroenterology*. 2017;152:497-514.

4. Koulaouzidis A, Rondonotti E, Giannakou A, Plevris JN. Diagnostic yield of small-bowel capsule endoscopy in patients with iron-deficiency anemia: a systematic review. *Gastrointest Endosc.* 2012;76:983-992.
5. Laine L, Sahota A, Shah A. Does capsule endoscopy improve outcomes in obscure gastrointestinal bleeding? Randomized trial versus dedicated small bowel radiography. *Gastroenterology.* 2010;138:1673-1680. e1671; quiz e1611-1672.
6. Triester SL, Leighton JA, Leontiadis GI, et al. A meta-analysis of the yield of capsule endoscopy compared to other diagnostic modalities in patients with obscure gastrointestinal bleeding. *Am J Gastroenterol.* 2005;100:2407-2418.
7. Saperas E, Dot J, Videla S, et al. Capsule endoscopy versus computed tomographic or standard angiography for the diagnosis of obscure gastrointestinal bleeding. *Am J Gastroenterol.* 2007;102:731-737.
8. de Leusse A, Vahedi K, Edery J, et al. Capsule endoscopy or push enteroscopy for first-line exploration of obscure gastrointestinal bleeding? *Gastroenterology.* 2007;132:855-862. quiz 1164-1165.
9. Appleyard M, Fireman Z, Glukhovskiy A, et al. A randomized trial comparing wireless capsule endoscopy with push enteroscopy for the detection of small-bowel lesions. *Gastroenterology.* 2000;119:1431-1438.
10. Appleyard M, Glukhovskiy A, Swain P. Wireless-capsule diagnostic endoscopy for recurrent small-bowel bleeding. *N Engl J Med.* 2001;344:232-233.
11. Hartmann D, Schilling D, Bolz G, et al. Capsule endoscopy versus push enteroscopy in patients with occult gastrointestinal bleeding. *Zeitschrift für Gastroenterologie.* 2003;41:377-382.
12. Voderholzer WA, Ortner M, Rogalla P, Beinhözl J, Lochs H. Diagnostic yield of wireless capsule enteroscopy in comparison with computed tomography enteroclysis. *Endoscopy.* 2003;35:1009-1014.
13. Hara AK, Leighton JA, Sharma VK, Fleischer DE. Small bowel: preliminary comparison of capsule endoscopy with barium study and CT. *Radiology.* 2004;230:260-265.
14. Davignon DL, Lee AC, Johnston AN, et al. Evaluation of capsule endoscopy to detect mucosal lesions associated with gastrointestinal bleeding in dogs. *J Small Anim Pract.* 2016;57:148-158.
15. Chang HS, Yang HT, Kim SY, et al. Assessment on gastrointestinal transit movement of capsule endoscopy in beagle dogs. *Korean J Med Phys.* 2008;19:125-130.
16. Lee ACY, Epe C, Simpson KW, Bowman DD. Utility of capsule endoscopy for evaluating anthelmintic efficacy in fully conscious dogs. *Int J Parasitol.* 2011;41:1377-1383.
17. Lee AC, Hostetler JA, Bowman DD. Assessing the speed of kill of hookworms, *Ancylostoma caninum*, by advantage multi (R) for dogs using endoscopic methods. *Vet Parasitol.* 2014;204:402-406.
18. Hardy BT, Gentile-Solomon J, Solomon JA. Multiple gastric erosions diagnosed by means of capsule endoscopy in a dog. *J Am Vet Med Assoc.* 2016;249:926-930.
19. Raju GS, Gerson L, Das A, Lewis B, American Gastroenterological Association. American Gastroenterological Association (AGA) institute medical position statement on obscure gastrointestinal bleeding. *Gastroenterology.* 2007;133:1694-1696.
20. Paltrinieri S, Preatoni M, Rossi S. Microcytosis does not predict serum iron concentrations in anaemic dogs. *Vet J.* 2010;185:341-343.
21. Laflamme DP, Mahaffey EA, Allen SW, Twedt DC, Prasse KW, Huber TL. Microcytosis and iron status in dogs with surgically induced portosystemic shunts. *J Vet Intern Med.* 1994;8:212-216.
22. Bunch SE, Jordan HL, Sellon RK, Cullen JM, Smith JE. Characterization of iron status in young dogs with portosystemic shunt. *Am J Vet Res.* 1995;56:853-858.
23. Simpson KW, Meyer DJ, Boswood A, White RN, Maskell IE. Iron status and erythrocyte volume in dogs with congenital portosystemic vascular anomalies. *J Vet Intern Med.* 1997;11:14-19.
24. Bunch SE, Johnson SE, Cullen JM. Idiopathic noncirrhotic portal hypertension in dogs: 33 cases (1982-1998). *J Am Vet Med Assoc.* 2001;218:392-399.
25. Harvey BFF JW. Microcytic anemias. In: Zinnk JG, Jain NC, eds. *Veterinary Hematology.* 5th ed. Philadelphia: Lippincott Williams and Wilkins; 2000.
26. Weiser G, O'Grady M. Erythrocyte volume distribution analysis and hematologic changes in dogs with iron deficiency anemia. *Vet Pathol.* 1983;20:230-241.
27. Pioche M, Vanbiervliet G, Jacob P, et al. Prospective randomized comparison between axial- and lateral-viewing capsule endoscopy systems in patients with obscure digestive bleeding. *Endoscopy.* 2014;46:479-484.
28. Zwinger LL, Siegmund B, Stroux A, et al. CapsoCam SV-1 versus PillCam SB 3 in the detection of obscure gastrointestinal bleeding: results of a prospective randomized comparative multicenter study. *J Clin Gastroenterol.* 2019;53(3):e101-e106.
29. Boillat CS, Gaschen FP, Hosgood GL. Assessment of the relationship between body weight and gastrointestinal transit times measured by use of a wireless motility capsule system in dogs. *Am J Vet Res.* 2010;71:898-902.
30. Liao Z, Gao R, Xu C, Li ZS. Indications and detection, completion, and retention rates of small-bowel capsule endoscopy: a systematic review. *Gastrointest Endosc.* 2010;71:280-286.
31. Yung DE, Koulaouzidis A, Douglas S, et al. Earlier use of capsule endoscopy in inpatients with melena or severe iron deficiency anemia reduces need for colonoscopy and shortens hospital stay. *Endosc Int Open.* 2018;6:E1075-E1084.

## SUPPORTING INFORMATION

Additional supporting information may be found online in the Supporting Information section at the end of this article.

**How to cite this article:** Mabry K, Hill T, Marks SL, Hardy BT. Use of video capsule endoscopy to identify gastrointestinal lesions in dogs with microcytosis or gastrointestinal hemorrhage. *J Vet Intern Med.* 2019;33:1964-1969. <https://doi.org/10.1111/jvim.15584>