

[CASE REPORT]

The Antemortem Diagnosis of Primary Malignant Pericardial Mesothelioma: A Multidisciplinary Evaluation

Kohei Shikano¹, Satoshi Hirano², Takuma Hiroishi¹, Noriko Hayama¹, Tetsuo Fujita¹, Hiroyuki Amano¹, Makoto Nakamura¹, Sukeyuki Nakamura¹, Hiroshi Tabeta¹, Shuji Ichinose³, Osamu Uchida³ and Shinichiro Shimizu⁴

Abstract:

A 64-year-old woman complaining of progressive dyspnea was admitted with recurrence of massive pericardial effusion. The patient had been diagnosed with radiation pericarditis based on a previous case of pericardiocentesis. To make a diagnosis and improve her symptoms, imaging examinations and pericardial fenestration were performed. Because of difficulty making a diagnosis, after some months, pericardiotomy and incision of the epicardium were performed. The patient was ultimately diagnosed with primary malignant pericardial mesothelioma of the epithelioid type. Primary malignant pericardial mesothelioma is a rare tumor that is difficult to diagnose. An antemortem diagnosis can be made by a multidisciplinary evaluation.

Key words: pericardial mesothelioma, pericardial fenestration, pericardiotomy, multidisciplinary evaluation

(Intern Med 57: 2559-2562, 2018)

(DOI: 10.2169/internalmedicine.0355-17)

Introduction

Primary malignant pericardial mesothelioma (PMPM) is an extremely rare malignant tumor that accounts for 0.8% of all mesotheliomas and 2-3% of all pericardial tumors (1, 2). Making a diagnosis of PMPM is very difficult, and the majority of cases are diagnosed at an autopsy (3).

We herein report the case of a patient with PMPM that was diagnosed clinically by a multidisciplinary evaluation involving diagnostic imaging and surgical biopsies.

Case Report

A 64-year-old woman complaining of progressive dyspnea was admitted to our hospital in December 2014. The patient had histories of tuberculosis treatment and radiation therapy for right breast cancer in 1988, but she had no history of

smoking or asbestos exposure.

Chest radiography showed cardiomegaly with bilateral pleural effusion. Chest computed tomography showed a thickened pericardium with massive pericardial effusion, mild bilateral pleural effusion, and calcified pulmonary nodules, although there were no pleural plaques. Transthoracic echocardiography also showed pericardial effusion (Fig. 1). In 2011, the patient had presented to our hospital with pericardial effusion. Pericardiocentesis had been performed several times. Carcinoembryonic antigen of the pericardial effusion was 0.7 ng/mL, and squamous cell carcinoma antigen was over 70 ng/mL, but a cytological examination of the fluid was class III, and polymerase chain reaction (PCR) for tuberculosis was negative. While the irradiation field for breast cancer was unknown because radiation therapy had been performed 26 years earlier, the patient was diagnosed with radiation pericarditis.

The patient underwent video-assisted thoracoscopic peri-

¹Department of Respiratory Medicine, Funabashi Municipal Medical Center, Japan, ²Department of Medical Oncology, Funabashi Municipal Medical Center, Japan, ³Department of Thoracic Surgery, Funabashi Municipal Medical Center, Japan and ⁴Department of Pathology, Funabashi Municipal Medical Center, Japan

Received: October 16, 2017; Accepted: February 1, 2018; Advance Publication by J-STAGE: April 27, 2018

Correspondence to Dr. Kohei Shikano, shika.v.a.r.1107@gmail.com

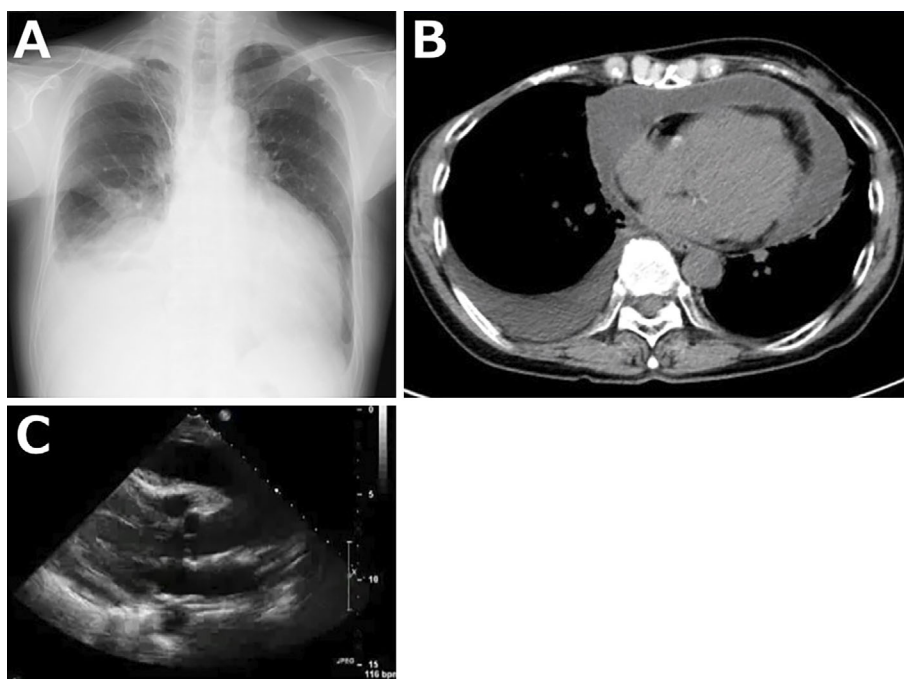


Figure 1. A: Chest radiography shows cardiomegaly with bilateral pleural effusion. B: Chest computed tomography shows a thickened pericardium with massive pericardial effusion and bilateral pleural effusion. C: Transthoracic echocardiography shows pericardial effusion.

cardial fenestration to make a diagnosis and improve her symptoms. A histological examination of the resected pericardial specimen showed chronic epicarditis with reactive mesothelial proliferation, but a definitive diagnosis was not possible. Diuretic therapy for heart failure and steroid therapy for chronic inflammation were started. The pericardial effusion decreased, and the patient was discharged in January 2015. However, the patient was re-admitted due to recurrence of the pericardial effusion in March 2015.

The patient then underwent pericardiectomy and incision of the epicardium (Waffle procedure) in April 2015. A histological examination showed thickening of the pericardium with severe fibrosis and hyalinosis. Immunohistochemistry was positive for calretinin, D2-40, and cytokeratin 5/6 and negative for carcinoembryonic antigen, BerEP4 and thyroid transcription factor 1 (Fig. 2). Ultimately, a diagnosis of the epithelioid type of PMPM was made. However, the patient's condition deteriorated due to disease progression. The patient received no chemotherapy, but she did receive palliative care. She died, and an autopsy was performed.

At the autopsy, malignant cells were found growing mainly in the pericardium, with invasion of the myocardium, ascending aorta, right pleura, and right lung (Fig. 3). No other distant metastases were identified.

Discussion

PMPM is an extremely rare tumor that arises from the pericardial mesothelial cell layers. The prevalence of PMPM was lower than 0.0022% in a large autopsy study (4). Compared with pleural malignant mesothelioma, PMPM is less

strongly associated with asbestos exposure (5, 6). Prior radiation therapy has been reported to be one of the causes of PMPM (7). In this case, the patient had no history of asbestos exposure but did have a history of radiation therapy. Therefore, she had been diagnosed with radiation pericarditis.

PMPM is often misdiagnosed at the first visit because of its nonspecific symptoms, including dyspnea, coughing, or chest pain. Chest radiography, chest computed tomography, and echocardiography, which are performed first in many cases, often show a thickened pericardium with massive pericardial effusion, which are not characteristic findings, making it difficult to distinguish PMPM from other diseases. The majority of patients with PMPM present with pericarditis with pericardial effusion, indicating that the disease has reached an advanced stage.

The diagnosis of PMPM is very difficult and often comes late in the clinical course. Serum mesothelin is considered to be the best biomarker of malignant pleural mesothelioma. Magnetic resonance imaging and fluorodeoxyglucose positron emission tomography scans are helpful for the diagnosis or staging of PMPM (8-11).

However, a definitive diagnosis requires a pathological examination. It is difficult to make a definitive diagnosis by pericardial fluid cytology or a histological examination of small pericardial specimens; thus, the majority of cases are diagnosed at an autopsy (3, 12). The antemortem diagnostic yield is reported to be only 20% (3). In the present case, although PMPM was suspected on diagnostic imaging on admission, radiation pericarditis and tuberculous pericarditis were considered in the differential diagnosis. A cytological

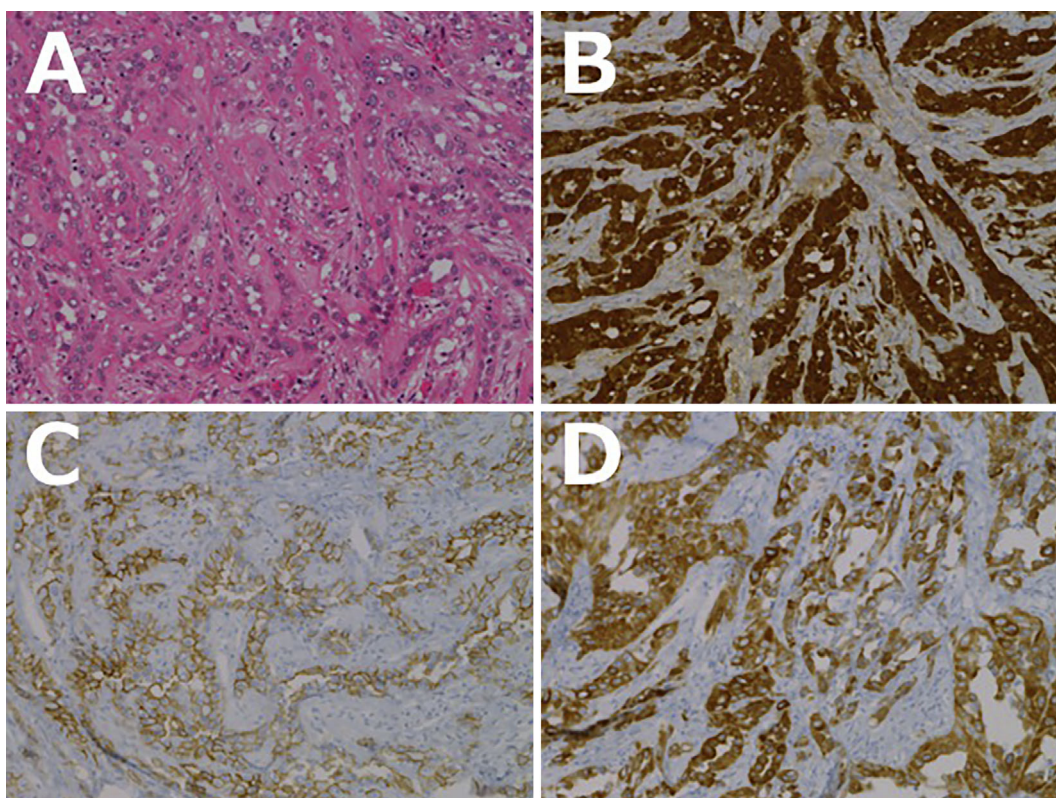


Figure 2. A: A histological examination of the resected pericardium specimen shows thickening of the pericardium with severe fibrosis and hyalinosis (Hematoxylin and Eosin staining, $\times 20$). B: Immunohistochemistry is positive for calretinin ($\times 20$). C: Immunohistochemistry is positive for D2-40 ($\times 20$). D: Immunohistochemistry is positive for cytokeratin 5/6 ($\times 20$).

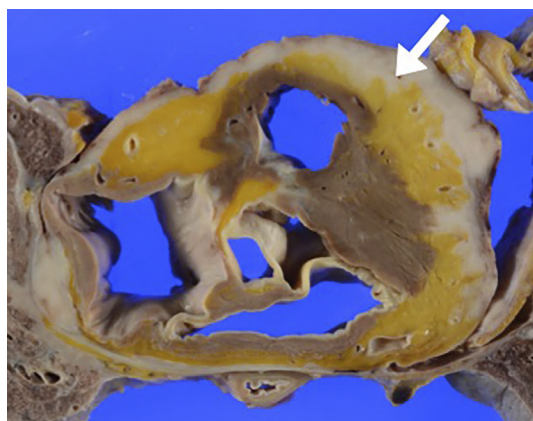


Figure 3. At the autopsy, malignant cells are seen growing in the pericardium (white lesion, arrow), with invasion of the myocardium, ascending aorta, right pleura, and right lung.

examination of the pericardial effusion was class III, and a histological examination of the resected pericardium specimen by thoracoscopic pericardial fenestration showed only chronic epicarditis with reactive mesothelial proliferation. The patient was ultimately diagnosed by a histological examination of the resected pericardial specimen obtained by pericardiotomy and incision of the epicardium. It is likely that an antemortem diagnosis can be made by a multidisciplinary evaluation, with laboratory studies such as serum

mesothelin and a pericardial analysis, diagnostic imaging, and surgical biopsies.

No standard treatment guideline for PMPM has yet been established. Although surgical resection is the treatment for localized disease (13), most cases are diagnosed at an advanced stage. In such cases, systemic chemotherapy is performed. Cisplatin combined with pemetrexed has demonstrated some activity against malignant pleural mesothelioma and is also considered the first-line treatment for PMPM (14, 15). Nonetheless, the prognosis of PMPM is dismal, with median survival times from the diagnosis of approximately six months (12).

In conclusion, our patient with PMPM was diagnosed antemortem by a multidisciplinary evaluation including diagnostic imaging and surgical biopsies.

The authors state that they have no Conflict of Interest (COI).

References

- Gemba K, Fujimoto N, Kato K, et al. National survey of malignant mesothelioma and asbestos exposure in Japan. *Cancer Sci* **103**: 483-490, 2012.
- Kaul TK, Fields BL, Kahn DR. Primary malignant pericardial mesothelioma: a case report and review. *J Cardiovasc Surg* **35**: 261-267, 1994.
- Suman S, Schofield P, Large S. Primary pericardial mesothelioma presenting as pericardial constriction: a case report. *Heart* **90**: e4,

- 2004.
4. Santos C, Montesinos J, Castañer E, Sole JM, Baga R. Primary pericardial mesothelioma. *Lung Cancer* **60**: 291-293, 2008.
 5. Patel J, Sheppard MN. Primary malignant mesothelioma of the pericardium. *Cardiovasc Pathol* **20**: 107-109, 2011.
 6. Yang GZ, Li J, Ding HY. Localized malignant myxoid anaplastic mesothelioma of the pericardium. *J Clin Med Res* **1**: 115-118, 2009.
 7. Rizzardi C, Barresi E, Brollo A, Cassetti P, Schneider M, Melato M. Primary pericardial mesothelioma in an asbestos-exposed patient with previous heart surgery. *Anticancer Res* **30**: 1323-1325, 2010.
 8. Kurosawa T, Sugino K, Isobe K, Hata Y, Fukasawa Y, Homma S. Primary malignant pericardial mesothelioma with increased serum mesothelin diagnosed by surgical pericardial resection: a case report. *Mol Clin Oncol* **5**: 553-556, 2016.
 9. Hollevoet K, Reitsma JB, Creaney J, et al. Serum mesothelin for diagnosing malignant pleural mesothelioma: an individual patient data meta-analysis. *J Clin Oncol* **30**: 1541-1549, 2012.
 10. Langer C, Butz T, Horstkotte D. Multimodality in imaging calcific constrictive pericarditis. *Heart* **92**: 1289, 2006.
 11. Ost P, Rottey S, Smeets P, Boterberg T, Stragier B, Goethals I. F-18 fluorodeoxyglucose PET/CT scanning in the diagnostic work-up of a primary pericardial mesothelioma: a case report. *J Thorac Imaging* **23**: 35-38, 2008.
 12. Nilsson A, Rasmuson T. Primary pericardial mesothelioma: report of a patient and literature review. *Case Rep Oncol* **29**: 125-132, 2009.
 13. Fujita K, Hata M, Sezai A, Minami K. Three-year survival after surgery for primary malignant pericardial mesothelioma: report of a case. *Surg Today* **44**: 948-951, 2014.
 14. Chung SM, Choi SJ, Kim MJ, et al. Positive response of a primary malignant pericardial mesothelioma to pemetrexed plus cisplatin followed by pemetrexed maintenance chemotherapy: a case report. *Oncol Lett* **12**: 213-216, 2016.
 15. Vogelzang NJ, Rusthoven JJ, Symanowski J, et al. Phase III study of pemetrexed in combination with cisplatin versus cisplatin alone in patients with malignant pleural mesothelioma. *J Clin Oncol* **15**: 2636-2644, 2003.

The Internal Medicine is an Open Access article distributed under the Creative Commons Attribution-NonCommercial-NoDerivatives 4.0 International License. To view the details of this license, please visit (<https://creativecommons.org/licenses/by-nc-nd/4.0/>).