

Submitted: 22.11.2016

Accepted: 27.11.2016

Published: 31.03.2017

## The standards of an ultrasound examination of the prostate gland. Part 2

Janusz F. Tyloch<sup>1</sup>, Andrzej Paweł Wieczorek<sup>2</sup>

<sup>1</sup> Chair of Urology, Department of General and Oncological Urology of the Collegium Medicum in Bydgoszcz, Nicolaus Copernicus University in Toruń, Poland

<sup>2</sup> Department of Paediatric Radiology of the Medical University of Lublin

Correspondence: Janusz F. Tyloch, MD, PhD, Department of General and Oncological Urology of the Collegium Medicum in Bydgoszcz, Marii Skłodowskiej-Curie 9, 85-094 Bydgoszcz, Poland, e-mail: januszyloch@gmail.pl

DOI: 10.15557/JoU.2017.0007

### Key words

transabdominal ultrasonography of the prostate gland (TAUS), transrectal ultrasonography of the prostate gland (TRUS), benign prostatic hyperplasia, prostatitis, prostate gland cancer

### Abstract

The paper discusses the rules of the proper performing of the ultrasound examination of the prostate gland. It has been divided into two parts: the general part and the detailed part. The first part presents the necessary requirements related to the ultrasound equipment needed for performing transabdominal and transrectal examinations of the prostate gland. The second part presents the application of the ultrasound examination in benign prostatic hyperplasia, in cases of prostate inflammation and in prostate cancer. Ultrasound examinations applied in the diagnostics of benign prostatic hyperplasia accelerated the diagnosis, facilitated the qualification to surgery and the selection of the treatment method. The assessment of the size of the prostate gland performed using the endorectal ultrasound examination is helpful in making the choice between transurethral electroresection and adenectomy. In prostate inflammation this examination should be performed with particular gentleness due to pain ailments. The indication for performing the examination in acute inflammation is the suspicion of prostate abscess. In chronic, exacerbating prostatitis it is possible to perform an intraprostatic antibiotic injection. In the recent years increased morbidity and detectability of prostate gland cancer is observed among men. In Poland it ranks second (13%) among diseases occurring in men. The indication for an endorectal examination is the necessity to assess the size of the prostate gland, its configuration, the echostructure in classical ultrasonography, the vascularization in an ultrasound examination performed with power doppler and, if possible, the differences in the gland tissue firmness (consistency) in elastography. The ultrasound examination is used for performing the mapping biopsy of the prostate gland – from routine, strictly defined locations, the targeted biopsy – from locations suspected of neoplastic proliferation and the staging biopsy – from the neurovascular bundles, the seminal vesicles, from the apex of the prostate and from the periprostatic tissue – this type of biopsy is supposed to help in determining local staging of the neoplastic disease. The ultrasound examination is also helpful during the treatment of the neoplasm performed using brachytherapy or using the method of ultrasonic ablation which is still in the phase of clinical trials.

The prostate gland (prostate) is an unpaired parenchymal-glandular organ, the shape and size of which resembles an edible chestnut. Its average dimensions in a healthy young man are: 3.75–4.00 × 2.5–3.00 × 3.1–3.8 cm (width x height x length) and its volume is ca. 20–25 cm<sup>3</sup>. It belongs to the male genital system – it produces the glycoprotein (*prostate specific antigen*, PSA) which is an ingredient of the semen and is responsible for its liquefying. The prostate has also got endocrine properties: it produces E, F and A prostaglandins, spermidine and spermine. It is also the place of the conversion of testosterone into dihydrotestosterone under the influence of the 5- $\alpha$ -reductase enzyme.

In 1981 John E. McNeal published his experiments referring to the structure of the prostate. He differentiated 4 areas of the prostate: the central zone, the transition zone, the peripheral zone and the periurethral zone as well as the anterior commissure which is a fibro-muscular stroma. The peripheral zone constitutes ca. 75% of the mass of a normal prostate and it is the place where neoplasms develop most frequently. The central zone constitutes 25% of the mass of a normal prostate – here prostatitis most often occurs. The transition zone constitutes only 2–10% of the mass of a normal prostate and it significantly expands

in the course of benign prostatic hyperplasia, creating an adenoma, often of a large size<sup>(1)</sup>.

The diseases which develop within the prostate gland may be divided into three groups: benign prostatic hyperplasia, prostatitis and prostate cancer<sup>(2)</sup>.

### Ultrasonography in the diagnostics and treatment of benign prostatic hyperplasia

Benign prostatic hyperplasia developing mainly in the transition zone is the most frequent cause of urination disorders in men in an elderly age. Due to its spread, the social and economic effects and the aging of populations this condition has been recognized by the WHO as a social disease. Histological features of benign prostatic hyperplasia occur in 50% of men aged ca. 60 and the symptoms of this disease – in 40–70% of such men. Histological features of benign prostatic hyperplasia occur in 90% of men aged 85. Benign prostatic hyperplasia does not directly threaten life but it significantly lowers the quality of life. In the last decade one can observe a significant reduction of the frequency of surgery treatment with a simultaneous increase of the frequency of applying pharmacological treatment. The syndrome consists of:

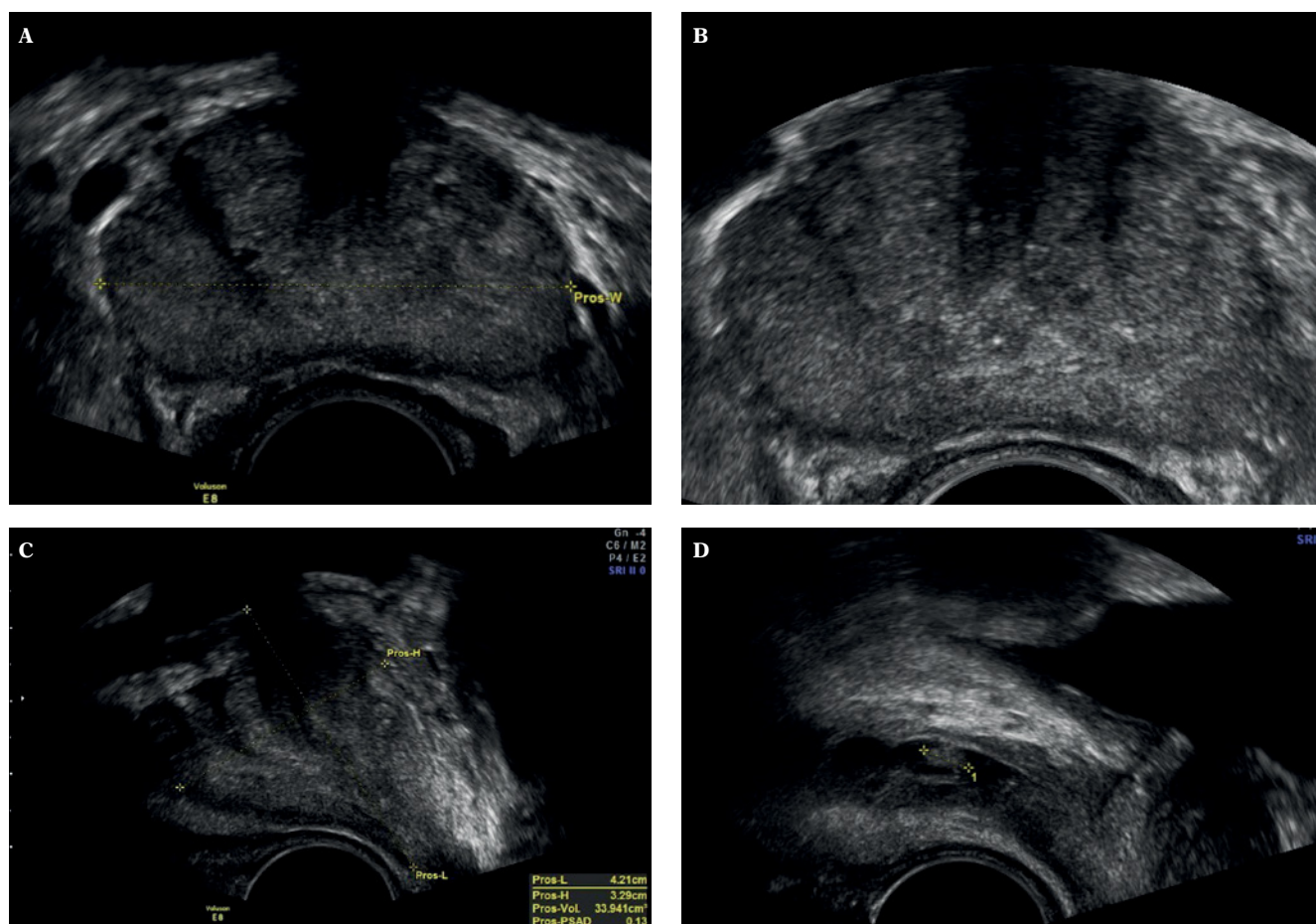
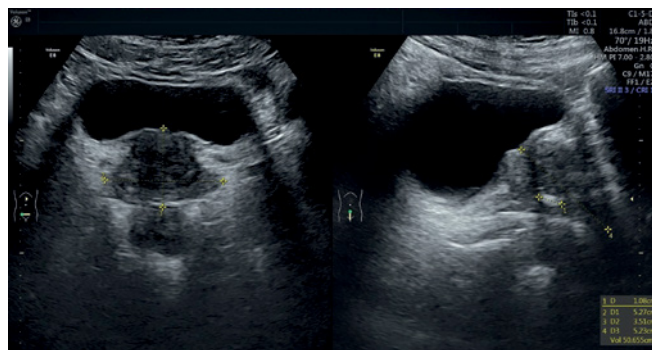


Fig. 1. An ultrasound examination performed using an endorectal probe. A, B. Transverse sections of the prostate gland; C, D. A longitudinal section of the prostate

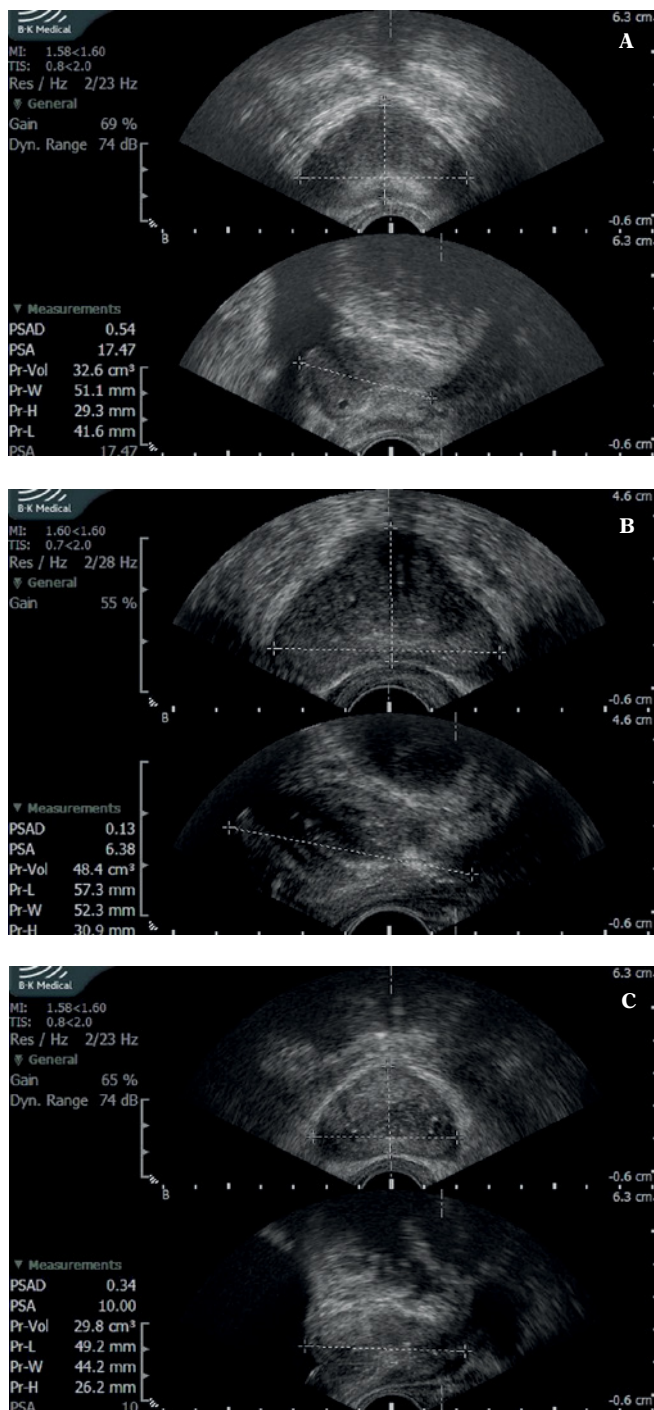

**Fig. 2.** The transabdominal ultrasound examination. The biplane method of measuring the volume of the prostate. The calculation method is similar to the method of calculating the capacity of the urinary bladder. The photo presents a prostate gland of 4.8 cm of height, 5.4 cm of width and 5.9 cm of length, with a volume of ca. 80 cm<sup>3</sup>, protruding into the lumen of the urinary bladder by ca. 2.3 cm

- 1) prostate enlargement (*benign prostatic enlargement, BPE; benign prostatic hyperplasia, BPH*), 2) a bladder outlet obstruction (BOO), 3) lower urinary tract symptoms (LUTS), 4) the bladder detrusor (BD) dysfunction.

The development of benign prostatic hyperplasia may be divided into 4 periods: the 1<sup>st</sup> period – asymptomatic (only prostate enlargement is observed), the 2<sup>nd</sup> period – irritation (the main symptom is pollakiuria – frequent urination), the 3<sup>rd</sup> period – the presence of residual urine in the bladder after voiding, the 4<sup>th</sup> period – decompensation (the observed symptoms are: urine retention, dilated pelvicalyceal systems of the kidneys also with hydronephrosis, widening of the ureters, hypertrophy of the detrusor, trans-beculation of the wall of the bladder, renal failure).

The diagnose is based on the taken history, the physical examination which includes the palpation examination of the prostate performed per rectum (digital rectal examination, DRE) and additional examinations, i.a. imaging, especially ultrasound examinations. The ultrasound examinations include transabdominal ultrasonography (TAUS) of the urinary organs and the prostate with the assessment of the presence of residual urine after voiding and transrectal ultrasonography (TRUS) (Fig. 1). According to the indications of the European Association of Urology (EAU) the examinations recommended in the course of benign prostatic hyperplasia include the measurement of the volume of residual urine present in the bladder after voiding performed during transabdominal ultrasonography; and in the group of supplementary examinations – the ultrasonography of the upper urinary tract and transrectal ultrasonography of the prostate. Ultrasound examinations are recommended for the assessment of the staging of the disease. The EAU recommends the measurement of the residual urine after voiding (TAUS) and the measurement of the volume of the prostate performed using transrectal ultrasonography. The ultrasound assessment of the size of the prostate is helpful in the selection of the method of treatment – in accordance with the recommendations of the EAU glands with a volume lower than 80 cm<sup>3</sup> are qualified for transurethral electroresection and glands of a higher volume – for open surgery – adenectomy.

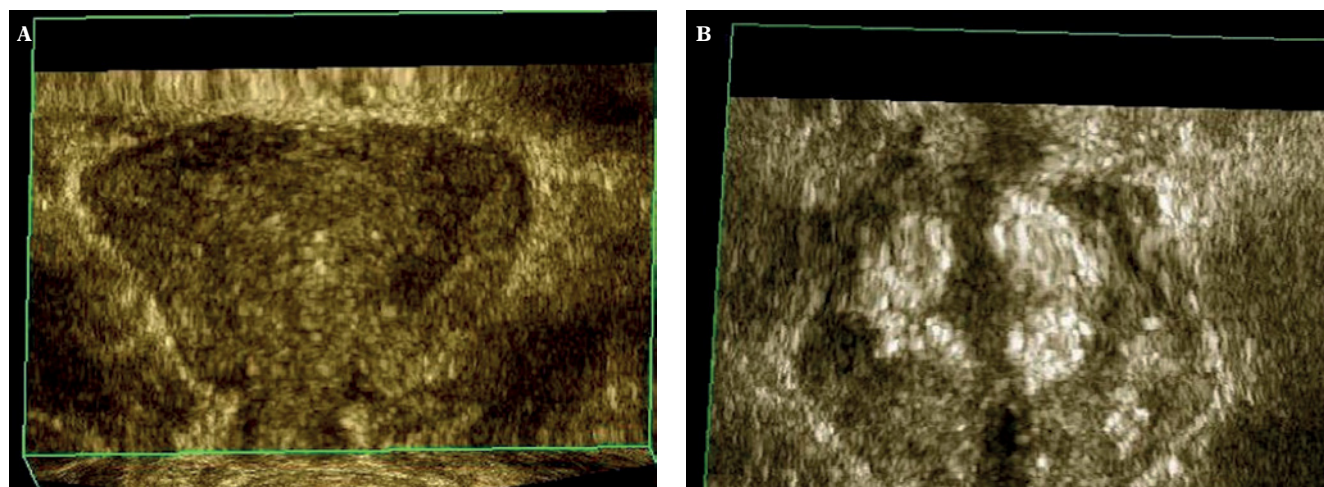


**Fig. 3.** The biplane method of measuring the volume of the prostate. The transverse and longitudinal sections obtained during the transrectal examination

In practice applying ultrasonography in benign prostate hyperplasia includes:

- the assessment of the amount of the residual urine present in the bladder after voiding – transabdominal examination (TAUS);
- the assessment of the size and the configuration of the prostate – transabdominal examination (TAUS) and





**Fig. 4.** The three-dimensional ultrasound examination (USG 3D) of the prostate gland: **A.** The coronal section of the prostate gland before the intraprostatic administration of the antibiotic; **B.** The image of the prostate gland in a coronal section after the administration of the antibiotic – the control of the distribution of the antibiotic. Two symmetric hyperechogenic areas which became visible after the injection of the antibiotic are the image of a solution administered to the prostate tissue

a more precise examination performed using the transducer through the rectum (TRUS);

- the assessment of the condition of the upper urinary tract and the urinary bladder – transabdominal examination (TAUS).

### The assessment of the amount of residual urine present in the bladder after voiding – TAUS

The assessment of the amount of residual urine present in the bladder after voiding becomes the qualification for surgical treatment – if the ultrasound examination demonstrates an increasing amount of residual urine after voiding this indicates the non-effectiveness of pharmacological treatment – in such a situation the patient should be qualified for surgical treatment<sup>(3-6)</sup>.

The most popular method of measuring the volume of the urinary bladder and the occurrence of residual urine after voiding are calculations based on the measurements of the width, the height and the length of the urinary bladder performed on two mutually perpendicular sections: the transverse section and the longitudinal section. The results of the measurements have been inserted into the formula for the volume of the ellipsoid:

$$V = \pi/6 \times W \times H \times L = 0,5236 \times W \times H \times L$$

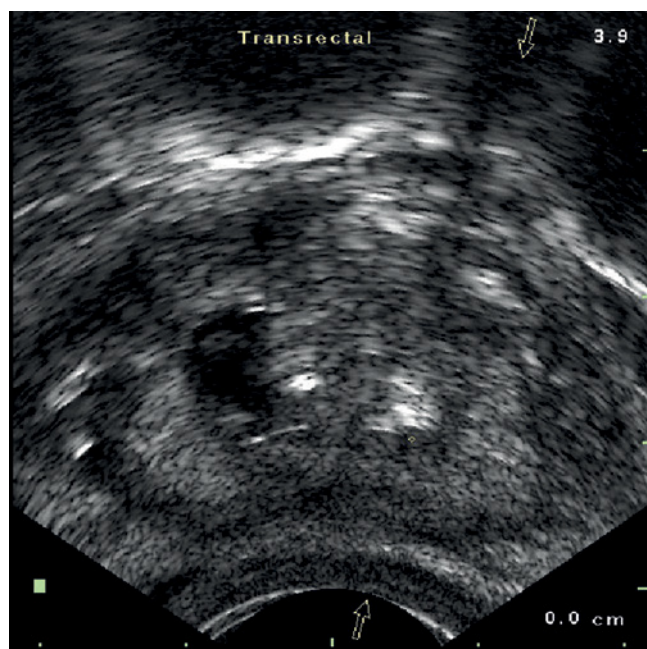
where W indicates the width, H – the height, L – the length of the urinary bladder.

Another method is the single-plane method which consists in inscribing the ellipsoid into the image of the transverse section of the urinary bladder. The researcher determines the rotation axis of a two-dimensional geometric figure and the computer in the USG machine uses the formula  $V = \pi/6 \times W \times W \times L = 0,5236 \times W \times W \times L = \pi/6 \times W^2 \times L$  to calculate the volume of the hypothetical geometric

figure, the shape of which is similar to the urinary bladder. Naturally, this method is far less accurate.

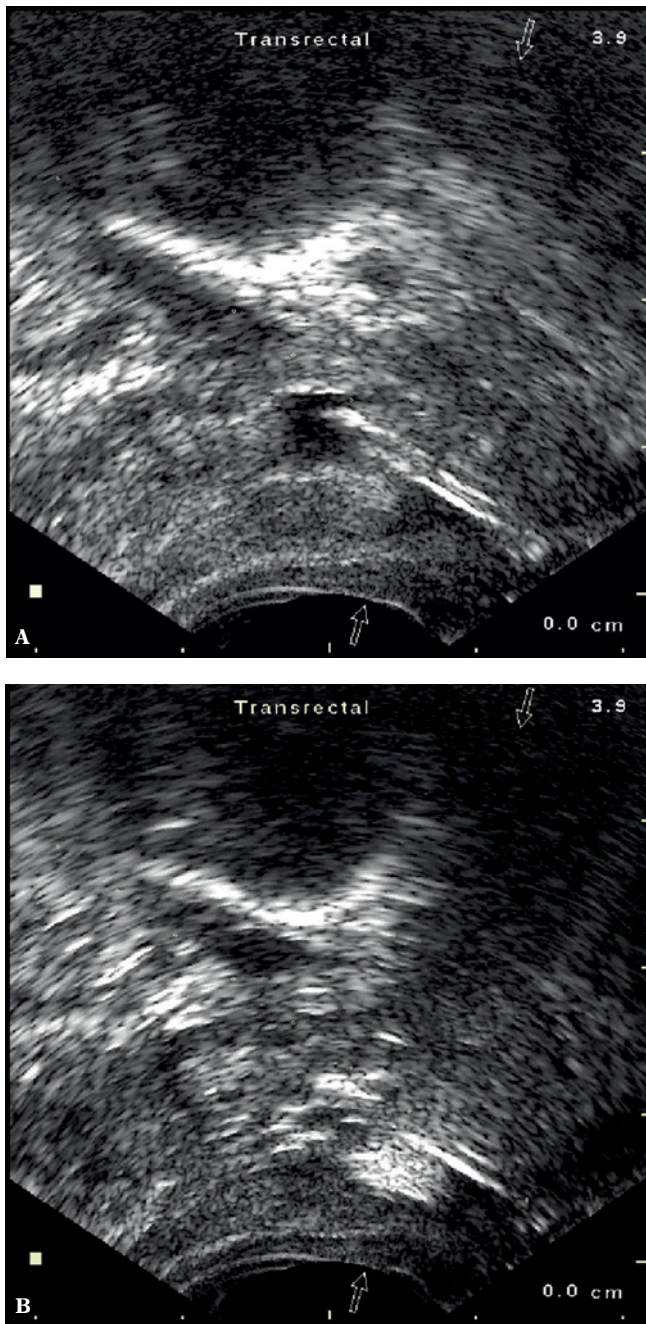
Also other methods of measuring the volume of the urinary bladder and the amount of the residual urine have been described. Some of them are accurate but complicated to use, other are simple to apply but less accurate<sup>(7,8)</sup>.

One of the methods of measuring the volume of the urinary bladder is also using an ultrasound scanner which is applied in the suprapubic area and which displays the result on the screen – the amount of residual urine is expressed



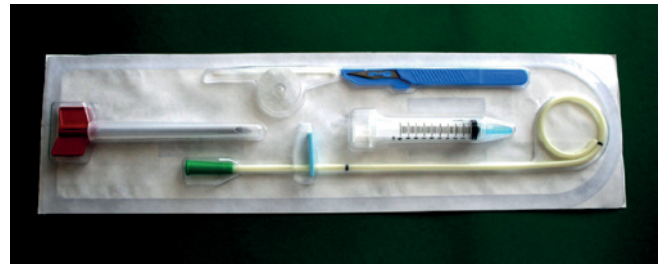**Fig. 5.** The transrectal ultrasound examination. The transverse section of the prostate gland is visible. The clearly demarcated hypoechogenic area in the right lobe is the image of an abscess



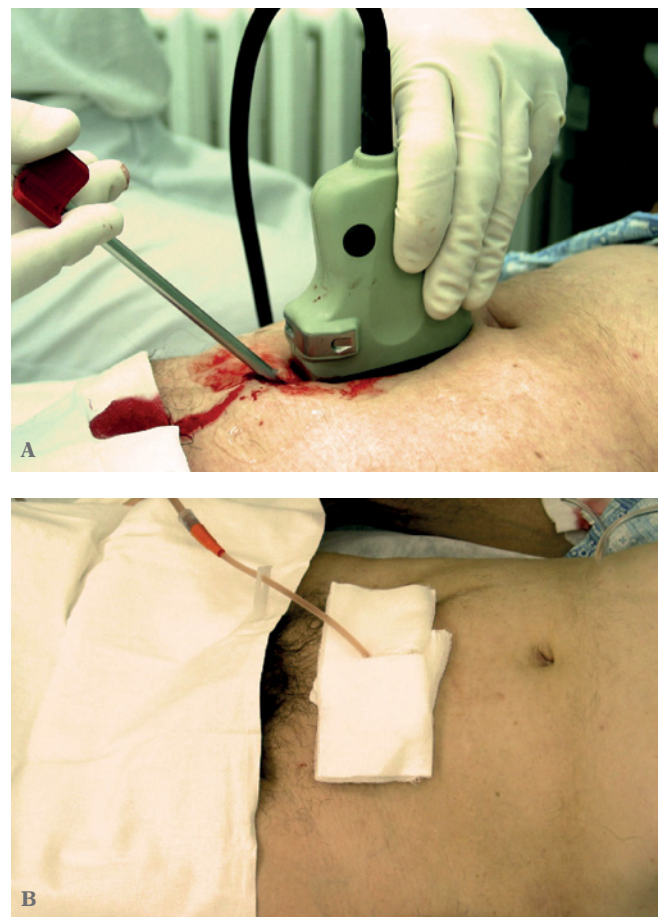

**Fig. 6.** The transrectal ultrasound examination, the longitudinal section of the prostate gland: **A.** A needle during the puncture of the prostate abscess is visible; **A, B.** the abscess content has been completely removed.

in ml. The scanner emits ultrasound beams in multiple planes, therefore in the measurements it takes into consideration the uneven shape of the urinary bladder. The measurement of the volume and the presence of residual urine after voiding which takes into consideration the uneven shape of the bladder is very accurate<sup>(9,10)</sup>. The assessment of the volume of residual urine may also be performed by applying automatic volumetry measurement methods – now nearly every USG machine is equipped with them.



**Fig. 7.** A set for forming a vesicocutaneous fistula (cystostomy) consisting of: a cystostomy needle, a catheter, a syringe, a scalpel, a mounting flange and a medical tourniquet

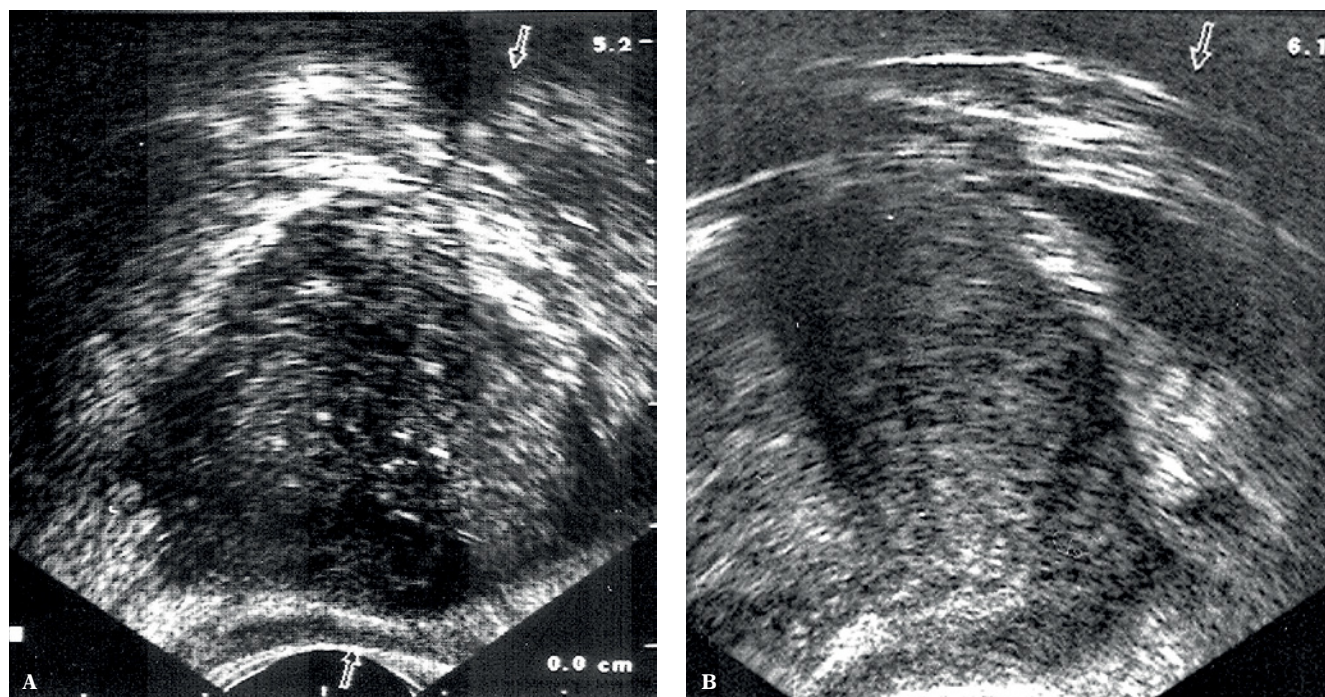


**Fig. 8.** Forming a vesicocutaneous fistula (cystostomy) under USG control

The assessment of the size and the configuration of the prostate – a transabdominal examination (TAUS) and a more precise transrectal examination (TRUS)

The most popular measurement method are calculations based on the dimensions of the prostate measured on two mutually perpendicular sections: the transverse section and the longitudinal section with applying the formula for the volume of the ellipsoid – the same formula which is used in





**Fig. 9.** The transrectal ultrasound examination – transverse sections of the prostate. In the peripheral zone hypoechoic areas are visible – they are places suspected of neoplastic proliferation

measurements of the urinary bladder. The measurements of the height, the width and the length of the prostate may be performed both during the transabdominal (Fig. 2) and the transrectal (Fig. 3) ultrasound examination. The results of the measurements performed during the transrectal examination are burdened with smaller error<sup>(11–14)</sup>.

### The assessment of the condition of the upper urinary tract and the urinary bladder

The assessment of the condition of the upper urinary tract includes the measurements of the size of the kidneys, the measurements of the thickness of the renal parenchyma, the assessment of the potential dilatation of the pelvicalyceal system, diagnosing hydronephrosis as well as the widening of the ureters, their tortuosity and the occurrence of deposits within the kidneys and the ureters.

The assessment of the urinary bladder includes the measurement of its volume and the amount of the residual urine after voiding, the measurement of the thickness of its walls, its thickening and the presence of increased transubeculation, diagnosing the presence of diverticula, the occurrence of the protrusion of the third lobe of the prostate and the presence of deposits within the bladder.

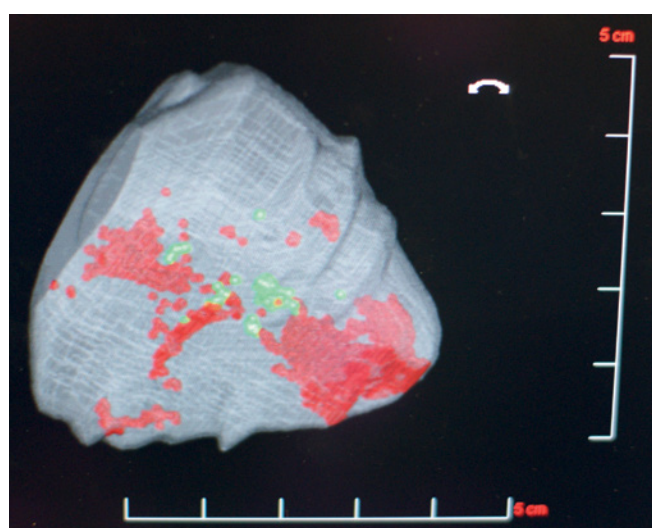
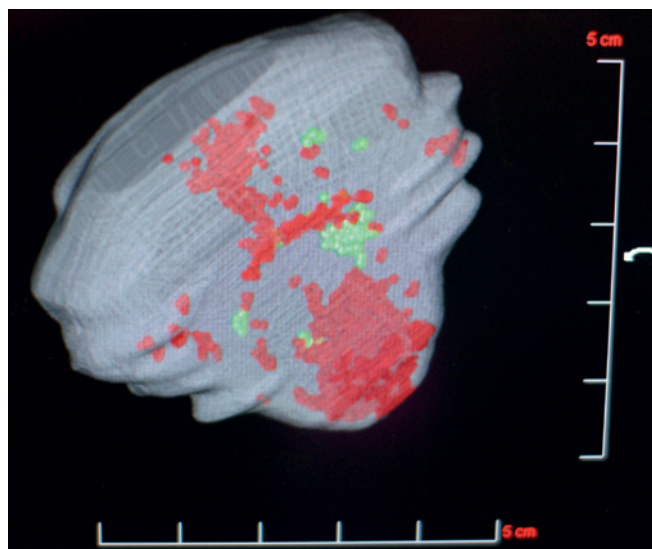
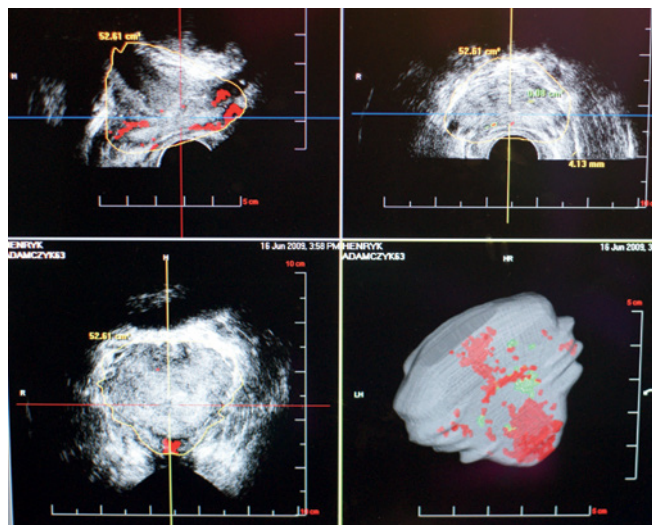
### Ultrasonography in the diagnosis and treatment of inflammations of the prostate

The prostate gland may be the place of development of acute inflammations (with accompanying high fever, pain


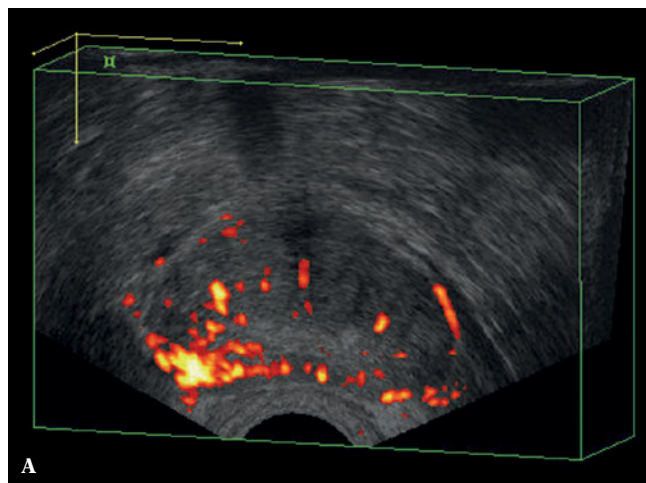
in the perineum and urinary retention) and chronic inflammations. Ultrasound images in the course of chronic prostatitis are not characteristic. The echogenicity of the gland parenchyma is not homogenous. The hypoechoic areas are accompanied by hyperechoic areas in a disordered manner. The prostate gland may be enlarged and deformed<sup>(15)</sup>.

Persistent, recurrent symptoms of chronic prostatitis (*prostatitis chronica exacerbata*), which are unresponsive to the classical antibiotic therapy, may be an indication for applying targeted antibiotic therapy performed through an intraprostatic injection. The antibiotic is selected in accordance with the result of the microbiological examination of the semen and the assessment of the antibiogram. The most frequently administered antibiotics were: gentamicin, amoxicillin with clavulanic acid, piperacillin. Gentamicin 80 mg is dissolved and administered in the amount of 1 ml to each lobe under USG control with the use of an intrarectal transducer. Piperacillin 2 g is dissolved in 3 ml of the solution and administered in the amount of 1.5 ml to each lobe. While administering the antibiotic it is important to distribute it evenly over the entire lobe and especially on the central zone. After administering the antibiotic to the prostate one should control the uniformity of its distribution within the scope of both lobes using the USG 3D option. The antibiotic solution containing microbubbles of air is visible as a hyperechoic area (Fig. 4)<sup>(16,17)</sup>.

A complication of acute prostatitis may be the occurrence of an abscess within the scope of the prostate gland. A hypoechoic surface appears in the ultrasound image



**Fig. 10.** Histoscanning – a method of computer analysis of the ultrasound image with visualizing areas suspected of neoplastic proliferation



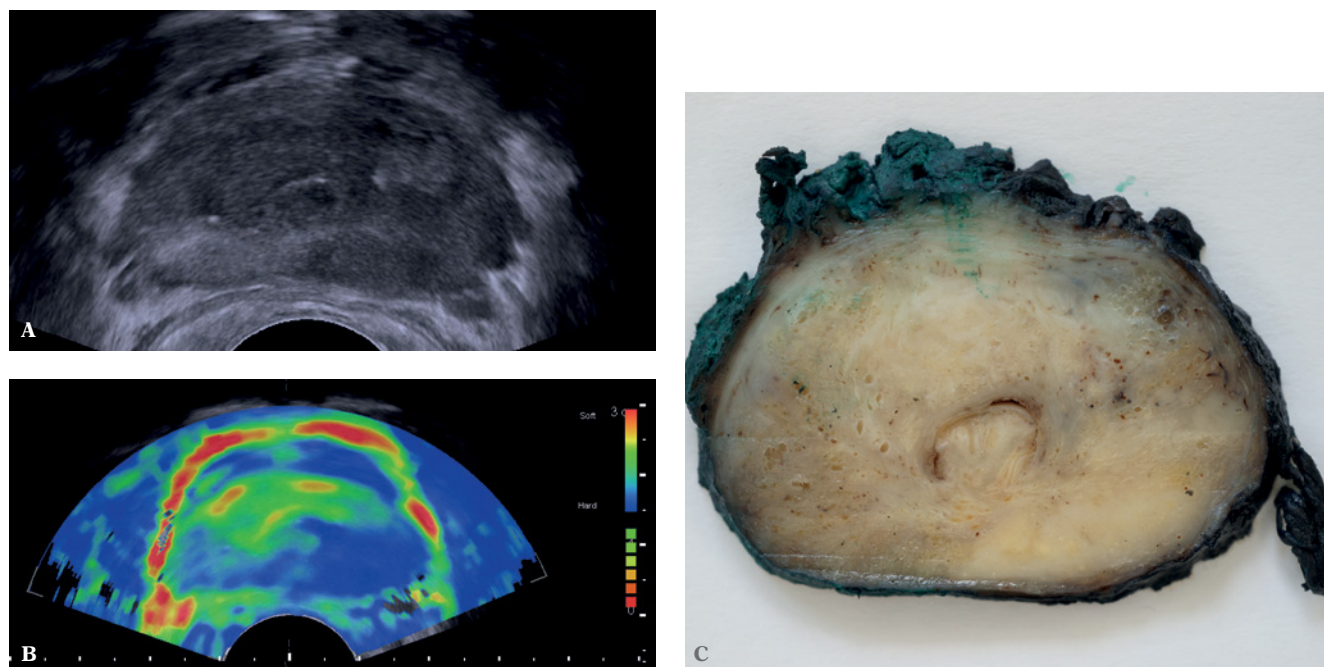
**Fig. 11.** The transrectal examination of the prostate gland with applying the power doppler: **A.** The clearly visible greater density of blood vessels within the scope of the right lobe of the prostate corresponds with the angiogenesis within the scope of neoplastic tissue. **B.** The image of the vascular tree within the scope of the prostate gland tissue in 3D USG with the application of the power doppler

(Fig. 5). Fluid space becomes visible within the scope of the prostate parenchyma in the USG 3D image.

The clinical image of the disease is very characteristic. The possibility of the occurrence of an abscess should be taken into consideration when in the period preceding the diagnosis the patient experiences high body temperature, pain in the lower abdomen, problems with urination, strong pain during the palpation examination performed per rectum, sometimes the symptom of fluctuation is palpable. The diagnosis of a prostate abscess is an indication for the evacuation of the abscess. The treatment method of choice is the evacuation of the abscess by means of a transrectal puncture and drainage under USG control (Fig. 6).

Acute prostatitis may lead to urinary retention. In such a situation inserting a catheter into the urinary bladder through the urethra is contraindicated because it exacerbates the inflammation by hindering the outflow of the





**Fig. 12.** A comparison of the images obtained during the transrectal ultrasound examination of the prostate gland in the greyscale, the elastographic examination with the specimen obtained after radical prostatectomy. **A.** TRUS – within the scope of the peripheral zone, on the left a hypoechoic area is visible which is clearly demarcated from the rest of the gland; the left neurovascular bundle is widened. **B.** The elastographic examination – within the scope of the peripheral zone, on the left an area with significantly more firm consistency than that of the remaining tissue of the gland is visible – intense blue color. **C.** The macroscopic image of the specimen obtained after prostatectomy – transverse section. Within the scope of the left peripheral zone an area which is clearly demarcated from the rest of the gland is clearly visible – it is the neoplastic proliferation

secretion through the urethra and intensifies the existing ailments. The treatment of choice is creating a temporary urine outflow from the bladder towards the outside directly through the skin (cystostomy). This procedure is performed under local anesthesia under USG control with a well filled bladder. For this purpose one should use a cystostomy set consisting of a puncture needle and a pigtail catheter with a curled tip (Fig. 7 and 8).

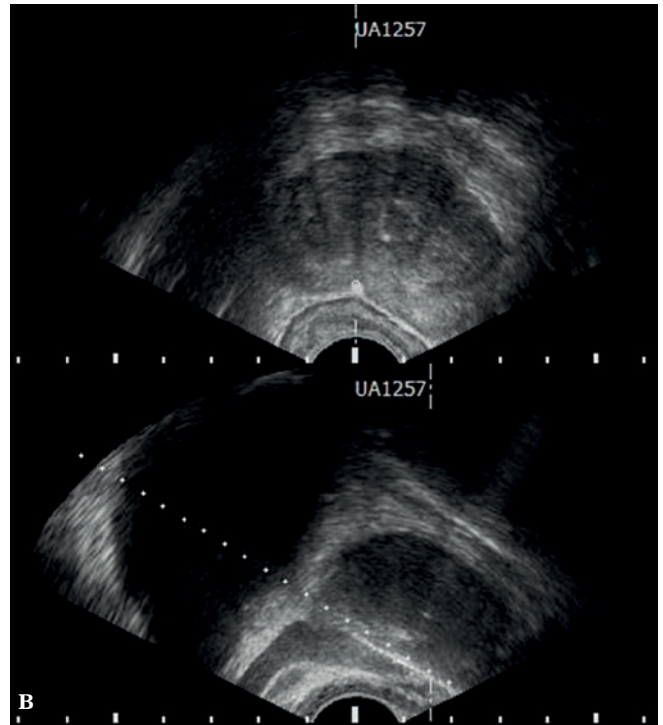
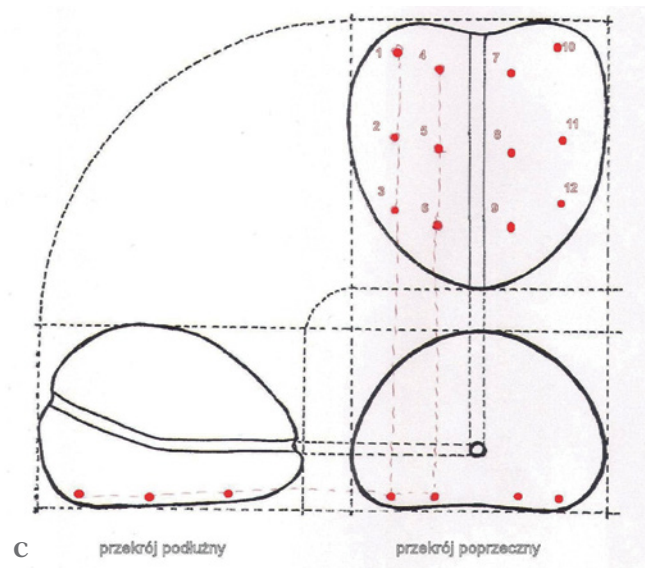
### Ultrasonography in the diagnostics and treatment of prostate neoplasms

Prostate gland cancer is the most frequently occurring neoplasm among men in the USA. In Poland it ranks second in terms of the frequency of occurrence (13%) after lung cancer (20%) and before colon cancer (12%). In the recent years an increase in the morbidity and detectability of prostate cancer can be observed. In the group of men who died at the age above 75 due to reasons other than prostate cancer, the percentage of prostate cancer in the necropsy materials varies between 50 and 75%. The increased detectability is associated with the dissemination of tests determining the level of PSA in the blood serum and with performing ultrasound examinations, especially transrectal ones (TRUS). PSA is a glycoprotein secreted by the prostate gland. The increase of the level of PSA in the blood serum is characteristic for prostate cancer. With the PSA concentration in the blood serum equal 0–1.0 ng/ml the probability of the occurrence of cancer equals 6.6%, with a concentration of 1.1–

2.0 ng/ml – 17%, with 2.1–3.0 ng/ml – 23.9%, and with 3.1–4.0 ng/ml – 26.9%. The suspicion of prostate cancer is suggested by the increase of the concentration of PSA above 4 ng/ml, however this edge value is moving up together with the age of the patient. Among men in case of who the level of PSA ranges between 4–10 ng/ml, there is a group in which cancer is not diagnosed. Due to this fact additional parameters referring to the PSA were introduced; their role is to make these examinations more specific. They are:

1. The ratio of the concentration of free PSA to total PSA (fPSA/tPSA) – the lower the value, the higher the probability of the occurrence of cancer. With f/tPSA >0.25 this probability is 8%, with f/tPSA <0.10 it is 56%. The cut-off value characteristic for cancer has not been determined, but the generally accepted values are 0.15–0.17.
2. The PSA density (PSAD) – an indicator calculated as the quotient of the PSA and the prostate volume. The higher the PSAD value, the higher the probability of the occurrence of cancer. The PSAD value in case of a negative biopsy result is 0.08–0.21 ng/ml/cm<sup>3</sup>, and in case of a positive result – 0.21–0.63 ng/ml/cm<sup>3</sup>.
3. The PSA growth rate (PSA velocity, PSAV) and the period during which the PSA value becomes doubled (*doubling time*, PSADT) – it is accepted that an annual growth of PSA equal 0.75 ng/ml and more correlates with the occurrence of cancer.
4. The predicted PSA (pPSA) – calculated as the product of the volume of the prostate and the coefficient 0.12. The value of 0.12 is the experimentally determined





**Fig. 13. A.** A transrectal probe allowing for the simultaneous observation of the prostate gland in two planes during the biopsy in real time. **B.** the image obtained during the biopsy. **C.** A scheme of the prostate and the places from which specimens are taken

amount of the PSA glycoprotein secreted by 1 g of the tissue of a healthy prostate.

The most common form of prostate cancer is adenocarcinoma occurring in the peripheral zone. The cancer frequently develops asymptotically and in case of the occurrence of symptoms at the beginning they are similar to those of benign prostatic hyperplasia and in the later period they are caused mainly by metastases to the bones and the central nervous system.

Prostate cancer may occur in the following forms: cancer limited to the organ (not exceeding the prostate capsule, without metastases), locally advanced cancer (exceeding

the prostate capsule, without metastases), diffuse (with metastases to the bones, the lymph nodes, the parenchymal organs and to the central nervous system).

Transrectal ultrasound examinations performed in patients with prostate cancer have been found to be widely applicable at every stage of the diagnostics<sup>(18)</sup>. Ultrasound examinations are performed in order to:

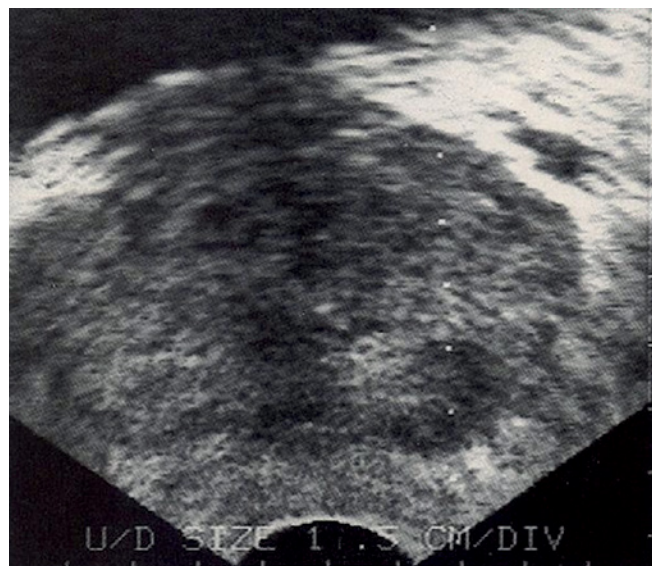
- detect the places suspected of neoplastic proliferation;
- perform biopsies from strictly defined places within the scope of the prostate gland;
- assess the local staging of cancer.

### The detection of suspected places

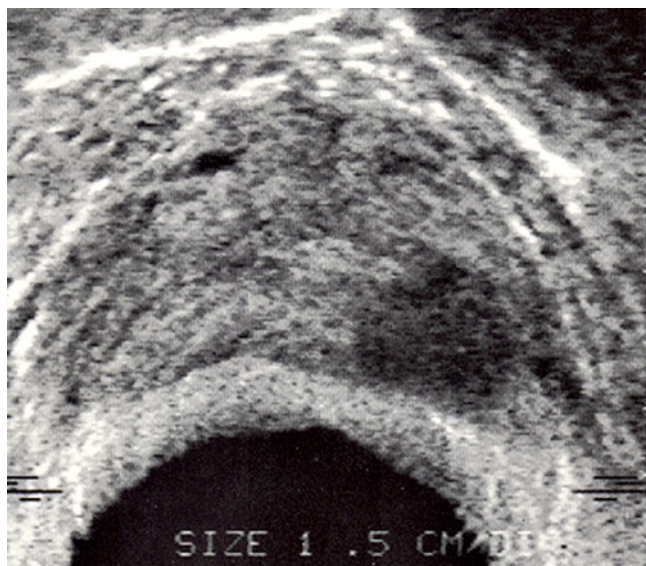
During the prostate examination performed using an endorectal transducer it is necessary to assess not only the dimensions and the configuration but also the echostructure of the particular sections of the prostate. Ultrasound diagnostics is hindered by the fact that 40% of prostate neoplasms possess an isoechogetic character.  $\frac{2}{3}$  of the prostate tumors are hypoechogetic tumors, however only  $\frac{1}{3}$  of the hypoechogetic lesions observed in the prostate are cancers. The positive diagnostic value is 30–40% (Fig. 9).



**Fig. 14.** The tru-cut needle used for prostate biopsy



**Fig. 15.** *The transrectal examination of the prostate. The lesion visible in the left lobe does not extend beyond the prostate capsule (T2)*

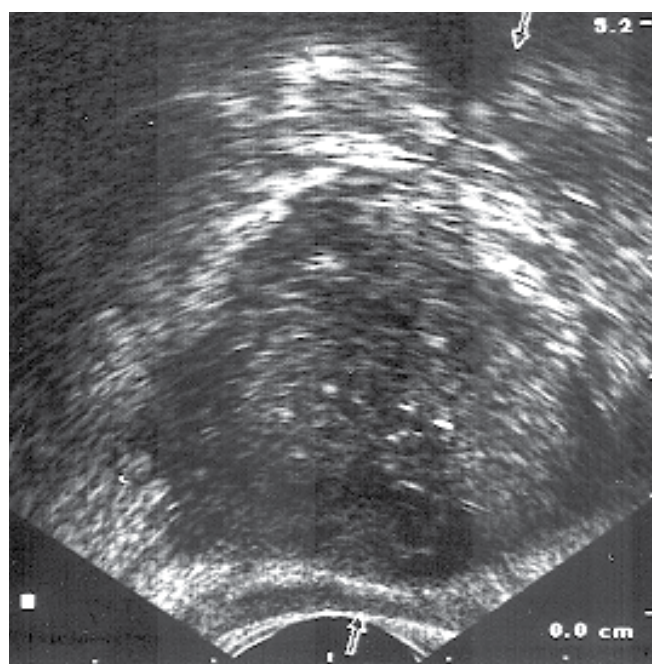


**Fig. 16.** *The transrectal examination of the prostate. The hypoechoic infiltration in the left lobe does not extend beyond the prostate capsule (T2)*

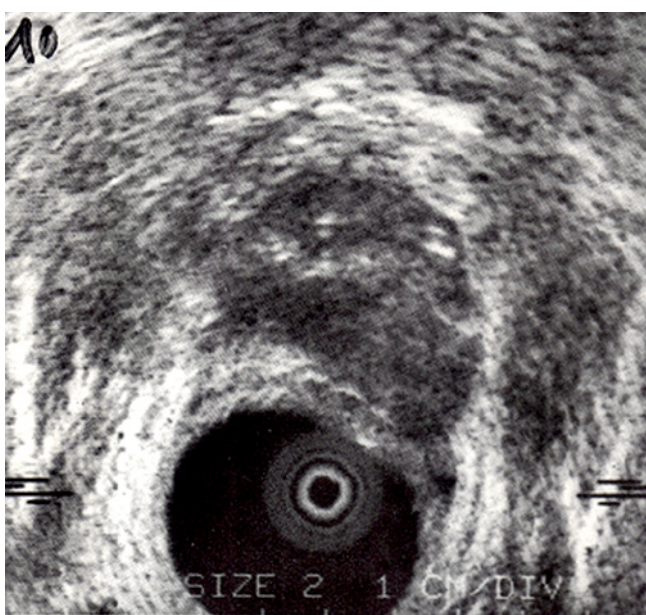
In order to increase the sensitivity and the specificity of the examination already in the 80's of the XX century a computer USG image analyzer was developed by prof. Debruyne's team. After the performing of the examination of the prostate the obtained images in the transverse section were analyzed using special computer software. The screen displayed an image of the prostate with the result inscribed in the form of a red spot which indicated the place of neoplastic proliferation. The assumption related to the computer USG image analyzer was that it was supposed to facilitate the

detecting of neoplastic lesions developing within the scope of the prostate, especially the isoechogenic ones. It was also supposed to reduce the number of false negative biopsy results and thus increase the accuracy of biopsies. In practice however, both the sensitivity and the specificity proved to be too low and the idea was never implemented.

The idea of the computer analysis of the ultrasound image was resumed at the beginning of the XXI century by developing the system called HistoScanning™. The introduction



**Fig. 17.** *The transrectal examination of the prostate. The hypoechoic infiltration developing within the scope of the peripheral zone clearly extends beyond the prostate capsule*

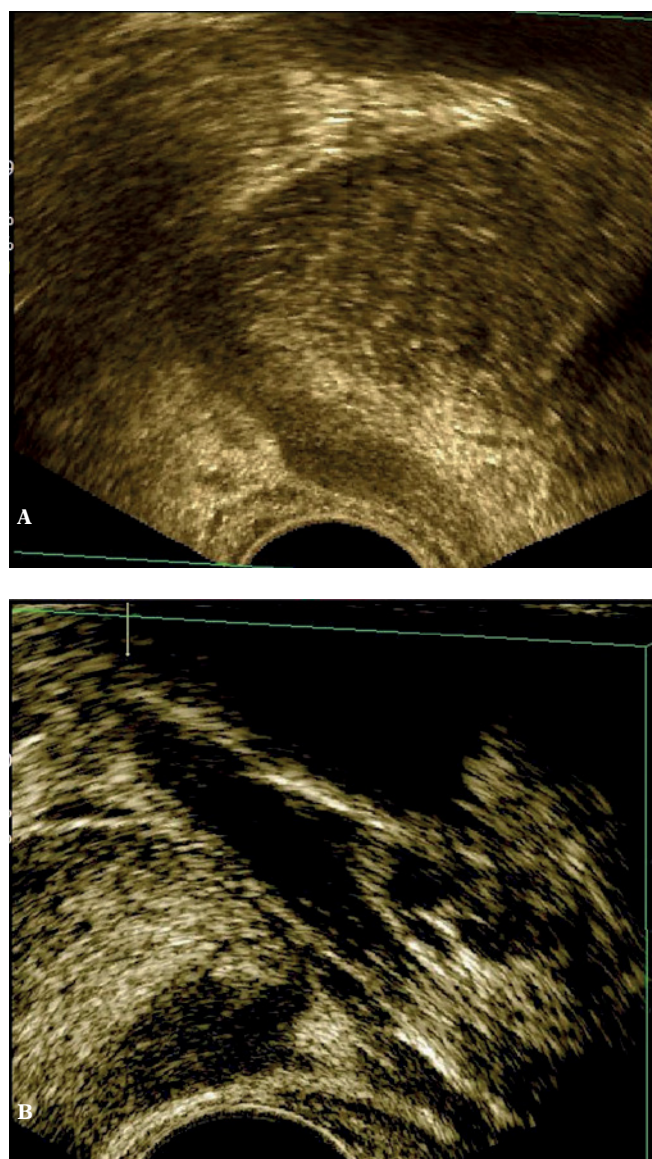


**Fig. 18.** *The transrectal examination of the prostate. A hypoechoic infiltration developing within the scope of the peripheral zone clearly extends beyond the prostate capsule and infiltrates the rectal wall (T4)*



to prostate histoscanning was performing a transrectal examination of the prostate with the 3D option. The structure of the prostate cancer tissue is specific, i.a. due to the angiogenesis within the scope of the infiltration. If such a tissue is isoechogenic in the USG image, then – despite of the fact that the human eye will not detect the difference in the architectonics between such a tissue and a healthy one – it will be detected by the computer which marks the suspected areas with colorful spots. The system is currently in the phase of research and clinical trials, therefore it is difficult to assess its sensitivity and specificity (Fig. 10)<sup>(19,20)</sup>.

The ultrasound examination with the doppler option helps to demonstrate the places suspected of focal neoplastic pro-



**Fig. 19.** The 3D transrectal USG examination: **A.** the peripheral zone on the right is hypoechoic; the infiltration extends beyond the boundaries of the prostate. **B.** the hypoechoic area on the left side of the prostate corresponds to a neoplastic infiltration; the integrity of the prostate capsule has been disrupted

liferation. The examination method of choice is the power doppler – the most sensitive examination demonstrating the flows in the blood vessels. Uncontrolled proliferation of blood vessels is found within the neoplastic tissue. This angiogenesis constitutes a feature typical for prostate cancer. Within the neoplastic proliferation the ultrasound examination performed with the application of the power doppler demonstrates an increased number of blood vessels which are tortuous and disordered (Fig. 11)<sup>(21)</sup>.

The elastographic examination allows for demonstrating places, the consistency of which is more firm than that of their surrounding. Provided that the ultrasound machine enables the performing of this examination it should be mandatorily carried out because it allows for demonstrating areas of significantly more firm consistency which may not be noticed in a classical examination. This examination increases the sensitivity of the endorectal ultrasound diagnostics of the prostate, which is especially important and useful in detecting neoplastic focuses during prostate biopsy (Fig. 12)<sup>(22–28)</sup>.

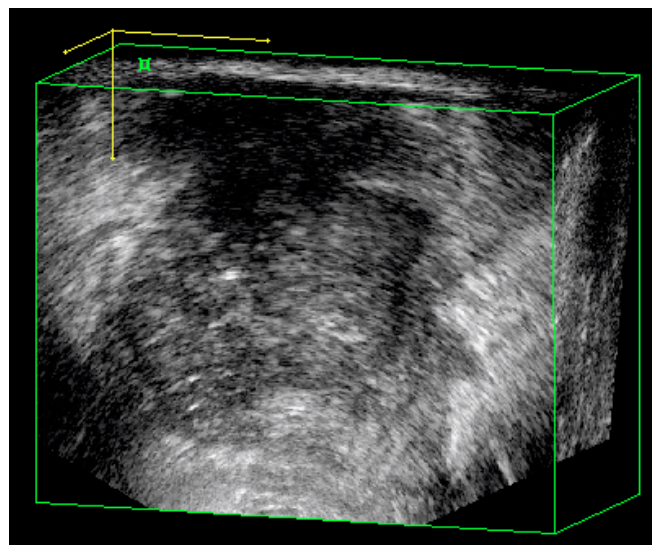
A method of improving the effectiveness of diagnosing neoplastic focuses is also the intravenous administering of an ultrasound contrast agent (e.g. SonoVue).

### Prostate gland biopsy

The treatment of prostate cancer should not be begun without a histopathological confirmation. The aim of a biopsy is obtaining valuable material on the basis of which it is possible to achieve: the histopathological diagnosis, the histological malignancy grading, the assessment of the degree of the impairment of cytoarchitectonics according to Gleason and the assessment of the local staging (T) of the neoplasm.

The patients who qualify for a biopsy are: patients with lesions found during the palpation examination performed per rectum (focal indurations within the prostatic parenchyma, clearly palpable tumors, infiltrations involving one or two lobes), patients with an elevated level of the prostate specific antigen (PSA) in the blood serum and patients with abnormalities found during transrectal ultrasonography, especially if these are patients from high-risk groups, e.g. patients who have a family history of prostate cancer<sup>(29)</sup>.

The first prostate biopsies were performed „under finger control”. In case of tumors found in the prostate such an examination usually provided good results. After the dissemination of determining the concentration of the PSA in the blood serum in a significant percentage of patients qualified for prostate biopsy no changes are found within the scope of the prostate during the palpation examination performed per rectum. In this situation it became important to ensure that biopsies are taken from precisely determined places and that such examinations are repeatable. This became possible thanks to applying endorectal transducers. The transrectal transducer presented in Fig. 14 allows for the simultaneous observation of the pros-



**Fig. 20.** The 3D transrectal USG examination. The neoplastic infiltration infiltrates the rectum (T4)

tate during a biopsy in real time in two planes: in the transverse plane and the longitudinal plane. This allows for very precise determining of the place from which the bioptic specimens are taken (Fig. 13)<sup>(30-32)</sup>.

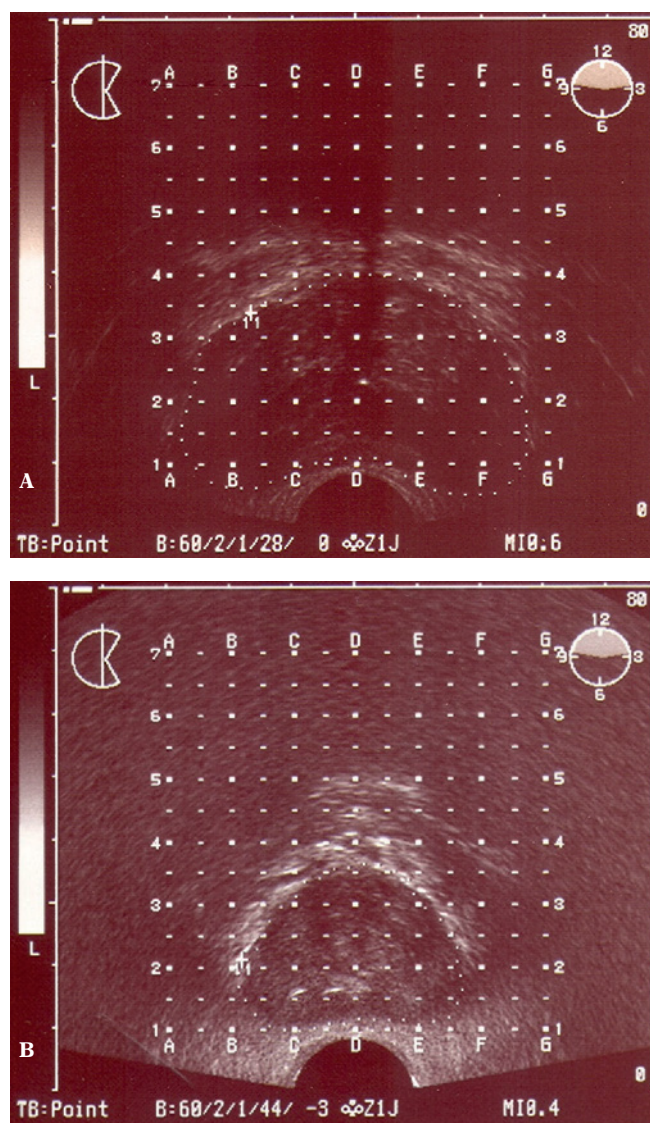
In order to perform a precise histological assessment with the histological malignancy grading and the assessment of Gleason's cytoarchitectonics it is necessary to perform a core biopsy. The material obtained in such a biopsy is histological material. The biopsy is performed using a trucut needle with a bioptic automaton (Fig. 14).

The main place of development of prostate cancer is the peripheral zone. During a mapping biopsy specimens should be taken from this zone – from the area of the base, the central part and the area of the apex. The number of the specimens depends on the size of the prostate and on which biopsy it is. Usually during the first biopsy 12 specimens are collected in a patient with a prostate of 40 cm<sup>3</sup> or smaller. A normogram has been published in which the number of specimens is strictly related to the size of the prostate<sup>(33)</sup>.

A staging biopsy consists in taking specimens from the seminal vesicles, from the area of the neurovascular bundles, from the transition zone, from the periglandular area, from the wall of the urinary bladder. It is performed when there is a suspicion of an infiltration on these structures. In 50% of cases the spread outside the prostatic capsule takes place along the neurovascular bundle, in 23% of cases – along the ejaculatory ducts and in 21% of cases – towards the fascia. The areas of anatomic weakness are: the area of the ejaculatory ducts towards the seminal vesicles, the trapezoid area in the area of the entrance of the branches of the neurovascular bundle, the apex and the base of the prostate. The features of the infiltration of the prostatic capsule are the lifting of the capsule, its blurred image and the tearing of its integrity. The thickening of the neurovascular bundle and observing

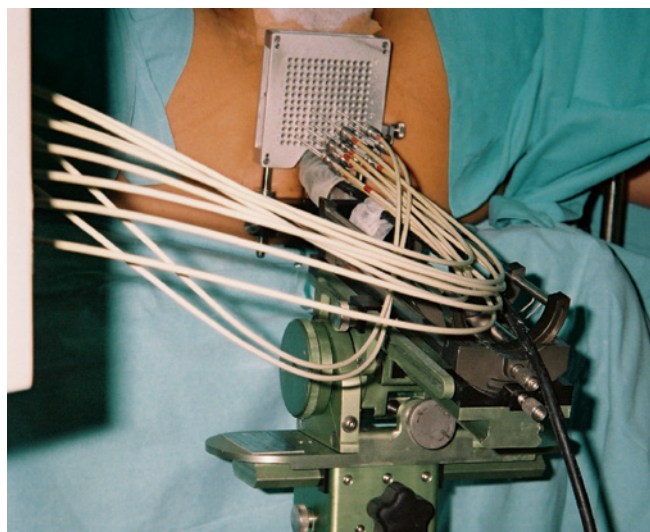
poor or not visible flow indicates the infiltration of the bundle. The features of the infiltration of the seminal vesicles are: asymmetry, enlargement of the anteroposterior dimension over 1.5 cm, their solid structure, the blurring of the angle between the vesicle and the prostate base and the displacement of the seminal vesicles to the front in such a way that the distance from the rectal wall is larger than 1 cm.

In the recent period the so called fusion guided biopsy became more common. This is related to the significant progress in the quality of examinations performed using the magnetic resonance imaging (MRI), which was made recently. Multiparametric MRI examinations performed with the application of a 3-Tesla device allow for a more accurate visualization of the structure of the prostate gland – higher sensitivity and specificity than in case of the TRUS



**Fig. 21.** The transrectal USG examination. Transverse sections of the prostate gland are visible. After the calculating of the volume and the configuration of the prostate, the puncture places of the needles with the isotope are designated





**Fig. 22.** Prostate brachytherapy (a photo taken by dr A. Wronczewski during the brachytherapy procedure). A plate with openings for needles. The points designated on the screen of the monitor correspond with the openings.

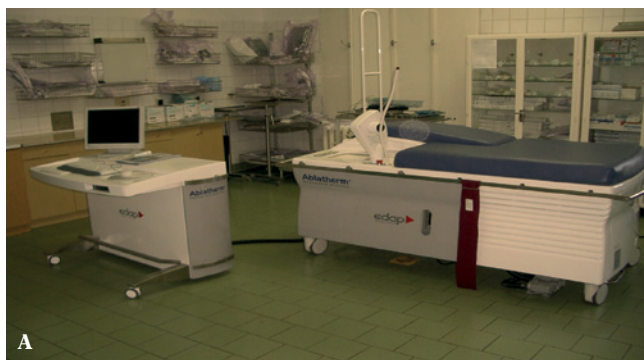images. The disposable intrarectal coil which significantly increased the cost of performing examinations using a MR 1,5 T device turned out to be redundant. In this situation software was developed and a special probe was constructed for performing biopsies under TRUS control with the application of images taken during the MR examination. In the first stage the described lesions and the contour of the prostate section are marked on the MR images taken earlier. Next the marked lesions are inscribed into the prostate contour obtained during a TRUS examination performed in real time. With ensuring appropriate experience (the accuracy of the contours in the MR images) and patience this method increases the number of positive results obtained during the biopsy of the prostate<sup>(34-37)</sup>. More modern ultrasound machines are equipped with software for automatic fusing of MR and TRUS images in real time, which significantly facilitates the taking of specimens from suspicious lesions in the prostate.

### The assessment of the advancement (staging)

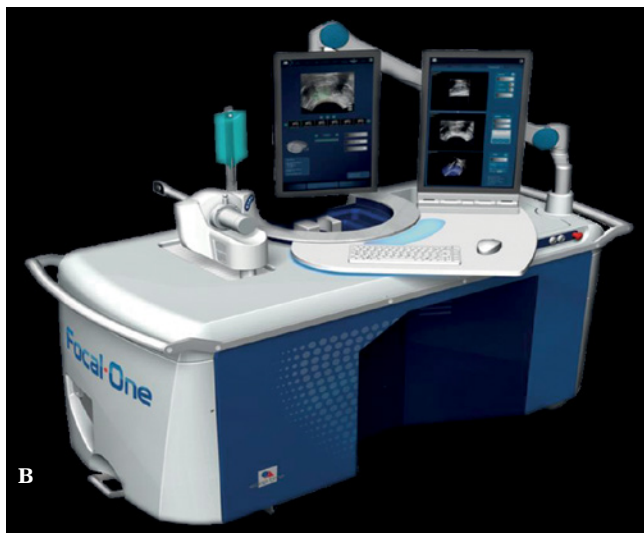The assessment of the local staging of the prostate gland cancer in the moment of diagnosing is crucial for the fur-



**Fig. 24.** A transducer containing two converters: 7.5 MHz – for the visualization of the prostate and 3 MHz – for generating a wave of high energy for destroying tissues



**A**



**B**

**Fig. 23.** Devices for performing HIFU: **A.** The older device Ablatherm; **B.** The device of a newer generation – Focal One

ther treatment of the patient. The system used for the assessment of the staging of prostate cancer is TNM, 7<sup>th</sup> edition from 2010.

The group of cancers which are assessed as T1 includes tumors which are clinically not apparent, imperceptible in palpation examinations of the prostate, not visible in imaging examinations. The neoplasms which are confined within the prostate are classified in the T2 group and those extending beyond the prostate capsule – in the T3 group (with taking into consideration the microscopic infiltration of the urinary bladder cervix – T3a, the seminal vesicles – T3b). Immobile (fixed) tumors or tumors infiltrating tissues other than seminal vesicles, e.g. the external urethral sphincter, the rectum, the levatori ani muscles or the pelvic wall are qualified in the T4 group (Fig. 15, 16, 17, 18).

Neoplasms which do not extend beyond the prostate capsule (T1 and T2) are qualified for radical treatment, however more and more radical prostatectomies are performed when the staging of the neoplasm is assessed as T3 before the surgery.

The local staging assessment before the qualification for surgery is very important. The sensitivity and the specificity of this assessment are improved by three-dimensional ultra-

sonography (USG 3D). The advantage of this type of examination over a classical endorectal ultrasound examination is based i.a. on the possibility to visualize suspected areas in various, freely chosen sections and on the fact that the examination consists of two stages. In the USG 3D examination the presence of the patient is required only during the acquisition of data (the first stage). The analysis of the images, the localization of the neoplastic infiltration, the assessment of the integrity of the prostatic capsule, the assessment of the size of the neoplastic infiltration outside the capsule takes place in front of the computer, without the presence of the patient. This way more time may be devoted to this analysis and therefore – it can be more precise (Fig. 19, 20).

Transrectal ultrasound examinations performed in patients with prostate cancer are applicable also during the treatment of this disease using the brachytherapy method and the HIFU method (*high intensity focused ultrasound*).

## Brachytherapy

Brachytherapy consists in the direct irradiation of tissues by means of radioactive isotope implants placed permanently or temporarily in the prostate gland. This allows for delivering directly into the prostate tissue a dose 2–3 times larger than during classical irradiation from external fields. This method is not new. Capsules inserted through a catheter and placed in the prostatic urethra were one of the first therapeutic applications of radioactive radium discovered in 1898 by Maria Skłodowska-Curie. For a long time however brachytherapy was very imperfect and its application was accompanied by numerous complications. Only the improvement of the methods of prostate imaging, the construction of ultrasound machines which operate in real-time with the application of transrectal transducers allowed Holm to insert iodine-125 grains in strictly defined places within the prostate in 1983. In the recent years the method of the permanent inserting of the isotope is used less frequently and instead of that more AND more often the isotope is inserted for a strictly defined period. After the preliminary transrectal examination of the prostate with the assessment of the size and the configuration, the dose of radiation which should be applied to every point within the scope of the prostate gland is calculated (Fig. 21)<sup>(38,39)</sup>.

The prostate gland is simultaneously punctured by numerous needles in strictly defined places designated by the guides. The light points in the ultrasound image correspond with these puncture points. Through particular needles the radiation source – iridium-192 – is inserted into the prostate tissue and the time of its presence there depends on the dose of radiation which needs to be taken by the prostate tissue. (Fig. 22)<sup>(20)</sup>.

## HIFU

HIFU (*high intensity focused ultrasound*) is thermal transrectal ultrasound ablation of the prostate – a procedure which is based on destroying tissue with the use of a spe-

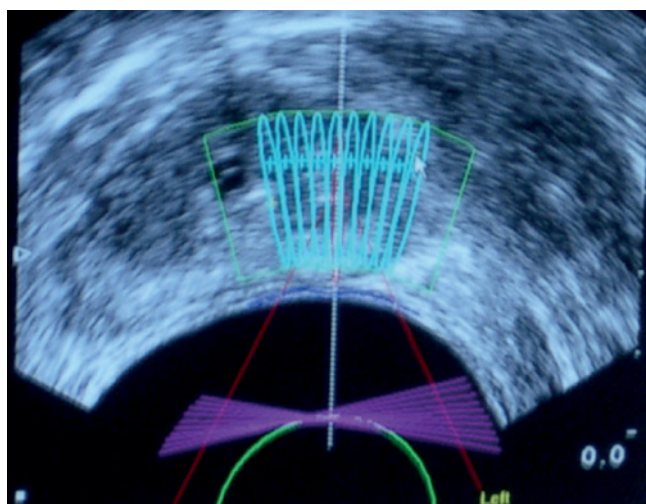
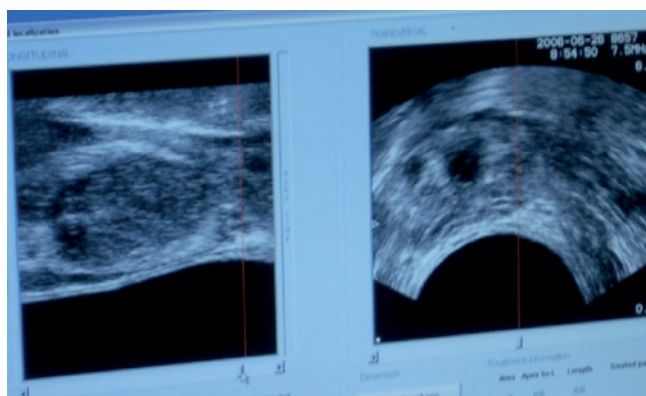
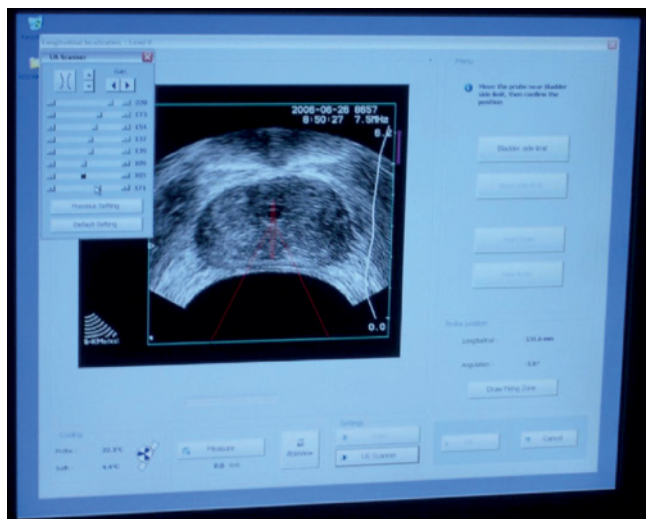

Fig. 25. The HIFU procedure preceded by precise "mapping" of the prostate gland

cially focused ultrasound wave of high energy. The ultrasound wave passes through living tissues without damaging them, however if an ultrasound beam of appropriate energy becomes concentrated then the energy within its focus causes a local increase of temperature by over 80–90°C in 2–3 seconds. Such an increase of the temperature destroys the neoplastic tissue. There is a large temperature gradient



between the irradiated focus and the surrounding tissues. The effect of this is a very clear demarcation line found in the histopathological examination. This line is present between the destroyed neoplastic lesion and the normal cells of the tissues surrounding the focus. The extent of the necrosis depends on the duration of the irradiation. It begins in the focusing point of the beam and it proceeds towards the transducer. The tissues present on the entering and exiting track of the wave are not damaged, therefore the procedures may be repeated with a small risk of damaging healthy tissues. Two companies have separately constructed devices for performing the HIFU procedures. These devices slightly differ from one another. They are: the older device Ablatherm and a device of a newer generation Focal One, both created by the French company EDAP and the device Sonoblate created by the American company Focus Surgery Inc.<sup>(40-43)</sup>

The first HIFU procedure in Poland was performed using the Ablatherm device on 27<sup>th</sup> June 2006 in the Department of General, Oncology and Paediatric Urology of the Collegium Medicum in Bydgoszcz. The indication for the procedure is prostate cancer T1–T2 N0 M0 in patients who, due to burdens from the side of the circulatory system, cannot be qualified for radical prostatectomy or who do not agree for this surgery; and supplementary treatment of patients with local recurrence after surgery, radiation therapy or brachytherapy.

The Ablatherm and Focal One devices consist of a bed, an ultrasound generator, an ultrasound targeting system, a transducer positioning system and a rectum cooling system (Fig. 23).

The transducer contains two converters: 7,5 MHz – it is used for performing visualizations of the prostate gland and localizing places which are to be destroyed and 3 MHz – which is used for generating HIFU and destroying tissues (Fig. 24).

During the procedure the patient is laying on his side under general anesthesia. The HIFU transducer is inserted into the rectum and numerous scans of the prostate gland are performed. Next the scans are analyzed at the control panel, the treatment areas are determined and these data

– inserted into the computer – are saved. The ideal gland for treatment is a prostate with a volume of 40 cm<sup>3</sup> or less. If the prostate gland is bigger, in the first stage, before the HIFU procedure, it is recommended to perform transurethral electroresection. The system has got numerous safeguards which ensure that the destruction is applied to the prostate tissue in a strictly defined area (Fig. 25). In the Focal One device there is a possibility to perform fusions of images taken during the magnetic resonance imaging MRI examination with TRUS images in real time. The possibility for performing the fusion is supposed to increase the precision of destroying the neoplastic tissue of the prostate. The procedure lasts about 3 hours. Due to the edema which is a result of the thermal effects the Foley catheter is inserted into the bladder or a suprapubic fistula is created. The catheter is maintained in the patient's body for an average of 2 weeks. The effectiveness of the treatment is checked immediately after the finishing of the procedure by the intravenous administration of SonoVue and performing an ultrasound examination of the prostate. The destroyed areas are visible in the examination as mute regions, clearly distinct from the well vascularized and well visible surrounding. Next, after 6-8 weeks the MRI examination is performed in order to confirm the size of the destroyed area of the prostate tissue.

## Conclusion

The progress in ultrasonography which has been made over the last 20 years completely changed the diagnostics of the prostate gland. Ultrasonography is useful at every stage of diagnosing, assessing the staging and planning the treatment. It is also useful during the treatment as an imaging method thanks to which it is possible to localize and destroy diseased tissues. Technological progress gives hope for further improvement of ultrasound examinations.

## Conflict of interests

*Authors do not report any financial or personal connections with other persons or organizations, which might negatively affect the contents of this publication and/or claim authorship rights to this publication.*

## Piśmiennictwo

1. Mc Neal JE: The zonal anatomy of the prostate. *Prostate* 1981; 2: 35–49.
2. Tyloch J: Ultrasonografia w diagnostyce i leczeniu chorób gruczołu krokowego. *Ultrasonografia* 2010; 10: 90–108.
3. Szopiński T, Sudol-Szopińska I: Gruczoł krokowy. In: Sudol-Szopińska I, Szopiński T (eds.): Diagnostyka ultrasonograficzna w urologii. Roztoczańska Szkoła Ultrasonografii, Warszawa–Zamość 2007: 94–128.
4. Tyloch J: Badanie usg przezbrzuszne gruczołu krokowego. In: Jakubowski W (ed.): Standardy badań ultrasonograficznych Polskiego Towarzystwa Ultrasonograficznego. Roztoczańska Szkoła Ultrasonografii, Warszawa–Zamość 2008: 161–162.
5. Tyloch J: Badanie usg pęcherza moczowego. In: Jakubowski W (ed.): Standardy badań ultrasonograficznych Polskiego Towarzystwa Ultrasonograficznego. Roztoczańska Szkoła Ultrasonografii, Warszawa–Zamość 2008: 159–160.
6. Tyloch J: Przydatność badania ultrasonograficznego do pomiaru pojemności pęcherza moczowego i oceny ilości zalegającego moczu – porównanie dokładności kilkunastu sposobów pomiaru. *Ultrasonografia* 2002; 2: 86–91.
7. Tyloch J: Własna metoda pomiaru pojemności pęcherza moczowego i oceny ilości zalegającego moczu. *Ultrasonografia* 2002; 2: 92–96.
8. Tyloch J: Ocena dokładności własnej metody pomiaru pojemności pęcherza moczowego i zalegania moczu u chorych z asymetrycznym, niekształtnym pęcherzem moczowym. *Ultrasonografia* 2002; 2: 97–100.
9. Tyloch J, Wołski Z, Szerstobitow B, Jakubowski W: Pomiary pojemności pęcherza moczowego i ocena objętości zalegającego moczu po mikcji za pomocą aparatu BladderScan™ BVI 6000. *Ultrasonografia* 2005; 21: 88–93.
10. Tyloch J, Wołski Z, Kobajło C: Evaluation of PINIT Echson Bladder Scanner use to measure the capacity of urinary bladder and evaluate the volume of urine retained following micturition. EAU 12<sup>th</sup> Central European Meeting (CEM), Dresden, Germany, 12–13 October 2012. *Eur Urol Suppl* 2012; 11: 117–118.

11. Tyloch J: Badanie usg gruczołu krokowego głowicą doodbytniczą. In: Jakubowski W (ed.): Standardy badań ultrasonograficznych Polskiego Towarzystwa Ultrasonograficznego. Roztoczańska Szkoła Ultrasonografii, Warszawa–Zamość 2008: 163–165.
12. Watanabe H, Saitoh M, Mishina T, Igari D, Tanahashi Y, Harada K *et al.*: Mass screening program for prostatic diseases with transrectal USG. *J Urol* 1977; 117: 746–748.
13. Bożiłow W, Tyloch J, Tyloch F, Sawicki K, Góralczyk K, Wronecowski A *et al.*: Ultrasonograficzne badania wymiarów stercza. *Ultrasonografia Polska* 1995; 5: 9–19.
14. Tyloch F, Tyloch J: Porównanie dwóch sposobów ultrasonograficznego pomiaru wielkości gruczołu krokowego. Program 23. Zjazdu Naukowego Polskiego Towarzystwa Urologicznego, Szczecin 14–16 września 1993. Streszczenie: *Urologia Polska*; 46 (Suppl. 47–48): 25.
15. Tyloch J: Diagnostyka usg chorób zapalnych nerek, pęcherza moczowego, stercza i moszny – punkt widzenia urologa. Część 3: Choroby zapalne gruczołu krokowego. *Ultrasonografia* 2009; 37: 90–95.
16. Tyloch J, Wolski Z, Drewa T: Three-dimensional ultrasonography (3D USG) administration in evaluation antibiotic distribution given intraprostatic injection during chronic prostatitis. EAU 3<sup>rd</sup> North Eastern European Meeting (NEEM), Szczecin 11–12 September 2009. *Eur Urol Suppl* 2009; 8: 588.
17. Tyloch J, Tyloch D, Wolski Z: Assessment of the distribution of intraprostatic antibiotic injections in chronic prostatitis using three-dimensional ultrasound (3D TRUS) – nine years' experience. 4<sup>th</sup> Meeting of the EAU Section of Urological Imaging (ESUI), Barcelona, 12–15 November 2015. *Eur Urol Suppl* 2015; 14: 227.
18. Marko J, Gould CF, Bonavia GH, Wolfman DJ: State-of-the-art imaging of prostate cancer. *Urol Oncol* 2016; 34: 134–146.
19. Kuru TH, Fütterer JJ, Schiffmann J, Porres D, Salomon G, Rastinehad AR: Transrectal ultrasound (US), contrast-enhanced US, real-time elastography, HistoScanning, magnetic resonance imaging (MRI), and MRI-US fusion biopsy in the diagnosis of prostate cancer. *Eur Urol Focus* 2015; 1: 117–126.
20. Simmons LAM, Ahmed HU, Moore CM, Punwani S, Freeman A, Hu Y *et al.*: The picture study – prostate imaging (multi-parametric MRI and prostate HistoScanning™) compared to transperineal ultrasound guided biopsy for significant prostate cancer risk evaluation. *Contemp Clin Trials* 2014; 37: 69–83.
21. Nelson ED, Slotoroff CB, Gomella LG, Halpern E: Targeted biopsy of the prostate: the impact of color Doppler imaging and elastography on prostate cancer detection and Gleason score. *Urology* 2007; 70: 1136–1140.
22. Szopiński T, Nowicki A, Záfura F, Gołąbek T, Chłosta P: Nowe trendy w obrazowaniu raka stercza metodą ultrasonografii przezodbytniczej. *J Ultrason* 2014; 14: 306–319.
23. Schiffmann J, Grindei M, Tian Z, Yassin D-J, Steinwender T, Leyh-Bannurah S-R: Limitations of elastography based prostate biopsy. *J Urol* 2016; 195: 1731–1736.
24. Woo S, Kim SY, Lee MS, Cho JY, Kim SH: Shear wave elastography assessment in prostate: an intraobserver reproducibility study. *Clin Imaging* 2015; 39: 484–487.
25. Koh J, Jung DC, Oh YT, Yoo MG, Noh S, Han KH *et al.*: Additional targeted biopsy in clinically suspected prostate cancer: prospective randomized comparison between contrast-enhanced ultrasound and sonoelastography guidance. *Ultrasound Med Biol* 2015; 41: 2836–2841.
26. Zhang B, Ma X, Zhan W, Zhu F, Li M, Huang J *et al.*: Real-time elastography in the diagnosis of patients suspected of having prostate cancer: a meta-analysis. *Ultrasound Med Biol* 2014; 40: 1400–1407.
27. Barr RG: Elastography in clinical practice. *Radiol Clin North Am* 2014; 52: 1145–1162.
28. Correas JM, Tissier AM, Khairoune A, Khoury G, Eiss D, Helenon O: Ultrasound elastography of the prostate: state of the art. *Diagn Interv Imaging* 2013; 94: 551–560.
29. Senkus-Konefka E, Antoniewicz A, Borkowski A, Borówka A, Demkow T, Dobruch J *et al.*: Zalecenia dotyczące postępowania w raku gruczołu krokowego – konferencja okrągłego stołu. *Onkologia w Praktyce Klinicznej* 2007; 3: 103–119.
30. Antoniewicz A (ed.): Biopsja stercza. *Urologia Praktyczna*. Komitet Edukacji Polskiego Towarzystwa Urologicznego 2002.
31. DiBianco JM, Mullins JK, Allaway M: Ultrasound guided, freehand transperineal prostate biopsy: an alternative to the transrectal approach. *Urology Practice* 2016; 3: 134–140.
32. Tyloch J: Ultrasonografia zabiegowa w urologii. In: Jakubowski W (ed.): Standardy badań ultrasonograficznych Polskiego Towarzystwa Ultrasonograficznego. Roztoczańska Szkoła Ultrasonografii, Warszawa–Zamość 2008: 171–173.
33. Szepliński S, Modzelewska E, Dzik T, Dobruch J, Borówka A: Gęstość wielomiejscowej biopsji mappingowej stercza wykonywanej pod kontrolą ultrasonografii przezodbytniczej u mężczyzn, u których podejrzewa się raka jedynie na podstawie podwyższenia stężenia swoistego antygenu sterczowego w surowicy. *Przegląd Urologiczny* 2010; 62: 48–51.
34. Hansen N, Patruno G, Wadhwa K, Gaziev G, Miano R, Barrett T *et al.*: Magnetic resonance and ultrasound image fusion supported transperineal prostate biopsy using the ginsburg protocol: technique, learning points and biopsy results. *Eur Urol* 2016; 70: 332–340.
35. Ghai S, Eure G, Fradet V, Hyndman ME, McGrath T, Wodlingert B *et al.*: Assessing cancer risk on novel 29 MHz micro-ultrasound images of the prostate: creation of the micro-ultrasound protocol for prostate risk identification. *J Urol* 2016; 196: 562–569.
36. Han M, Chang D, Kim C, Lee BJ, Zuo Y, Kim H-J *et al.*: Geometric evaluation of systematic transrectal ultrasound guided prostate biopsy. *J Urol* 2012; 188: 2404–2409.
37. Scattoni V, Zlotta A, Montironi R, Schulman C, Rigatti P, Montorsi F: Extended and saturation prostatic biopsy in the diagnosis and characterization of prostate cancer: a critical analysis of the literature. *Eur Urol* 2007; 52: 1309–1322.
38. Yan P, Cheeseborough JC 3<sup>rd</sup>, Chao KSC: Automatic shape-based level set segmentation for needle tracking in 3-D TRUS-guided prostate brachytherapy. *Ultrasound Med Biol* 2012; 38: 1626–1636.
39. Wolski Z: Brachyterapia raka gruczołu krokowego. *Przegląd Urologiczny* 2002; 6: 26–33.
40. Rouviere O, Souchon R, Salomir R, Gelet A, Chapelon JY, Lyonnet D: Transrectal high-intensity focused ultrasound ablation of prostate cancer: Effective treatment requiring accurate imaging. *Eur J Radiol* 2007; 63: 317–327.
41. Asimakopoulos AD, Miano R, Virgili G, Vespasiani G, Agro EF: HIFU as salvage first-line treatment for palpable, TRUS-evidenced, biopsy-proven locally recurrent prostate cancer after radical prostatectomy: a pilot study. *Urol Oncol* 2012; 30: 577–583.
42. Wolski Z, Rożnowski K: Termiczna przezodbytnicza ablacja ultradźwiękowa stercza (HIFU) – pierwsze zabiegi w Polsce. *Przegląd Urologiczny* 2006; 6: 7.
43. Tyloch J, Rożnowski K, Tyloch D, Gelet A, Wolski Z: Innovative technique of transrectal, high-intensity focused ultrasound ablation of prostate gland using „Focal One” device in patients with organ confined prostate cancer. EAU 14th Central European Meeting, Kraków, 10–12 October 2014. *Eur Urol Suppl* 2014; 13: 1308.