

Available online at www.sciencedirect.com

journal homepage: www.elsevier.com/locate/radcr

Case Report

MRI diagnosis of Takayasu arteritis in a young woman [☆]

Kreshnike Dedushi, MD, PHD^a, Fjolla Hyseni, MD^b, Juna Musa, MD^c, Masum Rahman, MD^d, Kristi Saliqaj, MD^e, Valon Vokshi, MD^f, Jeton Shatri, MD, PHD^a, Abu Bakar Siddik, MD^g, Eram Ahsan, MD^h, Samar Ikram, MD^d, Blina Abdullahu, MD^{a,i}, Serbeze Kabashi, MD, PHD^{a,*}, Ali Guy, MD^j, Mehmet Sahin Ugurel, MD, PHD^k

^a Clinical of Radiology, University Clinical Center of Kosovo, Pristina, Kosovo

^b Medical Researcher, NYU Langone Health, New York, USA

^c Department of General Surgery, Mayo Clinic, Rochester, MN, USA

^d Department Neurological surgery, Mayo Clinic, Rochester, MN, USA

^e Mother Teresa Hospital, Tirana, Albania

^f Department of Anesthesiology, University Clinical Center of Kosovo, Pristina, Kosovo

^g Department of Pain Medicine, Mayo Clinic, Jacksonville, FL, USA

^h Stem Cell Therapy and Skeletal Regeneration Lab, Mayo Clinic, Rochester, MN, USA

ⁱ Mother Teresa Hospital, Tirana, Albania

^j Clinical Assistant Professor, Department of Physical Medicine and Rehabilitation, New York University School of Medicine, NYU Medical Center, New York, USA

^k Department of Radiology, Gülhane Military Medical Academy, Ankara, Turkey

ARTICLE INFO

Article history:

Received 2 September 2021

Revised 14 September 2021

Accepted 15 September 2021

Keywords:

Takayasu's Arteritis

MRI

Inflammation

Aorta

ABSTRACT

Takayasu arteritis is a rare type of chronic, granulomatous vasculitis, characterized by inflammation of blood vessels of large caliber, such as the aorta, and its branches. Clinical presentation varies, depending on the severity of symptoms. Onset may be gradual, however at times, presentation may be acute, and life threatening. Herein, we present the case of a 29-year-old female, 3 months post-op, following a right carotid artery stenting procedure. The patient presented with nonspecific symptoms of malaise, arthralgia, and blurry vision. Clinical presentation and imaging findings were consistent with Takayasu's Arteritis.

© 2021 The Authors. Published by Elsevier Inc. on behalf of University of Washington.

This is an open access article under the CC BY-NC-ND license (<http://creativecommons.org/licenses/by-nc-nd/4.0/>)

[☆] Competing Interests: The authors declare that they have no conflict of interest.

* Corresponding author.

<https://doi.org/10.1016/j.radcr.2021.09.030>

1930-0433/© 2021 The Authors. Published by Elsevier Inc. on behalf of University of Washington. This is an open access article under the CC BY-NC-ND license (<http://creativecommons.org/licenses/by-nc-nd/4.0/>)

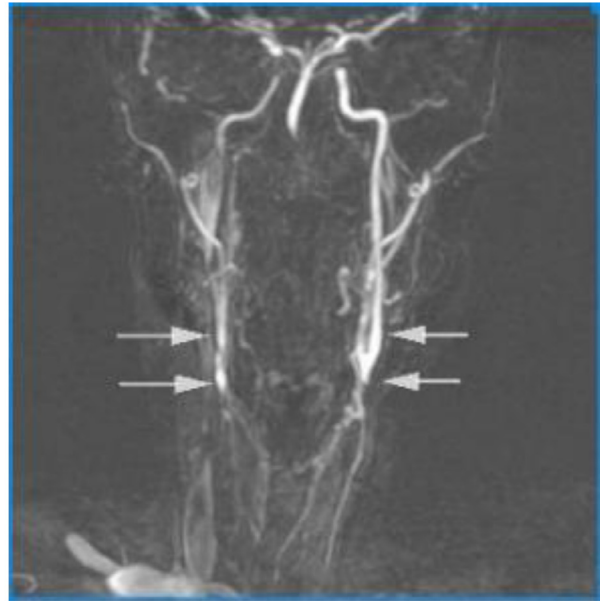
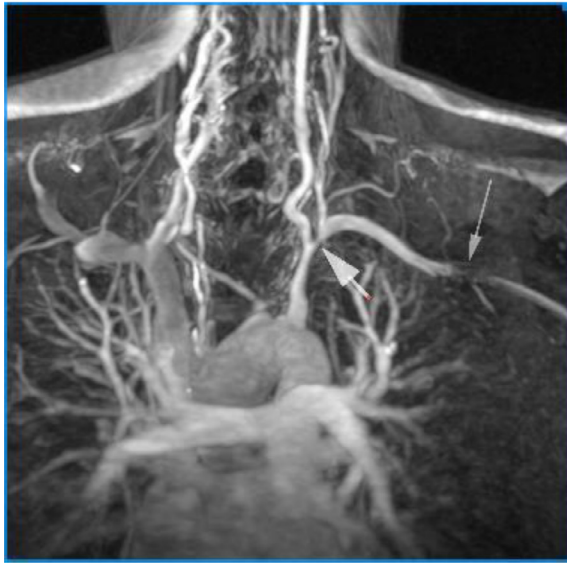


Fig. 1 – Angio MRI thoracic aorta presenting: 2 stenoses at the left subclavian artery (proximally around the origin of the left vertebral artery (thick arrows) and distally at the junction of the left axillary artery (arrowhead). In addition, diffuse narrowing of the brachiocephalic trunk that continues with the right subclavian artery, without giving off the totally occluded right common carotid artery is noted (thin arrows). Ostium of the right vertebral artery is stenotic. Neck MRA shows bilateral occlusion of the common carotid arteries, which fill with contrast via collaterals at their carotid bifurcation levels (arrows). Filling of the cervical internal carotid artery is still not satisfactory on the right side.

Introduction

Takayasu's arteritis (TA) is a chronic, granulomatous, large-vessel systemic vasculitis of unknown etiology [1]. It poses a serious diagnostic challenge and is associated with delayed diagnosis, due to the lack of specific laboratory test, biomarkers or autoantibodies. Difficulties arise in determining the disease activity when establishing the diagnosis, as well as in periods of relapse.

As a rule, prevalence is higher among young females, however, there have also been reported cases in older patients [1,2]. Ethnicity significantly impacts the prevalence of TA as well as its severity and prognosis. People of Far Eastern and Asian descent are more prone to developing TA, while the condition is less frequent in northern Europe and the US [1].

Classic manifestations of TA include stenosis, occlusion, and often aneurysms of the aorta and its branches, notably the subclavian, common carotid, and internal carotid arteries [1]. Clinical presentation differs depending on the severity of the inflammation and the arteries that are affected. Although TA generally has a gradual onset, it can occasionally manifest with unusual and/or life-threatening symptoms, such as sudden vision loss or stroke. TA is commonly classified into 3 distinct phases [3]. Nonspecific constitutional inflammatory symptoms are present in the early phase [3]. Transmural inflammation affecting major arteries, in the second phase, gives rise to carotidynia (neck pain) and occasionally thoracic and dorsal pain [3]. The third phase is characterized by reduced or absent pulses, as well as variations in arterial

blood pressure between the upper and lower extremities, arterial bruits, and intermittent limb claudication [3].

Case presentation

A 29-year-old female patient is referred to the Radiology Department for a Magnetic Resonance Angiography (MRA) of the neck, chest, and abdomen. The patient is 3 months post-op, following a right carotid artery stenting procedure. The patient presented at first, with a history of unspecific symptoms including generalized fatigue, malaise and arthralgia, weight loss, visual disturbances, trouble concentrating and high blood pressure associated with a difference in blood pressure between arms. Following a Doppler ultrasound, a diagnosis of severe stenosis of the right carotid artery was established. The patient underwent a successful stenting procedure. No complications arose during the post-op period, and she was subsequently referred to the Radiology Department for additional imaging.

The neck MRA revealed critical stenosis of the brachiocephalic trunk (string sign) and complete occlusion of the right common carotid artery from its origin all throughout its cervical segments. The right internal carotid artery was also occluded with a weak contrast filling visible in the upper cervical segments and intracranial segments alone.

Reduced contrast filling in the congenitally hypoplastic right vertebral artery, as opposed to the dominant left vertebral artery, showed multiple foci of stenosis throughout its

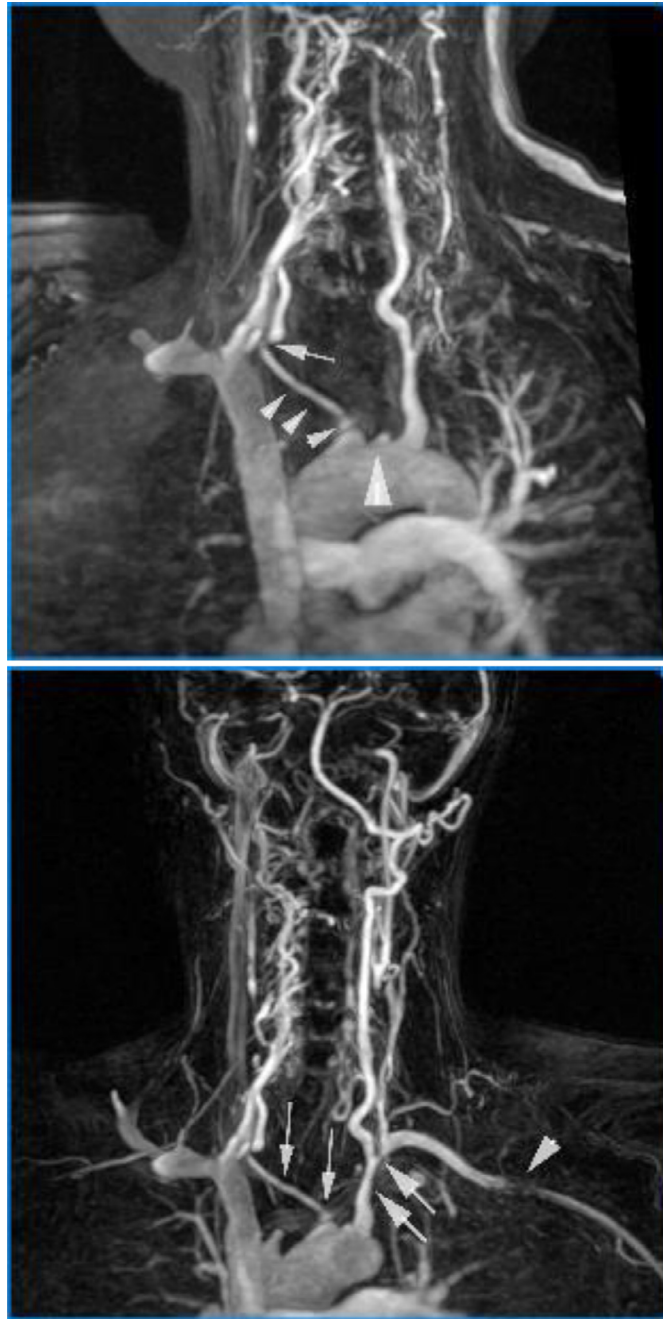

Fig. 2 – Neck MRA stump of the completely occluded left common carotid artery is noted, as it exits from aortic arch (large arrowhead). In addition, diffuse narrowing of the brachiocephalic trunk that continues with the right subclavian artery, without giving off the totally occluded right common carotid artery is noted (small arrowheads). Proximally, the brachiocephalic trunk is stenotic. Ostium of the right vertebral artery is also stenotic (arrow).

cervical and intracranial branches (Fig. 1). Hence, it was concluded that the dominant left vertebral artery was responsible for most of the basilar artery flow supply. The left vertebral artery contrast filling was altogether normal, including a normal ostium, normal cervical and intracranial segments, with a slightly enlarged diameter up to 5-6 mm. This likely represents a compensatory hypertrophy, since the left vertebral artery may potentially be the main blood supplier to the

ipsilateral and contralateral occluded cervical arteries, via an extensive collateral network.

The neck MRA also showed a severe occlusion of the left common carotid artery in the entirety of the segment from its origin up to the carotid artery bifurcation (Fig. 1 and Fig. 3). Normal contrast filling was evident throughout the left carotid artery and its related branches, due to the presence of rich collaterals. A 40% stenosis affecting a long segment of the prox-

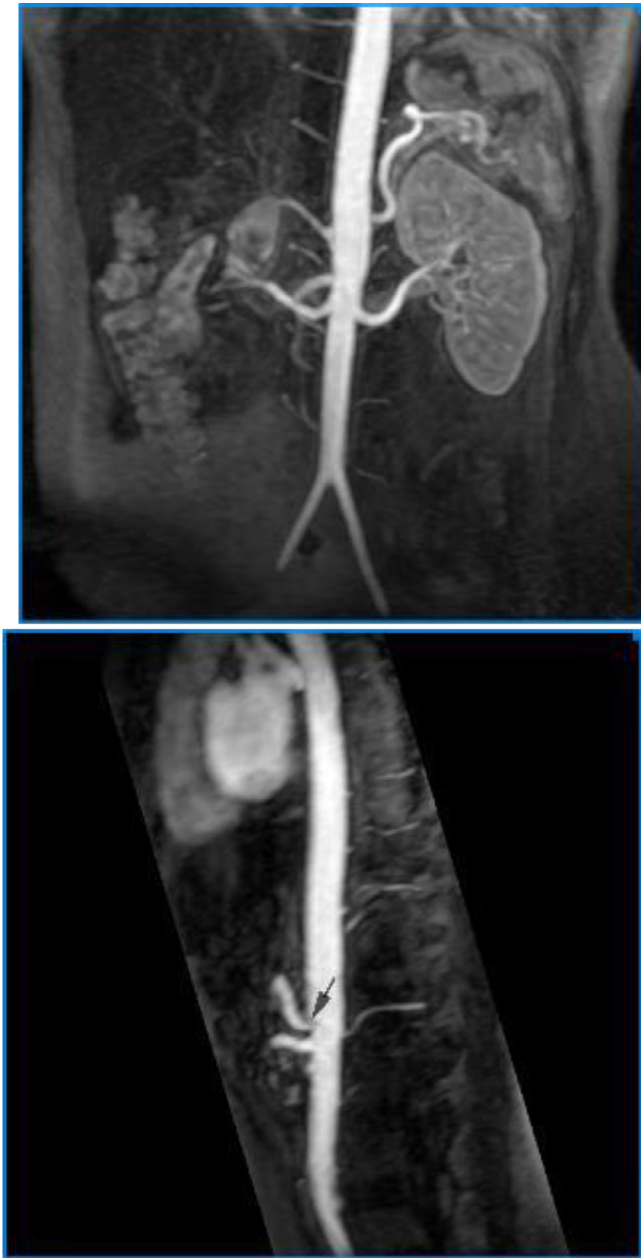

Fig. 3 – Angio MRI of abdominal aorta and renal arteries don't seem to be affected much, except for a mild narrowing at the origin of the celiac artery (black arrow).

imal left subclavian artery, up to the origin of the left vertebral artery was noticeable, in addition to a focal stenosis of approximately 80%, immediately adjacent to the origin of the left vertebral artery (Fig 1 and Fig. 3). A 50%-90% segmental stenosis of the left subclavian artery about 5 cm distal to its origin was also evident, however, the precise severity of the occlusion could not be correctly identified due to a number of artifacts (Fig. 1 and Fig. 3).

The ascending aorta, aortic arch, and descending aorta were normal (21 mm, 23 mm, and 17 mm respectively). A mild, but non-specific stenosis at the mid-thoracic level of the descending aorta (13 mm) was present. Aortic walls were normal with no evidence of intimal flap, dissection, or aneurys-

mal dilatation. The abdominal aorta, celiac trunk, superior mesenteric artery, along with both renal arteries presented with normal dimensions, and no evidence of structural alterations (Fig. 3).

Overall, imaging findings were most consistent with Takayasu's arteritis, further supported by the patient's age, sex, and clinical presentation.

Discussion

Takayasu's arteritis (TA) is a granulomatous, idiopathic large-vessel arteritis that primarily affects the aorta, its major branch arteries, and (less frequently) the pulmonary arteries [1]. It is a chronic inflammatory disease that causes increased arterial wall thickness, fibrosis, stenosis, aneurysmal development or dilatation, and thrombosis. In 6%-30% of TA cases, coronary arteries are affected as well, with the right coronary artery being the predominantly affected one [4]. The disease commonly involves the entire aorta and its main branches above and below the diaphragm. The subclavian artery (Left > Right), common carotid (Left > Right), renal, vertebral, and innominate arteries are the most typically affected [1]. Our patient presented with a severe occlusion of the left common carotid artery in the entirety of the segment from its origin, up to the carotid artery bifurcation.

TA affects both men and women of all ages and ethnic backgrounds. However, the majority of patients are in their third decade of life, and 90% of them are women [2]. In our case, the patient was a 29-year-old female. TA is recognized to have a complex genetic component to its etiology. High-resolution genomic techniques have pinpointed the link as the HLA-B*52:01 allele, the only HLA-B allele with genome-wide significance for the disease [3]. HLA-B52 has been found to have the strongest connection in Japanese and other populations. Japanese patients with HLA-B52 positive allele seem to carry a worse prognosis. Pro-inflammatory cytokines like IL-6, IL-12, and IL-18 are thought to play a role in the disease's development [1]. Acute phase reactant (C-reactive protein) and erythrocyte sedimentation rate (ESR) are common laboratory assays, but they are not specific for TA.

Clinical presentation of TA varies, depending on the stage of the disease. Non-specific systemic symptoms predominate for weeks or months during the early, active inflammatory phase. Ischemia and symptoms related to arterial obstruction define the late, chronic phase (the "pulseless" stage) [3]. Systemic hypertension may be linked to an increased risk of arterial wall dissection, a rare but life-threatening complication seen more frequently in children than adults with TA. Over half of patients have a blood pressure difference of more than 10 mm Hg (which is a categorization criteria) and bruits over the aorta and its major branches. The ocular signs of TA usually occur after a carotid artery occlusion or severe stenosis, and they usually present late in the course of the disease [1]. The diagnosis of TA is challenging. Anatomic involvement, clinical symptoms, and prognosis all play a role in determining the diagnosis of TA [2]. Imaging modalities assist in determining the definitive diagnosis, as well as in monitoring disease activity. When assessing TA, MRA has a high

level of accuracy and sensitivity, mainly when the lesions are in the aorta. It is non-invasive, requires no iodinated contrast load or radiation, and can offer high-resolution images of the arterial wall architecture (thickness, edema, and contrast enhancement) on most vessels during active, inflammatory phases. Diffusion-weighted MRI could be a helpful way to detect vascular inflammation and distinguish between active and inactive arterial lesions. CTA has a higher resolution and produces images with excellent anatomic detail in 3D reconstruction. MRA and CTA both produce cross-sectional artery wall images and allow for the detection of intramural inflammation. They both have high specificity and sensitivity for disease diagnosis and treatment. Color Doppler ultrasound (US) can detect thrombosis and aneurysms, especially in the carotid arteries, and offers information about the morphology of the vessels [1]. Angiography is the gold standard for diagnosis when symptoms lead to clinical suspicion of TA. Computed tomography angiography (CTA) is increasingly being used because it allows for the evaluation of wall inflammation. Recent, more favorable approaches include NMR (nuclear magnetic resonance) angiography and 18F fluorodeoxyglucose positron emission tomography (18F FDG-PET), which aid in diagnosing TA even in the pre-stenotic phase by detecting structural wall alterations [2].

TA is treated with glucocorticoids (GCs), which are the first-line therapy. They are typically associated with adverse effects when used long-term, and patients frequently relapse during GC tapering [2]. Immunosuppressants such as cyclophosphamide, azathioprine, or methotrexate may be required in other cases. It is critical to treat associated symptoms simultaneously [2]. In patients who do not respond to conventional immunosuppressive regimens, novel therapeutic options, particularly the use of biological agents such as anti-tumor necrosis factor (TNF-), rituximab (RTX), and tocilizumab (an inhibitor of interleukin 6 receptor IL-6R), have shown promising results. The efficacy of this approach has recently been tested in randomized controlled trials [5]. Data shows that symptoms may persist in some cases, requiring surgical intervention, including endovascular revascularization procedures. Despite numerous studies demonstrating the benefits of surgery in treating stenosis, these procedures have a significant failure rate, mainly when performed during an active inflammatory period [2].

Conclusion

Given studies that suggest that TA predominantly affects women, our 29-year-old female presents with classic nonspecific symptoms. The patient was started on glucocorticoids as a first-line empiric therapy, but close monitoring, and follow up is crucial in determining whether monotherapy with glucocorticoids will suffice. Obtaining a good clinical history and appropriate diagnostic tests, particularly imaging examinations as safe, non-invasive, highly sensitive, and specific diagnostic modalities, are imperative to establish a definitive diagnosis and evaluate the progression of the inflammation.

Patient consent statement

Written informed consent for publication was obtained from the patient.

REFERENCES

- [1] Russo Ricardo AG, Katsicas MM. Takayasu arteritis. *Front Pediatr* 2018;6:265. doi:10.3389/fped.2018.00265.
- [2] Nakaoka Y, Isobe M, Takei S, Tanaka Y, Ishii T, Yokota SH, et al. Efficacy and safety of tocilizumab in patients with refractory Takayasu arteritis: results from a randomised, double-blind, placebo-controlled, phase 3 trial in Japan (the TAKT study). *Ann Rheum Dis* 2018;77(3):348–54. doi:10.1136/annrheumdis-2017-211878.
- [3] Renauer Paul, Sawalha AH. The genetics of Takayasu arteritis. *Presse Med* 2017;46(7-8):e179–87. doi:10.1016/j.lpm.2016.11.031.
- [4] Seyahi Emire. Takayasu arteritis: an update. *Curr Opin Rheumatol* 2017;29(1):51–6. doi:10.1097/BOR.0000000000000343.
- [5] Akkececi NS, Cetin GY, Gogebakan H, Acipayam C. The C-reactive protein/albumin ratio and complete blood count parameters as indicators of disease activity in patients with takayasu arteritis. *Med Sci Monit* 2019;25:1401–9. doi:10.12659/MSM.912495.