




## CASE REPORT

# Repair of iatrogenic pulmonary vein occlusion with a vascularized atrial flap

Raphaelle A. Chemtob<sup>1</sup>  | Michael Smith<sup>2</sup> | Umur Hatipoglu<sup>3</sup> | Kevin Edward Hodges<sup>1</sup>  | Alan Marc Gillinov<sup>1</sup>  | Dermot Phelan<sup>4</sup> | Gösta Bengt Pettersson<sup>1</sup> | Per Wierup<sup>1</sup>

<sup>1</sup>Department of Thoracic and Cardiovascular Surgery, Cleveland Clinic, Cleveland, OH, USA

<sup>2</sup>Department of Internal Medicine, Cleveland Clinic, Cleveland, OH, USA

<sup>3</sup>Division of Pulmonary and Critical Care Medicine, Cleveland Clinic, Cleveland, OH, USA

<sup>4</sup>Department of Cardiology, Cleveland Clinic, Cleveland, OH, USA

## Correspondence

Per Wierup, Thoracic & Cardiovascular Surgery, Cleveland Clinic, 9500 Euclid Avenue, Cleveland, OH 44195, USA.  
Email: wierupp@ccf.org

## Abstract

Pulmonary vein obstruction is a rare condition, most commonly reported following pulmonary vein catheter ablation for atrial arrhythmia. This novel technique for treatment of pulmonary venous obstruction has the advantage of utilizing an autologous vascularized flap with intact endothelium for reconstruction of the pulmonary vein and to prevent restenosis.

## KEYWORDS

atrial fibroelastoma, autologous, pulmonary vein reconstruction, pulmonary venous occlusion

## 1 | INTRODUCTION

### 1.1 | Background

Iatrogenic pulmonary venous obstruction (PVO) is a rare condition, most commonly reported as a complication following ablation for atrial fibrillation or after complex congenital cardiac surgery.<sup>1-5</sup> Patients with PVO commonly complain of dyspnea and hemoptysis.<sup>1,6</sup> In cases of PVO including multiple pulmonary veins, symptoms can be life threatening and require prompt intervention.<sup>7</sup> Percutaneous revascularization strategies are most commonly applied in the treatment of PVO.<sup>8</sup> However, successful application of a percutaneous procedure depends on the location and severity of the occlusion, and pulmonary restenosis is a common complication. Since most PVOs are managed percutaneously, expertise regarding surgical repair of acquired PVO is limited, and restenosis of the pulmonary vein remains a feared complication.<sup>9</sup> Successful reconstruction of the pulmonary vein has previously been

described using a pericardium or polytetrafluoroethylene patch.<sup>10</sup> Nevertheless, the patches can be difficult to fashion correctly and may distort the pulmonary artery, shrink, or calcify. Vascularized autologous tissue offers the best potential for healing of the repair site and therefore, we believe that utilizing an autologous vascularized tissue to reconstruct the pulmonary vein decreases the risk of pulmonary venous restenosis.<sup>11</sup>

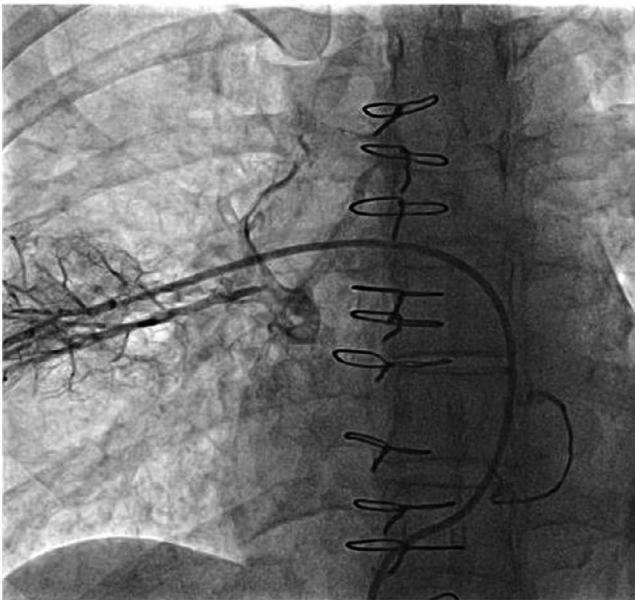
In the present report, we describe a new approach to surgical repair of PVO using a vascularized autologous flap from the superior vena cava and right atrium to reconstruct the pulmonary vein while minimizing the risk of pulmonary vein restenosis.

### 1.2 | The case: preoperative assessment and operative indications

A 41-year-old female referred for mitral valve re-repair presented with exertional dyspnea and hemoptysis. She

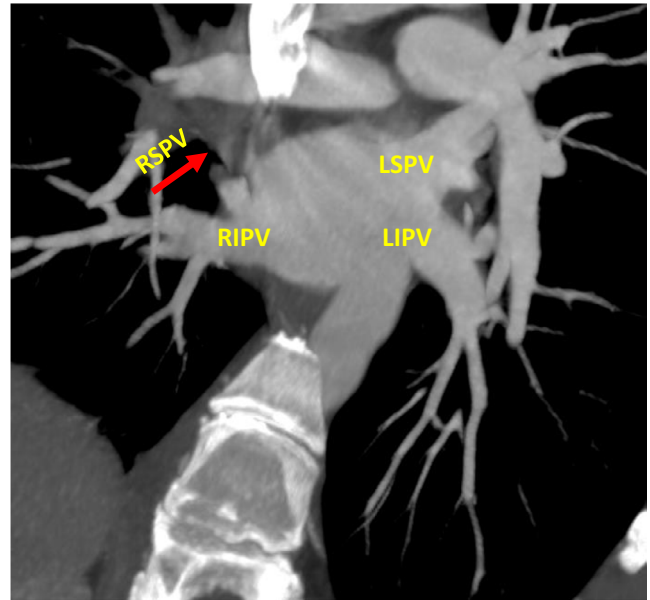
had a history of robotic mitral valve repair with a triangular resection of a papillary fibroelastoma on the posterior leaflet at another institution 8 months prior. In the postoperative course, the patient developed dyspnea, hemoptysis, and infiltrates in the right upper lobe. Computed tomography (CT) of the thorax demonstrated ground glass opacities at the periphery of the right upper lobe and a small right pleural effusion. A transbronchial biopsy was performed which was consistent with pulmonary edema and hemorrhage. The right upper lobe opacification was interpreted as pneumonia, and she experienced incomplete but temporary relief of symptoms during treatment with antibiotics and corticosteroids. A transthoracic echocardiography (TTE) was performed and revealed residual, moderate-to-severe mitral valve regurgitation with a posteriorly directed regurgitant jet for which the patient was referred to our institution and underwent mitral valve reoperation. The cause of the patient's pulmonary symptoms could not be identified on preoperative imaging.

A midline sternotomy was performed, and the left atrium was reopened. When opening the left atrium, the surgical findings revealed an unexpected and complete suture closure of the right superior pulmonary vein. The right lower lobe vein and both left-sided pulmonary veins were normal and wide open. Additional imaging was required to evaluate the remaining vasculature of the right superior lobe prior to surgical reconstruction and hence,

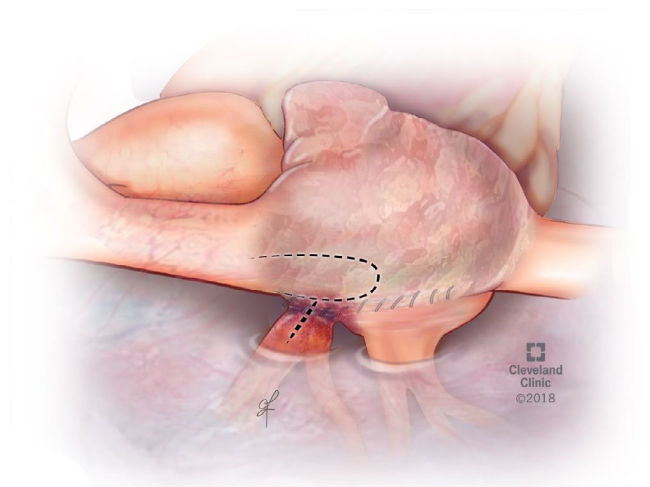


**FIGURE 1** Preoperative pulmonary angiogram of the right upper lobe in venous face (prior to the reconstruction of the pulmonary vein). The pulmonary veins are well visualized. There appears to be a complete occlusion of the right upper pulmonary vein with an obstruction of flow proximal to the occlusion. The remaining pulmonary vein structures were within normal limits with no evidence of pulmonary embolus or thrombus

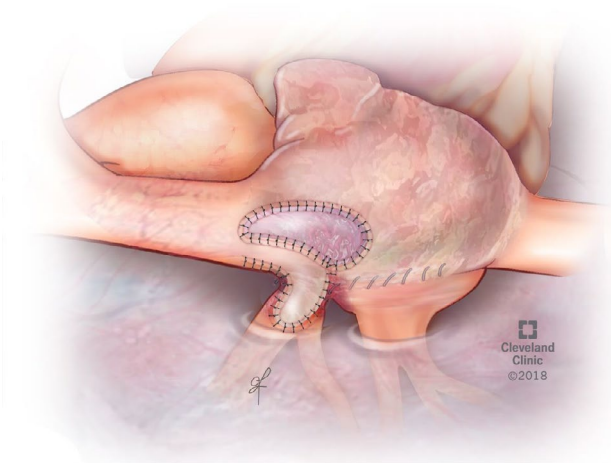
attention was turned toward the mitral valve, which was repaired with triangular resection and a flexible annuloplasty band. The left atrium was closed in a standard fashion and



**FIGURE 2** Preoperative CT reconstruction of the pulmonary vein structures (prior to the pulmonary vein reconstruction). The pulmonary arteries are well-opacified through the subsegmental level. The CT scan reveals occlusion of the right superior pulmonary vein (red arrow). A small area of ground-glass opacity is seen in the lateral right middle lobe. There is no evidence of pulmonary embolus or thrombus. CT, computed tomography; LIPV, left inferior pulmonary vein; LSPV, left superior pulmonary vein; RIPV, right inferior pulmonary vein; RSPV, right superior pulmonary vein



**FIGURE 3** Schematic of the right atrium and the right pulmonary vein arising from the left atrium (anterior view). The left atriotomy from the previous surgery is seen. The suture lines occluding the right pulmonary vein were identified and removed, hereby opening the lumen of the pulmonary vein. A portion of the interatrial septum was resected to enable a wider opening to the left atrium



**FIGURE 4** Schematic of the pulmonary vein reconstruction. A vascularized flap from the right atrium was mobilized and gently rotated and sutured to the ventral surface of the pulmonary vein creating a non-obstructive path through the pulmonary vein and into the left atrium. Autologous pericardium was used to reconstruct the lateral portion of the SVC and the proximal lateral part of the right atrium to prevent SVC stenosis. SVC, superior vena cava

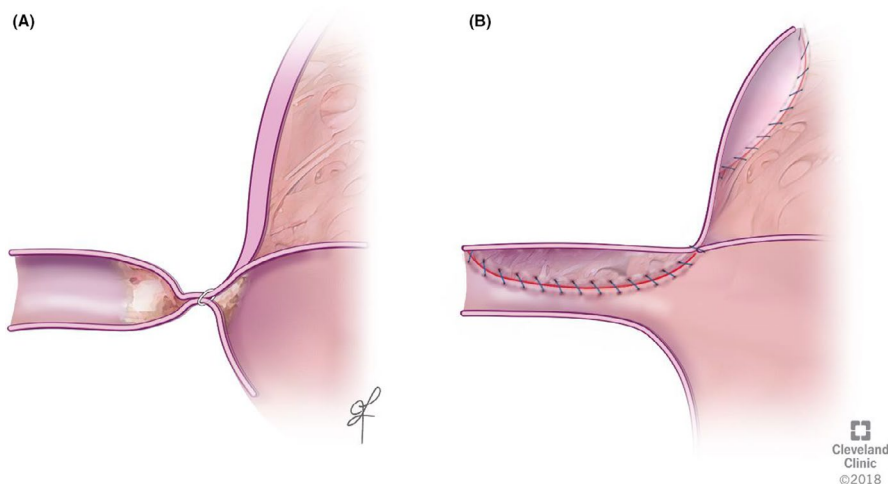
post repair intraoperative echocardiography confirmed a well-functioning mitral valve.

Immediate postoperatively pulmonary angiogram (Figure 1) and 3D reconstruction of the CT of the pulmonary vein structures (Figure 2) were performed and confirmed that the vasculature distal to the occlusion of the pulmonary vein was open and of normal size. The patient was consented for this novel potential reconstructive technique and returned to the operating room for reconstruction of the occluded right superior pulmonary vein.

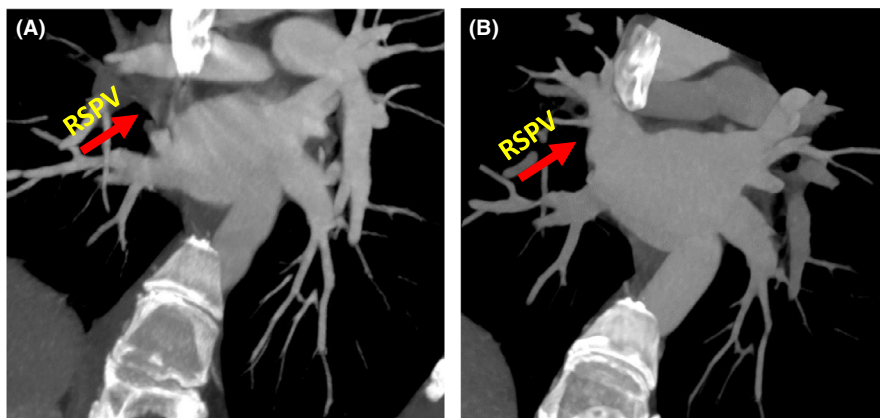
## 2 | OPERATIVE TECHNIQUES

The sternotomy was reopened, and the right side of the heart and pulmonary hilum were carefully dissected to avoid injury to the phrenic nerve. The patient was heparinized and cannulated in standard fashion using bicaval venous cannulation. The left atriotomy was reopened, and scar tissue was gently dissected off the right superior pulmonary vein and the sutures occluding the vein were removed, thereby opening the lumen (Figure 3). The opening in the vein was extended toward the lung where the vein looked perfectly normal. A portion of the interatrial septum was resected to enable a wider connection to the left atrium. A vascularized flap from the right atrium was mobilized, gently rotated, and sutured to the ventral surface of the open pulmonary vein. Partial thickness bites of this flap were used when suturing to the interatrial septum, creating a generous non-obstructive path between the pulmonary vein and the left atrium. An autologous pericardial patch was used to reconstruct the lateral portion of the superior vena cava and the defect in the right atrium (Figures 4 and 5). A 4-mm hole was created in the fossa ovalis to facilitate future endovascular interventions if needed. Post repair intraoperative echocardiography revealed unobstructed laminar flow both in the repaired pulmonary vein and in the superior vena cava, and a well-functioning mitral valve repair from the previous surgery.

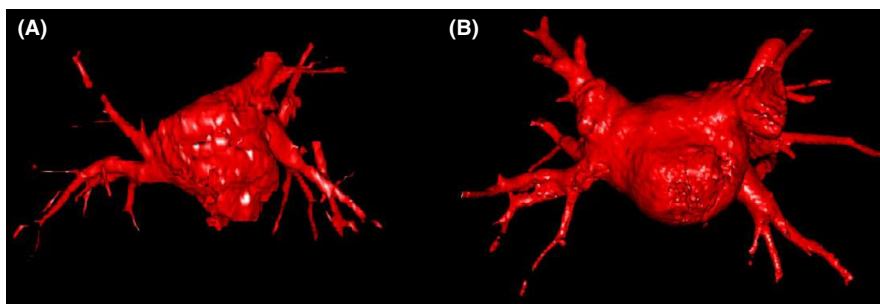
The postoperative course was uncomplicated, and the patient was discharged five days following surgery. At follow-up two months postoperatively, the patient was asymptomatic with complaints of occasional lightheadedness but she had no further hemoptysis or shortness of breath. Pulmonary



**FIGURE 5** Schematic of the pulmonary vein before (A) and following (B) surgical reconstruction (lateral view). A, Complete suture obliteration of the right pulmonary vein. B, The suture lines occluding the right pulmonary vein were removed, and a portion of the interatrial septum was resected to enable a wider opening to the left atrium. A vascularized flap from the right atrium was mobilized and gently rotated and sutured to the ventral surface of the pulmonary vein creating a nonobstructive path through the pulmonary vein and into the left atrium. Autologous pericardium was used to reconstruct the lateral portion of the SVC and the proximal lateral part of the right atrium



**FIGURE 6** Pre- and postoperative CT scan of the pulmonary vein structures (following the pulmonary vein reconstruction). A, The preoperative CT scan is described in Figure 2. B, The postoperative CT demonstrates patency of the right upper (red arrow), right middle, and right lower pulmonary veins. The right middle pulmonary vein is draining into the proximal right upper pulmonary vein. A surgical connection is seen between previously nonopacified right upper pulmonary vein and proximal right upper pulmonary vein. CT, computed tomography, RSPV, Right superior pulmonary vein



**FIGURE 7** A 3D reconstruction of the pulmonary veins structure seen on CT. A, The preoperative CT scan demonstrates an occlusion of the upper right pulmonary vein with occlusion of the flow proximal from the obstruction. B, The postoperative CT demonstrates patency of the entire pulmonary vein structure with no evidence of pulmonary thrombus or embolus. The right middle pulmonary vein is draining into the proximal right upper pulmonary vein. A surgical connection is seen between previously nonopacified right upper pulmonary vein and proximal right upper pulmonary vein. 3D, 3-dimensional, CT, computed tomography

function tests were normal. Immediate postoperative CT scan and a repeat CT scan at 9 months postoperatively revealed a widely patent right superior pulmonary vein (Figures 6 and 7). Transthoracic echocardiography demonstrated a well-functioning mitral valve repair with no mitral regurgitation and a mean gradient of 5 mm Hg.

### 3 | COMMENT

This technique demonstrates reconstruction of the right superior pulmonary vein by using a vascularized autologous right atrial wall pedicled flap.

Pulmonary restenosis is a common complication following percutaneous stenting of the pulmonary vein.<sup>11</sup> Surgical repair is recommended in patients who suffer from severe PVO if the risk of pulmonary restenosis can be minimized.<sup>10</sup> Previous case reports describe the feasibility and

effectiveness of surgical repair for PVO.<sup>10,12,13</sup> However, successful surgery can be difficult to accomplish, and improved surgical techniques are needed.<sup>14</sup> Furthermore, long-term follow-up reveal continuous high rates of pulmonary restenosis, which remains a concern in the treatment of PVO.<sup>12</sup>

Our surgical approach using a vascularized flap with intact endothelium to prevent restenosis has the advantage of utilizing autologous tissue for reconstruction of the pulmonary vein. This technique can potentially be applied to pulmonary vein stenosis due to radiofrequency ablations. Although long-term follow-up is needed, this is a promising approach to reduce the risk of pulmonary restenosis following surgical repair.


### CONFLICT OF INTEREST

None declared.

## AUTHOR CONTRIBUTIONS

Each author has participated sufficiently in the work to take responsibility for a meaningful share of the manuscript, as below. As such, we reflect the important contributions in the author list. RAC: is the main investigator of this study and contributed to study design, and prepared and submitted the manuscript. MJS: served as the co-investigator of this study, who contributed to study design and preparation of the manuscript. UH: served as the co-PI of this study, who through extensive interaction designed and supervised all aspects of this study, and who contributed with his expertise and skill in his field. KH: served as the co-investigator of this study, who contributed to study design and preparation of the manuscript. AMG: served as the co-PI of this study, who through extensive interaction designed and supervised all aspects of this study, and who contributed with his expertise and skill in his field. DP: served as the co-PI of this study, who through extensive interaction designed and supervised all aspects of this study, and who contributed with his expertise and skill in his field. GP: served as the co-PI of this study, who through extensive interaction designed and supervised all aspects of this study, and who contributed with his expertise and skill in his field. PW: served as the main PI of this study, who through extensive interaction designed and supervised all aspects of this study, and who contributed with his expertise and skill in his field.

## ORCID

Raphaelle A. Chemtob  <https://orcid.org/0000-0002-0451-5381>

Kevin Edward Hodges  <https://orcid.org/0000-0002-7724-5271>

Alan Marc Gillinov  <https://orcid.org/0000-0001-9410-7543>

## REFERENCES

- Fender EA, Widmer RJ, Hodge DO, Packer DL, Holmes DR. Assessment and management of pulmonary vein occlusion after atrial fibrillation ablation. *JACC Cardiovasc Interv.* 2018;11:1633-1639.
- Kumar N, Phan K, Aksoy I, et al. Management of pulmonary vein stenosis following catheter ablation of atrial fibrillation. *J Atr Fibrillation.* 2014;7(1):1060.
- Saad EB, Marrouche NF, Saad CP, Ha E, Bash D, White RD. Pulmonary vein stenosis after catheter ablation of atrial fibrillation : emergence of a new clinical syndrome. *Ann Intern Med.* 2003;138:634-638.
- Ussia GP, Marasini M, Zannini L. Acquired pulmonary vein obstruction after open-heart surgery. *Eur J Cardiothorac Surg.* 2002;22:465-467.
- Shi G, Zhu Z, Chen H, Zhang H, Zheng J, Liu J. Surgical repair for primary pulmonary vein stenosis: Single-institution, midterm follow-up. *J Thorac Cardiovasc Surg.* 2015;150(1):181-188.
- Braun S, Platzeck I, Zöphel K, et al. Haemoptysis due to pulmonary venous stenosis. *Eur Respir Rev.* 2014;23:170-179.
- Holmes DR, Monahan KH, Packer D. Pulmonary vein stenosis complicating ablation for atrial fibrillation: clinical spectrum and interventional considerations. *JACC Cardiovasc Interv.* 2009;2(4):267-276.
- Guadagnoli AF, Contreras AE, Leonardi CR, Ballarino MA, Atea L, Peirone AR. Treatment of pulmonary vein stenosis secondary to radiofrequency ablation. *Medicina (B Aires).* 2014;74:303-306.
- Schoene K, Sommer P, Arya A, et al. Complex cases of acquired pulmonary vein stenosis after radiofrequency ablation : is surgical repair an option? *Europace.* 2019;21(1):73-79.
- Patel NS, Pettersson G, Tuzcu EM, Kapadia SR. Successful surgical repair of iatrogenic pulmonary vein stenosis. *J Cardiovasc Electrophysiol.* 2012;23(6):656-658.
- Bacha EA, Kalimi R, Starr JP, Quinones J, Koenig P. Autologous repair of supra-valvar pulmonary stenosis. *Ann Thorac Surg.* 2004;77:734-736.
- van Putte BP, Smith T, De Kroon TL, Damiano RJ. Pulmonary vein widening plasty for pulmonary vein stenosis and occlusion after catheter ablation. *Ann Thorac Surg.* 2017;104:411-412.
- Tarui T, Watanabe G, Kiuchi R, Tomita S, Ohtake H, Yoshizumi K. Surgical repair for the treatment of pulmonary vein stenosis after radiofrequency ablation. *Ann Thorac Surg.* 2017;104:253-254.
- Kanter KR, Kirshbom PM, Kogon BE. Surgical repair of pulmonary venous stenosis: a word of caution. *Ann Thorac Surg.* 2014;98:1687-1691.

**How to cite this article:** Chemtob RA, Smith M, Hatipoglu U, et al. Repair of iatrogenic pulmonary vein occlusion with a vascularized atrial flap. *Clin Case Rep.* 2020;8:13–17. <https://doi.org/10.1002/ccr3.2500>