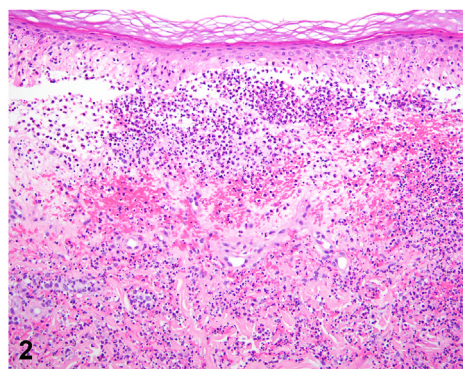
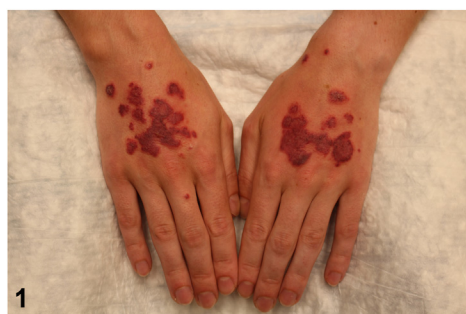

Dorsal hand eruption in a man with ulcerative colitis



Connie S. Zhong, MD, MSc,^{a,b} Nicolas Wyvekens, MD, PhD,^{a,c} Christine G. Lian, MD,^{a,c} and Vinod E. Nambudiri, MD, MBA^{a,b}

Key words: inflammatory bowel disease; medical dermatology; neutrophilic dermatosis of the dorsal hands; ulcerative colitis.



A 24-year-old man with ulcerative colitis well controlled on infliximab for 3 years presented to dermatology clinic with a recurrent eruption on the dorsal hands. The patient reported a similar rash 1 month prior that resolved spontaneously. The present eruption started as a single red, painful papule that progressed into several lesions. The patient was afebrile and well appearing. Examination showed multiple nonblanching dark red papulovesicles coalescing into plaques on the bilateral dorsal hands (Fig 1). Skin biopsy demonstrated diffuse dermal neutrophilic infiltrate with papillary dermal edema and hemorrhage (Fig 2). Special stains were negative for microorganisms. Immunofluorescence identified no specific immunoreactivity.

Question 1: What is the most likely diagnosis?

- A. Cutaneous small-vessel vasculitis
- B. Classic pyoderma gangrenosum
- C. Neutrophilic dermatosis of the dorsal hands
- D. Dermatitis herpetiformis
- E. Bowel-associated dermatosis-arthritis syndrome

Answer:

A. Cutaneous small-vessel vasculitis — Incorrect. Cutaneous small-vessel vasculitis is characterized by palpable purpura, often on the extremities and can rarely be bullous. Histology demonstrates leukocytoclasia, neutrophilic/mixed infiltrates, extravasated erythrocytes, and fibrinoid necrosis. Neutrophilic dermatosis of the dorsal hands (NDDH) was initially

From the Harvard Medical School, Boston, Massachusetts^a; Department of Dermatology, Brigham and Women's Hospital, Boston, Massachusetts^b; and Department of Pathology, Brigham and Women's Hospital, Boston, Massachusetts.^c

Funding sources: None.

IRB approval status: Not applicable.

Patient consent: The patient gave consent for their photographs and medical information to be published in print and online and with the understanding that this information may be publicly available.

Correspondence to: Vinod E. Nambudiri, MD, MBA, Department of Dermatology, Brigham and Women's Hospital, 221 Longwood Ave, Boston, MA 02115. E-mail: vnambudiri@bwh.harvard.edu. JAAD Case Reports 2022;28:107-9.

2352-5126

© 2022 by the American Academy of Dermatology, Inc. Published by Elsevier, Inc. This is an open access article under the CC BY-NC-ND license (<http://creativecommons.org/licenses/by-nc-nd/4.0/>).

<https://doi.org/10.1016/j.jidcr.2022.07.043>

described as a pustular vasculitis¹ but renamed NDDH given its dense dermal neutrophilic infiltrates; vasculitis may be variably seen in early lesions.^{2,3}

B. Classic pyoderma gangrenosum — Incorrect. Pyoderma gangrenosum (PG) begins with painful pustules evolving into ulcerations with rolled violaceous borders. Classic PG usually occurs on the lower extremities and with significant pain. Atypical (vesiculobullous) PG, which may include hemorrhagic bullae, may overlap clinically with NDDH.⁴ Histologically, PG can show neutrophilic infiltrates with or without leukocytoclastic vasculitis.

C. Neutrophilic dermatosis of the dorsal hands — Correct. NDDH is a localized Sweet syndrome variant.^{3,5} NDDH can be papular, pustular, or ulcerative; NDDH can show pathergy. Histologically, NDDH and Sweet syndrome show dense neutrophilic infiltrate, dermal edema, leukocytoclasia, and sometimes vasculitis.³ Cases often affect males, individuals over 60, and involve both hands.³ NDDH can extend to involve the palms, upper extremities, trunk, face, and lower extremities.³ Fevers and elevated inflammatory markers are variably present.⁴

D. Dermatitis herpetiformis — Incorrect. Dermatitis herpetiformis is a pruritic eruption associated with celiac disease, manifesting as small vesicles on extensor surfaces of extremities and the buttocks.

E. Bowel-associated dermatosis-arthritis syndrome — Incorrect. Bowel-associated dermatosis-arthritis syndrome is a noninfectious neutrophilic dermatosis—comprising erythematous macules, papules, and vesiculopustules on the proximal extremities and trunk, along with arthritic symptoms—often seen post bariatric surgery. Histologically, lesions demonstrate perivascular, nodular neutrophilic infiltrates with dermal edema.

Question 2: Which of the below is most commonly associated with this diagnosis?

- A. Inflammatory bowel disease
- B. Hematologic disorders
- C. Rheumatoid arthritis
- D. Medications
- E. Mycobacterial infection

Answer:

A. Inflammatory bowel disease — Incorrect. While NDDH is associated with ulcerative colitis and Crohn's disease, it is not the most common systemic condition associated with the disease. In a review of

123 cases of NDDH, 3.3% of patients had inflammatory bowel disease.³

B. Hematologic disorders — Correct. Of the underlying associated diseases, hematologic disorders are most commonly associated with NDDH. Hematologic disorders include gammopathies, myelodysplasias, and malignancies; 14.3% of 123 NDDH patients in a study had a hematologic disorder.³

C. Rheumatoid arthritis — Incorrect. NDDH is associated with rheumatologic disease, including rheumatoid arthritis, but it is not the most common condition associated with NDDH; 10.6% of 123 patients in a study had a rheumatologic disorder.³

D. Medications — Incorrect. While medications, such as granulocyte colony-stimulating factor, nonsteroidal anti-inflammatory drugs, trimethoprim/sulfamethoxazole, can be associated with the onset of neutrophilic dermatoses, medications are not the most common cause of NDDH.

E. Mycobacterial infection — Incorrect. 10.6% of 123 patients in a study had recent infections of some sort associated with NDDH, but infection was less commonly associated with NDDH than hematologic dyscrasias.³

Question 3: Which of the following is the best initial treatment for this condition?

- A. Prednisone
- B. Gluten-free diet
- C. Dapsone
- D. Intravenous immunoglobulin
- E. Metronidazole

Answer:

A. Prednisone — Correct. As with classic Sweet syndrome, topical and systemic steroids (prednisone 0.5-1 mg/kg/day) are first-line therapy for NDDH. In our case, the patient was prescribed high-potency topical steroids with some improvement, followed by initiation of systemic prednisone 40 mg for 5 days, leading to rapid clearance. Treatment of underlying predisposing conditions is also advised.

B. Gluten-free diet — Incorrect. Gluten-free diet is a first-line treatment for dermatitis herpetiformis associated with celiac disease.

C. Dapsone — Incorrect. Dapsone may be used to treat NDDH and has been reported to be a steroid-sparing agent for chronic relapsing NDDH.³ However, dapsone is not first-line treatment.

D. Intravenous immunoglobulin — Incorrect. Intravenous immunoglobulin is not typically used to treat NDDH.

E. Metronidazole — Incorrect. While tetracyclines have been reported in the management of refractory NDDH,³ metronidazole is not a typical antibiotic option for the management of NDDH.

Abbreviations used:

NDDH: neutrophilic dermatosis of the dorsal hands

PG: pyoderma gangrenosum

Conflicts of interest

None disclosed.

REFERENCES

1. Struton G, Weedon D, Robertson I. Pustular vasculitis of the hands. *J Am Acad Dermatol.* 1995;32(2):192-198.
2. Galaria NA, Junkins-Hopkins JM, Kligman D, James WD. Neutrophilic dermatosis of the dorsal hands: pustular vasculitis revisited. *J Am Acad Dermatol.* 2000;43(5):870-874.
3. Micallef D, Bonnici M, Pisani D, Boffa MJ. Neutrophilic dermatosis of the dorsal hands: a review of 123 cases. *J Am Acad Dermatol.* 2019. <https://doi.org/10.1016/j.jaad.2019.08.070>
4. Walling HW, Snipes CJ, Gerami P, Piette WW. The Relationship between neutrophilic dermatosis of the dorsal hands and Sweet syndrome: report of 9 cases and comparison to atypical pyoderma gangrenosum. *Arch Dermatol.* 2006;142(1):57-63. <https://doi.org/10.1001/archderm.142.1.57>
5. DiCaudo DJ, Connolly SM. Neutrophilic dermatosis (pustular vasculitis) of the dorsal hands: a report of 7 cases and review of the literature. *Arch Dermatol.* 2002;138(3):361-365. <https://doi.org/10.1001/archderm.138.3.361>