

# Localized pemphigus vegetans of the nose and lips: A classic case of a rare entity



Cynthia Magro, MD,<sup>a,b</sup> Marc E. Grossman, MD,<sup>c,d</sup> Selda Karaaslan, MD,<sup>a</sup> Robert Skrokov, MD,<sup>e</sup> and Mary Valinotti, MS RPA-C<sup>e</sup>  
*New York, New Hyde Park, and Great River, New York; and New Haven, Connecticut*

**Key words:** autoimmune reaction; dermatopathology; light microscopy; pathology; pemphigus vegetans; pemphigus vulgaris; ulcer.

## INTRODUCTION

Pemphigus vegetans (PVeg) is a rare variant of the autoimmune vesiculobullous disorder pemphigus vulgaris (PV), exhibiting very distinct clinical and histologic features and accounting for >5% of cases of PV. As suggested by the designation “vegetans,” one of its characteristic hallmarks is the vegetative epithelial response that underlies the common pathobiology implicated in PV, being one of a humorally mediated autoimmune reaction targeting a select intercellular protein of the epidermis. Circulating autoantibodies of the IgG or IgA isotype reactive against components of epithelial desmosome-tonofilament complexes are seen in PV and its variants, where disease activity is reflected by the circulating levels of these antibodies.<sup>1</sup>

PVeg was first described in 1876 by Neumann,<sup>2</sup> exhibiting a similar pattern of flaccid bullae but also with supervening papillomatous projections demonstrating a predilection to involve intertriginous areas and the oral cavity. Thirteen years later, a cobblestoned, pustular, verrucoid variant exhibiting localization to flexural areas was described by Hallopeau.<sup>3</sup> The clinical course of the Neumann variant is one that is relentless without treatment, whereas the Hallopeau variant may exhibit spontaneous regression. The age of onset is lower than that of classic PV, whereby these patients are typically between 40 and 50 years of age.<sup>2</sup> PVeg limited to the nose and lips without concomitant oral involvement is particularly rare, and to our knowledge, only 4

### Abbreviations used:

PV: pemphigus vulgaris  
 PVeg: pemphigus vegetans

reports exist in the literature. We report 2 additional cases of nasal PVeg and discuss the diagnostic pitfalls that were encountered in each case.

## CASE REPORT

### Case 1

A 67-year-old man presented to a surgeon with a nonhealing ulcer on the nose. A biopsy was taken and interpreted as invasive squamous cell carcinoma. It subsequently recurred. The recurrent tumor was sent to a dermatopathology consultant, who rendered a diagnosis of PVeg on the initial biopsy material and subsequent recurrence. There was no morphologic evidence of squamous cell carcinoma.

### Case 2

A 48-year-old white woman of Irish descent presented with a 2-week history of painless red plaques with granulation tissue, pustules, and crusting of her swollen nasal tip and upper lip. She had not traveled outside of Long Island, New York. Her past medical history included a bipolar disorder, perforated sigmoid diverticulitis, chronic sinusitis, and nasal polypectomy. Her medications included aripiprazole, lamotrigine, and bupropion.

From Department of Pathology and Laboratory Medicine, New York Presbyterian Hospital-Weill Cornell Medicine<sup>a</sup>; Department of Pathology and Laboratory Medicine, Weill Cornell Medicine, New York<sup>b</sup>; Department of Dermatology, Yale University School of Medicine, New Haven<sup>c</sup>; Department of Dermatology, Hofstra/Northwell Donald and Barbara Zucker School of Medicine, New Hyde Park<sup>d</sup>; and Northwell Dermatology, Great River.<sup>e</sup>

Funding sources: None.

IRB approval status: This study presents archival pathology material where any additional studies were covered under IRB protocol 20- 02021524.

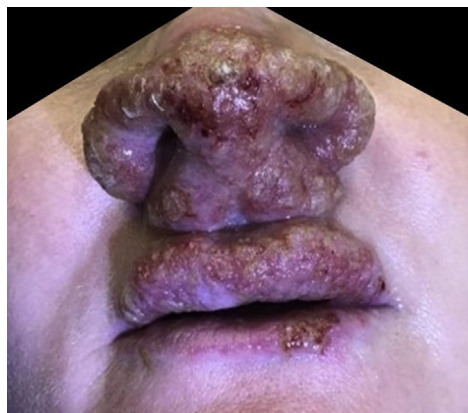Correspondence to: Cynthia Magro, MD, Department of Pathology and Laboratory Medicine, Weill Cornell Medicine, 1300 York Avenue F-309, New York, NY 10065. E-mail: [cym2003@med.cornell.edu](mailto:cym2003@med.cornell.edu).

JAAD Case Reports 2022;25:67-71.

2352-5126

© 2022 Published by Elsevier on behalf of the American Academy of Dermatology, Inc. This is an open access article under the CC BY-NC-ND license (<http://creativecommons.org/licenses/by-nc-nd/4.0/>).

<https://doi.org/10.1016/j.jidcr.2022.05.001>

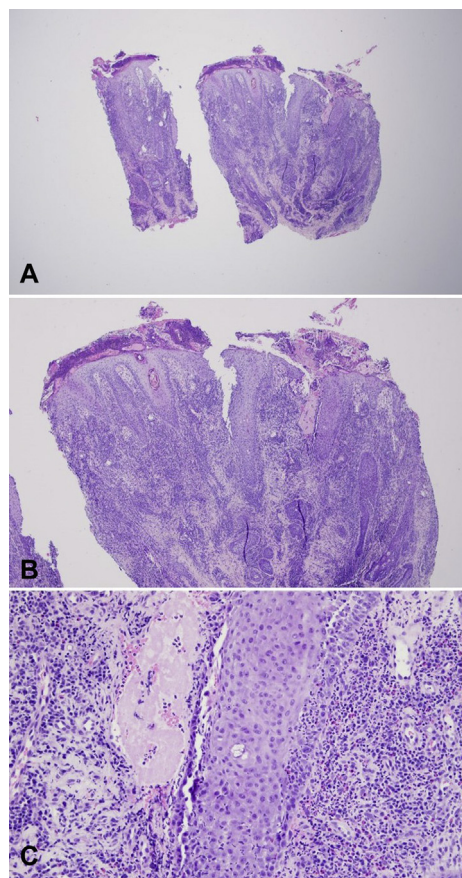


**Fig 1.** This 48-year-old woman presented with a 2-week history of painless red plaques with granulation tissue, pustules, and crusting of her swollen nasal tip and upper lip. She was diagnosed with impetiginized contact allergic dermatitis, facial cellulitis, and herpes simplex virus infection; however, 5 months after her initial presentation, she was diagnosed with PVeg.

She was diagnosed with impetiginized contact allergic dermatitis after self-treatment with neomycin, polymyxin, and bacitracin ointment for several weeks without improvement. She improved with prednisone 40 mg/d for 3 weeks but flared when it was stopped (Fig 1). The recurrence was so severe with swelling, crusting, and nasal obstruction that she was admitted to a community hospital with the diagnosis of facial cellulitis. She received intravenous doxycycline and clindamycin without improvement. A dermatologic consultation suggested a chronic herpes simplex virus infection, although molecular studies for herpes simplex virus I and II and varicella-zoster virus infection were negative. There was no benefit from courses of dapson, valacyclovir, or ciprofloxacin. Because of progressive exuberant inflammation, a second dermatopathologic opinion was obtained 5 months after the patient presented to dermatology, leading to a diagnosis of PV confirmed by serologic studies. She was treated with intravenous methylprednisolone 80 mg/d for 5 days, followed by prednisone 80 mg/d tapered with complete healing. The prednisone was tapered and she received 1 g rituximab-pvvr biosimilar infusion x 2, 2 weeks apart.

### Light microscopy

Both cases showed virtually identical light microscopic findings. The biopsies demonstrated an irregular pattern of epithelial hyperplasia characterized by an irregular endophytic squamous proliferation associated with suprabasilar acantholysis.



**Fig 2.** The biopsy showed a striking, vegetative, hyperplastic epithelial inflammatory process (A, Original magnification:  $\times 20$ ). The biopsy demonstrated an irregular vegetative psoriasiform epithelial hyperplasia associated with suprabasilar acantholysis (B, Original magnification:  $\times 200$ ). A striking infiltration of the epithelium by neutrophils and eosinophils with concomitant acanthocytes was observed (C, Original magnification:  $\times 400$ ).

There was striking infiltration of the epithelium by neutrophils and eosinophils, including discrete eosinophil- and neutrophil-enriched microabscesses (Fig 2, A-C).

### DISCUSSION

PVeg restricted to the nose and lips without any oral, flexural, or intertriginous involvement can present a diagnostic dilemma because of the rarity of this presentation. Clinically, typical features that would provide a clue to the diagnosis of PV are not seen. Because of the dramatic vegetative erosive quality of the lesions in concert with regional nasal localization, other clinical entities, such as hypertrophic discoid lupus erythematosus, sarcoidosis, inflammatory bowel disease-associated pyostomatitis vegetans, and certain infections, including chronic herpes

**Table I.** Pemphigus vegetans involving nose

Cases	Age/sex of patient	Clinical presentation	Additional lesions	Management	Treatment	Follow-up
Case 1	67 y/ Man	Chronic nonhealing ulcer on the nose		Initially interpreted as invasive squamous cell carcinoma. The tumor subsequently recurred.	A dermatopathology consultation rendered a diagnosis of pemphigus vegetans on the initial biopsy material and subsequent recurrence.	
Case 2	48 y/ Woman	A 2 week history of painless red plaques with granulation tissue, pustules and crusting of her swollen nasal tip	Plaques with granulation tissue, pustules and crusting also on upper lip	Initial diagnoses included: impetiginized contact allergic dermatitis; facial cellulitis; and herpes simplex. Due to progressive exuberant inflammation a second dermatopathologic opinion 5 months after she presented to dermatology led to a diagnosis of pemphigus vegetans confirmed by serologic studies.	Intravenous methylprednisolone 80 mg/d × 5 days and followed by prednisone 80 mg/d tapered with complete healing. She received 1 gram rituximab-pvvr biosimilar infusion × 2, 2 weeks apart.	Complete clearing
3 Sigmund GA et al, <sup>5</sup> 2012	43 y/ Woman	Progressively enlarging nasal mass over 19 mo	An eczematous process in the lip, along the right medial canthus, extending into the upper portion of the eyelid	Initial treatment with oral antibiotics and 3 weeks of IV vancomycin Subsequent diagnosis of squamous cell carcinoma and referral for partial rhinectomy.	Prednisone 60 mg/d for 2 weeks and tapering over a month and maintenance with a prednisone of 30 mg/d	Near-complete clearing
4 Dhamija A et al, <sup>7</sup> 2012	45 y/ Man	Recurrent painful oral erosions for 3 years. Well-defined, irregular, hypertrophic, fissured plaque with oozing and crusting surrounding the mouth, extending up to and into the ala nasii	Scattered patches over the scalp and glans penis with oozing and pus formation	Several courses of broad-spectrum antibiotics along with supportive treatment without any improvement 2-week course of Itraconazole 2-week course of standard antitubercular drugs PET-CT) scan and excisional biopsy of enlarged lymph node for the suspicion of malignancy.	Intravenous dexamethasone 8 mg twice daily for 1 wk, 4 mg twice daily for 1 wk and maintenance on standard dexamethasone cyclophosphamide pulse regimen.	Near-complete clearing

Continued

Table I. Cont'd

Cases	Age/sex of patient	Clinical presentation	Additional lesions	Management	Treatment	Follow-up
5 Downie JB et al, <sup>8</sup> 1998	38 y/ Woman	Hypertrophic verrucous plaques on the external nares. Associated with intranasal heroin abuse	Philtrum and lips without intraoral involvement	A nasal biopsy showed classic features of PVeg along with a corroborative direct immunofluorescent profile.	Prednisone 40 mg/day	Complete clearing
6 Feitoza R/C et al, <sup>6</sup> 2019	89 y / Man	Crusted vegetative lesion in the anterior nasal cavity and on the nasal tip evolved within 3 mo	Erythematous plaque, ulcerations, thick crusts, and flaccid bulla with purulent content in chest	No improvement after initial antibiotic therapy Referred for suspected skin cancer.	Prednisone 1 mg/kg/day	Complete remission

IV, Intravenous; mo, months; PET-CT, positron emission tomography-computed tomography; wk, week; y, year.

simplex virus infection, rhinoscleroma, and lupus vulgaris, are considered.

The accurate diagnosis relies on the biopsy findings, which include the vegetative benign epithelial hyperplasia,<sup>4</sup> suprabasilar acantholysis that exactly recapitulates the pattern seen in PV,<sup>5</sup> and the appropriate inflammatory milieu that one associates with pemphigus, including intraepithelial collections of eosinophils and neutrophils (intraepithelial eosinophilic microabscesses).<sup>6</sup> Direct immunofluorescence studies will show intercellular epidermal deposits of complement and immunoglobulin IgG, whereas C3d and C4d in an intercellular array can be seen via an immunohistochemical technique on paraffin-embedded formalin-fixed tissue. The presence of desmoglein 3 autoantibodies confirms the diagnosis of PVeg, although other antibodies potentially reflective of epitope spreading, including antibodies against desmocollin 1, desmocollin 2, and periplakin, can also be seen.<sup>4</sup> There are 4 previous reports describing nasal PV with or without concomitant lip involvement (Table I).<sup>5-8</sup>

One might also question potential risk factors for the development of PVeg. Intranasal heroin has been associated with PVeg involving the nose and lips. PVeg has been reported with drug exposure and malignancy,<sup>9</sup> including colon,<sup>10</sup> gastric,<sup>11</sup> and lung malignancies.<sup>12</sup> PVeg has been reported to mimic malignancy on an 18F-fluorodeoxyglucose positron emission tomography scan with prominent involvement of the nose as well as multiple sites on the scalp, lips, and bilateral cervical lymph nodes.<sup>13</sup> Underlying malignancy and a drug-based trigger, such as captopril and enalapril, are additional associations.

The treatment of PVeg is the same as that of PV and includes systemic steroids and immunosuppressants. Despite the dramatic appearance, the disease readily and rapidly responds to systemic steroids, and therefore, heightened awareness of a localized nasal variant of this condition allows earlier therapeutic intervention, a critical cornerstone in optimal management.

#### Conflicts of interest

None disclosed.

#### REFERENCES

1. Cozzani E, Christana K, Mastrogiacomo A, et al. Pemphigus vegetans Neumann type with anti-desmoglein and anti-periplakin autoantibodies. *Eur J Dermatol*. 2007;17(6):530-533. <https://doi.org/10.1684/ejd.2007.0270>
2. Son YM, Kang HK, Yun JH, Roh JY, Lee JR. The Neumann type of pemphigus vegetans treated with combination of dapsone and steroid. *Ann Dermatol*. 2011;23(suppl 3):S310-S313. <https://doi.org/10.5021/ad.2011.23.S3.S310>

3. Ahmed AR, Blose DA. Pemphigus vegetans. Neumann type and Hallopeau type. *Int J Dermatol*. 1984;23(2):135-141. <https://doi.org/10.1111/j.1365-4362.1984.tb05688.x>
4. Mergler R, Kerstan A, Schmidt E, Goebeler M, Benoit S. Atypical clinical and serological manifestation of pemphigus vegetans: a case report and review of the literature. *Case Rep Dermatol*. 2017;9(1):121-130. <https://doi.org/10.1159/000468919>
5. Sigmund GA, Oppenheimer R. Pemphigus vegetans of the nose. *Ear Nose Throat J*. 2012;91(1):E14-E15. <https://doi.org/10.1177/014556131209100117>
6. Feitoza RIC, Santos M, Schettini MDCA, Ferreira SAD. Pemphigus vegetans with isolated involvement of the nose and chest: rare variant of pemphigus vulgaris. *An Bras Dermatol*. 2019;94(4):476-478. <https://doi.org/10.1590/abd1806-4841.20198285>
7. Dhamija A, D'souza P, Meherda A, Kothiwala RK. Pemphigus vegetans: an unusual presentation. *Indian Dermatol Online J*. 2012;3(3):193-195. <https://doi.org/10.4103/2229-5178.101818>
8. Downie JB, Dicostanzo DP, Cohen SR. Pemphigus vegetans-Neumann variant associated with intranasal heroin abuse. *J Am Acad Dermatol*. 1998;39(5 Pt 2):872-875. [https://doi.org/10.1016/s0190-9622\(98\)70369-x](https://doi.org/10.1016/s0190-9622(98)70369-x)
9. Bastiaens MT, Zwan NV, Verschueren GL, Stoof TJ, Nieboer C. Three cases of pemphigus vegetans: induction by enalapril--association with internal malignancy. *Int J Dermatol*. 1994;33(3):168-171. <https://doi.org/10.1111/j.1365-4362.1994.tb04942.x>
10. Torres T, Ferreira M, Sanches M, Selores M. Pemphigus vegetans in a patient with colonic cancer. *Indian J Dermatol Venereol Leprol*. 2009;75:603-605. <https://doi.org/10.4103/0378-6323.57724>
11. Koga C, Izu K, Kabashima K, Tokura Y. Pemphigus vegetans associated with gastric cancer. *J Eur Acad Dermatol Venereol*. 2007;21(9):1288-1289. <https://doi.org/10.1111/j.1468-3083.2007.02184.x>
12. Serwin AB, Bokinić E, Chodynica B. Pemphigus vegetans in a patient with lung cancer. *Dermatol Online J*. 2005;11(1):13. <https://doi.org/10.5070/D3959528sv>
13. D'souza MM, D'souza PV, Jaimini A, et al. A rare case of pemphigus vegetans mimicking malignancy on F-18 FDG PET/CT. *Clin Nucl Med*. 2011;36(3):248-251. <https://doi.org/10.1097/RLU.0b013e318208f746>