

Does Perifollicular Vascularity on the Day of Oocyte Retrieval Affect Pregnancy Outcome in an *In Vitro* Fertilization Cycle?

Nikita Naredi, Santosh Kumar Singh¹, Rajesh Sharma²

Assisted Reproductive Technology Centre, Command Hospital,
¹Department of Obstetrics and Gynaecology, Command Hospital, ²IVF Specialist Assisted Reproductive Technology Centre, Pune, Maharashtra, India

ABSTRACT

Background: The vascularization status of ovarian follicles affects reproductive competence of oocytes and in turn embryo quality by regulating its oxygen supply. Transvaginal power Doppler ultrasound can noninvasively map this vascularity of the ovarian follicles. Thus, we aimed to study the association of perifollicular vascularity and pregnancy outcome in women while on treatment for an *in vitro* fertilization cycle. **Material and Methods:** A prospective study on 200 participants evaluated the vascularity of 1008 follicles on the day of oocyte retrieval to outline a map depicting perfusion of each follicle. The vascularity was graded based on percentage of the perifollicular outline in the map depicting vascularity which was Grade 1 $\leq 25\%$, Grade 2 26-50%, Grade 3 51-75%, Grade 4 76-100%. **Results:** Of 1008 follicles aspirated, only 733 follicles were analyzed as per the exclusion criteria. Grades III and IV follicles were high vascular grade follicle whereas Grades I and II were low perfused follicles. Six hundred and twenty-seven oocytes were retrieved from 733 follicles with majority from Grade III and IV vascularity (75.8%: Grade III and IV vs. 24.2%: Grade I and II). The number of oocytes exhibiting maturity and their fertilization rates were significantly higher in high vascularity follicles. Three hundred and forty-one Grade I embryos formed and 89.1% were from better-perfused follicles versus 10.9% from lower ones. **Conclusions:** The association between perifollicular perfusion and follicular oxygenation and oocyte maturation does exist which ultimately gets translated to quality of embryos. If other confounding factors such as endometrial receptivity and transfer technique are controlled, it influences the implantation potential too.

KEYWORDS: Oocyte quality, perifollicular vascularity, vascular perfusion

INTRODUCTION

Clinical and laboratory procedures have been constantly evolving to improve the success rate of *in vitro* fertilization (IVF) all over the globe. There are numerous factors which influence the success and in turn the clinical pregnancy rate in an IVF cycle, of which the major ones are patient selection, ovulation induction methods, oocyte retrieval technique, embryo quality, uterine receptivity, and embryo transfer technique.^[1] Among these, the significant ones affecting pregnancy and implantation rates are uterine, receptivity, embryo quality, and transfer efficiency. The quality of transferred embryos is in turn determined by the quality

of oocytes. Oocyte quality ultimately affects early embryonic survival, establishment, and maintenance of pregnancy, fetal development, and even adult disease. Developmental competence of an oocyte is acquired during folliculogenesis, its growth, and the period of oocyte maturation.^[2]

New markers of an oocyte's ability to develop into a healthy and morphologically good embryo are being pursued continuously. Understanding whether an

Address for correspondence: Prof. Nikita Naredi, IVF Specialist Assisted Reproductive Technology Centre, Command Hospital, Pune - 411 040, Maharashtra, India.
E-mail: nikitanaledi@gmail.com

This is an open access article distributed under the terms of the Creative Commons Attribution-NonCommercial-ShareAlike 3.0 License, which allows others to remix, tweak, and build upon the work non-commercially, as long as the author is credited and the new creations are licensed under the identical terms.

For reprints contact: reprints@medknow.com

How to cite this article: Naredi N, Singh SK, Sharma R. Does perifollicular vascularity on the day of oocyte retrieval affect pregnancy outcome in an *in vitro* fertilization cycle? J Hum Reprod Sci 2017;10:281-7.

| Access this article online | |
|---|---------------------------------|
| Quick Response Code:  | Website: www.jhrsonline.org |
| | DOI: 10.4103/jhrs.JHRS_43_17 |

oocyte is really “mature,” and ready to be fertilized, is of great help in choosing an embryo that will implant. In normal day-to-day embryology practice, it is the extrusion of the polar body (metaphase II) which is studied and found to be the only sign of maturity of the oocytes. In addition, understanding more about how the cytoplasm contributes to an oocyte’s competency is also a promising method of predicting which embryos will implant. Criteria which subdivide the quality of oocytes are classified into morphological, cellular, biochemical, and molecular.^[3] Further to these, newer modalities were introduced to qualify the oocyte competence, of which was the study of vascular supply of the ovarian follicles.

In the ovary, primordial and preantral follicles have no independent blood supply of their own and derive their vascularity from the stromal blood vessels. However, subsequently, the growth of the primary follicles leads to the development of a vascular network in the theca layer with increased follicular vascularity.^[4,5] It was observed that embryos from oocytes resulting from well-vascularized follicles had a higher implantation rate than those from oocytes developed in poorly vascularized follicles.^[6] The introduction of transvaginal power Doppler ultrasound (PDU) has facilitated noninvasive study of the vascularity of ovarian follicles in detail.^[7] Ovarian perifollicular blood flow (PFBF) assessment during IVF using PDU has been documented to be a good marker of oocyte competence, embryo viability, and implantation potential too.^[8]

Thus, we aimed to study the role of perifollicular vascularity in patients undergoing IVF cycle in predicting pregnancy outcome. The perifollicular perfusion by color Doppler ultrasonography (USG) was done and their correlation with the quality of oocytes and thus the embryo quality and pregnancy outcome were evaluated.

MATERIAL AND METHODS

This was a prospective study carried out at the Assisted Reproductive Technology (ART) Centre of a tertiary care hospital after getting approval by the Institutional Ethical Committee.

Inclusion criteria

This study was carried out on 200 subfertile women who met the following inclusion criteria: subfertile women <40 years of age, presence of both ovaries, lack of ovarian cysts, and undergoing IVF only through the long agonist protocol. Women were not part of the study protocol if fresh embryo transfer was not done due to any reasons: presence of endometrial polyp during stimulation cycle, poor endometrial thickness (<7 mm), ovarian hyperstimulation syndrome (OHSS), history of

partial or complete surgical resection of the ovary, history of or present endometriosis confirmed by laparoscopy, and presence of uterine lesions such as uterine myoma or documented congenital uterine anomaly confirmed by diagnostic hysterolaparoscopy. Women undergoing IVF due to male factor infertility were also excluded from the study.

Controlled ovarian hyperstimulation

All patients included in the study protocol underwent stimulation for IVF after downregulation by agonist long protocol, i.e., on 21st day of the menstrual cycle. Gonadotropin-releasing hormone agonist was introduced as daily subcutaneous injection leuprolide acetate 0.5 mg daily for at least 10 days until pituitary downregulation was confirmed by serum estradiol (E2) (<50 pg/ml) and ovarian quiescence as evident on transvaginal sonography. Recombinant follicle-stimulating hormone (FSH) injection (Gonal F, Merck Serono, Italy) was commenced for ovarian stimulation with the starting dose being determined by the patient’s profile. The dosage of FSH, thereafter, was individualized as per the ovarian response. Recombinant human chorionic gonadotropin (hCG; Ovitrelle: Merck Serono, Italy) 250 µg was administered for ovulation trigger when at least three follicles were ≥18 mm in mean diameter.

Oocyte retrieval

Ovum pickup was performed 36 h after the hCG injection transvaginally under USG guidance. The eggs collected were inseminated with prepared sperm 2–4 h following collection. Fertilization was confirmed 16–18 h later. Embryos were transferred transcervically into the uterine cavity under ultrasound guidance after 3 days of ovum pickup.

Luteal support

Luteal phase support was started from the day of ovum pickup with injection micronized progesterone 100 mg intramuscularly daily and tablet dydrogesterone (tablet Duphaston; Abbott) 10 mg twice daily.

Diagnosis of pregnancy

A successful IVF was confirmed when serum beta-hCG level was >50 mIU/ml. The test was done 15 days after the embryo transfer. Clinical pregnancy was confirmed with the visualization of a gestational sac on ultrasound 3 weeks after embryo transfer.

Power Doppler ultrasound examination

A Doppler ultrasound was performed transvaginally by a Logic P5 USG machine having a 8 MHz transvaginal probe on the day of ovum pickup on each participant. For all the scans, the velocity range, wall filter, and color gain were standardized in the USG machine. A map depicting the perfusion of each follicle was mapped

out depending on the vascular flow of the follicles using power Doppler imaging (PDI). The PDI enabled the subjective grading depending on the vascularity of each follicle. The grading system which was adopted was based on an estimation of the percentage of the perifollicular circumference in the “perfusion map” that depicted vascularity and thus the blood flow. It was as follows: Grade 1 $\leq 25\%$, Grade 2 26-50%, Grade 3 51-75%, Grade 4 76-100%.^[9]

The diameter and the location of each follicle to be studied within the ovary were also recorded. A maximum of ten follicles per patient were classified as “study follicles” before ovum retrieval. To aid in the identification of individual follicles at the time of oocyte collection, a hard copy of the print of the follicle position was kept [Figure 1].

Therefore, Grade 1 follicles had blood flow 1%–25% of the follicular circumference; Grade 2 follicles were vascularized to the extent of 26%–50% of the circumference, Grade 3 follicles had vascularity in 51%–75% of the follicular circumference whereas Grade 4 follicles were most vascularized with blood flow in 76%–100% of the follicular circumference [Figures 2 and 3].

As per previous authors, ovarian PFBF Grades 3 and 4 have been categorized as high-grade PFBF and Grades 1 or 2 as low-grade vascularity.^[9] We also incorporated Grades 1 or 2 as low-grade perfusion whereas Grades 3 or 4 as high grade. The mean follicular diameter of each studied follicle was also recorded.

Thereafter, the size of the follicle was calculated from the mean of two maximum diameters. The follicles were also divided into one of three categories according to the size range: small (5–10 mm), medium (11–14 mm), and large (≥ 15 mm). The “study follicles” as per our study protocol were a maximum of large ten follicles per patient which were selected before oocyte retrieval, defined as preovulatory follicles. The blood flow indices were measured consistently by the same ultrasound operator or the clinician and the surgeon.

Follicular fluid from all the studied follicles were aspirated in separate tubes and labeled. It was analyzed by the embryologist immediately for oocyte identification and classification of maturational status. The oocytes were cultured as per the laboratory protocol with the embryologist blinded to the blood flow indices. Oocytes were inseminated for IVF after sperm preparation by standard protocol. Before transfer the cleavage stage, embryos were visualized and a morphological grading was assigned to them. Embryos were either transferred under transabdominal ultrasound or cryopreserved as per the vitrification protocol.

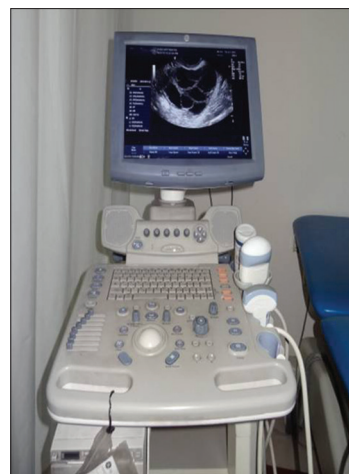

Figure 1: Study follicles before oocyte retrieval

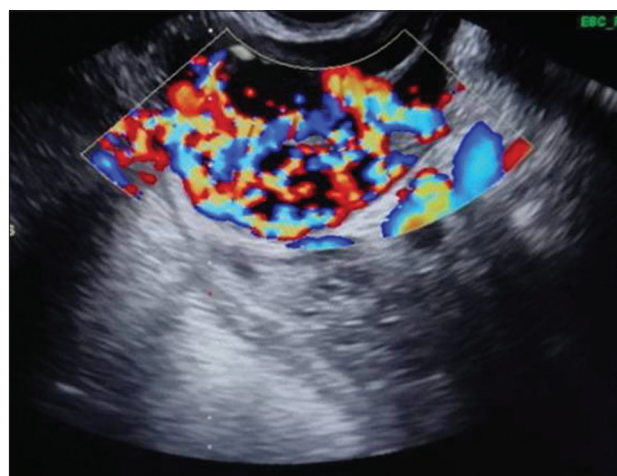


Figure 2: Grade 3 perifollicular vascularity: vascularization to the extent of 51%–75% of the circumference

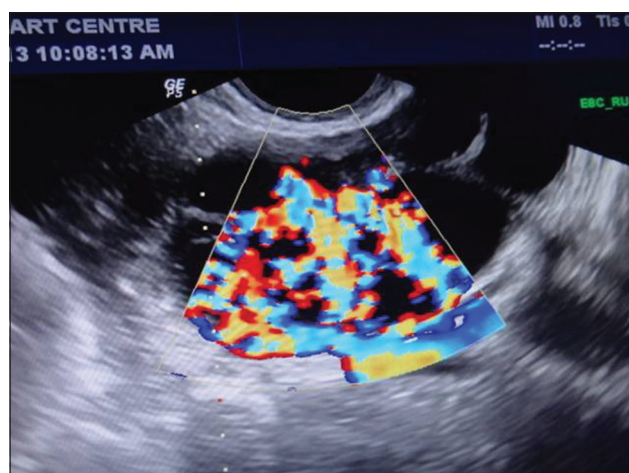


Figure 3: Grade 4 perifollicular vascularity: blood flow in 76%–100% of the follicular circumference

Statistical analysis

Data were analyzed as per the Statistical Package for the Social Sciences version 13.0 software (SPSS Inc,

Chicago; USA). Continuous data are presented as mean \pm standard deviation. Analysis of variance and independent samples *t*-test helped to study the potential confounding effects of continuous variables related to pregnancy. Chi-square test was applied to assess and compute the numerical data. $P < 0.05$ was considered statistically significant.

RESULTS

A total of 200 patients were included in the study. The patient demographic characteristics as well as the endocrine features and history of previous IVF cycles are depicted in Table 1. The mean age of patients undergoing the treatment cycle was 28.9 ± 3.5 years and the reasons for subfertility in the study group were as follows: Tubal 54.5%, unexplained 15.5%, male factor 16.5%, polycystic ovarian disease 7.5%, endometriosis 1.5% *t*, and a combination of one or more of these factors 22.5%.

A total of 200 patients were included in the study protocol after meeting the inclusion and exclusion

criteria; however, 26 study participants were further excluded from the final analysis due to the following reasons:

Nine women went into OHSS, two had endometrial polyps during the stimulation cycle, three had very poor endometrial thickness, eight had fertilization failure, and four had nil oocyte retrieval.

A total of 1008 follicles were studied. However, only 733 follicles were finally analyzed as the rest of the follicles belonged to the excluded patients who did not undergo embryo transfer as our primary outcome measure was to study the pregnancy rate. Table 2 summarizes the distribution of follicle vascularity grades of the 733 follicles. Grades III and IV follicles were high vascular grade follicle whereas Grades I and II were low perfused follicles [Figure 4]. It was seen that Grade 3 follicles were observed most frequently [Table 2], with 43.2% being Grade III followed by Grade IV (27.3%). It was observed that, of the 733 follicles aspirated, 627 oocytes were retrieved and maximum oocytes were from Grade III and IV vascular follicles (75.8%: Grade III and IV vs. 24.2%: Grade I and II). Oocyte retrieval, oocyte maturity, and fertilization rates were all significantly higher when high and low perifollicular vascularity grades were compared [Table 3]. Fertilization rate of 75.8% (475/627) was achieved in follicles of higher grades (III and IV vascularity) which was also significantly higher as compared to 24.2% from the lesser vascular follicles ($P < 0.01$).

Table 1: Patient characteristics

| Variables | Mean \pm SD | Range |
|---------------------------------|----------------|-----------|
| Total number of patients | 200 | - |
| Age (years) | 28.9 \pm 3.5 | 21.0-38.0 |
| Duration of infertility (years) | 5.7 \pm 2.1 | 2.0-12.0 |
| Baseline FSH value (IU/L) | 6.0 \pm 1.6 | 2.2-10.1 |
| BMI (kg/m ²) | 23.9 \pm 2.4 | 18.5-32.6 |
| Number of days of stimulation | 8.3 \pm 1.6 | 5.0-13.0 |
| Number of embryos transferred | 2.6 \pm 0.5 | 1.0-3.0 |
| Male factor | | |
| Present | 33 (16.5%) | - |
| Absent | 167 (83.5%) | - |
| History of IVF cycle | | |
| First | 132 (66.0%) | - |
| Second | 68 (34.0%) | - |

Table 2: Distribution of various vascularity grades in the study follicles

| Vascular grades | Frequency | Percentage |
|-----------------|-----------|------------|
| I | 36 | 4.9 |
| II | 180 | 24.6 |
| III | 317 | 43.2 |
| IV | 200 | 27.3 |
| Total | 733 | 100.0 |

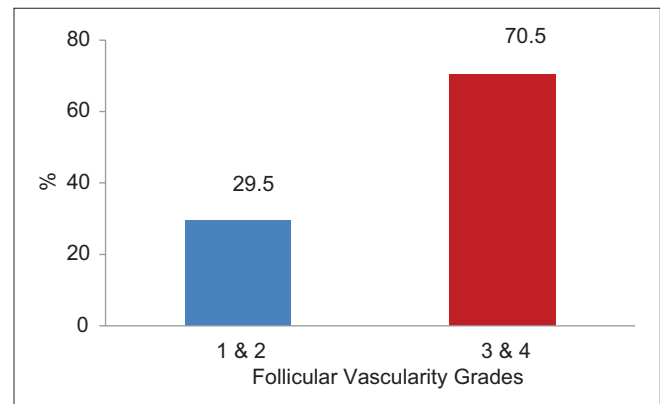


Figure 4: Distribution of high and low vascular follicles

Table 3: Embryology Parameters in relation to follicular vascularity grades

| Variables | Follicular vascularity | | | P (χ^2 [df=1]) (OR and 95% CI) |
|------------------------|------------------------|---------------|-------|--|
| | Grade 3 and 4 | Grade 1 and 2 | Total | |
| Total no. of follicles | 517 (70.5) | 216 (29.5) | 733 | |
| Oocytes | 475 (75.8) | 152 (24.2) | 627 | $P < 0.001$ (OR=4.8, CI=3.1-7.3) |
| Fertilized | 475 (75.8) | 152 (24.2) | 627 | $P < 0.001$ (OR=4.8, CI=3.1-7.3) |
| Grade I embryos | 304 (89.1) | 37 (10.9) | 341 | $P < 0.001$ (OR=6.9, CI=4.7-10.3) |

Three hundred and forty-one Grade I embryos were obtained and 89.1% of them were from better-perfused follicles as compared to 10.9% from low vascular follicles [Table 3]. The difference in the best quality embryos derived from higher vascularized follicles as compared to lesser vascularized follicles was also statistically significant.

Sixty-five women conceived out of the 174 who underwent embryo transfer giving a pregnancy rate of 37.35% per embryo transfer cycle. Data on clinical pregnancy rate and their relation to follicular vascularity when analyzed were seen that implantation occurred primarily from the “study embryos” derived from oocytes of follicles with the “highest vascularity.” Of the 733 follicles analyzed, 301 follicles were from the ovaries of women who conceived and the higher perfused follicles were also significantly more in this group [Table 4].

DISCUSSION

The advent of high-resolution USG scanning led to the formulation of uterine and ovarian sonographic markers which could enable the prediction of outcome in assisted reproductive treatment cycles.^[10,11] Of these markers, the computation of follicular blood flow using color Doppler imaging was elucidated to be a useful predictor of ovarian responsiveness and predict treatment outcome.^[12]

Chui *et al.* had observed that PD USG brought an improvement in the visualization of follicular vascularity and could grade the vascularity based on percentage circumference of the follicle depicting flow visibly. It was suggested that vascularity of the preovulatory follicles could possibly be a new parameter in the gradation of folliculogenesis adding to the traditional clinical and embryological criteria, for example, size of the follicles and fertilization rate.^[9]

In the present study, we prospectively analyzed individual follicular vascularity and micromilieu and assessed the developmental capacity of the corresponding oocyte–embryo. It was seen that the perifollicular color Doppler flow assessed on the day of oocyte recovery gives an insight of the oocyte–embryo

development in an IVF cycle. We observed that, of the 733 follicles aspirated, 627 oocytes were retrieved and maximum oocytes were from Grade III and IV vascular follicles (75.8% Grade: III and IV vs. 24.2% Grade: I and II). The percentage of oocytes retrieved, their maturity, and their rates of fertilization reached a statistical significance when high and low perifollicular vascularity grades were compared [Table 2]. This is in congruence with the findings of the work by Bhal *et al.*, who also deduced that the oocyte retrieval rate and their maturational stage were both significantly higher in their study as was the yield of mature eggs from high-grade vascularity follicles which reflects follicular maturity.^[13] However, Chui *et al.* disagreed to any association between oocyte retrieval rates and follicular vascularity.^[9]

Studies on ovarian vascular morphology and its hemodynamics have revealed an extensive and intense network of capillaries around the preovulatory follicles.^[14] As a consequence, initiation and subsequent growth and development of the follicles are dependent on the perifollicular microvasculature. Increased rates of blood flow increase the network of perifollicular vascular expansion flow and thus bring about the development of a normal follicle and ultimately a competent oocyte. This was evident in our study too wherein we found that greater number of fertilized oocytes and statistically significant number of Grade I embryos were more in higher perfused follicles as compared to Grade 1 and 2 vascularized follicles.

Lozano *et al.* observed 61 monofollicular IVF cycles and studied the follicle vascularization by transvaginal three-dimensional (3D) PD sonography. They also carried out quantitative analysis by colored/gray voxel ratio (vascularization index [VI]) and qualitative analysis by blood cell displacement (flow index [FI]) calculation. Their study concluded that a qualitative (FI) correlation was more than quantitative (VI) association between vascularity and functional status of the follicle after ovulation trigger.^[15] Our study was different in that vascularization on the entire follicle was done with a two-dimensional Doppler and it was for all the follicles and not using automated 3D reconstruction and PD technology which is in comparison to the expert computerized system (virtual organ computer-aided analysis [VOCAL]) that allowed the distinct analysis of quantitative and qualitative aspects. Lozano *et al.* were also of the opinion that just the quantitative study of perifollicular vascularity (VI) probably is a much less sensitive harbinger of a follicle’s reproductive capability than the computation of blood flow dynamics (FI) in the wall of the whole follicle. Thus, further studies

Table 4: Pregnancy outcome in relation to follicular vascularity

| | No of follicles among positive pregnancy (n=301) | 95% CI | P |
|-------------------|--|-----------|-------|
| Vascularity grade | | | |
| I and II | 70 (23.3) | 18.5-28.0 | 0.000 |
| III and IV | 231 (76.7) | 71.9-81.5 | |
| Embryos grade | | | |
| Grade I | 155 (51.5) | 45.9-57.1 | 0.000 |
| Grade ≥II | 108 (35.9) | 30.5-41.3 | |

should be conducted on the effect of drugs inducing vasodilatation and/or cardiotoxic drugs in an attempt to enhance follicle vascularization and consequently, oocyte quality.^[15]

Other workers too have assessed the ovarian PFBF semi-quantitatively applying the grading system (Grades 1–4) in IVF cycles with the help of PDU or color Doppler ultrasound (CDU).^[5-7] In these patients, the PFBF in the ovaries was estimated on the day of hCG trigger in the CDU study or on the day of ovum pickup in the PDU studies. These works by various authors have elucidated a significant enhancement in the pregnancy rate when embryos resulted from the fertilization of oocytes from better perfused follicles. In their study, Chui *et al.* demonstrated that oocytes derived from follicles with low-grade vascularity resulted in a significantly higher proportion of triploid embryos when compared to those derived from follicles with high-grade vascularity.^[9] Similarly, Bhal *et al.* depicted that the group with high-grade vascularized follicles had a significantly higher oocyte pick rate, maturity, and fertilization rate with significantly lower triploidy rate.^[13] The perifollicular microcirculation which is compromised induces hypoxia and it may thus cause an increased incidence of aneuploid oocytes. However, the fact which has been perplexing is, whether it is the ovulation trigger with hCG which alters the path of PFBF by the time ova are retrieved or the inherent vascular pattern of the follicle. It has been proven by various workers that the administration of hCG exogenously or the surge in luteinizing hormone endogenously increases angiogenesis of human ovarian follicles by increasing the production of the angiogenic factor vascular endothelial growth factor, locally.^[7] An adequate blood supply is the basic requirement for the control of intrafollicular oxygen levels and the determining factor of oocyte quality. Our study has also demonstrated or corroborated that better embryos and better pregnancy rates are obtained from better perfused follicles which ultimately decide the oocyte quality.

Robson *et al.* in their assessment of follicle vascularity using PD during oocyte retrieval found it to be reproducible and to add minimally to the workload of the clinician and embryologist. In their protocol, the grade of follicle vascularity did not correlate with the yield of oocytes, fertilization rate, or concentration of hormones in follicular fluid. Although their study group was small, there was a statistically significant trend toward higher clinical pregnancy rates when the embryo transfer cohort contained at least one embryo from a highly vascular follicle (50% vs. 15.4%) and their findings are in agreement to ours.^[16]

To have a better chance of pregnancy in ART cycles, synchronization between ovarian follicles and the endometrium is a must: a suitable oocyte (metaphase II) giving rise to a Grade I embryo and a highly receptive endometrium, i.e., around the implantation window. Therefore, it would be more prudent if utero-ovarian vascularity is assessed at the same time. This is the limitation of our study wherein we evaluated ovarian vascular status and correlated with the pregnancy rate without simultaneously assessing the endometrial and subendometrial blood flow. Nonetheless, we had excluded patients with poor endometrium in our study protocol.

Although our study has found a correlation between oocyte competence and pregnancy rate through its vascularization status, it has applied PD in its most basic form. Availability of better, sophisticated, and sensitive 3D PD technology, vascularization patterns of the entire follicle using automated 3D reconstruction can be done in an improved manner employing an expert computerized system (VOCAL) which would allow the distinct analysis of quantitative and qualitative aspects of follicle vascularization.

CONCLUSION

The association between perifollicular perfusion and follicular oxygenation and oocyte maturation does exist which ultimately gets translated to quality of embryos. If other confounding factors such as endometrial receptivity and transfer technique are controlled, it influences the implantation potential too. Larger studies may help in elucidating this aspect further and can thus be incorporated as a protocol for assessing the embryo quality.

Financial support and sponsorship

Nil.

Conflicts of interest

There are no conflicts of interest.

REFERENCES

1. Aflatoonian A, Asgharnia M. Factors affecting the successful embryo transfer. *Iran J Reprod Med* 2006;4:45-50.
2. Krisher RL. The effect of oocyte quality on development. *J Anim Sci* 2004;82 E-Suppl: E14-23.
3. Lasiene K, Vitkus A, Valanciute A, Lasys V. Morphological criteria of oocyte quality. *Medicina (Kaunas)* 2009;45:509-15.
4. Findlay JK. Angiogenesis in reproductive tissues. *J Endocrinol* 1986;111:357-66.
5. Gordon JD, Shifren JL, Foulk RA, Taylor RN, Jaffe RB. Angiogenesis in the human female reproductive tract. *Obstet Gynecol Surv* 1995;50:688-97.

6. Borini A, Maccolini A, Tallarini A, Bonu MA, Sciajno R, Flamigni C, *et al.* Perifollicular vascularity and its relationship with oocyte maturity and IVF outcome. *Ann N Y Acad Sci* 2001;943:64-7.
7. Van Blerkom J. Intrafollicular influences on human oocyte developmental competence: Perifollicular vascularity, oocyte metabolism and mitochondrial function. *Hum Reprod* 2000;15 Suppl 2:173-88.
8. Gregory L. Ovarian markers of implantation potential in assisted reproduction. *Hum Reprod* 1998;13 Suppl 4:117-32.
9. Chui DK, Pugh ND, Walker SM, Gregory L, Shaw RW. Follicular vascularity – The predictive value of transvaginal power Doppler ultrasonography in an *in-vitro* fertilization programme: A preliminary study. *Hum Reprod* 1997;12:191-6.
10. Kim SH, Ku SY, Jee BC, Suh CS, Moon SY, Lee JY, *et al.* Clinical significance of transvaginal color Doppler ultrasonography of the ovarian artery as a predictor of ovarian response in controlled ovarian hyperstimulation for *in vitro* fertilization and embryo transfer. *J Assist Reprod Genet* 2002;19:103-12.
11. Syrop CH, Willhoite A, Van Voorhis BJ. Ovarian volume: A novel outcome predictor for assisted reproduction. *Fertil Steril* 1995;64:1167-71.
12. Oyesanya OA, Parsons JH, Collins WP, Campbell S. Prediction of oocyte recovery rate by transvaginal ultrasonography and color Doppler imaging before human chorionic gonadotropin administration in *in vitro* fertilization cycles. *Fertil Steril* 1996;65:806-9.
13. Bhal PS, Pugh ND, Chui DK, Gregory L, Walker SM, Shaw RW, *et al.* The use of transvaginal power Doppler ultrasonography to evaluate the relationship between perifollicular vascularity and outcome in *in-vitro* fertilization treatment cycles. *Hum Reprod* 1999;14:939-45.
14. Clark JG. The origin, development and degeneration of the blood vessels of the human ovary. *Johns Hopkins Hosp Rep* 1990;9:593-676.
15. Lozano DH, Frydman N, Levaillant JM, Fay S, Frydman R, Fanchin R, *et al.* The 3D vascular status of the follicle after HCG administration is qualitatively rather than quantitatively associated with its reproductive competence. *Hum Reprod* 2007;22:1095-9.
16. Robson SJ, Barry M, Norman RJ. Power Doppler assessment of follicle vascularity at the time of oocyte retrieval in *in vitro* fertilization cycles. *Fertil Steril* 2008;90:2179-82.