


Role of secukinumab in ankylosing spondylitis with tubercular uveitis

*Padmamalini Mahendradas, Vikramraj K Jain¹,
Sherina Thomas, Ankush Kawali, Srinivasan Sanjay,
Bhujang K Shetty²*

Access this article online	
Quick Response Code:	Website: www.ijo.in
	DOI: 10.4103/ijo.IJO_1081_20

Department of Uveitis and Ocular Immunology Services, Narayana Nethralaya, ¹Department of Clinical Immunology and Rheumatology, Bhagwan Mahavir Jain Hospital, ²Department of Cataract, Narayana Nethralaya, Bangalore, Karnataka, India

Correspondence to: Dr. Padmamalini Mahendradas, Narayana Nethralaya, 121/C, Chord Road, Rajajinagar, 1st 'R' Block, Bangalore - 560 010, Karnataka, India. E-mail: m.padmamalini@gmail.com

Received: 21-Apr-2020

Revision: 01-Sep-2020

Accepted: 04-Sep-2020

Published: 26-Oct-2020

We present the case of a 32-year-old Indian male one-eyed individual with a history of unilateral panuveitis with HLA B 27 positive spondyloarthropathy on systemic immunosuppressant (Adalimumab). He developed recurrent inflammation in the same eye in a span of 2 years, later complicated with retinal vasculitis. On evaluation, he was diagnosed with tubercular uveitis and started on antitubercular treatment along with systemic steroids. In view of Increased IOP due to steroid response, Inj. Secukinumab (IL 17 A inhibitor) was started and significant improvement was noted.

Key words: IL 17A inhibitor, Secukinumab, spondyloarthropathy, tubercular uveitis

The management of ocular inflammatory diseases in the presence of active systemic infections or vice versa has always been a challenge especially with organisms like Mycobacterium tuberculosis. Incidence of reactivation of latent tuberculosis infection (LTBI) or active TB is high with most immunosuppressive agents. The role of Tumor Necrosis

This is an open access journal, and articles are distributed under the terms of the Creative Commons Attribution-NonCommercial-ShareAlike 4.0 License, which allows others to remix, tweak, and build upon the work non-commercially, as long as appropriate credit is given and the new creations are licensed under the identical terms.

For reprints contact: WKHLRPMedknow_reprints@wolterskluwer.com

Cite this article as: Mahendradas P, Jain VK, Thomas S, Kawali A, Sanjay S, Shetty BK. Role of secukinumab in ankylosing spondylitis with tubercular uveitis. Indian J Ophthalmol 2020;68:2569-72.

Factor (TNF) alpha in providing immunity to mycobacterial infections is well known.^[1,2] Anti TNF therapy leads to decreased levels of interferon-gamma production and also reduced expression of Toll-like receptor 4 on dendritic cells.^[3] In Rheumatoid arthritis, anti-TNF alpha inhibitors (especially Infliximab) among other biologics have been associated with increased risk of TB infection when compared to disease-modifying anti-rheumatic drugs.^[4]

In Ankylosing spondylitis (AS), the first-line treatment is mainly with non-steroidal anti-inflammatory agents (NSAIDs) and in active cases despite treatment, anti-TNF alpha agents have proved to be very effective. The newer agent, IL17-A inhibitor, has proved to be useful for (a) TNF inhibitor-naive patients with active AS, and also for (b) those who have a poor response to (or, are intolerant) to TNF inhibitors.^[5]

Secukinumab (Cosentyx®; Novartis International AG, Basel, Switzerland) is a recombinant human monoclonal antibody that selectively targets IL17-A and spares the T-helper (Th1) pathway. This target specificity allows a better safety profile for secukinumab among other biologics by preserving Th1 based host immunity.

Case Report

A 34-year-old Indian male patient presented to us with complaints of blurred vision, redness and eyepain in the left eye (LE) of 2 weeks duration. A fire cracker injury to the right eye resulted in a complete loss of vision in that eye. His best-corrected visual acuity was no perception of light in the right eye (RE) and 20/20P, N6 in the LE. Right eye examination showed corneal edema with old keratic precipitates (KPs), elevated intraocular pressure, and glaucomatous optic atrophy [Fig. 1a]. LE examination showed fine KPs, cells 2+, flare 2+, posterior synechiae, and deposits on the crystalline lens [Fig. 1b]. Posterior segment examination showed vitritis ++, hyperemic disc, and chorioretinal scars in the inferotemporal retina [Fig. 2a] He was diagnosed with LE panuveitis evaluated in detail for the possibility of sympathetic ophthalmia and it was ruled out. Fundus Fluorescein Angiography (FFA, Spectralis HRA, Heidelberg Engineering, Heidelberg, Germany) was done which showed mild disc and perivascular leak capillary nonperfusion (CNP) areas and staining of the chorioretinal scars in the inferotemporal quadrant in the LE [Fig. 2b and c]. His systemic investigations were normal (including Mantoux (negative) and Quantiferon TB gold test (Negative) with Normal Chest X Ray) except for a positive Human Leucocyte Antigen (HLA) B 27, hence referred to a rheumatologist. He was diagnosed with ankylosing spondylitis and started on

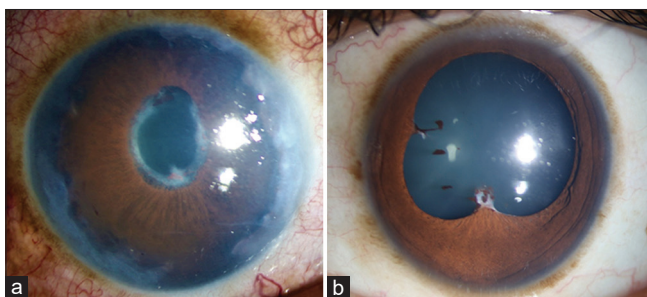


Figure 1: (a and b): Anterior segment photograph of the (a) right eye showing corneal edema, areas of sclera thinning with peripheral anterior synechiae and (b) left eye showing posterior synechiae and pigments on anterior lens capsule

immunosuppressive therapy along with continuation of topical medications and systemic steroids. Patient was asymptomatic for 2 years until he developed recurrence in the LE. At this point he was on Inj Adalimumab 40 mg taken once in 15 days for 7 months after complete evaluation in view of his systemic activity. On examination his RE was status quo, LE had a vision of 20/20, with fibrinous anterior chamber reaction, vitritis+ and retinal vasculitis in the superior quadrant [Fig. 3a]. FFA of LE revealed a delayed arm to retina time of 42 seconds, leakage and staining of retinal vessels in the superior quadrant and CNP areas in superotemporal quadrant with blocked fluorescence corresponds to retinal haemorrhages [Fig. 3b and c]. A diagnosis of LE panuveitis with retinal vasculitis was made and patient was investigated. He was found to be Quantiferon Tuberculosis test (QTB) positive, and was found to have, a "tree in bud" appearance on HRCT (high resolution computed tomography), but his sputum and BAL (Bronchioalveolar lavage) were negative for AFB (acid-fast bacilli). Systemic Methotrexate and Inj. Adalimumab therapy were stopped. He was started on topical prednisolone 1% eyedrops, ATT (anti Tubercular Therapy) with systemic prednisolone 1mg/kg, and targeted laser was given to the areas of CNP. Two days later patient worsened with an episode of lower respiratory tract infection, suspected pulmonary tuberculosis reactivation, and raised intraocular pressure of 30 mm Hg in the LE. Hence, topical prednisolone was changed to loteprednol etabonate 1%, systemic steroids were tapered to 20 mg OD, ATT was continued, injection Secukinumab 150 mg s/c (subcutaneous) once a week was added after 10 days of ATT and anti-glaucoma drops were started. Patient improved systemically and his ocular findings also improved gradually hence systemic and topical steroids were tapered and stopped [Fig. 4]. Patient completed 9 months course of ATT. He was given a total of 8 injections of s/c Secukinumab 150 mg weekly and later tapered to two weekly once followed by monthly schedule. At present patient's uveitis and ankylosing spondylitis is well under control with Secukinumab therapy.

Discussion

TNF alfa has an important role in the pathogenesis of uveal inflammation by recruiting leukocytes to the eye, chemokine production, promotion of leukocytes adhesion to vascular endothelium and it also promotes maturation of dendritic cells which acts as antigen-presenting cells and activate macrophages.^[6] In the pathogenesis of TB, TNF alpha regulates granuloma formation and hence the ability to restrict bacterial growth.^[7] So anti-TNF monoclonal antibodies (including infliximab, adalimumab, and certolizumab) pose a higher risk for reactivation of TB infection. Our patient was one eyed and he was doing well with Inj adalimumab. After two years of Methotrexate and 7 months of Adalimumab therapy for ankylosing spondylitis, he presented with panuveitis and retinal vasculitis, positive QTB gold test along with characteristic HRCT findings which according to the COTS nomenclature^[8] fell under TB panuveitis. Hence he was started on ATT and systemic steroids. But since the patient was a strong steroid responder and also one eyed, steroids were tapered and Inj. Secukinumab was tried to control the disease activity.

Secukinumab acts by the unique mechanism of selectively targeting IL-17A, a downstream product of Type 17 cells, and leaves the other functions of Th17 cells like release of IL-22 and TNF intact thus limiting the scope for off-target-related

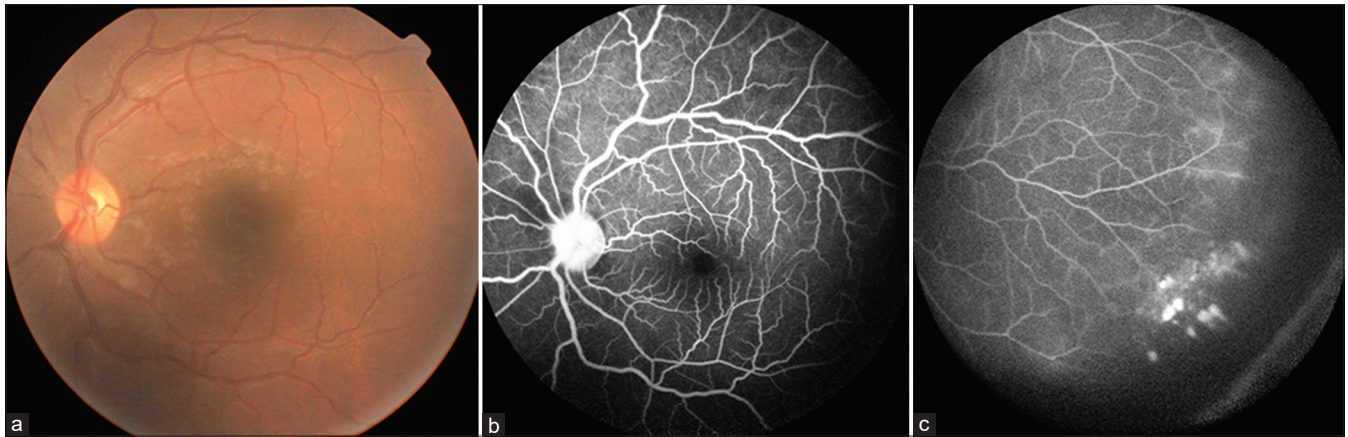


Figure 2: (a): Colour fundus photo of the left eye showing grade two media haze and mild hyperemia of the optic disc. (b and c): Fundus fluorescein angiography of the left eye showing (b) mild disc and perivascular leak (c) capillary non perfusion (CNP) areas in the inferotemporal quadrant and staining of the chorioretinal scars

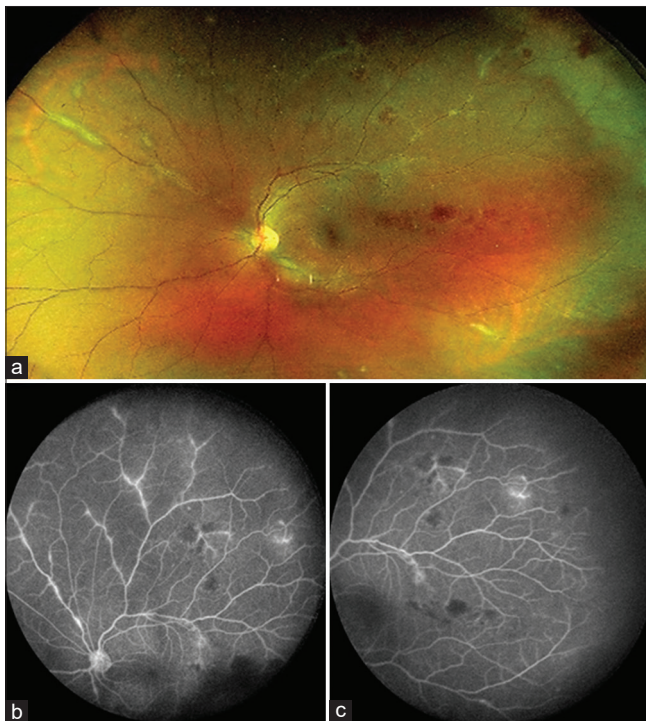


Figure 3: (a): Colour fundus photograph of the left eye showing retinal vasculitis with retinal haemorrhages. (b and c): Fundus fluorescein angiography of the left eye showing (b) leakage and staining of retinal vessels in the superior quadrant and (c) CNP areas in superotemporal quadrant

effects with secukinumab compared with other biologics.^[9] Secukinumab has been found to have a superior safety profile in the long term treatment of Psoriasis and AS with no increased rate of adverse effects over time.^[9] Our patient responded well to Inj Secukinumab along with systemic ATT.

Conclusion

Secukinumab can be a useful and safer alternative to TNF alpha-blockers in spondyloarthropathies with suspected TB especially when steroids are contraindicated. The role of Secukinumab in the treatment of ocular TB is still unexplored but may prove to be a promising option as steroid-sparing agent.

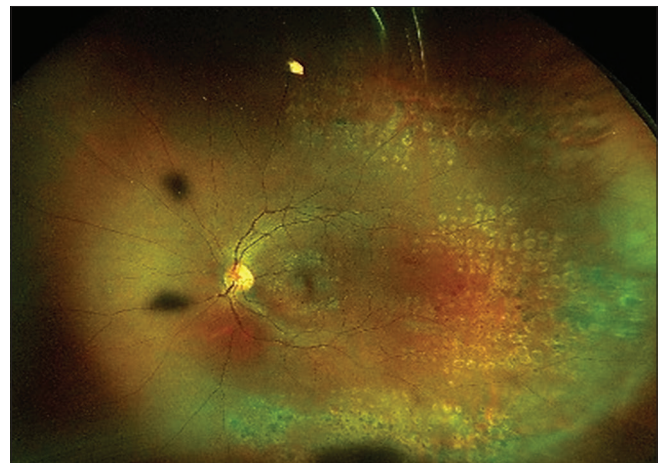


Figure 4: Fundus photograph of the left eye showing healed vasculitis with laser scars in the superotemporal, temporal and inferotemporal quadrant

Acknowledgement

We acknowledge Dr. Kushagra Jain for providing the fundus images.

Declaration of patient consent

The authors certify that they have obtained all appropriate patient consent forms. In the form the patient(s) has/have given his/her/their consent for his/her/their images and other clinical information to be reported in the journal. The patients understand that their names and initials will not be published and due efforts will be made to conceal their identity, but anonymity cannot be guaranteed.

Financial support and sponsorship

Nil.

Conflicts of interest

There are no conflicts of interest.

References

1. Winthrop KL, Baxter R, Liu L, Varley CD, Curtis JR, Baddley JW, *et al.* Mycobacterial diseases and antitumour necrosis factor therapy in USA. *Ann Rheum Dis* 2013;72:37-42.
2. Minozzi S, Bonovas S, Lytras T, Pecoraro V, González-Lorenzo M,

- Bastiampillai AJ, *et al.* Risk of infections using anti-TNF agents in rheumatoid arthritis, psoriatic arthritis, and ankylosing spondylitis: A systematic review and meta-analysis. *Expert Opin Drug Saf* 2016;15(Sup1):11-34.
3. Netea MG, Radstake T, Joosten LA, van der Meer JW, Barrera P, Kullberg BJ. Salmonella septicemia in rheumatoid arthritis patients receiving anti-tumor necrosis factor therapy: Association with decreased interferon-gamma production and Toll-like receptor 4 expression. *Arthritis Rheum* 2003;48:1853-7.
 4. Furst DE. The risk of infections with biologic therapies for rheumatoid arthritis. *Semin Arthritis Rheum* 2010;39:327-46.
 5. Blair HA. Secukinumab: A review in ankylosing spondylitis. *Drugs* 2019;79:433-43.
 6. Nakamura S, Yamakawa T, Sugita M, Kijima M, Ishioka M, Tanaka S, *et al.* The role of tumor necrosis factor-alpha in the induction of experimental autoimmune uveoretinitis in mice. *Investig Ophthalmol Vis Sci* 1994;35:3884-9.
 7. Ray JC, Flynn JL, Kirschner DE. Synergy between individual TNF-dependent functions determines granuloma performance for controlling Mycobacterium tuberculosis infection. *J Immunol* 2009;182:3706-17.
 8. Agrawal R, Agarwal A, Jabs DA, Kee A, Testi I, Mahajan S, *et al.* Collaborative Ocular Tuberculosis Study (COTS) Group. Standardization of nomenclature for ocular tuberculosis – results of collaborative ocular tuberculosis study (COTS) Workshop. *Ocul Immunol Inflamm* 2019;10:1-11.
 9. Deodhar A, Mease PJ, McInnes IB, Baraliakos X, Reich K, Blauvelt A, *et al.* Long-term safety of secukinumab in patients with moderate-to-severe plaque psoriasis, psoriatic arthritis, and ankylosing spondylitis: Integrated pooled clinical trial and post-marketing surveillance data. *Arthritis Res Ther* 2019;21:111.
-