

Image-guided vacuum-assisted breast biopsy in the diagnosis of breast microcalcifications

Jun Liu and Linping Huang

Abstract

Objective: The present study was performed to assess the accuracy and clinical value of image-guided vacuum-assisted breast biopsy in the diagnosis of mammography-detected breast microcalcifications.

Methods: This prospective study involved 100 patients with suspicious mammography-detected microcalcifications who underwent image-guided vacuum-assisted breast biopsies from January 2013 to October 2016. Stereotactic vacuum-assisted breast biopsy (SVAB) was performed in 64 patients, and ultrasound (US)-guided vacuum-assisted breast biopsy (US-VAB) was performed in 36 patients in whom application of SVAB was difficult. The microcalcifications were detectable by mammography or US. The mean follow-up duration was 32 months (range, 9–57 months). The biopsy results were correlated with the pathological examination results.

Results: The positive predictive value of microcalcifications detected by mammography and US in the diagnosis of breast cancer was 37.0% (37/100) and 52.8% (19/36), respectively. The negative predictive value of microcalcifications detected by US in the diagnosis of breast cancer was 71.9% (46/64). No recurrence was observed in the 37 patients with breast cancer. No evidence of malignancy was found among the 63 patients with benign lesions.

Conclusion: Image-guided vacuum-assisted breast biopsy is accurate and minimally invasive. It can be used as a safe approach for diagnosis in patients with breast microcalcifications.

Keywords

Image-guided breast biopsy, mammography, microcalcifications, ultrasonography, breast cancer, vacuum assistance

Date received: 16 January 2018; accepted: 22 March 2018

Breast Center, China-Japan Friendship Hospital,
Beijing, China

Corresponding author:

Liping Huang, Breast Center, China-Japan Friendship
Hospital, 2 Yinghuayuan Dongjie, Beijing 100029, China.
Email: hplsurg406@sina.com



Introduction

Microcalcification commonly refers to calcification of <1 mm in diameter, which is a major indicator of breast cancer. Since the widespread application of screening mammography, nonpalpable breast microcalcifications have been identified with increasing frequency. Hook-wire localization excisional biopsy was historically the gold standard for the diagnosis of breast microcalcifications. However, because 63.2% of microcalcifications are associated with benign outcomes,¹ hook-wire localization excisional biopsy is often an unnecessarily invasive means of diagnosis and affects the appearance of the breasts because it leaves a scar. As a result, some less invasive alternative procedures have been evaluated.^{2,3} Stereotactic vacuum-assisted breast biopsy (SVAB) is a minimally invasive and accurate procedure for the diagnosis of breast microcalcifications.⁴ This technique involves high-quality specimens, a high calcification retrieval rate, and a low false-negative rate, making it a preferred means of diagnosis for breast microcalcifications.^{5,6} However, SVAB has some limits. First, SVAB requires special equipment, including a three-dimensional positioning bed and a vacuum-assisted rotary cutting system, resulting in a substantially high medical cost. This factor makes promotion of SVAB difficult at lower-level hospitals in China. Second, SVAB is not suitable for biopsy when the breast size is small, the lesion is located at the edge of the gland or within the deep layer near the chest muscle or axilla, and in patients undergoing breast augmentation. When SVAB is difficult to perform or a mammography-guided localization puncture device is unavailable, ultrasound (US)-guided vacuum-assisted breast biopsy (US-VAB) is an alternative option if the calcifications are detectable by US. US-VAB has several advantages over SVAB, including real-time visualization of the needle position during tissue sampling and the lack of

ionizing radiation.^{7,8} Therefore, in the present study, we compared the accuracy and clinical value of US-VAB versus SVAB for diagnosis of mammography-detected breast microcalcifications.

Patients and methods

This prospective study was approved by the Ethics Committee of the China-Japan Friendship Hospital (Beijing, China). All patients gave written consent to undergo the invasive procedure after being fully informed about the possible risks and complications. Patients who underwent diagnosis of breast microcalcifications by vacuum-assisted breast biopsy (VAB) under mammography or US guidance from January 2013 to October 2016 were enrolled in this study. Screening mammography indicated that all patients had breast microcalcifications. All patients were examined by bilateral breast palpation, breast US, and mammography. No masses were found on clinical examination. Patients with American College of Radiology Breast Imaging-Reporting and Data System (BI-RADS) category 5 lesions were required to undergo biopsy. Patients with BI-RADS category 4 lesions were evaluated for calcification characteristics, and biopsy was recommended for those with clustered, regionally distributed, linear, and segmental calcifications of $>10/\text{cm}^2$. Follow-up was recommended for patients with BI-RADS category 3 lesions. Additionally, biopsy was performed in patients with severe mental stress or extreme fear of disease and in those who requested surgery. The patient and lesion characteristics are summarized in Table 1.

SVAB procedure

The patients underwent preoperative bilateral breast mammography to determine the locations of their calcifications using a

Table 1. Patient and lesion characteristics

Patient characteristics (n = 100)	
Patient age, years	45.4 (25–78)
Menopausal status	
Premenopausal	58 (58)
Postmenopausal	42 (42)
Family history of breast cancer	
Yes	24 (24)
No	76 (76)
Microcalcification location	
Left breast	59 (59)
Right breast	41 (41)
Microcalcification distribution	
Clustered calcification	59 (59)
Regional calcifications	30 (30)
Diffuse calcifications	7 (7)
Linear calcifications	3 (3)
Segmental calcifications	3 (3)
BI-RADS (lesion)	
3	8 (8)
4	87 (87)
5	5 (5)

Data are presented as mean (range) or n (%).

BI-RADS: Breast Imaging-Reporting and Data System.

prone stereotactic mammography system (Hologic, Marlborough, MA, USA). In patients with diffuse and regional calcifications, punctures were made at the site with the densest distribution of lesions. Biopsies were taken with the patients in the prone position, allowing the breasts to droop naturally. A splint was adjusted to fix the breast according to the location of the calcifications. Scout images were taken at 0° to confirm the presence of calcifications within the field of projection. If the calcifications surrounded the field of projection, the position of the splint was adjusted. Stereo images were then taken at +15° and –15°. The puncture target was determined from these two directions and the three-dimensional coordinates of the calculated target (Figure 1(a) and (b)).

A Mammotome system (Johnson & Johnson, New Brunswick, NJ, USA) and

a puncture needle (Johnson & Johnson) were connected. The puncture handle and needle were fixed onto the bracket of the mammography machine, and the needle was moved toward the puncture target. After local anesthesia was administered with 2 to 5 ml of 1% lidocaine, a 3- to 5-mm incision was made at the puncture point. The needle was inserted into the breast according to the three-dimensional coordinates of the target. Images were taken to confirm that the target was in front of the needle. After the needle was inserted, images were taken to ascertain whether the target was located at or near the groove of the needle. The needle was then rotated to cut the tissue serially according to the location of the calcifications. After completion of rotary cutting, breast images were taken to confirm complete or partial removal of the calcifications. The needle was then removed and the biopsy specimens were imaged to confirm the calcifications (Figure 1(c) and (d)). The puncture site was compressed for 10 minutes to stop the bleeding, and pressure dressing was applied with an elastic bandage for 3 days. Paraffin-embedded sections of the specimens were sent for pathological examination.

US-VAB procedure

US-VAB was performed when SVAB was difficult to apply. The microcalcifications were detectable by a color Doppler US system (Toshiba, Tokyo, Japan). The patients were placed in the supine position, and the calcifications were located by US. An appropriate puncture site was selected and marked. Following conventional disinfection and draping, local infiltration anesthesia was performed in all directions of the calcifications with 10 to 20 ml of 1% lidocaine under US guidance. A 3- to 5-mm incision was made at the selected puncture site using a sharp blade. A rotary blade was

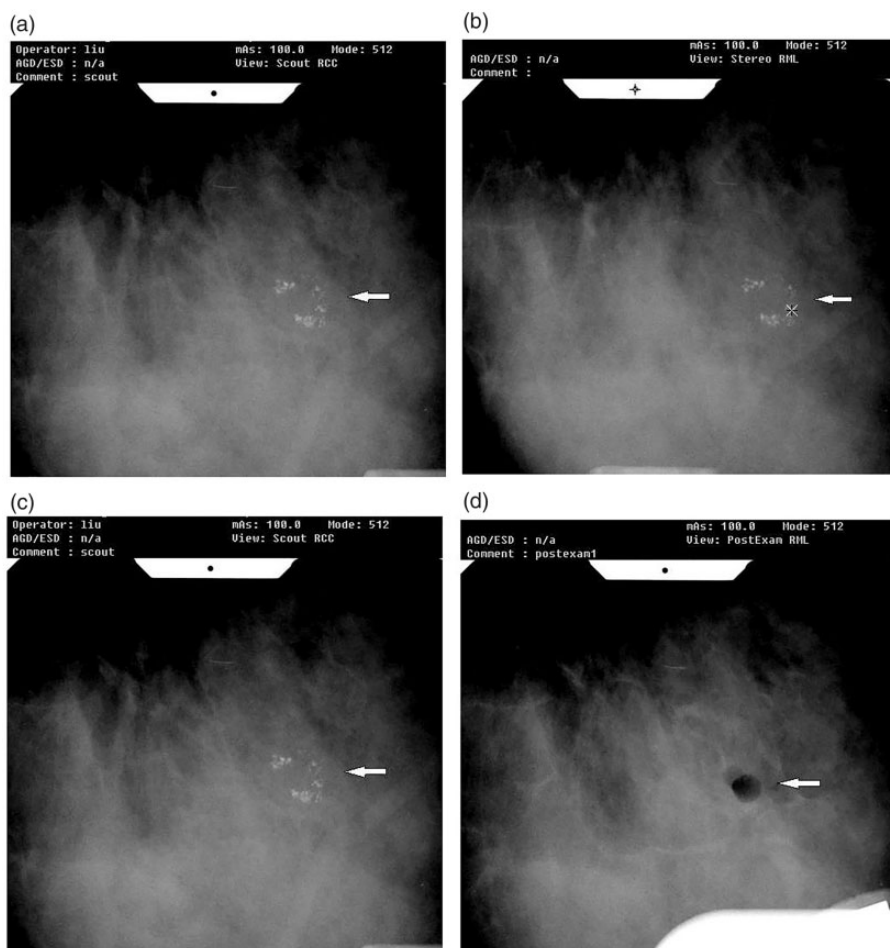


Figure 1. Stereotactic vacuum-assisted breast biopsy. (a, b) Stereo image before puncture shows the position of calcifications and puncture target spot. (c, d) The pre- and post-biopsy images show that the calcifications were completely removed. The white arrow indicates the position of the microcalcifications.

then inserted into the rear of the calcifications under US guidance. If necessary, the position of the blade was adjusted so that its groove targeted the lesions. Rotary cutting of the lesions was performed under US monitoring. The puncture needle was rotated in a fan shape for repeated rotary cutting. Mammography of the specimens was used to confirm the calcifications (Figure 2). After completion of rotary cutting, the puncture site was subjected to local

compression for 10 minutes followed by pressure dressing with an elastic bandage for 3 days. Paraffin-embedded sections of the specimens were subjected to pathological examination.

Postoperative treatment and follow-up

Postoperative treatment was performed based on the pathological examination results. Patients with breast cancer underwent

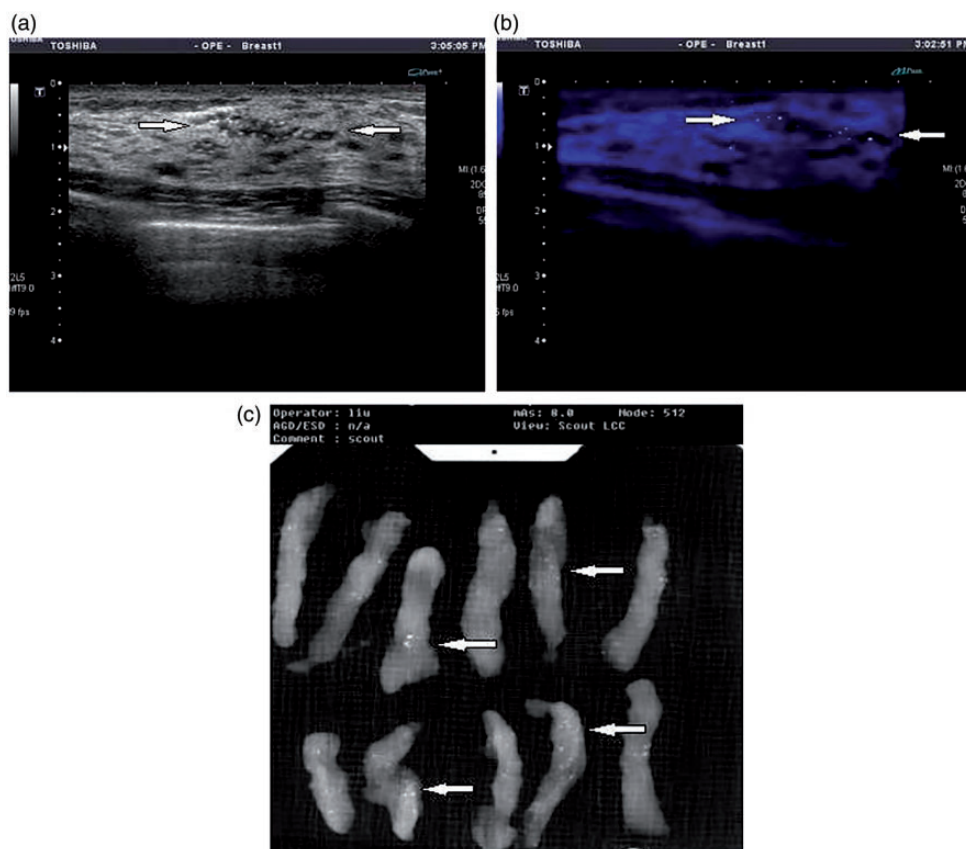


Figure 2. Ultrasound-guided vacuum-assisted breast biopsy. (a) Breast microcalcifications detected by ultrasound. (b) Microcalcifications detected by ultrasound (firefly technology). (c) Specimen mammography shows that the targeted microcalcifications were retrieved. The white arrow indicates the position of microcalcifications.

mastectomy or breast-conserving surgery in combination with sentinel lymph node biopsy or axillary lymph node dissection. These patients were re-examined every 4 to 6 months for 3 years after surgery to check for possible local recurrences and distant metastases. Patients with benign lesions were re-examined 3 months after surgery and then at 6-month intervals to check for postoperative complications and recurrence.

Statistical analysis

Student's t-test was performed for nondependent, normally distributed, random

variables. The χ^2 -test was performed for distribution characteristics. Fisher's test was performed for statistical analysis of contingency tables.

Results

Patients

In total, 100 patients who underwent diagnosis of breast microcalcifications by VAB under mammography or US guidance from January 2013 to October 2016 were enrolled in this study. The patients ranged in age from 25 to 78 years (mean, 45.4 years).

Breast microcalcifications were visualized in 36 patients by US and in all 100 patients by mammography. Fifty-nine patients had lesions in the left breast and 41 had lesions in the right breast. The lesions appeared as clustered calcifications (range, ≤ 1 cm) in 59 patients (detected by US in 17 patients), regional calcifications in 30 (detected by US in 15), diffuse calcifications in 7 (detected by US in 2), linear calcifications in 1 (not detected by US), and segmental calcifications in 3 (detected by US in 2). Eight lesions were classified as BI-RADS category 3, 87 were classified as BI-RADS category 4, and 5 were classified as BI-RADS category 5.

SVAB

SVAB was performed in 64 patients. The operating time ranged from 40 minutes to 2.5 hours (mean, 77 minutes). The rotary cutting duration was 10 to 50 minutes. Calcium was visualized by imaging and calcification was confirmed by pathological examination in all biopsy specimens. Forty-two lesions had clustered calcifications (range of ≤ 1 cm). Pre- and post-biopsy images showed that these calcifications were completely removed in 34 patients and partially removed in 8. Other types of lesions in the remaining 22 patients were partially removed.

US-VAB

US-VAB was performed in 36 patients. The operation time was 15 to 35 minutes (mean, 22 minutes). The rotary cutting duration was 5 to 10 minutes. Calcium was visualized by imaging and calcification was observed on pathological examination in all biopsy specimens. Seventeen lesions had clustered calcifications (range of ≤ 1 cm). Pre- and post-biopsy images showed that these calcifications were completely removed in 15 patients and partially removed in 2.

The remaining 19 lesions were partially removed.

The postoperative pathological diagnosis was ductal carcinoma in situ (DCIS) in 24 patients, 1 of whom had concomitant microinvasion. One patient had enlarged axillary lymph nodes and underwent modified radical mastectomy, 1 underwent lumpectomy and concomitant sentinel lymph node biopsy, and the remaining 22 underwent mastectomy and concomitant sentinel lymph node biopsy. Infiltrating ductal carcinoma was diagnosed in 12 patients, 1 of whom underwent lumpectomy and concomitant sentinel lymph node biopsy, 7 of whom underwent mastectomy and concomitant sentinel lymph node biopsy, and 4 of whom underwent modified radical mastectomy. Infiltrating lobular carcinoma was diagnosed in one patient who underwent mastectomy and concomitant sentinel lymph node biopsy. Additionally, three patients had atypical hyperplasia with concomitant microcalcifications and seven had breast fibroadenoma. The remaining 53 patients were diagnosed with adenosis with calcifications; 2 of these patients had fibrocystic hyperplasia, 19 had varying degrees of ductal epithelial hyperplasia, 13 had microcysts, 6 had fibroadenomas, and 2 had intraductal papilloma. These 53 patients received no treatment.

Microcalcifications were detectable by US in 36 patients. Segmental calcifications had the highest rate of detection at 66.7% (2/3), followed by regional calcifications at 50.0% (15/30), clustered calcifications at 28.8% (17/59), and diffuse calcifications at 28.6% (2/7); linear calcifications were not detected (0/1). Postoperative pathological examination showed DCIS in 13 patients and infiltrating ductal carcinoma in 6. In the 64 patients with microcalcifications that were undetectable by US, the postoperative pathological diagnoses were DCIS in 11 patients, infiltrating ductal carcinoma in 6, infiltrating lobular carcinoma in 1, and

Table 2. Correlation between type of mammographic abnormality and pathological diagnosis

Mammography	Ductal carcinoma in situ	Infiltrating ductal carcinoma	Infiltrating lobular carcinoma	Benign lesions
BI-RADS category				
5 (n = 5)	4	1	0	0
4 (n = 87)	20	11	1	55
3 (n = 8)	0	0	0	8
Distribution of calcification				
Cluster (n = 59)	15	4	1	39
Segmental (n = 3)	2	0	0	1
Diffuse (n = 7)	1	0	0	6
Regional (n = 30)	5	8	0	17
Linear (n = 1)	1	0	0	0
Morphology of calcification				
Coarse heterogeneous (n = 8)	1	0	0	7
Amorphous (n = 14)	1	0	1	12
Fine pleomorphic (n = 76)	22	12	0	42
Round (n = 2)	0	0	0	2

Table 3. Significance of microcalcification in the diagnosis of breast cancer

		Pathological diagnosis		Positive predictive value	Negative predictive value
Method		Malignant	Benign		
Microcalcification detected by mammography	+	37	63	37.0% (37/100)	
Microcalcification detected by ultrasound	+	19	17	52.8% (19/36)	71.9% (46/66)
	−	18	46		
BI-RADS category of microcalcification detected by mammography	4, 5	37	55	40.2% (37/92)	
	3	0	8		

atypical hyperplasia with concomitant microcalcifications in 3. The pathological diagnoses according to the mammographic appearance are shown in Table 2. The significance of microcalcification in the diagnosis of breast cancer is shown in Table 3. For the diagnosis of breast cancer, the positive predictive value of microcalcification detected by mammography and US was 37.0% and 52.8%, respectively ($\chi^2 = 2.721$).

Postoperative and follow-up results

No patients developed postoperative infections. One patient developed bleeding at the puncture site after surgery and was treated by re-bandaging with a pressure dressing. Nine patients had 2- to 4-cm subcutaneous ecchymoses that spontaneously absorbed within 3 months. No hematoma was observed near the incisions. The duration

of follow-up was 9 to 57 months (mean, 23 months). No recurrences occurred in the 27 patients with breast cancer. The incisions healed well. There was no evidence of malignancy in the 63 patients with benign lesions.

Discussion

Calcifications with diameters of <1 mm are usually defined as microcalcifications. Breast microcalcification is an important indicator of early-stage breast cancer. Some nonpalpable breast cancers can be identified by detecting microcalcifications on mammography.¹ In these patients, microcalcifications may be the only indicator of the diagnosis. However, microcalcification is not a specific indicator for breast cancer. Benign and malignant breast lesions with microcalcifications can be differentiated based on their morphology and distribution. Burnside et al.⁹ showed that with respect to morphology, the probability of malignancy is 7% in lesions with coarse heterogeneous calcifications, 11% for those with round calcifications, 20% to 26% for those with amorphous calcifications, 25% to 41% for those with fine pleomorphic calcifications, and $>80\%$ for those with linear and branched calcifications. The authors also showed that with respect to distribution, the probability of malignancy is 36% for lesions with clustered calcifications, 46% for those with regional calcifications, 68% for those with linear calcifications, and 78% for those with a segmental distribution.⁹ In the present study, the probability of malignancy was 0.0% for round calcifications, 12.5% for coarse heterogeneous calcifications, 16.7% for amorphous calcifications, and 44.7% for fine pleomorphic calcifications. Moreover, different distributions of calcifications detected by mammography had different probabilities of breast cancer. Seven lesions were classified as diffuse calcifications, only one of which was

malignant. However, in the 59 lesions with clustered calcifications and 30 lesions with regional calcifications, the rate of malignancy was 33.9% and 43.3%, respectively. Two of three lesions with segmental calcifications were malignant. One lesion with linear calcifications was malignant. These results are constant with previous reports.

In most cases, breast microcalcifications are identified by screening mammography; US cannot detect most microcalcifications. Lesions detected on mammography require stereotactic guidance for biopsy, and VAB is currently the preferred method for stereotactic biopsies.⁴ In the present study, the positive predictive value for a diagnosis of breast cancer after detection of microcalcifications by mammography was 37.0%, whereas that by US was 52.8%. We observed 18 cases of breast cancer among 64 patients with microcalcifications that were undetectable by US, indicating that mammography is of great value in breast cancer screening. The lesions identified by mammography were benign in all 8 patients with BI-RADS category 3 lesions, whereas cancerous lesions were found in 37 of 92 patients with BI-RADS category 4 and 5 lesions. The positive predictive value of BI-RADS category ≥ 4 lesions was 40.2% on mammography, indicating a strong possibility of breast cancer when microcalcifications of BI-RADS category ≥ 4 are detected.

SVAB is a preferred approach for diagnosis of breast microcalcifications. However, this approach requires a specific breast volume and calcification location. SVAB is not suitable for biopsy when the breast is small, when the lesion is located at the edge of the gland or within the deep layer near the chest muscle or axilla, or when the patient is undergoing breast augmentation. Moreover, specialized devices and complex procedures are required, and the procedure a long time to perform. Only a few hospitals in China are currently able to perform SVAB. US-VAB has several advantages

over SVAB. First, the patient can lie flat on the operating table and there is no need to compress the breast. Second, there is no radiation exposure. Third, the procedure is simpler and allows real-time confirmation of calcification removal. Finally, most hospitals have the US equipment required for US-VAB, thereby facilitating its extensive application.

However, US-VAB also has some disadvantages. The main drawback of US-VAB is that US cannot detect all microcalcifications. Mammography currently remains the gold standard for the diagnosis of breast microcalcifications. Because small microcalcifications show no obvious contrast with surrounding tissue, they are difficult to detect by US. Conversely, some calcifications detected by US are not visualized on mammograms. In the present study, US only detected 36.0% (36/100) of breast microcalcifications. US-VAB is more valuable when puncture biopsy is difficult to perform by SVAB and microcalcifications can be clearly distinguished by US.

VAB is an accurate diagnostic method for breast microcalcifications and can avoid unnecessary surgery, making it the preferred technique for guiding biopsies. The sample obtained by VAB is larger than that obtained by core needle biopsy¹⁰ and thus provides more an accurate pathological diagnosis. Penco et al.¹ and Huang et al.¹¹ reported that SVAB has a sensitivity of 99.7% to 100% and a false negative rate of 1.7% to 7.1%, which are better than those for catapult-type core needle biopsy (84% and 21%, respectively). The accuracy of US-VAB for diagnosing breast microcalcifications reportedly ranges from 94.4% to 95.9%.¹²⁻¹⁴ In the present study, VAB identified all cases of breast cancer, and no malignancy developed during follow-up in the lesions diagnosed as benign. Once again, this result confirmed the accuracy of VAB in the diagnosis of breast microcalcifications.

One reason for the high accuracy of VAB in the diagnosis of breast microcalcifications is its ability to retrieve calcification in breast lesions. The presence of calcification in biopsy specimens is critical for the diagnosis of breast microcalcifications. Failure to retrieve calcification may miss important lesions.¹⁵ The accuracy of retrieval of calcifications depends on the biopsy method and number of biopsy specimens.¹⁶ Multiple punctures with a catapult-type core needle in the same area retrieve progressively smaller amounts of tissue,¹⁶ whereas VAB can more easily retrieve 6 to 12 specimens from the same region. Calcifications are unable to be retrieved in only $\leq 5\%$ of SVAB procedures using 11-gauge needles¹⁷⁻¹⁹ but in up to 16% of procedures using 14-gauge catapult-type core needles.^{17,18} In the present study, all biopsy specimens contained calcifications, and 49 of 59 clustered calcifications were completely removed under image guidance. This may explain the higher accuracy obtained in this study than in others.

According to previous reports, up to 17.8% of postoperative diagnoses of DCIS diagnosed by SVAB are upgraded to infiltrating carcinoma,^{1,11} whereas up to 18.8% of DCIS diagnosed by US-VAB are upgraded to infiltrating carcinoma postoperatively.¹²⁻¹⁴ Diagnostic upgrading from DCIS is associated with the proportion of calcification removed by biopsy. The upgrade rate for DCIS is 23.0% for partial removal of calcifications and only 5.6% for complete removal.¹ In the present study, 24 patients had DCIS, including 1 with concomitant microinvasion. No diagnoses were upgraded postoperatively. Fifteen patients with DCIS had clustered calcifications, which were completely removed in 13 patients. The remaining 9 patients with DCIS had regional and segmental calcifications, which were partially removed. The low upgrade rate for DCIS in the present study may have been a result of the large

specimen size and complete removal of calcifications in most patients.

The complications of VAB include bleeding and infection. According to previous reports, the incidence of ecchymosis is 2.2%, and the incidence of hematoma ranges from 0.8% to 1.1%.^{20,21} The incidence of infection is extremely low (0.0%–0.1%).^{21,22} In the present study, no patients had infections. Ten patients had various degrees of bleeding; one had bleeding from the puncture site and nine had 2- to 4-cm subcutaneous ecchymoses. These complications were controlled with symptomatic treatment, and no hematomas developed.

Conclusion

Breast microcalcifications detected by mammography and US are very valuable for diagnosis of breast cancer. Image-guided VAB diagnosis is accurate and minimally invasive and has good cosmetic effects and few postoperative complications. It is an optimal approach for the diagnosis of breast microcalcifications.

Acknowledgements

We thank all staff members at the Breast Cancer Center of China-Japan Friendship Hospital (Beijing). We are also grateful to all patients for their participation in this study.

Authors' contributions

Jun Liu collected, analyzed, and interpreted the data and wrote the article. Linping Huang conceived and designed the study, provided critical revisions, and approved the final version of the manuscript. Both authors read and approved the final manuscript.

Declaration of conflicting interest

The authors declare that there is no conflict of interest.

Funding

This research did not receive any specific grant from funding agencies in the public, commercial, or not-for-profit sectors.

References

1. Penco S, Rizzo S, Bozzini AC, et al. Stereotactic vacuum-assisted breast biopsy is not a therapeutic procedure even when all mammographically found calcifications are removed: analysis of 4086 procedures. *AJR Am J Roentgenol* 2010; 195: 1255–1260.
2. Liberman L, Feng TL, Dershaw DD, et al. US-guided core breast biopsy: use and cost-effectiveness. *Radiology*. 1998; 208: 717–723.
3. Smith DN, Rosenfield Darling ML, Meyer JE, et al. The utility of ultrasonographically guided large-core needle biopsy: results from 500 consecutive breast biopsies. *J Ultrasound Med* 2001; 20: 43–49.
4. Esen G, Tutar B, Uras C, et al. Vacuum-assisted stereotactic breast biopsy in the diagnosis and management of suspicious microcalcifications. *Diagn Interv Radiol* 2016; 22: 326–333.
5. Jackman RJ, Burbank F, Parker SH, et al. Atypical ductal hyperplasia diagnosed at stereotactic breast biopsy: improved reliability with a 14-gauge directional vacuum biopsy. *Radiology* 1997; 204: 485–488.
6. Jackman RJ, Burbank F, Parker SH, et al. Stereotactic breast biopsy of nonpalpable lesions: determinants of ductal carcinoma in situ underestimation rates. *Radiology* 2001; 218: 497–502.
7. Liberman L. Percutaneous image-guided core breast biopsy. *Radiol Clin North* 2002; 40: 483–500.
8. Whitman GJ, Erguvan-Dogan B and Yang WT. Ultrasound-guided breast biopsies. *Ultrasound Clinics* 2006; 1: 603–615.
9. Burnside ES, Ochsner JE, Fowler KJ, et al. Use of microcalcification descriptors in BI-RADS 4th edition to stratify risk of malignancy. *Radiology* 2007; 242: 388–395.
10. Kettritz U. Minimally invasive biopsy methods-diagnostics or therapy? Personal opinion and review of the literature. *Breast Care (Basel)* 2011; 6: 94–97.

11. Huang PC, Cheung YC, Lo YF, et al. A comparison of spring-loaded and vacuum-assisted techniques for stereotactic breast biopsy of impalpable microcalcification lesions: experience at Chang Gung Memorial Hospital at Linkou. *Chang Gung Med J* 2011; 34: 75–83.
12. Kim HS, Kim MJ, Kim EK, et al. US-guided vacuum-assisted biopsy of microcalcifications in breast lesions and long-term follow-up results. *Korean J Radiol* 2008; 9: 503–509.
13. Cho N, Moon WK, Cha JH, et al. Ultrasound-guided vacuum-assisted biopsy of microcalcifications detected at screening mammography. *Acta Radiol* 2009; 50: 602–609.
14. Hahn SY, Shin JH, Han BK, et al. Sonographically-guided vacuum-assisted biopsy with digital mammography-guided skin marking of suspicious breast microcalcifications: comparison of outcomes with stereotactic biopsy in Asian women. *Acta Radiol* 2011; 52: 29–34.
15. Cho N, Moon WK, Chang JM, et al. Ultrasonography-guided vacuum-assisted biopsy of microcalcifications: comparison of the diagnostic yield of calcified cores and non-calcified cores on specimen radiographs. *Acta Radiol* 2010; 51: 123–127.
16. O'Flynn EA, Wilson AR and Michell MJ. Image-guided breast biopsy: state-of-the-art. *Clin Radiol* 2010; 65: 259–270.
17. Jackman RJ and Rodriguez-Soto J. Breast microcalcifications: retrieval failure at prone stereotactic core and vacuum breast biopsy-frequency, causes, and outcome. *Radiology* 2006; 239: 61–70.
18. Berg WA, Arnoldus CL, Teferra E, et al. Biopsy of amorphous breast calcifications: pathologic outcome and yield at stereotactic biopsy. *Radiology* 2001; 221: 495–503.
19. Gümüş H, Gümüş M, Devalia H, et al. Causes of failure in removing calcium in microcalcification-only lesions using 11-gauge stereotactic vacuum-assisted breast biopsy. *Diagn Interv Radiol* 2012; 18: 354–359.
20. Lee SH, Kim EK, Kim MJ, et al. Vacuum-assisted breast biopsy under ultrasonographic guidance: analysis of a 10-year experience. *Ultrasonography* 2014; 33: 259–266.
21. Agacayak F, Ozturk A, Bozdogan A, et al. Stereotactic vacuum-assisted core biopsy results for non-palpable breast lesions. *Asian Pac J Cancer Prev* 2014; 15: 5171–5174.
22. Park HL and Hong J. Vacuum-assisted breast biopsy for breast cancer. *Gland Surg* 2014; 3: 120–127.