

Nystagmus in enlarged vestibular aqueduct: a case series

Judith White, Paul Krakovitz

Cleveland Clinic, USA

Abstract

Enlarged vestibular aqueduct (EVA) is one of the commonly identified congenital temporal bone abnormalities associated with sensorineural hearing loss. Hearing loss may be unilateral or bilateral, and typically presents at birth or in early childhood. Vestibular symptoms have been reported in up to 50% of affected individuals, and may be delayed in onset until adulthood. The details of nystagmus in patients with EVA have not been previously reported.

The objectives were to describe the clinical history, vestibular test findings and nystagmus seen in a case series of patients with enlarged vestibular aqueduct anomaly.

Chart review, included computed tomography temporal bones, infrared nystagmography with positional and positioning testing, caloric testing, rotary chair and vibration testing.

Clinical history and nystagmus varied among the five patients in this series. All patients were initially presumed to have benign paroxysmal positional vertigo, but repositioning treatments were not effective, prompting referral, further testing and evaluation. In three patients with longstanding vestibular complaints, positional nystagmus was consistently present. One patient had distinct recurrent severe episodes of positional nystagmus. Nystagmus was unidirectional and horizontal. In one case horizontal nystagmus was consistently reproducible with seated head turn to the affected side, and reached 48 d/s. Nystagmus associated with enlarged vestibular aqueduct is often positional, and can be confused with benign paroxysmal positional vertigo. Unexplained vestibular symptoms in patients with unilateral or bilateral sensorineural hearing loss should prompt diagnostic consideration of EVA.

Correspondence: Judith White, Cleveland Clinic, 26900 Cedar Rd. 320-S, Beachwood, Ohio 44122 USA.

Tel.: +1.2168393999. E-mail: whitej3@ccf.org

Key words: vertigo, enlarged vestibular aqueduct, nystagmus.

Conflict of interests: the authors declare no potential conflict of interests.

Received for publication: 9 October 2014.

Revision received: 14 November 2014.

Accepted for publication: 14 November 2014.

This work is licensed under a Creative Commons Attribution NonCommercial 3.0 License (CC BY-NC 3.0).

©Copyright J.White and P. Krakovitz, 2015

Licensee PAGEPress, Italy

Audiology Research 2015;5:120

doi:10.4081/audiores.2015.120

Introduction

Enlarged vestibular aqueduct (EVA) is one of the most commonly identified congenital temporal bone abnormalities associated with sensorineural hearing loss. Hearing loss may be unilateral or bilateral, and typically presents at birth or in early childhood, although audiometric patterns are highly variable and may involve a low frequency conductive component, and progressive hearing loss has been commonly observed. EVA is defined as enlargement of the bony canal that extends from the vestibule to the posterior surface of the petrous temporal bone. Originally, enlargement of the vestibular aqueduct was defined as bony diameter greater than 1.5 mm at the midpoint based on polytomographic studies. High resolution computed tomography has been used to establish standardized measurement algorithms defining EVA as bony vestibular aqueduct diameter greater than or equal to 0.9 mm at midpoint and 1.9 mm at the operculum.¹ Bilateral EVA is frequently linked to Pendred syndrome (severe to profound hearing loss, inner ear anomalies, thyroid goiter and hypothyroidism). Genetic studies have identified SLC26A4 mutations affecting pendrin synthesis, a protein involved in iodine and chloride ion transport, as the most common genetic etiology. Unilateral EVAs are less likely syndromic, but a recent review by Grienwald,² reported bilateral hearing loss was present in 55% of their cohort of 74 patients with unilateral EVA findings radiographically, suggesting that defects of the membranous labyrinth in EVA may not always be associated with bilateral bony enlargement depending on the embryologic expression. Descriptions of vestibular complaints in patients with EVA have been more limited than audiometric reports. Patient complaints range from imbalance and incoordination to episodic vertigo, and reported incidence ranges widely from 12-71%.³⁻⁸ This is the first report to quantify positional nystagmus in patients with EVA. Persistent complaints of positional vertigo prompted referral and vestibular evaluation in this cohort of patients. The objective of this study was to describe the clinical history, vestibular test findings and positional nystagmus seen in a case series of patients with enlarged vestibular aqueduct anomaly.

Materials and Methods

Patients were identified retrospectively using electronic medical record review, meeting the following selection criteria: Seen by the author between 2009 and present, for persistent complaints of positional vertigo unresponsive to previous interventions, in a tertiary vestibular disorder center with detailed clinical history, computed tomography (CT) scan temporal bone with fine cuts [performed because of unilateral hearing loss or abnormal cervical vestibular evoked myogenic potential (c-VEMP)] which demonstrated EVA. Patients with EVA not complaining of positional vertigo were not included in this report. Audiograms were available for all patients. Vestibular testing included digitally recorded infrared nystagmography

with spontaneous, positional and positioning testing in all patients. Four of the 5 patients had caloric (warm and cool water), sinusoidal rotary chair 0.01-2Hz, oculomotor (saccades, pursuit and optokinetic nystagmus with full field stimuli) and sub-occipital neck vibration testing. All patients also had magnetic resonance imaging. One patient had c-VEMP, with abnormal threshold defined as less than or equal to 67 dB.

Results

Radiology

Three adults with unilateral EVA and one child (aged 9) with bilateral EVAs were identified based on radiological criteria: bony vestibular aqueduct diameter greater than or equal to 0.9 mm at midpoint and 1.9 mm at the operculum.¹ Cochlear and vestibular dysmorphism in addition to EVA was noted in one other adult. One adult had borderline bilateral radiological findings of EVA, incomplete visualization of apical and middle turn partitions in the cochlea, and is also included in this report because c-VEMP was bilaterally abnormal.

Hearing loss was variable. The 9-year old with bilateral EVAs (patient A) had a moderate down-sloping sensorineural hearing loss on the left (larger aqueduct) and a mild conductive hearing loss on the right. Three adults had severe to profound unilateral hearing loss present since childhood on the side of their unilateral EVA. The patient with borderline bilateral EVA and poorly visualized cochlear partitions had normal hearing but bilaterally abnormal c-VEMPs (62 and 67dB).

Clinical history and vestibular test findings

Patient A: A 9-year old child complaining of clusters of episodic vertigo lasting one to two hours, at times nearly daily, and persistent dizziness while lying on her side. Hearing loss identified in early childhood prompted CT temporal bones, identifying EVA. Hearing remains stable. Vestibular testing demonstrated normal caloric responses, normal rotary chair gain, phase and symmetry, normal oculomotor function, and reproducible 9 d/s symptomatic right horizontal nystagmus in left ear down positioning (without latency).

Patient B: A 44-year old female with no previous childhood history of vertigo, including competitive gymnastics participation. Patient had severe stable flat left unilateral sensorineural hearing loss since childhood, with 12% discrimination, but had never had radiological evaluation. She abruptly developed severe acute vertigo which lasted for days. This improved but she continued to have severe disequilibrium and nausea upon arising from the lying position. Vestibular therapy, using infrared video nystagmography, attempted repositioning for mild left torsional nystagmus in left Dix-Hallpike positioning, and the patient became severely nauseas upon arising, without observed nystagmus. She was referred for further evaluation. Using infrared video nystagmography with recording, 4 d/s left nystagmus (without latency) was found in all right ear down positions. CT scan was obtained, identifying left EVA. The patient complains of waxing and waning recurrent vertigo lasting seconds if she turns her head quickly to the right while sitting,

and declined additional vestibular testing.

Patient C: A 55-year old male with recollection of severe episodic vertigo, lasting days, throughout childhood, with a profound left sensorineural hearing loss identified when he began early school years, but had never had radiological evaluation. Vertigo ceased during young adulthood and has not recurred. For several weeks he had noted severe momentary disequilibrium with rapid seated head turn. This is severe enough that that it is limiting his work as a truck driver. Previous attempts at canalith repositioning were unsuccessful and he was referred. CT was obtained which identified EVA. Vestibular testing demonstrated normal caloric responses, normal sinusoidal rotary chair gain, phase and symmetry, and normal oculomotor function. Positional and positioning testing demonstrated 7 d/s left oblique downbeat nystagmus (without latency) throughout. Sub-occipital neck vibration reproduced the vertigo accompanying rapid head turn which was his presenting complaint, and provoked instantaneous 48 d/s recorded left nystagmus. Patient participated in eight visits to vestibular physical therapy to learn to avoid particularly provoking maneuvers, and utilize visual fixation to suppress nystagmus

Patient D: A 54-year old male without previous vertigo (and extensive childhood athletic experience), or hearing complaints who was noted to have a mildly asymmetric right sensorineural hearing loss when he was evaluated for abrupt sensation of twisting disequilibrium, intolerance for head movement and staggering to the right, which recurred and interfered with his occupation as a law enforcement officer. Vestibular physical therapy was not beneficial and he was referred for complaints of reproducible vertigo with rapid right seated head turns. CT was performed to evaluate semicircular canal dehiscence, and right enlarged vestibular aqueduct was identified. Vestibular testing demonstrated normal caloric, sinusoidal rotary chair, oculomotor, positional and positioning testing. Objective nystagmus during rapid seated right head turns could not be visualized, but patient's symptoms were reproduced.

Patient E: A 31-year old female with no prior history of hearing loss or vertigo who presented to vestibular physical therapy after a motor vehicle accident (mild closed head injury and loss of consciousness), complaining of severe vertigo with seated head turn. Physical therapy did not appreciate any nystagmus, and neck physical therapy did not improve complaint. Audiogram was normal, but c-VEMP was bilaterally abnormal (right 67 dB, left 62 dB). CT temporal bone was obtained which identified bilateral borderline enlarged vestibular aqueducts and incomplete visualization of apical and middle cochlear partitions bilaterally. Vestibular testing demonstrated normal caloric, sinusoidal rotary chair, oculomotor, positional and positioning testing.

In summary, these results suggest that the all four adults with EVA /borderline EVA evaluated for positional vertigo actually complained of brief vertigo with rapid seated head turn. In only one case this could be elicited in the office, when 48 d/s horizontal nystagmus was noted upon sub-occipital vibration, reproducing symptoms experienced during rapid head turn. The nine year old child had persistent positional nystagmus (9 d/s) but could not historically associate the recurrent vertigo with rapid head turns. Other vestibular test abnormalities were absent in the four patient who received full vestibular test batteries. Hearing

Table 1. Results summary.

| Case | Age | Hearing loss | EVA | Supine positional nystagmus | Vestibular testing |
|------|-----|---------------------|----------------------|-----------------------------|---------------------------------|
| A | 9 | Moderate bilateral | Bilateral | 9 d/s | Otherwise normal |
| B | 44 | Severe unilateral | Unilateral | 4 d/s* | - |
| C | 55 | Profound unilateral | Unilateral | 7 d/s* | Otherwise normal [#] 1 |
| D | 54 | Mild unilateral | Unilateral | None* | Normal |
| E | 31 | None ^o | Bilateral borderline | None* | Normal |

EVA, enlarged vestibular aqueduct. *Indicated complaint of vertigo with rapid seated head turn; [#]abnormal bilateral cervical vestibular evoked myogenic potential; ¹48 d/s horizontal nystagmus provoked by sub-occipital vibration.

loss was variable, ranging from normal to profound. The patient with normal hearing and bilateral borderline EVAs had abnormal c-VEMPs bilaterally (Table 1; Figure 1).

Discussion

Estimates of the occurrence of vertigo in patients with EVA vary. In prior research on EVA and vertigo, Sigiura⁷ associated episodic vertigo with fluctuating hearing loss in 12 patients, but this association has not been confirmed in Grimmer's cohort of 32.⁸ The most common vestibular test abnormality seen in patients with EVA is reduced caloric response, found in 80-86% of patients in Yetiser⁵ and Berrettini's⁶ published series. Selection of patients undergoing vestibular testing is probably biased towards those with vestibular complaints, but the incidence of reduced caloric responses in these 21 patients appears to be greater than the frequency of active vestibular complaints, since only 11 complained of vertigo. Conversely, Oh⁹ reported normal caloric responses in both their patients with vertigo and bilateral EVA, although one patient with normal caloric responses had decreased gain and increased phase lead at low frequency sinusoidal rotation, which normalized at higher frequencies. Sigiura⁷ reported 4 EVA patients with horizontal nystagmus recorded during acute vertigo episodes. In 2001, Oh⁹ reported a six year old girl with bilateral EVA who complained of vertigo with vigorous spinning in place, but no attempt was made to record nystagmus. Benign paroxysmal positional vertigo is the most common vestibular disorder in the general population. Song¹⁰ reported on five patients with both EVA and benign paroxysmal positional vertigo, noting that their benign paroxysmal positional vertigo (BPPV) was more likely to involve multiple canals, but *canalith repositioning procedures were usually performed without difficulty*. Manzari¹¹ has hypothesized that abnormalities in the bony or membranous vestibular aqueduct may predispose to BPPV recurrence.

BPPV is the most common vestibular disorder, and complaints of positional vertigo are often ascribed to this condition. This case series demonstrates that patients who present a clinical history suggestive for positional vertigo who do not have nystagmus typical of posterior or lateral semicircular canal BPPV, and do not respond to canalith repositioning should be further evaluated for underlying vestibular abnormalities. Hearing loss was present in 4 out of 5 of these patients and may be considered a *red flag* prompting CT scan to evaluate bony structural abnormalities of the otic capsule. The one patient with normal hearing had bilaterally abnormal c-VEMP thresholds, prompted imaging of the temporal bones. The presence of hearing loss in most of the patients in this series raises the possibility that vertigo episodes may have been associated with Meniere's syndrome. Several of the patients had a distant history of prolonged episodes of vertigo, lasting for hours to days. However, a diagnosis of Meniere's syndrome is based on the absence of other explanatory pathology, and these patients had known radiological EVA. In addition, the duration of current episodes of vertigo (lasting for seconds) and clear causal association with position change or rapid head turn on repeated occasions argue against endolymphatic hydrops as an explanatory etiology.

An additional differential diagnosis in patients with episodic vertigo is migraine. None of these patients reported headaches in association with their episodes of positional or head-turn induced vertigo. There was no family history of episodic vertigo or hearing loss.

An additional interesting observation was that all the adults in the series presented with the complaint of vertigo during rapid seated head turn (unilateral or bilateral). This complaint is unusual, and differentiates this group from those patients with typical benign paroxysmal positional vertigo, who usually complain of vertigo with lying back, sitting up, or rolling over in bed. In one case, sub-occipital vibration pro-

voked 48 d/s horizontal nystagmus towards the side of the EVA, and reproduced the patient's symptoms with rapid head turn. One explanation may be the anatomic configuration of the utriculo-endolymphatic valve. This valve, formed after the endolymphatic duct enters the vestibule and passes through the endolymphatic sinus, is formed by the utricular wall and duct.¹² A pressure wave of cerebrospinal fluid formed during rapid head rotation, and travelling through the enlarged vestibular aqueduct and endolymphatic duct, may stimulate the utricle (an otolith organ that senses linear acceleration), or possibly continue to the nearby cupula of the lateral semicircular canal. Horizontal nystagmus would be expected to occur in this model, as observed in this patient series. Computerized head thrust testing, growing in utilization, may offer additional diagnostic evaluation for patients with EVA complaining of positional vertigo. The rapid seated lateral head turn used in horizontal semicircular canal head thrust testing may elicit significant nystagmus in patients with EVA.

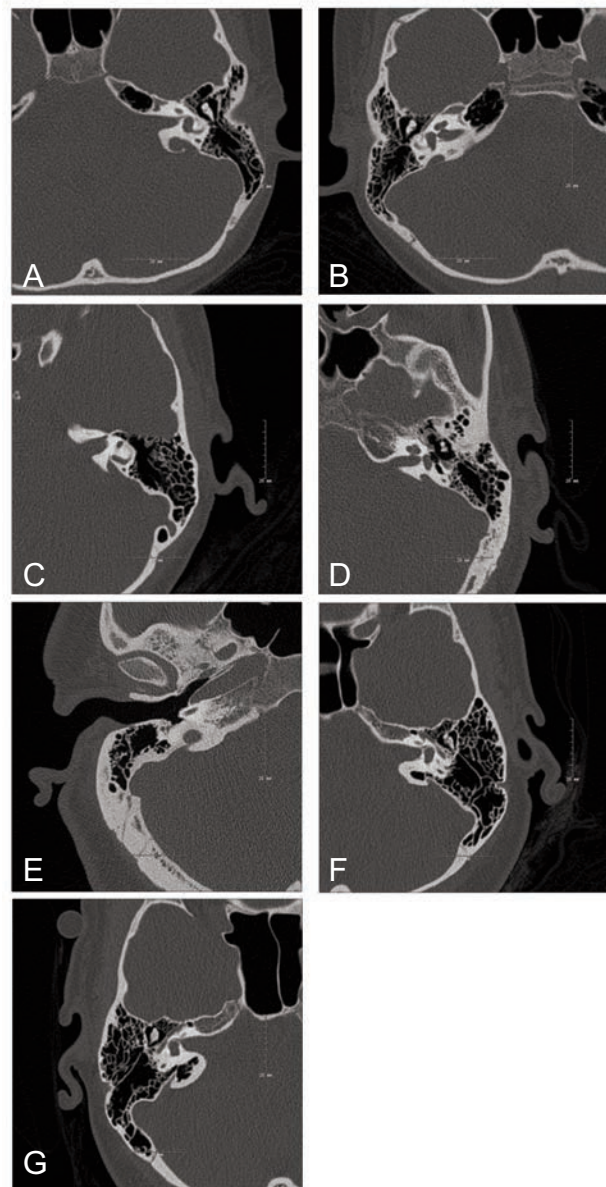


Figure 1. Axial computed tomography images showing EVA in A) case A left; B) case A right; C) case B; D) case C; E) case D; F) case E left; and G) case E right.

References

1. Vijayasekaran S, Halsted MJ, Boston M, Meinzen-Derr J, Bardo DM, Greinwald J, et al. When is the vestibular aqueduct enlarged? A statistical analysis of the normative distribution of vestibular aqueduct size. *Am J Neuroradiol* 2007;28:1133-38.
2. Greinwald J, de Alarcon A, Cohen A, Uweira T, Zhang K, Benton C, et al. Significance of unilateral enlarged vestibular aqueduct. *Laryngoscope* 2013;123:6:1357-46.
3. Emmett JR. The enlarged vestibular aqueduct syndrome. *Am J Otol* 1985;6:387-415.
4. Jackler RK, De La Cruz A. The large vestibular aqueduct syndrome. *Laryngoscope* 1989;99:1238-43.
5. Yetiser S, Kertmen M, Ozkaptan Y. Vestibular disturbance in patients with large vestibular aqueduct syndrome (LVAS). *Acta Otolaryngol* 1999;119:641-6.
6. Berrettini S, Forli F, Neri E, Salvatori L, Casani AP, Franceschini SS. Large vestibular aqueduct syndrome: audiological, radiological, clinical and genetic features. *Am J Otolaryngol* 2005;26:363-71.
7. Sigiura M, Sato E, Nakashima T, Sugiura J, Furuhashi A, Yoshino T, et al. Long term follow-up in patients with Pendred syndrome: vestibular, auditory and other phenotypes. *Eur Arch Otorhinolaryngol* 2005;262:737-43.
8. Grimmer JF, Hedlund G. Vestibular symptoms in children with enlarged vestibular aqueduct. *Int J Pediatr Otolaryngol* 2007;71:275-82.
9. Oh AK, Ishiyama A, Baloh R. Vertigo and enlarged vestibular aqueduct syndrome. *J Neurol* 2001;248:971-4.
10. Song J, Hong S, Kim S, Koo J. Enlarged vestibular aqueduct may precipitate benign paroxysmal vertigo in children. *Acta Otolaryngol* 2012;132:109-17.
11. Manzari L. Enlarged vestibular aqueduct (EVA) related with recurrent benign paroxysmal positional vertigo (BPPV). *Med Hypotheses* 2008;701:61-5.
12. Schuknecht HF, Gulya AJ. *Anatomy of the temporal bone with surgical implications*. Philadelphia, PA: Lea and Febinger; 1986.