



Contrast Kinetics in CT Coronary Angiography

Manphool Singhal^{1,*} Pavithra Subramanian^{1,*} Arun Sharma¹

¹Department of Radiodiagnosis and Imaging, Postgraduate Institute of Medical Education and Research, Chandigarh, India

Indian J Radiol Imaging 2025;35:234–241.

Address for correspondence Manphool Singhal, MD, DNB, FICR, FSCCT, FSCMR, Department of Radiodiagnosis and Imaging, Postgraduate Institute of Medical Education and Research, Chandigarh 160012, India (e-mail: drmsinghal@yahoo.com).

Abstract

Keywords

- contrast kinetics
- CT coronary angiography
- time-density curve
- peak aortic enhancement
- minimum scan delay
- test-bolus
- bolus-tracking

Computed tomography coronary angiography (CTCA) is a technically demanding radiological investigation that requires adequate opacification of coronary arteries at peak aortic enhancement phase, with minimal or no contrast in the superior vena cava and right-sided cardiac chambers to avoid streak artifacts of dense contrast. Therefore, it is prudent to know about contrast media, contrast kinetics, and contrast injection protocols. This article attempts to describe the essentials of various aspects of contrast media that should be considered for CTCA along with an in-depth analysis of contrast kinetics that every radiologist should know for obtaining adequate opacification of coronary arteries.

Introduction

Computed tomography coronary angiography (CTCA) is widely used for the diagnosis and follow-up of coronary artery diseases. It is also used in the diagnosis of other coronary artery pathologies, including, but not limited to, anomalous coronary origin and coronary artery aneurysms.

CTCA with electrocardiographic gating was practically possible after the advent of 64-multidetector CT. Hardware developments in CT scanners over the last few years, coupled with software advancements have allowed faster imaging with improved image quality. However, proper scan planning and adequate coronary contrast opacification are indispensable for the generation of reportable images. These are in turn dependent on the efficacious use of contrast material and accurate scan timing to image coronaries of the beating heart.

A thorough understanding of contrast kinetics is thus essential for the radiologist for planning CTCA, for not only obtaining adequate coronary arteries opacification, but also to avoid dense contrast in the superior vena cava (SVC) and

right-sided cardiac chambers. This article reviews the considerations and kinetics of intravenous contrast, pertaining to CTCA, including the time-density curve (TDC) and the factors affecting it. Contrast injection protocols and methods of timing the scan after contrast injection are also briefly discussed.

Catheter Angiography versus CTCA

Angiography is the radiological evaluation of a vessel of interest following the injection of radio-opaque contrast medium. This may be invasive or noninvasive. Catheter CA (CCA) involves peripheral artery access (radial or femoral) followed by cannulation of coronary ostium with catheter and injection of contrast. The principle of CCA is the replacement of the column of blood in the coronary artery with the contrast. Since there is no dead space, a small volume of contrast injected at physiological flow rate yields optimal opacification. On the other hand, in CTCA, contrast is injected in a peripheral vein, to opacify the coronary arteries. This requires a larger volume of contrast to replace the dead space between the site of injection and the area of interest. The contrast flow rate is accordingly

* Both authors contributed equally and share first authorship.

increased, using a power injector. A scan delay is set to allow for the transit of dead space, and the scan is synchronized with peak aortic enhancement. Opacification of coronary arteries in CTCA thus should be adequate—this translates not only to optimal (300–350 Hounsfield units [HU]) enhancement, but uniform attenuation of coronary arteries (without any difference in attenuation of contrast-filled coronary arteries).¹ Studies on the correlation of contrast attenuation in proximal coronary artery with subjective assessment of the enhancement quality showed that the evaluation of coronaries with attenuation less than 200 HU was suboptimal, and attenuation > 350 HU led to poor differentiation between opacified lumen and calcified plaques. Very high coronary artery attenuation can also underestimate the stenosis in the presence of noncalcified plaques. Hence, a coronary artery attenuation of 300 to 350 HU is considered ideal for optimal evaluation.^{2–4}

Contrast Agents in CTCA

Nonionic low or iso-osmolar iodinated contrast agents are used in CTCA. These consist of a tri-iodinated benzene ring, with various side chains containing alcohol groups, making them water soluble.^{5,6} The degree of radio-opacity is proportional to the amount of iodine present in the contrast agent.

Low-osmolar agents have an osmolality of less than three times that of human serum. These include iohexol (Omnipaque, GE healthcare), iopamidol (Isovue, Bracco), iopromide (Ultravist, Bayer Schering), and ioversol (Optiray, Covidien). These contrast media are available in many iodine concentrations; however, a high iodine concentration (320–400 mgI/mL) is recommended by the Society of Cardiovascular Computed Tomography (SCCT) for CTCA.⁷

Iso-osmolar contrast (iodixanol: Visipaque, GE Healthcare) is a low-osmolar iodinated contrast agent, with similar osmolality to the human serum. It is a nonionic dimer, consisting of two covalently bound tri-iodinated benzene rings. Iodixanol 320 is preferable for CTCA.⁷ Iodixanol has lesser incidence of contrast-related adverse effects and is particularly preferable in patients at a higher risk of contrast-induced nephropathy.^{8,9}

Temporal Changes in Contrast Circulation and Time-Density Curve

The temporal variation in contrast enhancement of the aorta/coronary arteries, following intravenous contrast injection through a pressure injector, is plotted as a TDC (►Fig. 1). From the injection site, the bolus travels through the venous circulation, first entering the right-sided cardiac

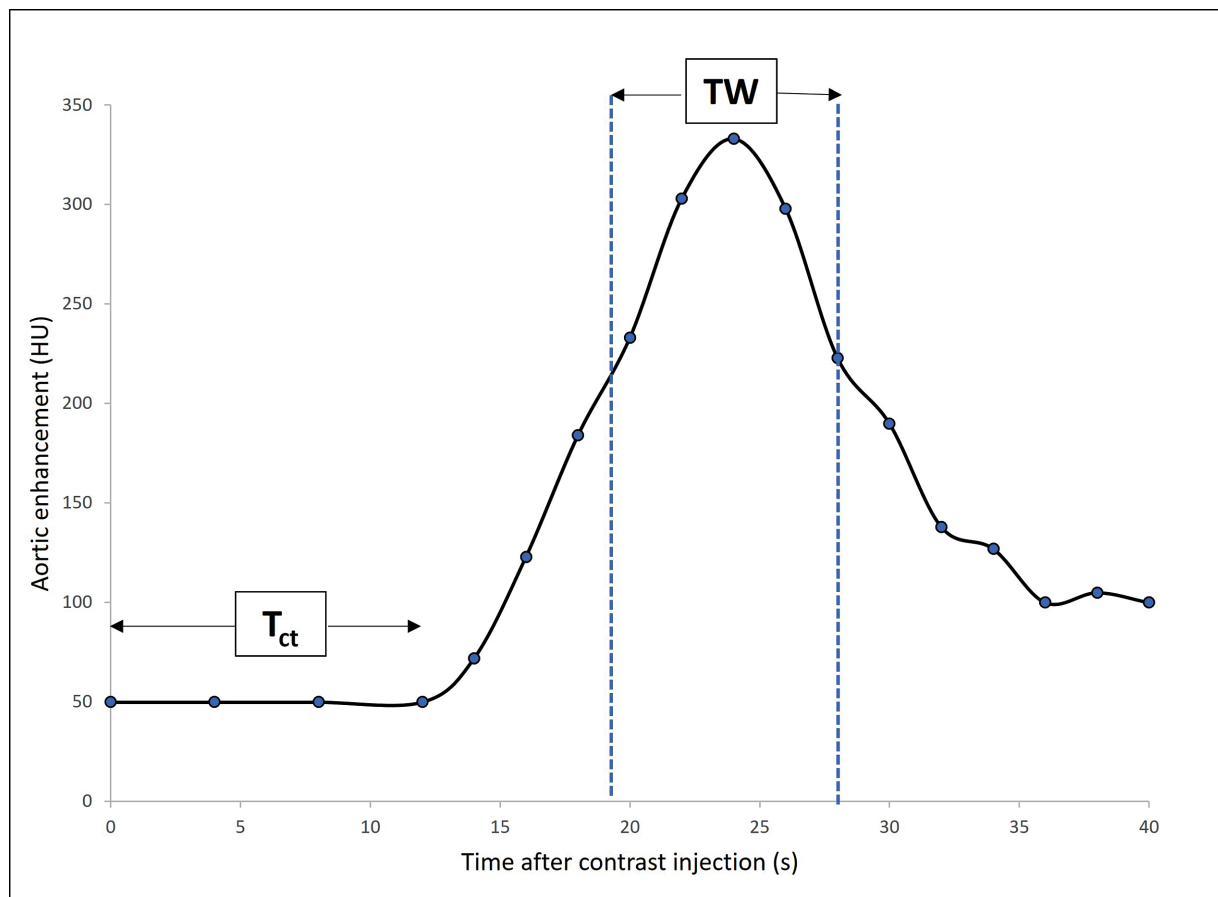


Fig. 1 Time-density curve representing temporal variation in aortic enhancement following pressure injection. T_{ct} represents the minimum scan delay, proportionate to the time taken for contrast to reach the aorta from the venous side. Following this, monitoring is done for aortic enhancement in the bolus-tracking technique. TW or temporal window (area within the blue dotted lines) represents the period of acquisition, during which there will be optimal, maximal contrast enhancement in the aorta and coronaries.

chambers, pulmonary circulation, and then left-sided cardiac chambers, where significant mixing and dispersion occur. This duration corresponds to the *minimum scan delay* (T_{ct}). During this time, there is no contrast in the aorta. As contrast reaches the aorta, consecutive axial scans are started to monitor the aortic enhancement in bolus tracking technique (discussed later). During this monitoring period, there is progressive increase in aortic enhancement.

Peak aortic enhancement is an approximately gamma-variate bolus geometry, with the peak width (duration of enhancement) proportional to the contrast injection time.¹⁰ It is imperative to note that the contrast-opacified blood reaching the aorta is continuously replaced by nonopacified blood coming from the systemic venous return.¹¹ The duration of contrast staying in the aorta corresponds to the *temporal window/width* (TW) of CTCA acquisition, during which the scan has to be acquired to ensure uniform and optimal opacification of the aorta and coronaries. TW is proportional to contrast volume and injection time.

In an ideal hypothetical situation, following single-dose contrast injection, aortic contrast enhancement curve will show a rapid rise, followed by a flat, broad plateau of steady-state enhancement and a decline of enhancement. However, in reality, aortic peak contrast enhancement is affected by hemodynamic perturbation and contrast recirculation. As a result, the plateau of contrast enhancement is not maintained, with a higher and narrower peak of contrast enhance-

ment. The peak can, however, be broadened by increasing the injection rate and iodine concentration (► **Fig. 2**).

Shorter injections (< 10 seconds) are not significantly affected by contrast recirculation. However, the TDC with short injections has a rapid rise, short peak, and a rapid fall, similar to a Gaussian curve. Thus, the optimal aortic enhancement (at least 250 HU) may not be achieved with a short injection duration.¹² Distal segments of the coronary arteries may not be sufficiently opacified with short injections.

With longer injection duration (> 20 seconds), contrast recirculation may occur even during the contrast injection. The newly injected contrast and the circulating contrast in the blood pool then summate, thus increasing the aortic enhancement proportionately. However, this may result in streak artifacts in the SVC/right atrium due to recirculation, leading to poor coronary evaluation.³

Therefore, the length of contrast injection has to be optimized in such a way that the acquisition of data occurs in the plateau phase (TW) matching the peak aortic/coronary enhancement with avoidance of contrast in SVC/right-sided cardiac chambers (more elaborately explained in contrast injection protocols).

Factors Affecting Time-Density Curve

The TDC is affected by multiple factors, mainly categorized into patient-related, contrast medium-related, and

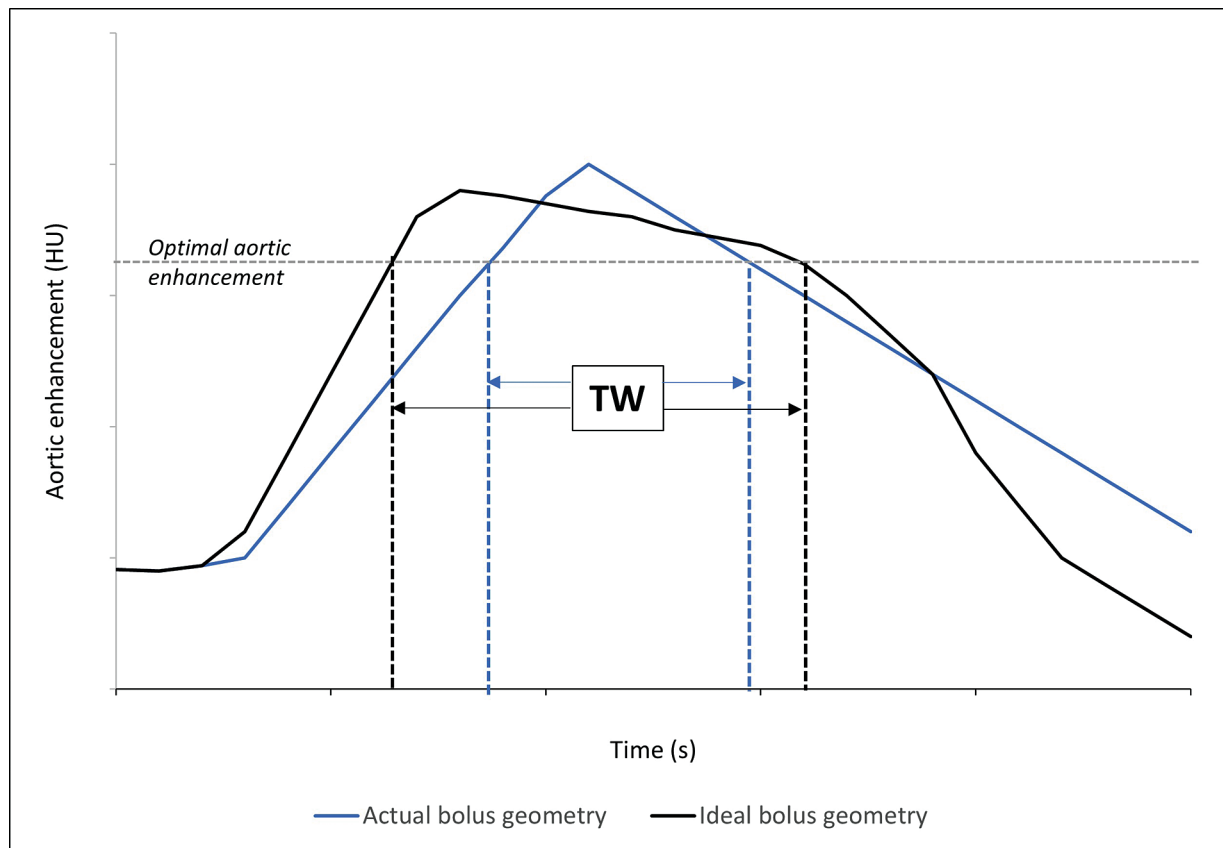


Fig. 2 Actual versus ideal bolus geometry. The blue-colored curve represents the actual bolus geometry, which has a short, high peak. The black-colored curve represents the ideal bolus geometry, which has a broad plateau representing the longer temporal window for acquisition (TW). Increasing the contrast injection rate and iodine concentration broaden the peak, optimizing the enhancement during the acquisition time.

injection-related factors. These are classified in ► **Fig. 3** and elucidated below.

Patient-Related Factors

Body weight is one of the important patient-related factors affecting contrast enhancement. It directly correlates with blood volume and extracellular compartment; so, a given volume of contrast material dilutes more in a larger patient than in a smaller patient. Thus, body weight is inversely proportional to the magnitude of contrast enhancement. As a result, patients with higher body weight need higher iodine load or higher injection rates to opacify the larger blood volume. A commonly used formula for adjusting the iodine mass to body weight is the 1:1 scale, that is, doubling the iodine mass with doubling body weight.¹³ However, since it considers the total body weight, the iodine mass required may be overestimated. Other recommendations consider lean body weight (LBW) and body surface area (BSA), instead.^{14–17} Since obese patients have a higher proportion of body fat and relatively small blood volume, LBW provides a more accurate estimate of contrast dose. The recommended formula for calculating LBW in men is $[1.10 \times W] - 128 [W^2 / (100.H)^2]$, and in women is $[1.07 \times W] - 148 [W^2 / (100.H)^2]$.¹⁴ BSA accounts for body height and weight and is less affected by changes in body fat¹⁶ and is calculated as $BSA (m^2) = (\text{square root of product of weight [kg]} \times \text{height [cm]}) / 60$.¹⁸ Studies have shown that estimating contrast dose based on BSA and LBW yielded better results and ideal contrast

opacification, in comparison with estimations based on total body weight.^{14,16,17}

Cardiac output affects the timing of contrast enhancement.¹⁹ It is directly proportional to the arrival time of the contrast bolus and inversely proportional to the degree of peak contrast enhancement. As cardiac output decreases, as is commonly encountered in various patients undergoing CTCA, the timing of the contrast peak is delayed due to slower circulation. Further, there is higher peak attenuation due to retained contrast and slower clearance from circulation, resulting in a prolonged contrast enhancement (broadened peak of TDC).²⁰ Conversely, the mean contrast enhancement is reduced in patients with higher cardiac output.²¹ These differences can be overcome by customizing the scan delay, and adjusting the contrast volume.^{22,23}

Other less influential patient-related factors include height, age, and gender. Relatively fewer studies have evaluated these factors. Blood volume increases with height, and there is a moderately strong inverse correlation between aortic attenuation and patient height.¹⁶ Estimations of contrast dose based on BSA include the effects of patient height. As cardiac output decreases with age, increasing age can lead to delayed contrast enhancement and this can be overcome by adjusting the iodine dose and injection rate accordingly.²⁴ Circulating blood volume in females is 5 to 10% lesser than males for given height and weight. As a result, despite administration of a fixed contrast dose adjusted to body weight, early bolus arrival and higher aortic enhancement are observed in females.²¹

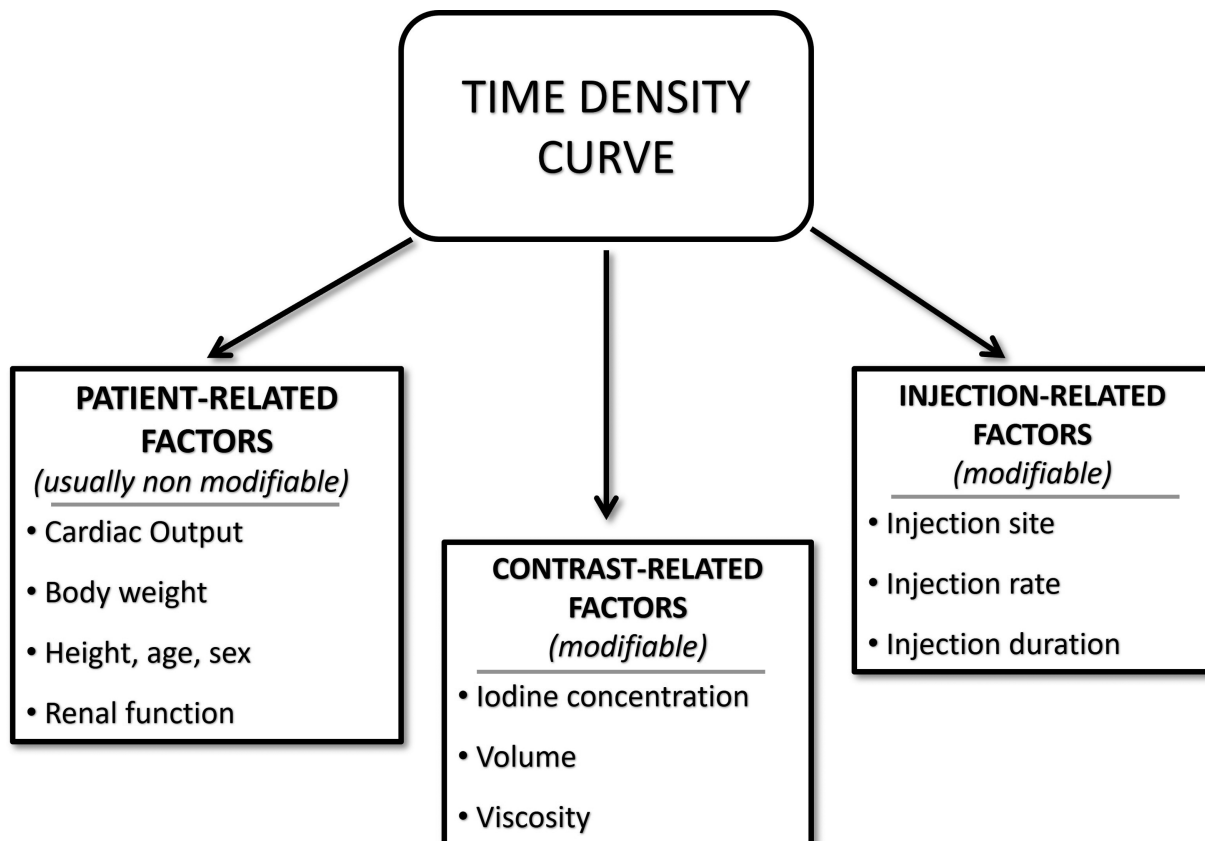


Fig. 3 Diagram showing major factors affecting the time-density curve.

Contrast Medium-Related Factors

The concentration of iodine in the contrast directly affects the magnitude of aortic enhancement. This is secondary to the increased absorption of X-rays by iodine, resulting in increased CT attenuation. When the tube voltage is constant, contrast opacification is proportionate to the iodine concentration (–Fig. 4). This relationship varies among scanners, however, is approximately 25 to 40 HU per mgI/mL at tube voltage of 100 to 120 kVp.²¹ As tube voltage is closer to the Kedge of iodine (33.2 keV), CT attenuation increases. Therefore, an iodine concentration of 1 mg/mL leads to attenuation of 30 HU at 100 kVp as compared to an attenuation of 40 HU at 80 kVp.^{25–27} The SCCT recommends an iodine concentration of 320 to 400 mgI/mL, for CTCA.⁷ Despite the linear relationship between iodine concentration and enhancement, higher concentrations are not recommended due to the increased risk of nephrotoxicity and streak artifacts in the right heart during the acquisition window.²⁸

Iodine volume is dependent on the scan time, flow rate, and the inherent delay for a particular scanner and scan. The contrast volume is calculated as follows²:

Contrast volume = (Scan time + inherent delay) × flow rate

Contrast viscosity is affected by the room temperature. Lower viscosity favors faster delivery of contrast. Warming the contrast agent to body temperature before injection hastens delivery. Warming the contrast has the same effect as increasing the flow rate.²¹

Injection-Related Factors

The venous access site is decided based on institutional protocol; however, an access closer to the heart is favorable to mitigate the dead space and circulation delay. The right antecubital vein is preferred as dense contrast in the left brachiocephalic vein across the midline may impair the evaluation of the aortic arch branches, which may have implications in patients with coronary artery bypass grafts. Hand veins are avoided, unless there is no other available access site. The location and size of the cannula should be able to withstand the high flow rate. The SCCT guidelines recommend an intravenous cannula of at least 18G in adults, and a 22G cannula in pediatric patients.⁷

Appropriate injection rate is essential for homogeneous enhancement, particularly of distal branches of coronary arteries. With constant volume and concentration of contrast, the injection rate is directly related to maximal enhancement and inversely related to the bolus arrival time. Faster injection results in earlier peak aortic enhancement and requires a quicker scan. With the older generation of CT scanners, acquiring such quick scans was difficult. However, with the newer, fast scanners and single-breath hold scanning protocols, flow rates of 4 to 6 mL/s are recommended in adults.⁷

The injection duration is critical for achieving optimal coronary opacification. It is the total contrast material volume divided by the contrast injection rate.²² Increasing the injection duration without reducing the rate, results in a larger contrast volume. Further, increasing the injection duration (by

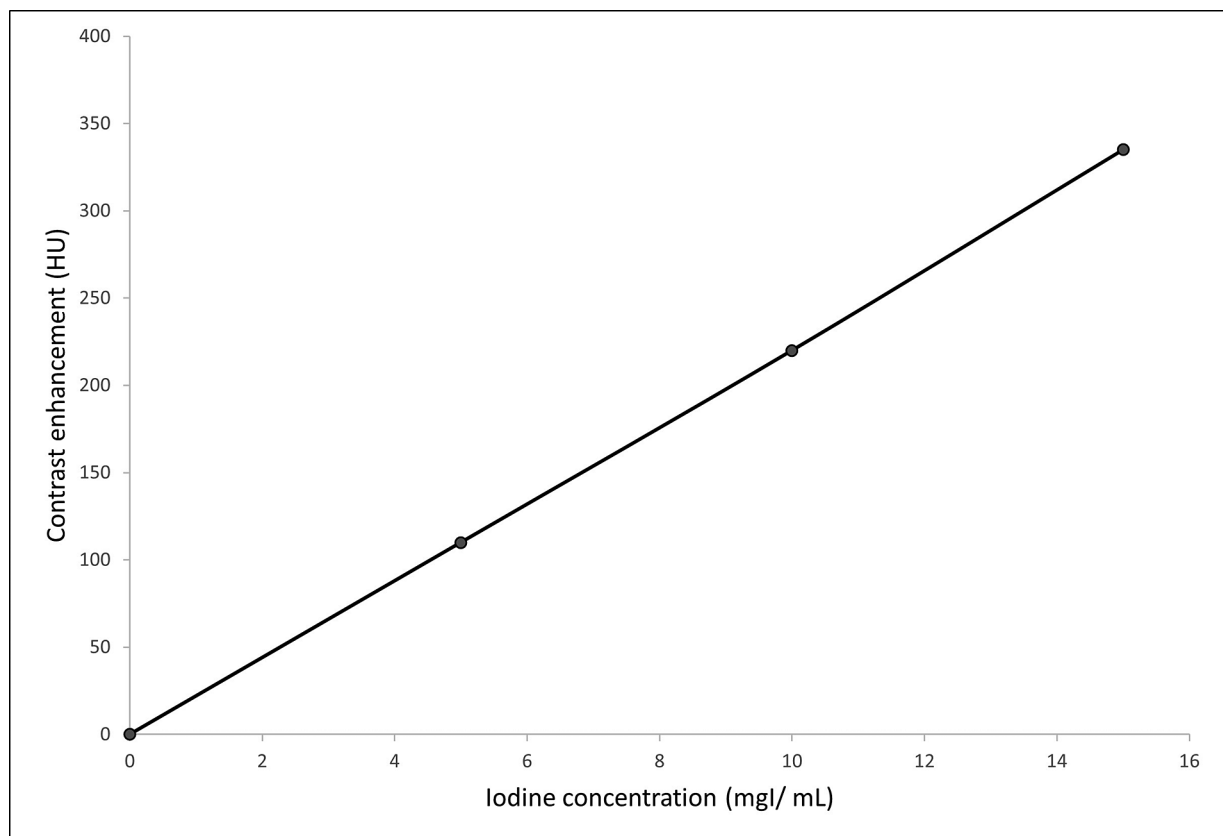


Fig. 4 Relationship between contrast enhancement of aorta/coronary arteries and iodine concentration. At constant tube voltage, there is a linear relationship between the iodine concentration and contrast opacification (more the iodine concentration in contrast, more is the attenuation in the aorta/coronary artery).

increasing the volume or reducing the injection rate) increases the time to peak contrast enhancement, necessitating a longer scan delay.^{13,19,29} A contrast injection duration of 10 to 20 seconds is considered optimal, and other confounding factors, such as cardiac output, need to be considered.⁷

Contrast Injection Protocols (Delivery Technique)

Contrast delivery technique affects the peak of the TDC. Prior to the development of dual-head power injectors, only contrast was injected intravenously using a uniphasic or biphasic technique. In the uniphasic technique, contrast is administered at a constant rate. In the biphasic technique, contrast is administered as a split bolus—a fast, constant injection followed by a slow, constant injection, to prolong the injection duration and hence the contrast peak.²¹ The biphasic technique was used with the older generation slow CT scanners.

With the advent of dual-head injectors, a saline chase or follow-through is administered after the contrast bolus. This has two main advantages—first, it clears off the injected contrast from the dead space, effectively reducing the contrast volume needed to opacify the coronaries. Second, the saline bolus “chases” the contrast into the left heart and ensures that the right heart and brachiocephalic vein are contrast-free during the acquisition. This eliminates the risk of streak artifacts arising from residual

contrast in the right heart.^{30,31} On the contrary, the tradeoff with this technique is that the right heart pathologies such as thrombus or tumor can be missed on a CTCA due to lack of opacification.

The saline flush is injected at the same flow rate as the preceding contrast bolus, and at least 18 mL of saline is needed to ensure that the contrast stays in the area of interest.³²

Scan Timing Determination

Accurate scan timing is essential to image the coronaries when they are maximally opacified. There are two techniques for determining the timing of scan following contrast administration—test-bolus method and bolus-tracking method.

In the *test-bolus method*, a small bolus (10–20 mL) of contrast is initially administered and the ascending aorta (target artery) is continuously scanned using minimal radiation, to estimate the TDC (►Fig. 5). Then, the scan delay is determined as follows²¹:

Scan delay = Time to peak + inherent delay

The posttrigger delay is decided based on factors such as the injection duration, scan duration, and the distance of target organ from the injection site. For a dual-source CT scanner, the inherent delay is 5 seconds.

In the *bolus-tracking method*, after the initiation of contrast injection, a region of interest (ROI) is placed in the

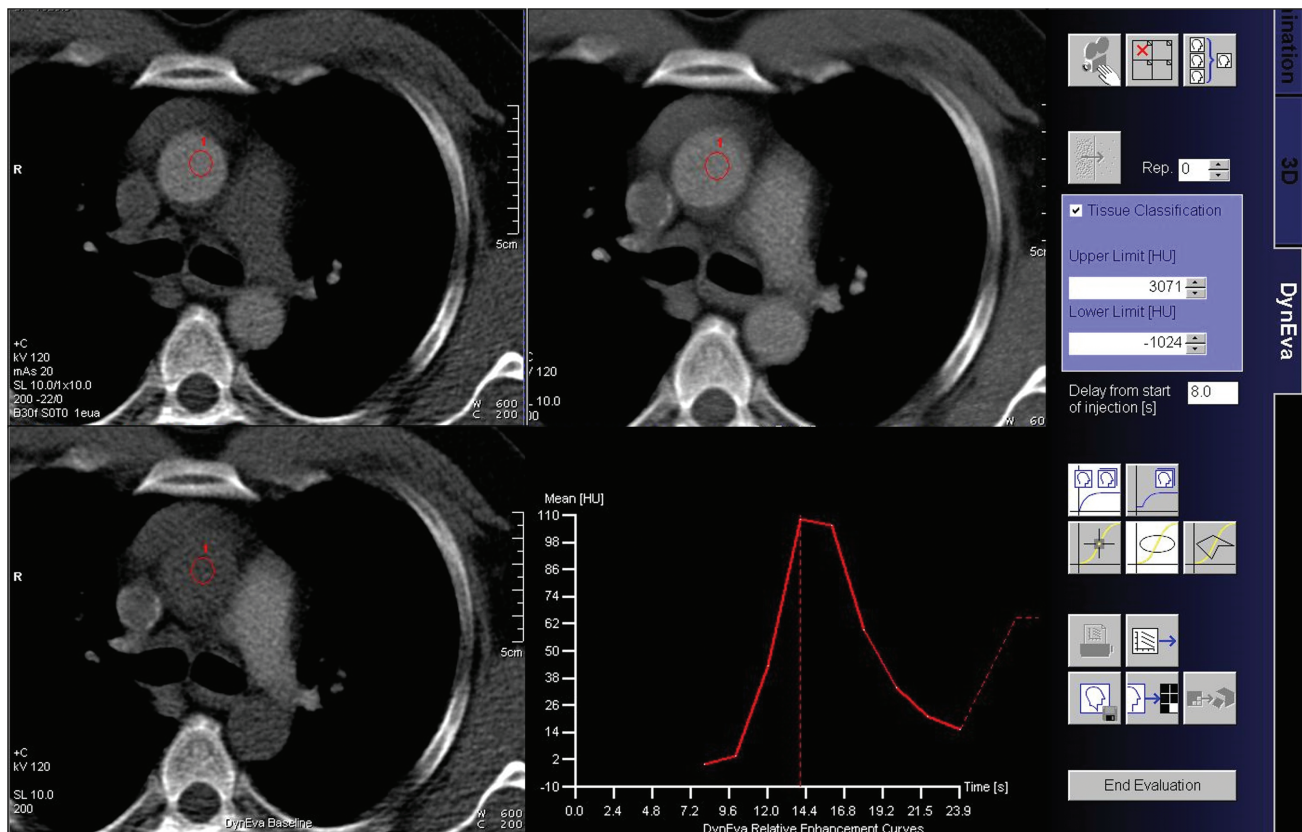


Fig. 5 Test-bolus technique. For computed tomography coronary angiography (CTCA), the region of interest is placed in the ascending aorta and low-dose scans are acquired following injection of a test dose of contrast. The time-density curve is plotted for the bolus and the scan delay time is automatically displayed based on software calculations.

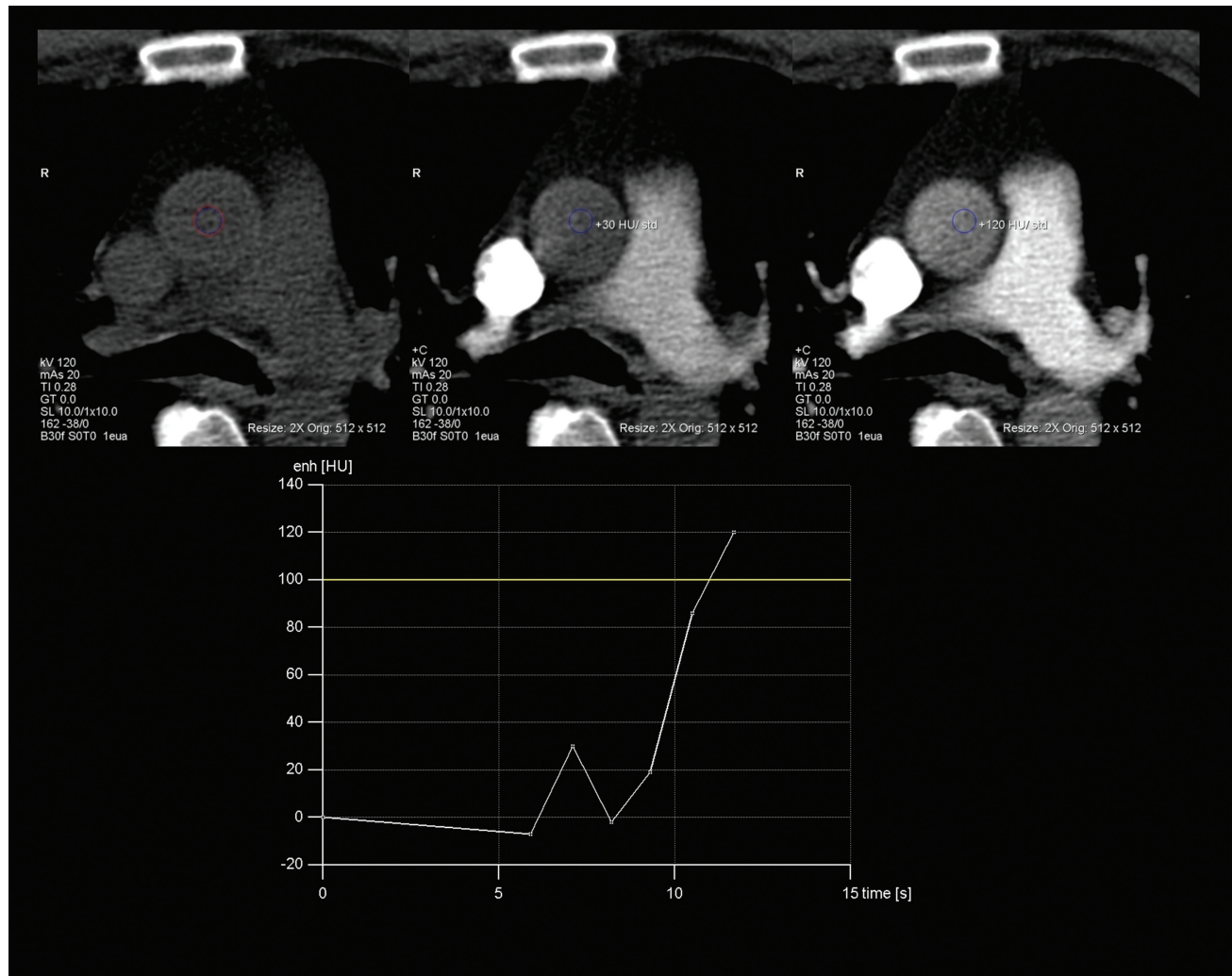


Fig. 6 Bolus-tracking technique. The region of interest is placed in the ascending aorta, followed by one-time injection of the complete contrast volume. The scan acquisition is automatically triggered when the threshold attenuation (100 Hounsfield units [HU] in this case) is reached.

ascending aorta and continuous low-dose single-slice scans are obtained at this level. When the attenuation in the ROI reaches a threshold (usually 100–150 HU), the scan is automatically started (→ Fig. 6). While the bolus-tracking method is easier to use, it has the disadvantage of interpatient variations of contrast enhancement due to posttrigger delay.¹²

Conclusion

CTCA is a state-of-art technique for the evaluation of coronary pathologies in adults and children. Understanding the principles of contrast kinetics is not only crucial in optimizing image acquisition and interpretation, but also for the judicious use of iodinated contrast media. The knowledge of factors affecting the TDC helps in tailoring the scan according to the patient.

Note

Authors declare this manuscript is solely submitted to IJRI and not submitted anywhere else.

Conflict of Interest
None declared.

References

- 1 Frydrychowicz A, Pache G, Saueressig U, et al. Comparison of reconstruction intervals in routine ECG-pulsed 64-row-MSCT coronary angiography in frequency controlled patients. *Cardiovasc Intervent Radiol* 2007;30(01):79–84
- 2 Johnson PT, Pannu HK, Fishman EK. IV contrast infusion for coronary artery CT angiography: literature review and results of a nationwide survey. *AJR Am J Roentgenol* 2009;192(05):W214–21
- 3 Becker CR, Hong C, Knez A, et al. Optimal contrast application for cardiac 4-detector-row computed tomography. *Invest Radiol* 2003;38(11):690–694
- 4 Johnson TRC, Nikolaou K, Wintersperger BJ, et al. Optimization of contrast material administration for electrocardiogram-gated computed tomographic angiography of the chest. *J Comput Assist Tomogr* 2007;31(02):265–271
- 5 Pasternak JJ, Williamson EE. Clinical pharmacology, uses, and adverse reactions of iodinated contrast agents: a primer for the non-radiologist. *Mayo Clin Proc* 2012;87(04):390–402

- 6 Caschera L, Lazzara A, Piergallini L, Ricci D, Tuscano B, Vanzulli A. Contrast agents in diagnostic imaging: present and future. *Pharmacol Res* 2016;110:65–75
- 7 Abbata S, Blanke P, Maroules CD, et al. SCCT guidelines for the performance and acquisition of coronary computed tomographic angiography: a report of the society of Cardiovascular Computed Tomography Guidelines Committee: endorsed by the North American Society for Cardiovascular Imaging (NASCI). *J Cardiovasc Comput Tomogr* 2016;10(06):435–449
- 8 Xiao Y, Zeng G, Liu X, Peng C, Lai C, Zhou P. Safety enhancement in adult body computed tomography scanning: comparison of iodixanol versus iohexol. *Springerplus* 2016;5(01):148
- 9 Sundgren PC, Bååth L, Törnquist C, Hougens Grynne B, Kjaersgaard P, Almén T. Image quality and safety after iodixanol in intravenous urography; a comparison with iohexol. *Br J Radiol* 1996;69(824):699–703
- 10 Hubbard L, Malkasian S, Zhao Y, Abbata P, Molloy S. Contrast media timing optimization for coronary CT angiography: a retrospective validation study in swine. *Eur Radiol* 2023;33(03):1620–1628
- 11 Faggioni L, Gabelloni M. Iodine concentration and optimization in computed tomography angiography: current issues. *Invest Radiol* 2016;51(12):816–822
- 12 Oda S, Utsunomiya D, Nakaura T, et al. Basic concepts of contrast injection protocols for coronary computed tomography angiography. *Curr Cardiol Rev* 2019;15(01):24–29
- 13 Heiken JP, Brink JA, McClennan BL, Sagel SS, Crowe TM, Gaines MV. Dynamic incremental CT: effect of volume and concentration of contrast material and patient weight on hepatic enhancement. *Radiology* 1995;195(02):353–357
- 14 Ho LM, Nelson RC, DeLong DM. Determining contrast medium dose and rate on basis of lean body weight: does this strategy improve patient-to-patient uniformity of hepatic enhancement during multi-detector row CT? *Radiology* 2007;243(02):431–437
- 15 Kondo H, Kanematsu M, Goshima S, et al. Abdominal multi-detector CT in patients with varying body fat percentages: estimation of optimal contrast material dose. *Radiology* 2008;249(03):872–877
- 16 Bae KT, Seeck BA, Hildebolt CF, et al. Contrast enhancement in cardiovascular MDCT: effect of body weight, height, body surface area, body mass index, and obesity. *AJR Am J Roentgenol* 2008;190(03):777–784
- 17 Yanaga Y, Awai K, Nakaura T, et al. Effect of contrast injection protocols with dose adjusted to the estimated lean patient body weight on aortic enhancement at CT angiography. *AJR Am J Roentgenol* 2009;192(04):1071–1078
- 18 Mosteller RD. Simplified calculation of body-surface area. *N Engl J Med* 1987;317(17):1098
- 19 Bae KT, Heiken JP, Brink JA. Aortic and hepatic contrast medium enhancement at CT. Part II. Effect of reduced cardiac output in a porcine model. *Radiology* 1998;207(03):657–662
- 20 Husmann L, Alkadhi H, Boehm T, et al. Influence of cardiac hemodynamic parameters on coronary artery opacification with 64-slice computed tomography. *Eur Radiol* 2006;16(05):1111–1116
- 21 Bae KT. Intravenous contrast medium administration and scan timing at CT: considerations and approaches. *Radiology* 2010;256(01):32–61
- 22 Weininger M, Barraza JM, Kemper CA, Kalafut JF, Costello P, Schoepf UJ. Cardiothoracic CT angiography: current contrast medium delivery strategies. *AJR Am J Roentgenol* 2011;196(03):W260–72
- 23 Fleischmann D, Kamaya A. Optimal vascular and parenchymal contrast enhancement: the current state of the art. *Radiol Clin North Am* 2009;47(01):13–26
- 24 Birnbaum BA, Jacobs JE, Langlotz CP, Ramchandani P. Assessment of a bolus-tracking technique in helical renal CT to optimize nephrographic phase imaging. *Radiology* 1999;211(01):87–94
- 25 Huda W, Scalzetti EM, Levin G. Technique factors and image quality as functions of patient weight at abdominal CT. *Radiology* 2000;217(02):430–435
- 26 Marchal G, Vogl TJ, Heiken JP, Rubin GD. Multidetector-row computed tomography: scanning and contrast protocols. Springer: Milan, Italy; 2005:1–33
- 27 McCollough CH, Bruesewitz MR, Vrtiska TJ, et al. Image quality and dose comparison among screen-film, computed, and CT scanned projection radiography: applications to CT urography. *Radiology* 2001;221(02):395–403
- 28 Awai K, Hiraishi K, Hori S. Effect of contrast material injection duration and rate on aortic peak time and peak enhancement at dynamic CT involving injection protocol with dose tailored to patient weight. *Radiology* 2004;230(01):142–150
- 29 Bae KT. Peak contrast enhancement in CT and MR angiography: when does it occur and why? Pharmacokinetic study in a porcine model. *Radiology* 2003;227(03):809–816
- 30 Auler MA, Heagy T, Aganovic L, Brothers R, Costello P, Schoepf UJ. Saline chasing technique with dual-syringe injector systems for multi-detector row computed tomographic angiography: rationale, indications, and protocols. *Curr Probl Diagn Radiol* 2006;35(01):1–11
- 31 Cademartiri F, Mollet N, van der Lugt A, et al. Non-invasive 16-row multislice CT coronary angiography: usefulness of saline chaser. *Eur Radiol* 2004;14(02):178–183
- 32 Yamaguchi I, Kidoya E, Suzuki M, Kimura H. Evaluation of required saline volume in dynamic contrast-enhanced computed tomography using saline flush technique. *Comput Med Imaging Graph* 2009;33(01):23–28