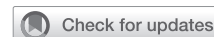

Simple completion Bentall procedure of preserving aortic bioprosthesis after aortic valve replacement



Soichiro Henmi, MD,^{a,b} Raffaele Scaffa, MD,^a Giulio Folino, MD,^{a,c} and Ruggero De Paulis, MD,^a Rome and Padua, Italy, and Kobe, Japan

From the ^aDepartment of Cardiac Surgery, European Hospital, Rome, Italy; ^bDivision of Cardiovascular Surgery, Japanese Red Cross Kobe Hospital and Hyogo Emergency Medical Center, Kobe, Japan; and ^cDivision of Cardiac Surgery, Department of Cardiac, Thoracic and Vascular Sciences, University of Padua, Padua, Italy.

Disclosures: Ruggero De Paulis is the inventor of the Valsalva Graft and has received royalties from Vascutek Terumo in the past. All other authors reported no conflicts of interest.

The *Journal* policy requires editors and reviewers to disclose conflicts of interest and to decline handling or reviewing manuscripts for which they may have a conflict of interest. The editors and reviewers of this article have no conflicts of interest.

Received for publication Jan 22, 2022; revisions received April 4, 2022; accepted for publication April 18, 2022; available ahead of print April 27, 2022.

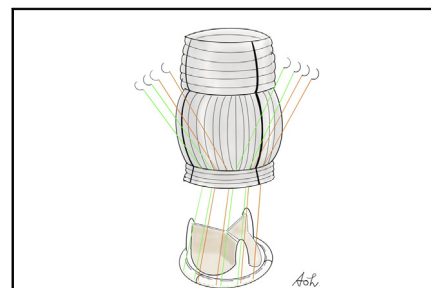
Address for reprints: Soichiro Henmi, MD, Cardiac Surgery Department, European Hospital, Via Portuense 700, Rome, Italy, 00149 (E-mail: awaswimcvsoh@hotmail.co.jp).

JTCVS Techniques 2022;14:66-8

2666-2507

Copyright © 2022 The Author(s). Published by Elsevier Inc. on behalf of The American Association for Thoracic Surgery. This is an open access article under the CC BY-NC-ND license (<http://creativecommons.org/licenses/by-nc-nd/4.0/>).

<https://doi.org/10.1016/j.jtc.2022.04.020>



Simple and feasible completion Bentall procedure preserving aortic bioprosthesis.

CENTRAL MESSAGE

Bioprosthesis-preserving aortic root replacement is an extremely rare situation. The size of the Valsalva graft should be decided after measuring the “true” external sewing ring diameter.

▶ Video clip is available online.

The “completion Bentall” is a redo procedure that consists in replacing the aortic root with reimplantation of coronary ostia in the case of a previously implanted normally functioning aortic prosthesis.¹ Bioprosthesis-preserving completion Bentall operation in particular is an extremely rare situation.²⁻⁵ We describe a simple and feasible technique of completion Bentall procedure preserving aortic bioprosthesis after aortic valve replacement.

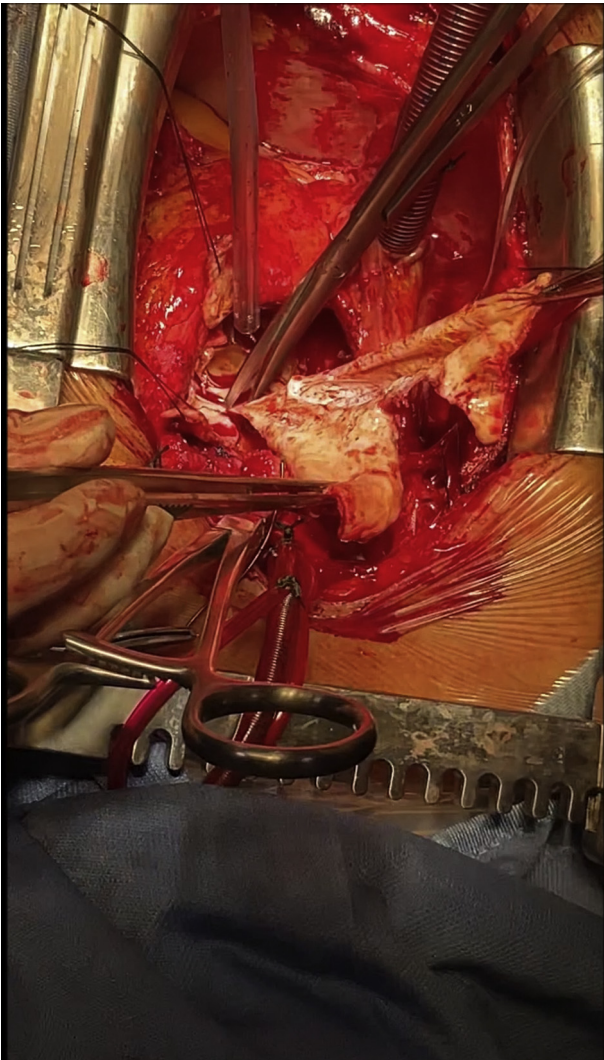
CLINICAL SCENARIO

In this specific situation, after 4 years from an implantation of a 21-mm Carpentier-Edwards Magna pericardial prosthesis (Edwards Lifesciences), we were faced with a 60-mm aortic root aneurysm due to chronic aortic dissection. At the time of initial surgery, the aortic root and the ascending aorta were macroscopically unremarkable. There were no signs of paravalvular leakage or structural valve deterioration in the preoperative transesophageal echocardiogram.

SURGICAL TECHNIQUE

Completion Bentall procedure preserving the previously implanted aortic bioprosthesis was performed as shown in

Video 1. The aortic arch and the right atrium were cannulated to initiate cardiopulmonary bypass. Following the clamping of the aorta, myocardial protection was achieved by blood cardioplegia in the aortic root. After cardiac arrest, the aneurysmal aortic wall was completely removed. A limited entry tear was found just above the orifice of the left coronary artery. Visual aspect revealed an intact bioprosthesis without leaflet calcifications, tears, infection, or thrombus (Figure 1, A). Each coronary ostium was detached. The external sewing ring diameter of the implanted 21-mm Carpentier-Edwards Magna pericardial prosthesis was exactly 28 mm measured with the unlabeled cylindrical sizer (Figure 1, B). Eleven interrupted single sutures of 2-0 CV-25 braided polyester (Covidien) were placed on the outer edge of the bioprosthesis sewing ring (Figures 1, A, and 2). The aortic root was replaced using a 28-mm Valsalva graft (Terumo Aortic, Vascutek Ltd). The collar at the bottom of the graft was trimmed to a length of 4 mm (approximately 4 crimps) and connected to the prosthesis sewing ring. Each coronary ostia were reattached to the graft by using the button technique. After distal graft anastomosis, the aortic clamping was removed. There was no



VIDEO 1. Simple completion Bentall procedure of preserving aortic bioprosthesis after aortic valve replacement. Video available at: [https://www.jtcvs.org/article/S2666-2507\(22\)00255-3/fulltext](https://www.jtcvs.org/article/S2666-2507(22)00255-3/fulltext).

bleeding at the proximal anastomosis. Aortic crossclamp time was 78 minutes and cardiopulmonary bypass time was 86 minutes. Blood transfusion was not necessary. The postoperative course was uneventful without complications.

DISCUSSION

Whether to remove or preserve the bioprosthesis is still matter of controversy. Removal and reimplantation of the new bioprosthesis might offer extended durability; however, it also necessitates prolonged operative time and reimplantation into a damaged aortic annulus, which can cause further complications such as bleeding. Urbanski and colleagues² reported that removing a previously implanted aortic prosthesis led to considerable damage of annular tissue with an increase of mortality up to 12%. In addition, in the present case the bioprosthesis was implanted only 4 years ago and was considered in very good condition. Therefore, it was preserved.

In this procedure, although it is theoretically possible to suture the graft to a rim of aortic tissue above the annulus, this approach will expose the patient to additional risk, like tissue tearing with bleeding or pseudoaneurysm formation or flow stagnation between the sewing ring and the Valsalva graft. By securing the graft to the prosthesis’s sewing ring, we reproduce the standard situation of a Bentall procedure, minimizing complications.

We believe that optimized size selection for the Dacron graft plays a key role in this approach. A wrong graft size may lead to complications such as uncontrollable bleeding and future occurrence of pseudoaneurysm. Generally, in the primary Bentall procedure, biological conduits are customized by selecting a Valsalva graft 3-5 mm larger than the aortic prosthesis size. In the described case, the “true” external sewing ring diameter of the 21-mm bioprosthesis, measured using an unlabeled cylindrical sizer, was 28 mm

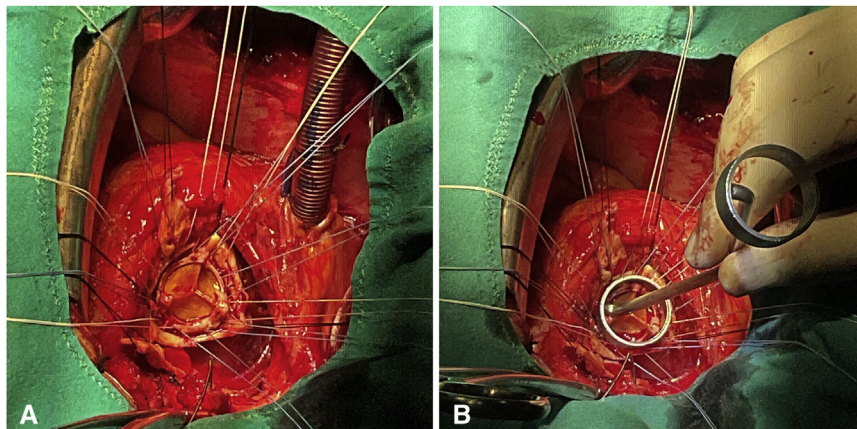


FIGURE 1. Intraoperative picture. A, Eleven interrupted single sutures were placed on the lateral area in the sewing ring. B, Measuring the “true” external sewing ring diameter by the 28-mm sizer.

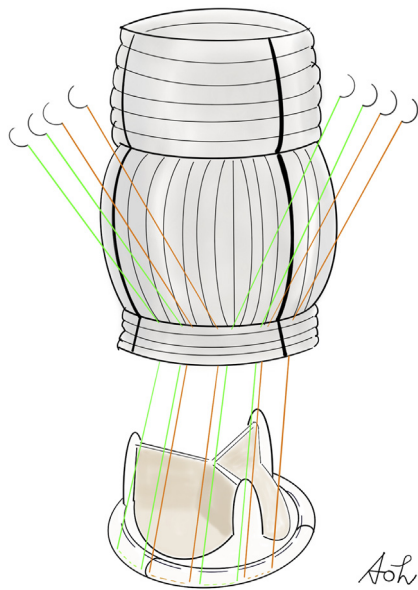


FIGURE 2. The operative techniques in the simple completion Bentall procedure of preserving bioprosthesis.

(2 mm larger than the reported size). This can be speculated to be due to the enlargement of the prosthesis sewing ring by the compressing sutures of the initial

operation. Thus, a direct and precise intraoperative measurement is strongly advised. By virtue of a careful sizing, the collar of the Valsalva graft covers comfortably the entire valve sewing ring ensuring excellent hemostatic property. The size of the Valsalva graft should be decided after measuring the “true” external sewing ring diameter of the prosthesis.

We have obtained written informed consent from this patient for reporting. The institutional review board deemed the study exempt because the same technique was already used in the presence of mechanical valve.

References

1. Malekan R, Spielvogel D, Saunders PC, Lansman SL, Griep RB. The completion Bentall procedure. *Ann Thorac Surg.* 2011;92:362-3.
2. Urbanski PP, Lakew F, Dinstak W, Heinz N, Zacher M, Irimie V, et al. Bentall procedure after previous aortic valve or complete root replacement: usefulness of self-assembled aortic valve conduit. *J Thorac Cardiovasc Surg.* 2018;156:89-95.
3. Luciani N, Anselmi A, de Geest R, Glieca F, Possati G. Facilitated aortic root substitution after aortic valve replacement: technique and results of the prosthesis-sparing operation. *J Thorac Cardiovasc Surg.* 2010;139:785-7.
4. Pacini D, Villa E, Martin-Suarez S, Bartolomeo RD. Aortic root substitution after aortic valve replacement: a prosthesis-sparing operation. *Eur J Cardiothorac Surg.* 2005;27:717-9.
5. Scaffa R, Salica A, Weltert L, Irace FG, Guerrieri Wolf L, D'Aleo S, et al. Optimized use of the "skirt" of the Valsalva graft for the completion Bentall procedure. *Ann Thorac Surg.* 2021;112:e303-5.