

## Case Report

# A Successful Case for Deselection of Albino Embryo and Live Birth of Albinism-Free Healthy Baby Followed by PGT-M

Nayana Patel, Harsha K. Bhadarka, Salil Vaniawala<sup>1</sup>, Arpita Patel

Department of IVF,  
Akanksha Hospital and  
Research Institute, Anand,  
<sup>1</sup>Department of Genetic,  
S N Gene Lab, Surat,  
Gujarat, India

### ABSTRACT

In recent years, Preimplantation genetic testing for monogenic disorders (PGT-M) has gained a lot of focus in the field of assisted reproduction technology, various studies have been published in support of it and many are opposing its role. It has been criticized due to many ethical as well as scientific reasons, but there is no doubt that PGT-M has been one of the most important breakthroughs in *in vitro* fertilization. A critical aspect of this technology is the possibility that the biopsy itself can adversely affect the quality of embryo and compulsion of embryo freezing. Oculocutaneous albinism (OCA) is a condition which is related to skin, hair, eye color (pigments), where affected individuals typically have very fair skin and white- or light-colored hair. These patients are prone to skin cancers on prolonged sun exposure. It also reduces the pigmentation of the colored part of the eyes (the iris) and the light-sensitive tissue at the back of the eye (the retina). People with this condition usually have problem in vision such as reduced sharpness, involuntary eye movements, and photophobia. Here, we report the successful use of PGT-M and a novel protocol for the preimplantation genetic diagnosis of OCA following trophoctoderm cell biopsy from blastocysts and the birth of a healthy infant to a couple having previously affected child.

**KEYWORDS:** Albinism, intracytoplasmic sperm injection, PGT-M, preimplantation genetic diagnosis, mutation

## INTRODUCTION

First PGT-M was done successfully for sex selection on day 5 rabbit embryos by Gardner and Edwards in 1968.<sup>[1]</sup> Earlier, PGT-M was used to determine the gender as an indirect means to avoid an X-linked disorder. In 1989 in London, the first unaffected child born was reported by performing PGT-M for an X-linked disorder by Handyside *et al.* Preimplantation genetic testing, a highly specialized field which incorporated the latest techniques of ART and genetics, is an early form of prenatal diagnosis bringing hope of healthy babies to patients, who are at risk of transmitting genetic abnormalities to their next generation. Trophoctoderm biopsies have been performed from the fertilized embryos at the blastocyst stage, and they are further investigated for the specific monogenic disease. This

would lead to healthy embryos to be selected for transfer. This approach would reduce the chances of abnormalities to be passed on to the next generation. With betterment of prenatal diagnostic techniques such as amniocentesis and chorionic villi sampling (CVS) and noninvasive prenatal testing, it has been possible for couples at risk of genetic diseases to give birth to healthy babies, but these techniques are available for the diagnosis in the postconception period and are all invasive procedures.

In these diagnostic procedures, termination of pregnancy will be the ultimate option if the test turns out to be abnormal. PGT-M is essentially an alternative to

**Address for correspondence:** Dr. Harsha K. Bhadarka,  
Department of IVF, Akanksha Hospital and Research Institute,  
Anand, Gujarat, India.  
E-mail: harshabhadarka@yahoo.co.in

Received: 27-05-2019  
Accepted: 20-04-2020

Revised: 01-11-2019  
Published: 27-10-2020

### Access this article online

#### Quick Response Code:



**Website:**  
www.jhrsonline.org

**DOI:**  
10.4103/jhrs.JHRS\_38\_19

This is an open access journal, and articles are distributed under the terms of the Creative Commons Attribution-NonCommercial-ShareAlike 4.0 License, which allows others to remix, tweak, and build upon the work non-commercially, as long as appropriate credit is given and the new creations are licensed under the identical terms.

**For reprints contact:** WKHLRPMedknow\_reprints@wolterskluwer.com

**How to cite this article:** Patel N, Bhadarka HK, Vaniawala S, Patel A. A successful case for deselection of albino embryo and live birth of albinism-free healthy baby followed by PGT-M. J Hum Reprod Sci 2020;13:245-8.

prenatal diagnosis, which helps in negative selection of pretentious embryo before implantation, i.e., before the implantation of embryo and thus eliminates the stress and psychological trauma associated with the termination of pregnancy.

In this case report, we describe a novel protocol for the preimplantation genetic diagnosis of oculocutaneous albinism (OCA). OCA is a group of autosomal-recessive conditions, characterized by the mutations in melanin biosynthesis with resultant absence or reduction of melanin in the melanocytes. Melanin-poor, pigment-poor melanocytes phenotypically present as hypopigmentation of the hair, skin, and eyes.<sup>[2,3]</sup>

There are primarily four genes responsible for the four principal types of OCA. OCA type 1A (OCA1A) and OCA type 1B (OCA1B) are caused by a mutation in the tyrosinase gene (TYR) on chromosome 11q14.3. OCA type 2 is caused by a mutation in the OCA2 gene.<sup>[3,4]</sup> OCA type 3 is caused by a mutation in the tyrosinase-related protein 1 gene, and OCA type 4 is caused by a mutation in SCL45A2 (a.k.a. MATP).<sup>[3,4]</sup>

OCA1A is considered the most severe type of OCA due to a complete absence of melanin production. OCA1B, OCA2, OCA3, and OCA4 are considered less severe, as they often show small amounts of pigment accumulation over time.<sup>[5]</sup>

Overall, there is a significant clinical overlap between the variants of OCA. Thus, molecular diagnosis is often necessary to establish the specific OCA subtype.

The clinical characteristics found in individuals afflicted with OCA type 1 include hypopigmentation of the skin and hair and the distinctive ocular changes characteristic of all forms of albinism.<sup>[4]</sup> Decreased melanin production does not alter the development of skin, but it does alter the color. The absence of melanin in the eye, on the other hand, leads to anomalous development and function.<sup>[3]</sup> The ocular changes associated with OCA include severe nystagmus, prominent photophobia, reduced pigmentation of the retinal epithelium, and reduced visual acuity.<sup>[5]</sup> A pathognomonic finding of albinism is misrouting of the optic nerve at the optic chiasm, resulting in strabismus and reduced stereoscopic vision.<sup>[3,5]</sup>

Mutations in the TYR gene may entirely abolish TYR activity, resulting in OCA1A, or decrease the activity of the TYR enzyme, resulting in the development of OCA1B. Clinically, the difference between OCA1A and OCA1B is seen overtime, as OCA1B individuals often accumulate minor quantities of melanin and begin to display small amounts of pigmentation.

Ultimately, OCA needs to be considered for clinical diagnosis. The diagnosis is made if the individual has hypopigmentation of the skin or hair in conjunction with the aforementioned characteristic ocular signs. Molecular genetic testing is often used in combination with the clinical diagnosis to establish the specific genetic mutation and thus the OCA subtype.<sup>[3]</sup> Approximately one out of every 17,000 people has one of the four types of albinism. In the present study, a rare case of a sibling diagnosed with OCA type 1, emphasizes the importance of PGT-M and how the next baby was albinism free.<sup>[3,6]</sup>

## CASE REPORT

This is the case of a 35 year old female and a 36-year-old male, married for 9 years, were seeking consultation, they had a 4-year-old child suffering from albinism type-OCA 1. As per previous reports, affected child inherited this disorder due to mutation in OCA1 gene from parents, there was a strong possibility of obligate asymptomatic carrier in the family. Hence, decision was made by the clinic to check for mutation in OCA1 gene responsible for albinism and also do preimplantation diagnosis of embryos for the detection of the same mutation. Couple was counseled about the genetic risk, success rates, the risk of misdiagnosis, and the importance of prenatal diagnosis during pregnancy. Thorough deliberation and multiple counseling sessions are done between ART clinician, embryologist, and molecular laboratory person with patient's family. Informed consent taken for PGT-M testing.

### *In-vitro* fertilization cycle details

#### Materials and methods

Blood samples in ethylenediaminetetraacetic acid were taken from intended parents. DNA extraction from blood was carried out following the protocol described; DNA was extracted from blood samples using a QIAamp DNA Blood Mini Kit (Germany) and from biopsied samples using an REPLiG Mini Kit from Qiagen, Germany. Whole Genome Amplification (WGA) was performed using a PicoPLEX™ WGA Kit from New England Biolabs (UK). Sample amplification efficiency was analyzed using a real-time quantitative polymerase chain reaction (PCR) instrument by adding SYBR Green I Dye at × 0.125 final concentration in the amplification cocktail. OCA1 (TYR) gene mutation analysis was performed by PCR followed by automated DNA sequencing of the amplicon using Big Dye™ Terminator Chemistry on an ABI Genetic Analyzer 3500DX platform to generate nucleotide sequence flanking the c.530T >A (p.V177D) region. The raw data obtained are subsequently analyzed for the presence or absence of mutation at the hotspot region.

Gene-specific oligonucleotide primers (TYRF: 5' ATGGCCAAATGAAAAATGGA 3' and TYRR: 5' CATCTCCTGTCAGCTTCTGG 3') were designed to amplify a 219 bp PCR amplicon-harboring position c.530T >A of the TYR gene. The thermal cycling conditions were as follows: hold of 94°C for 2 min followed by 35 cycles, each comprising of 94°C for 30 s and 62°C for 1 min. This was followed by a hold of 72°C 30 s. Amplified products were purified using a QIA quick PCR Purification Kit (Qiagen, Germany), sequenced using a BigDye Terminator v3.1 Cycle Sequencing Kit and resolved on a 3130xl Genetic Analyzer (Thermo Fisher Scientific, USA).

Parents were found to be asymptomatic carrier and found to be heterozygous for the mutation of OCA1 gene.

Individual controlled ovarian stimulation was performed followed by egg retrieval. Intracytoplasmic sperm injection (ICSI) was performed on all mature oocytes to avoid sperm DNA contamination during PGT-M genetic testing. Trophectoderm biopsy from all embryos was taken on day 5. Approximate 7–10 cells were precisely taken during biopsy by skilled and experienced embryologist and were then transported for PGT-M analysis to the genetic laboratory. After biopsy, embryos were vitrified with kitazato vitrification method as per kit's protocol and stored in liquid nitrogen at –196°C.

Three round of stimulation and three functional electrical therapy were required to achieve positive outcome [Table 1]. Endometrial preparation on all 3 occasion was by HRT protocol (estradiol valerate 6 mg daily followed by injection progesterone). Embryos were thawed 2 h prior of transfer procedure as per kitazato kits warming protocol. Embryo transfer was done with soft embryo transfer catheter (Cook.Australia) under sonography guidance.

Positive pregnancy was confirmed in the last cycle [Figure 1]; CVS was performed at 11 weeks of pregnancy to confirm the absence of mutation and for confirmation of PGT-M report. After uneventful antenatal period, normal baby girl was delivered at the full term of 3.2 kg by LSCS.

## DISCUSSION

To date, 12 genetic mutations have been identified in the development of albinism. OCA type 1 is caused by a mutation in the TYR gene on chromosome 11q14.3.<sup>[7]</sup> The TYR gene consists of 529 amino acids and five exons that span 65 kb of genomic DNA. The gene encodes TYR, an enzyme that catalyzes the first two steps in the melanin biosynthesis pathway. TYR converts tyrosine

to L-dihydroxyphenylalanine and then to dopaquinone. The TYR gene mutation causes a complete or partial loss of the catalytic activity of TYR.<sup>[8]</sup> The current case emphasizes on a rare molecular gene mutation of OCA type 1, and how manifestation can be eliminated from the family with the help of PGT-M analysis.

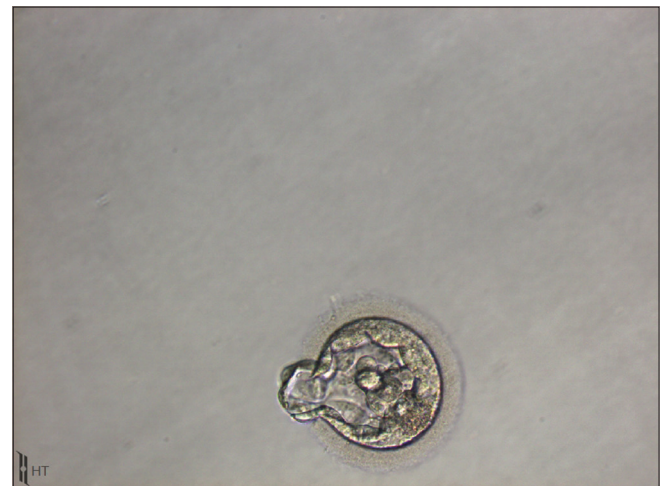
To the best of our knowledge, this is the first report of its kind in our country, in which the preimplantation diagnosis of embryos was done to check mutation in OCA1 gene.

Nowadays, PGT-M is a well-established reproductive option for couples at risk of transmitting genetic disorders to the offspring. In context to genetically transmitting disorders, in which one parent is carrier for abnormal gene, at conception each offspring has a 25% probability of being a carrier and 50% probability of being unaffected. For this reason, the PGT-M associated with *in vitro* fertilization/ICSI in a risk situation seems to be the only way to avoid recurrence.

PGT-M is an extremely valuable tool for the prevention of many deadly monogenic disorders. If used

**Table 1: IVF cycle details**

|                              | First cycle | Second cycle | Third cycle |
|------------------------------|-------------|--------------|-------------|
| Oocytes retrieved            | 6           | 11           | 14          |
| Oocyte fertilized            | 1           | 4            | 8           |
| Blastocyst                   | 1           | 4            | 5           |
| Embryo biopsied              | 1           | 4            | 5           |
| Heterozygous embryo          | 1           | 2            | 3           |
| Homozygous embryo            | -           | 2            | 2           |
| Number of embryo transferred | 1           | 2            | 1           |
| Serum B-HCG                  | Negative    | Negative     | Positive    |



**Figure 1: Blastocyst embryo transferred**

meticulously with proper expertise, it is a big boon in ART techniques.

The only drawbacks being PGT-M is a procedure that require a team work comprising of ART clinician, embryologist team, molecular team, and geneticists. It require in depth and thorough counseling of the couple.<sup>[9]</sup> Other major hurdle in its widespread use is the high-cost factor involved. This technique along with its exhaustive preprocedure, procedure, and technical work demands also falls back in its application more frequently due to the dearth of public awareness.

## CONCLUSION

The PGT-M with assisted reproductive technology is an efficient method for the detection of OCA1 gene mutation. Our positive experience may encourage other clinicians for the use of this technique for indicated cases.

In addition to this, our findings may raise the awareness for the use of this technique and stimulate the development of PGT-M protocols for several other genetic disorders. Obviously, during any PGT-M procedure, role of counseling of the patient is very important, so it should be done thoroughly. All informed consent should be taken before the procedure. Double confirmation of resulted pregnancy with CVS should be strictly followed as mandatory protocol by the clinic.

## Financial support and sponsorship

Nil.

## Conflicts of interest

There are no conflicts of interest.

## REFERENCES

1. Gardner RL, Edwards RG. Control of the sex ratio at full term in the rabbit by transferring sexed blastocysts. *Nature* 1968;218:346-9.
2. Oetting WS, Brilliant MH, King RA. The clinical spectrum of albinism in humans. *Mol Med Today* 1996;2:330-5.
3. Gronskov K, Ek J, Brondum-Nielsen K. Oculocutaneous albinism. *Orphanet J Rare Dis* 2007;2:43.
4. Kamaraj B, Purohit R. Mutational analysis of oculocutaneous albinism: A compact review. *Biomed Res Int* 2014;2014:905472.
5. Lewis R. Oculocutaneous Albinism Type 1. *Gene Reviews*; 2000. Available from: <http://www.ncbi.nlm.nih.gov/books/NBK1166/>. [Last updated on 2013 May 16; Last accessed on 2016 Aug 15].
6. Witkop CJ. Albinism: Hematologic-storage disease, susceptibility to skin cancer, and optic neuronal defects shared in all types of oculocutaneous and ocular albinism. *Ala J Med Sci* 1979;16:327-30.
7. Tomita Y, Takeda A, Okinaga S, Tagami H, Shibahara S. Human oculocutaneous albinism caused by single base insertion in the tyrosinase gene. *Biochem Biophys Res Commun* 1989;164:990-6.
8. Karaman A. Oculocutaneous albinism type 1A: A case report. *Dermatol Online J* 2008;14:13.
9. Patel NH, Bhadarka HK, Patel KB, Vaniawala SN, Acharya A, Mukhopadhyaya PN, *et al.* Embryo genome profiling by single-cell sequencing for successful preimplantation genetic diagnosis in a family harboring COL4A1 c. 1537GA; p.G513S mutation. *J Hum Reprod Sci* 2016;9:200-6.