

Structural modifications of the prostate in hypoxia, oxidative stress, and chronic ischemia

Portia Thurmond, Jing-Hua Yang, Yedan Li, Lori B. Lerner, Kazem M. Azadzi¹

Department of Urology, VA Boston Healthcare System and Boston University School of Medicine, Boston, ¹Department of Urology and Department of Pathology, VA Boston Healthcare System and Boston University School of Medicine, Boston, MA, USA

Purpose: Clinical studies have reported a correlation between pelvic ischemia and voiding dysfunction in elderly men. The aim of this study was to identify and compare prostate structural modifications in cultured cells and in a rabbit model after exposure to hypoxia, oxidative stress, and chronic ischemia.

Materials and Methods: Cultured human prostate smooth muscle cells (SMCs), epithelial cells (ECs), and stromal cells (SCs) were incubated under normoxia, hypoxia, and oxidative stress conditions by use of a computerized oxycycler system. We developed a rabbit model of chronic prostate ischemia by creating aorto-iliac arterial atherosclerosis. Markers of oxidative stress were examined by using fluorometric analysis and enzyme immunoassay. Prostate structure was examined by using Masson's trichrome staining and transmission electron microscopy (TEM).

Results: Lipid peroxidation was found in SMCs exposed to hypoxia and in all cell types exposed to oxidative stress. We identified protein oxidation in ECs exposed to hypoxia and in all cell types exposed to oxidative stress. Markers indicating oxidative damage were present in chronically ischemic rabbit prostate tissue. These reactions were associated with DNA damage. Prostate ischemia resulted in epithelial atrophy, loss of smooth muscle, and diffuse fibrosis. TEM showed swollen mitochondria with degraded cristae, loss of membrane, loss of Golgi bodies, degenerated nerves, and disrupted cell-to-cell junctions.

Conclusions: Human prostate cells exhibited differential reactions to hypoxia and oxidative stress with widespread DNA damage. Structural modifications in ischemic prostate tissue were similar to those in cells exposed to oxidative stress. Structural changes due to ischemia and oxidative stress may contribute to prostatic noncompliance in aging men.

Keywords: Fibrosis; Ischemia; Oxidative stress; Prostate

This is an Open Access article distributed under the terms of the Creative Commons Attribution Non-Commercial License (<http://creativecommons.org/licenses/by-nc/3.0>) which permits unrestricted non-commercial use, distribution, and reproduction in any medium, provided the original work is properly cited.

INTRODUCTION

Lower urinary tract symptoms (LUTS) are common urological complaints whose prevalence increases with age [1,2]. In men, voiding and post-micturition symptoms have often been associated with benign prostatic enlargement (BPE). Although BPE is very common in men as they age and

can result in LUTS, it is not the sole mechanism leading to obstructive symptoms [3]. Several studies comparing prostate volume, standardized symptom scores, and urodynamic studies have demonstrated weak correlations between BPE, bladder outlet obstruction, and obstructive symptoms [4-6]. In addition, studies of healthy elderly male volunteers and elderly men living in the community have

Received: 16 January, 2015 • **Accepted:** 7 February, 2015

Corresponding Author: Kazem M. Azadzi

Department of Urology, VA Boston Healthcare System, 150 South Huntington Avenue, Building 1A, Room 315 (151), Boston, MA 02130, USA
TEL: +1-857-364-5602, FAX: +1-857-364-4540, E-mail: kazadzi@bu.edu

found that a proportion of men without voiding symptoms have evidence of obstruction on urodynamic testing [7,8]. The data suggest that although BPE can be present with LUTS, the anatomic changes resulting from BPE are not pathognomonic for LUTS.

It is well recognized that α -blockers and therapeutic strategies for achieving androgen suppression reduce LUTS in men with BPE, possibly by diminishing prostate smooth muscle tension and epithelial volume, respectively [9-11]. These observations suggest the presence of both dynamic and static mechanisms of bladder outlet obstruction, although the dynamic forces have yet to be completely described and the mechanism of increased tension in the aging prostate remains essentially unknown. These unrecognized factors in the mechanism of LUTS impose major clinical challenges. The mechanism of LUTS improvement by α -blockers remains controversial, and studies investigating outcomes for men with LUTS presumed to also have BPE reported treatment failure in a moderate proportion of patients [12,13].

Chronic ischemia due to arterial insufficiency has recently received increasing attention as a possible etiology for bladder dysfunction and resulting LUTS [14-16]. In the bladder, chronic ischemia leads to neurodegeneration, fibrosis, smooth muscle injury, and contractile dysfunction [17-19]. Ischemia as a mechanism of prostatic injury has not been thoroughly explored, although limited data suggest that ischemia may contribute to changes in prostatic contractility [20-23]. In the present study, we conducted a series of experiments using cultured human prostatic cells and an animal model to illustrate the effects of hypoxia, oxidative stress, and chronic ischemia on prostatic tissue structure.

MATERIALS AND METHODS

1. Cell culture

Primary human prostatic smooth muscle cells (SMCs), epithelial cells (ECs), and stromal cells (SCs) were obtained from Lonza (Allendale, NJ, USA). Cells were cultured in growth media followed by passaging and subculturing as per routine. Once the cells reached confluence, they were trypsinized and washed. Trypan blue staining and transmission electron microscopy (TEM) were used to confirm cell viability. Viable cells were counted and processed for analysis.

2. Cell culture model of hypoxia and oxidative stress

A computerized servo-control cell oxycycler system (BioSpherix, Lacona, NY, USA) was used to expose cultured SMCs, ECs, and SCs to normoxia, hypoxia, and hypoxia/reoxygenation (oxidative stress) conditions, as previously reported [21]. In brief, the computer was programmed to provide the desired oxygen profile and length of time of oxycycling in independent oxycycler cell culture chambers. We incubated confluent cells in normoxia (21% oxygen) and continuous hypoxia (2% oxygen) for 48 hours. To study oxidative stress, cells were incubated in hypoxia at 2% oxygen for 30 minutes followed by reoxygenation with 21% oxygen for 1-hour cycles in this manner for 48 hours.

3. Preparation of cultured cells for analysis

After 48 hours, cells were collected, lysed, and centrifuged. The pellet was discarded, the supernatant was collected, and protein concentrations were determined by use of a NanoDrop ND-1000 Spectrophotometer (Thermo Fisher Scientific, Cambridge, MA, USA). Protein extracts diluted with phosphate-buffered saline to a constant protein concentration per milliliter in each sample were processed for analysis.

4. Prostate ischemia model

Animal care and experimental protocols were in accordance with the guidelines of our Institutional Animal Care and Use Committee. The animal model of chronic prostatic ischemia was developed as previously reported [20,22]. In brief, New Zealand white male rabbits (n=10, 3–3.5 kg) were anesthetized with continuous inhalation of 1%–2% isoflurane mixed with oxygen. Aorto-iliac arterial atherosclerosis and prostate ischemia were produced by use of a balloon de-endothelialization technique. Arterial ballooning was repeated 3 to 4 times on each side while rotating the catheter. The animals received a 0.5% cholesterol diet for 4 weeks and then a regular rabbit diet. After 8 weeks, changes in the treated animals (n=10) were compared with sham controls (n=10) that underwent a similar operation without balloon de-endothelialization.

5. Prostate blood flow measurement

Prostatic ischemia was determined by a laser Doppler probe placed into the prostatic tissue and connected to a laser Doppler flowmeter (Transonic Systems Inc., Ithaca, NY, USA). Five measurements were obtained at random prostatic sites in each animal and the average blood flow for each animal was calculated.

6. Assessment of oxidative damage to proteins and lipids

Advanced oxidation protein product (AOPP) levels were analyzed by use of an OxiSelect AOPP kit (STA-318, Cell Biolabs, San Diego, CA, USA). Samples containing 250- μ g/mL protein were prepared. Constant volumes of 200 μ L were added to the wells of a microtiter plate (Cell Biolabs) and then exposed to chloramine reaction initiator followed by stop solution. Absorbance was recorded by use of a spectrophotometric plate reader by using 340 nm as the primary wavelength. Malondialdehyde (MDA) levels were measured by use of an OxiSelect MDA Adduct ELISA Kit (STA-332, Cell Biolabs). Samples containing 10- μ g/mL protein were prepared. Constant volumes of 100 μ L were added to the 96-well protein binding plate, incubated with anti-MDA antibody, washed, and then incubated with secondary antibody-horseradish peroxidase conjugate. Absorbance was read on a microplate reader at 450 nm as the primary wavelength and was standardized in micromoles as an absorbance equivalent.

7. DNA damage assay

Cells were processed for DNA extraction by using Pure-Link Genomic DNA kits (K1820-01, Invitrogen, Carlsbad, CA, USA). DNA damage was analyzed with an OxiSelect Oxidative DNA Damage ELISA kit (STA-320, Cell Biolabs). DNA samples were added to separate wells of the 8-hydroxy-2'-deoxyguanosine (8-OHdG) conjugate-coated plate and incubated at room temperature. Anti-8-OHdG antibody was added, the plates were incubated for 1 hour and then washed, and then 100 μ L of the diluted secondary antibody-enzyme conjugate was added. The plate was washed and incubated with the substrate color development reagents. Absorbance was read on a microplate reader by use of 450 nm as the primary wavelength.

8. Histologic examination

Cross-sections of prostatic tissues from ischemic and sham groups were fixed in 10% neutral buffered formalin and then embedded in paraffin. Sections measuring 5 μ m were mounted onto glass slides and processed for staining according to the standard Masson's trichrome protocol.

9. Transmission electron microscopy

Cultured cells and rabbit prostate tissues were fixed according to standard protocols. The following day, samples were embedded and polymerized. Ultrathin sections were placed on copper grids stained with lead citrate and analyzed by using a JEOL 1200EX microscope (JEOL USA Inc,

Peabody, MA, USA).

10. Statistical analysis

Data are expressed as mean \pm standard error of the mean. All measured parameters in treated cells and tissues were compared with controls. Significant differences were determined with analysis of variance followed by *post hoc* comparisons. Significance was determined at the $p < 0.05$ level.

RESULTS

1. Differential reactions of human prostate cells to hypoxia and oxidative stress

Protein oxidation, characterized by increased AOPP levels, was detected in ECs exposed to hypoxia and in SMCs, ECs, and SCs exposed to oxidative stress (Fig. 1). Lipid peroxidation, characterized by MDA upregulation, was found in SMCs exposed to hypoxia and in SMCs, ECs, and SCs exposed to oxidative stress (Fig. 1).

2. DNA damage in human prostate cells

Protein oxidation and lipid peroxidation in prostatic cells were associated with widespread DNA damage. SMCs, ECs, and SCs exposed to both hypoxia and oxidative stress demonstrated significantly increased 8-OHdG levels, suggesting DNA damage (Fig. 2).

3. Ultrastructural changes in human prostate SMCs

Hypoxia impaired cell membrane structure, caused a partial loss of the outer mitochondrial membrane, and led to swollen, enlarged endoplasmic reticulum (ER) and glycogen accumulation (Fig. 3). Oxidative stress produced similar changes in a more pronounced manner. SMCs exposed to oxidative stress exhibited deformed cell membranes, partial loss of mitochondrial membrane, degradation of mitochondrial cristae, enlarged splintered ER, and accumulation of cytoplasmic lysosomes (Fig. 3).

4. Markers of oxidative damage in chronic prostate ischemia

Prostate blood flow of 4.9 ± 0.4 (mL/min/100 g of tissue, mean \pm standard error) in animals with aorto-iliac atherosclerosis was significantly less than the 9.8 ± 0.6 recorded in the sham group ($p < 0.001$). Fluorometric analysis of chronically ischemic rabbit prostate tissue revealed protein oxidation, characterized by a significant increase in AOPP levels. Increased AOPP levels suggest oxidative

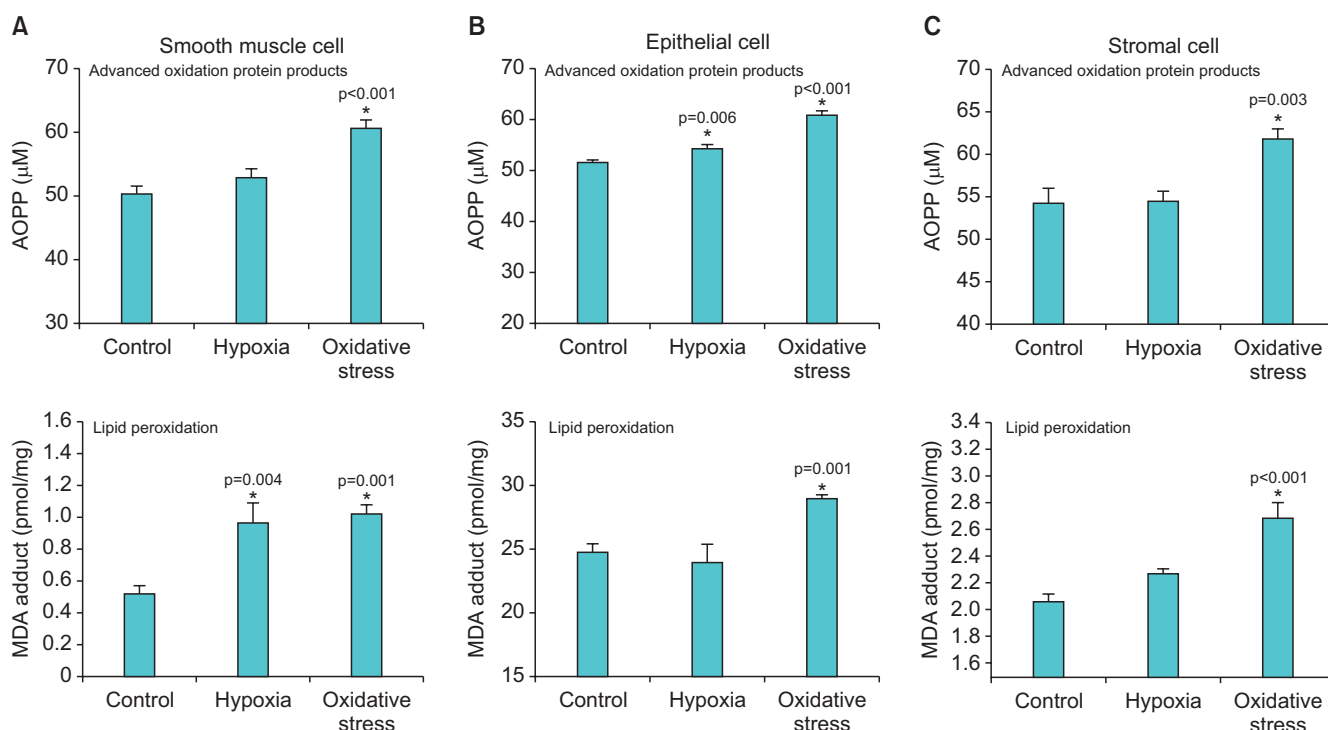


Fig. 1. Human prostate SMCs (A), ECs (B), and SCs (C) exhibited explicit reactions to hypoxia and oxidative stress. Lipid peroxidation was more prevalent in SMCs, whereas ECs appeared more susceptible to protein oxidation. Hypoxia caused lipid peroxidation in SMCs and protein oxidation in ECs. Oxidative stress led to protein oxidation and lipid peroxidation in SMCs, ECs, and SCs. Protein oxidation and lipid peroxidation suggest damage to protein- and lipid-containing structures of the cells, respectively. SMC, smooth muscle cell; EC, epithelial cell; SC, stromal cell; AOPP, advanced oxidation protein product; MDA, malondialdehyde. *Represent significance versus control.

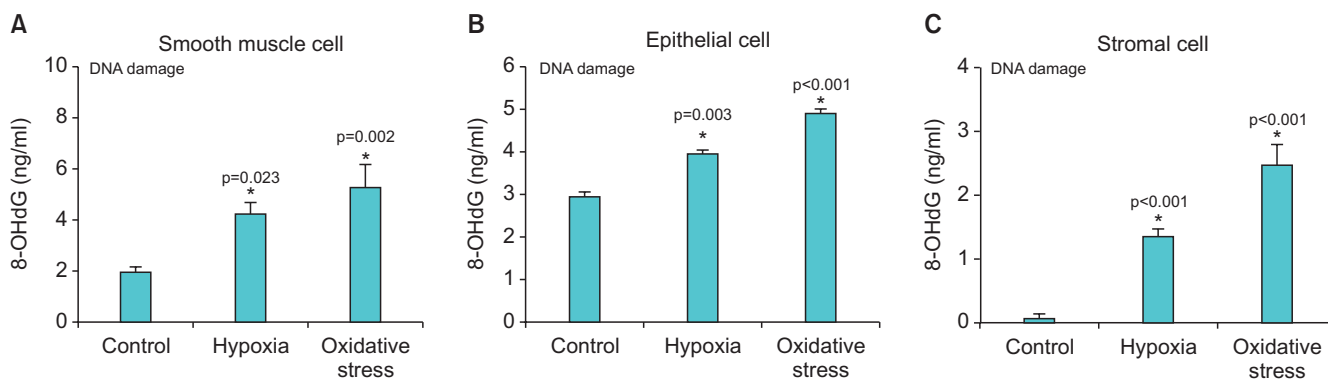


Fig. 2. Nonconforming oxygen tension led to widespread DNA damage in cultured human prostatic cells. Both hypoxia and oxidative stress induced DNA damage in SMCs (A), ECs (B), and SCs (C), characterized by a significant increase in 8-hydroxy-2'-deoxyguanosine levels. SMC, smooth muscle cell; EC, epithelial cell; SC, stromal cell. *Represent significance versus control.

damage to protein-containing structures (Fig. 4). Enzyme-linked immunosorbent assay of chronically ischemic rabbit prostate tissues showed lipid peroxidation, characterized by a significant increase in MDA levels versus sham, suggesting oxidative damage to lipid-containing structures in ischemia (Fig. 4).

5. Structural changes in chronic prostate ischemia

Masson's trichrome staining revealed marked thickening of the stroma, decreased smooth muscle fibers, diffuse

fibrosis, deformed flattened epithelium lining, and large intraluminal spaces in the ischemic prostate compared with sham control tissues (Fig. 5).

6. Ultrastructural damage in chronic prostate ischemia

TEM of ischemic rabbit prostate tissue showed swollen epithelium with diffuse vacuolization, loss of desmosomes, and disruption of epithelial cell-to-cell junctions (Fig. 6). Separated and twisted SMCs, collagen invasion of SMCs,

Effects of hypoxia and oxidative stress on human prostate smooth muscle cell structure

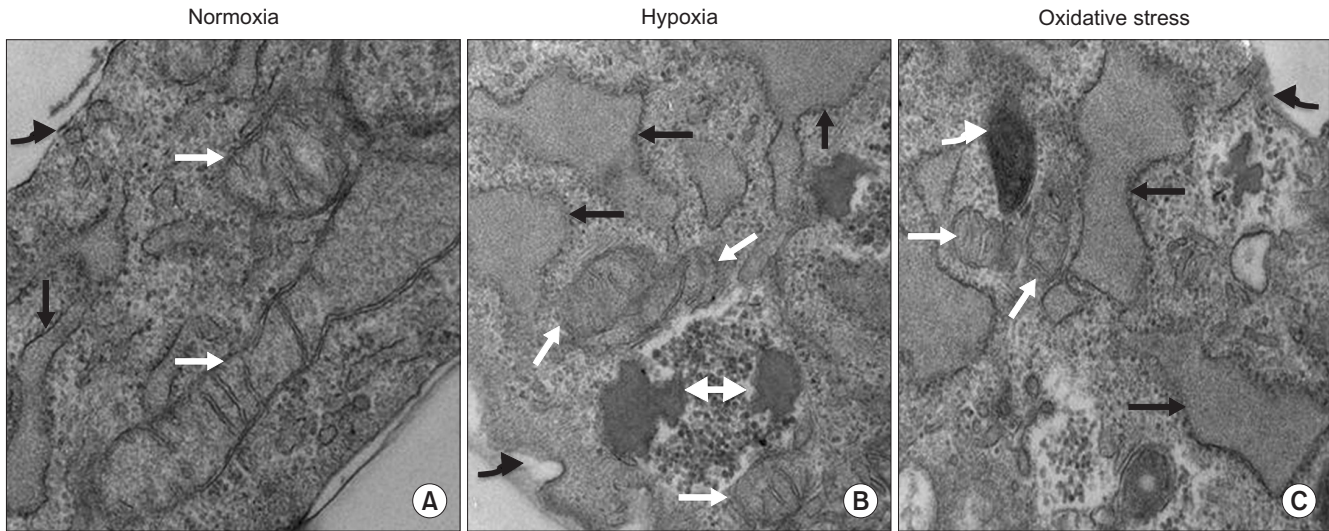


Fig. 3. Hypoxia and oxidative stress altered human prostate SMC structure. (A) TEM of cultured cell samples from the normoxia group showed distinct cell membrane, normal cytoplasmic structures, mitochondria with well-defined membrane and cristae, and normal ER. (B) Cell samples from the hypoxia group showed twisted cell membrane, distorted mitochondria with deformed membranes, swollen deformed ER, and cytoplasmic accumulation of glycogen. (C) Cell samples from the oxidative stress group showed irregular cell membranes and degradation of cytoplasmic structures such as swollen mitochondria with deformed or lost cristae, enlarged and partially degraded ER, and cytoplasmic accumulation lysosomes. White arrows point to mitochondria, black arrows point to ER, curved white arrows points to lysosomes, curved black arrows point to cell membrane, and double arrows point to glycogen. ER, endoplasmic reticulum; SMC, smooth muscle cell; TEM, transmission electron microscopy.

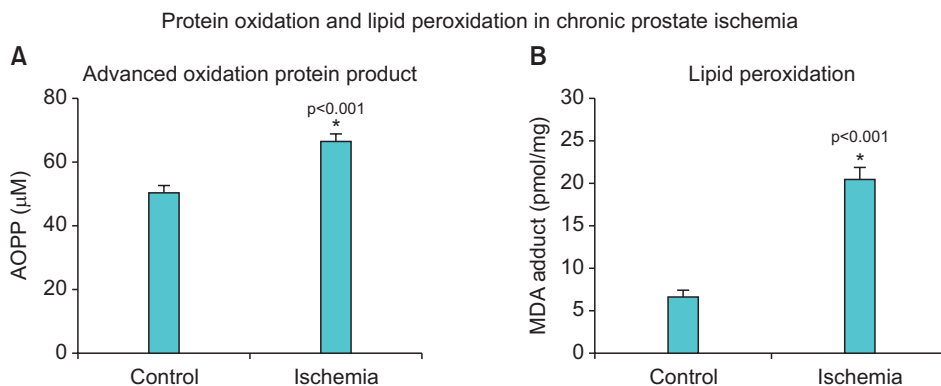


Fig. 4. Markers of oxidative damage in chronic rabbit prostate ischemia. Prostatic tissues from the ischemia group showed significant protein oxidation (A) and lipid peroxidation (B), characterized by significant increases in MDA and AOPP levels versus the sham group. AOPP, advanced oxidation protein product; MDA, malondialdehyde. *Represent significance versus control.

nuclear structural deformation, collagen invasion of the nucleus, and sporadic vacuolization were present in the ischemic prostate (Fig. 6). Swollen mitochondria, loss of mitochondrial membrane, decreased mitochondrial granules, and decreased or completely lost Golgi bodies were found in the ischemic prostatic tissue. These changes were associated with degenerating nerve bundles surrounded by dense collagen fibers (Fig. 7).

DISCUSSION

We observed that human prostate cells exposed to oxidative stress developed structural modifications similar to those in chronically ischemic prostate tissue in a rabbit

model. These changes could lead to prostate noncompliance, which increases bladder outlet resistance and mimics bladder outlet obstruction. We previously demonstrated that pelvic atherosclerosis in rabbits causes lower urinary tract ischemia and oxidative stress, resulting in functional changes in the bladder and prostate leading to voiding dysfunction [16-22,24]. Our prostate ischemia model was recently reproduced in rats and showed similar changes [23]. It is likely that similar processes occur in ischemic or hypoxic human prostate tissue, and studies support a correlation between pelvic ischemia and LUTS in elderly men [15,25]. Wehrberger et al. [26] found that among the 2,092 men included in their study, the 10-year risk among men with severe LUTS for cardiovascular disease (CVD)

Structural changes in chronic prostate ischemia

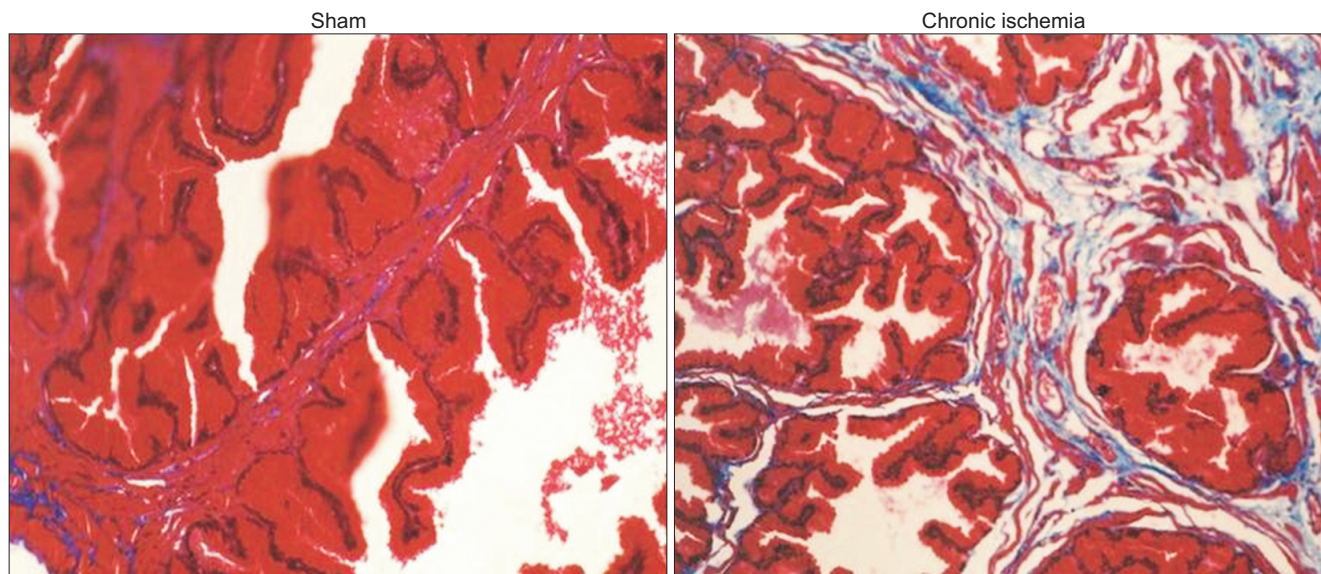


Fig. 5. Masson's trichrome staining of rabbit ischemic prostate tissues ($\times 40$) showed stromal thickening with diffuse fibrosis, decreased smooth muscle fibers, distorted glands with flattened epithelium lining, and large intraluminal spaces compared to prostatic tissues from the sham group ($\times 40$).

and stroke was 15.9% and 11.7%, respectively. With control for age, diabetes, and cholesterol levels, men with severe LUTS had odds ratios for CVD and stroke of 1.28 and 1.66. In addition, studies have reported that compared to symptomatic patients without vascular disease, International Prostate Symptom Scores are significantly worse in men with multiple vascular risk factors [27,28].

The structural modifications we identified leading to noncompliance in prostatic tissue were the result of free radical generation and propagation in the mitochondria. Mitochondria use oxygen to generate adenosine triphosphate (ATP), and excessive activity in the setting of nutrient deficiency, reduced ability to clear waste products, and low oxygen tension lead to an imbalance of homeostatic pathways in the cell. Healthy cells have protective mechanisms to defend against oxidative damage, including enzymes like superoxide dismutase, catalase, and glutathione peroxidase as well as nonenzymatic antioxidants like vitamins C and E, flavonoids, and carotenoids. In certain disease states, these protective pathways can be overwhelmed and create an environment amenable to free radical accumulation and injury [29]. In prior studies, we found that ischemia increases contractile reactivity of prostatic tissue while impairing nitric oxide synthesis and smooth muscle relaxation [20,22]. Increased contractile activity may involve free radical-mediated neuroexcitation, adrenoreceptor hypersensitivity, and co-release of glutamenergic and purinogenic transmission

in the ischemic prostate. In this setting, the machinery for generating ATP is readily hijacked to generate and accumulate free radicals, resulting in mitochondrial injury and malfunction [30].

Oxidative mitochondrial injury has also been shown to initiate free radical damage to other cell structures via leakage of substances that initiate organelle degeneration, such as cytochrome c, endonuclease G, and apoptosis-inducing factor [18]. At high concentrations, free radicals attack mitochondria and other organelles, generate additional radicals, and oxidize the lipid- and protein-containing structures of cells. They oxidize the lipid membranes of the ER, leading to accumulation of poorly folded proteins and protein fragments in the cytosol and nucleus. These oxidative reactions contribute to cell membrane damage, nuclear deformation, collagen accumulation, and loss of nerve fibers. Lysosomes are responsible for breaking up waste products and cellular debris, and the quantity and quality of lysosomes in the cytosol is indicative of the severity of cellular damage [30].

We identified protein oxidation, lipid peroxidation, and DNA damage in all cell types. Whereas lipid peroxidation was frequently detected in prostatic SMCs during hypoxia and oxidative stress, protein oxidation was more prevalent in ECs under both conditions. DNA damage was observed in all prostatic cell types exposed to disturbed oxygen tension. SMCs demonstrated loss of mitochondrial outer membranes and swollen ER, most likely due to leakage

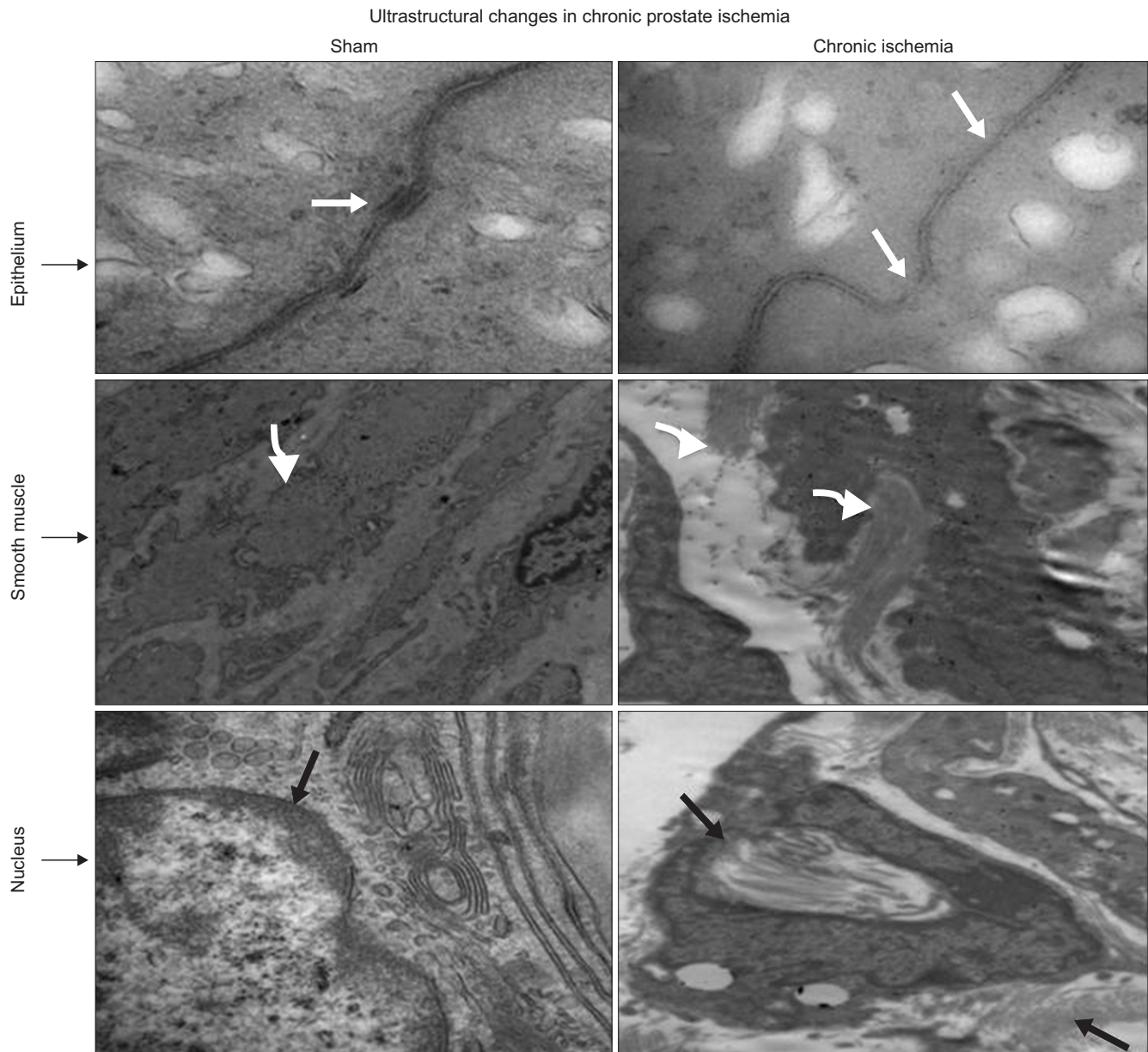


Fig. 6. Transmission electron microscopy of chronically ischemic rabbit prostate showed thickened epithelium with degraded or totally lost desmosomes; disruption of cell to cell junctions; disrupted and twisted muscle cells surrounded by collagen; collagen invasion of smooth muscle cells; nuclear deformation; loss of nuclear membrane; and collagen invasion of the nucleus. White arrows point to desmosome and epithelial cell to cell junctions. Curved arrows point to smooth muscle cells showing collagen accumulation and collagen invasion of smooth muscle cells in the ischemic sample. Black arrows point to nucleus showing collagen invasion of the nucleus and loss of nuclear membrane in the ischemic sample.

of free radicals into the cytosol. In SMCs exposed to intermittent low oxygen tension, these changes were more pronounced, suggesting extensive oxidative injury. Swelling and enlargement of mitochondria and ER may indicate hypoxia-related survival signaling as well as coping mechanisms within the cell to generate energy and preserve protein synthesis. On the other hand, degraded, splintered, and damaged organelles and increased numbers of lysozymes in oxidative stress appear to indicate structural deterioration and the onset of cell degeneration.

Products of protein and lipid oxidation have already been identified as markers of oxidative stress and may prove useful in clinical practice in helping to identify ischemia as an etiology of LUTS.

Markers of oxidative damage and deterioration of cell organelles in chronic prostate ischemia were associated with epithelial atrophy, loss of smooth muscle, degeneration of nerve bundles, and diffused fibrosis. Collagen bundles appear to surround and invade degenerating structures including SMCs, nucleus, and nerve

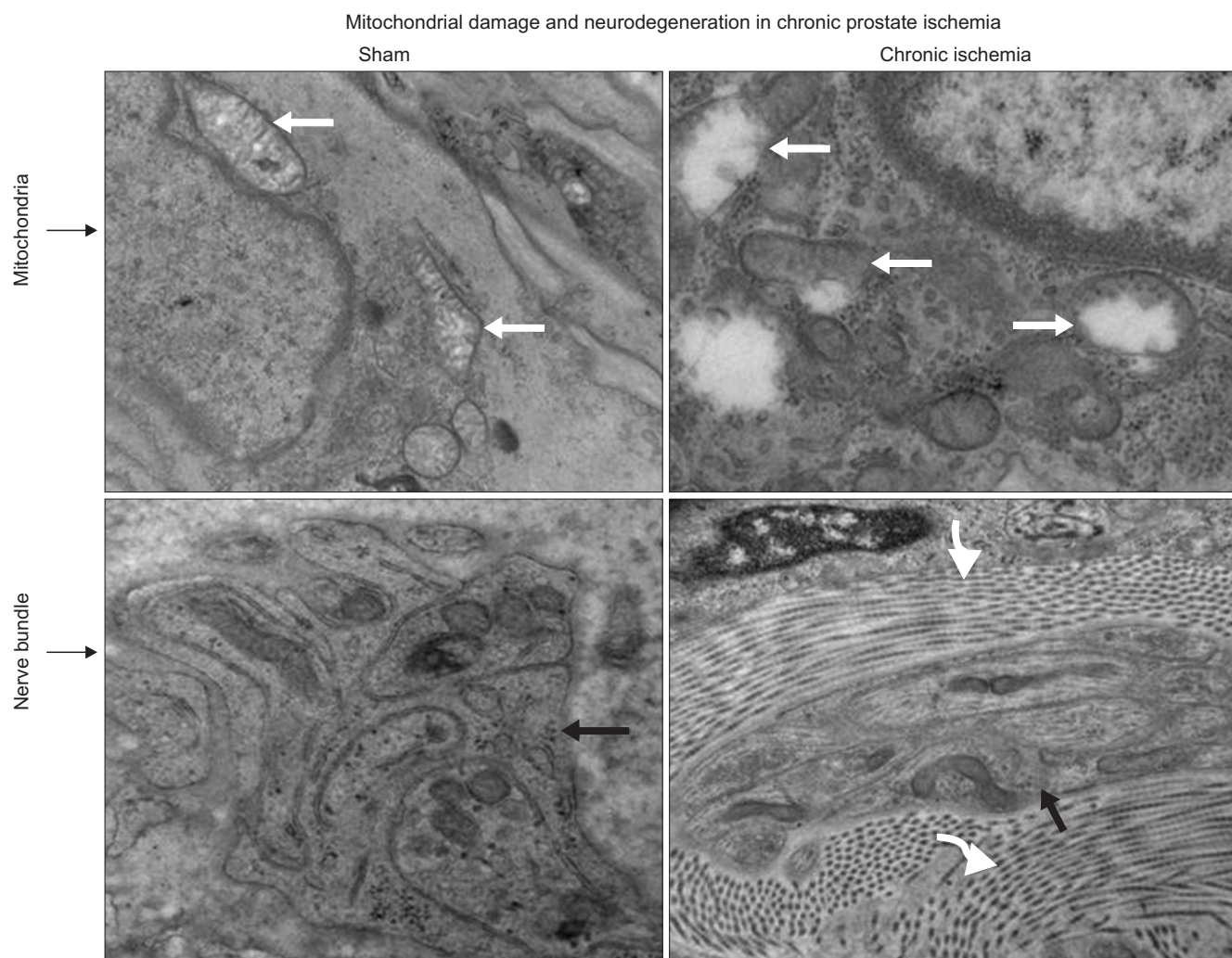


Fig. 7. Marked changes in cellular organelles including swollen mitochondria with irregular membrane, loss of mitochondrial membrane, disrupted mitochondrial granules, and sporadic vacuolization were present in the chronically ischemic rabbit prostate. Mitochondrial structural damage in the ischemic prostate was associated with degenerating nerve bundles surrounded by dense collagen fibers. White arrows point to mitochondria, black arrows point to the nerve bundles, and curved arrows point to collagen fiber bundles around the nerves.

fibers. Previous studies of chronically ischemic bladder tissue demonstrated increased collagen production and altered muscarinic receptor activity, followed by nerve bundle degeneration, fibrosis, and eventual loss of bladder contractility and noncompliance [19]. In addition, we have shown that oxidative stress is a key component of neurodegeneration in the bladder [18]. This study strongly suggests that prostatic neurodegeneration most likely results from free radical-mediated reactions within neural structures as well as neurotoxic elements accumulating in adjacent tissues. The result is the subsequent destruction of the myelin sheath and degeneration of the underlying neurons and axons. Although further investigation is necessary to identify evidence of oxidative reactions in prostatic neurons, if present, it stands to reason that oxidative damage would affect bladder neck contractility

and relaxation of the prostate, thus contributing to voiding dysfunction.

CONCLUSIONS

This study adds further support to the already growing body of evidence that factors other than prostatic size may contribute to LUTS. Structural modifications resulting in limited elasticity of the prostate secondary to ischemic disease states can alter the dynamic mechanisms of voiding. Oxidative deterioration of prostatic epithelial and SCs, loss of SMCs and nerve fibers, and ensuing fibrosis may lead to stiffness, noncompliance, and increased bladder outlet resistance. Further research into the role of pelvic ischemia in prostate structural damage and smooth muscle contractility may lead to more effective diagnosis

and better management of LUTS.

CONFLICTS OF INTEREST

The authors have nothing to disclose.

ACKNOWLEDGMENTS

This study was supported by Grant BLR&D MERIT 1I01BX001428 from the U.S. Department of Veterans Affairs.

REFERENCES

- Berry SJ, Coffey DS, Walsh PC, Ewing LL. The development of human benign prostatic hyperplasia with age. *J Urol* 1984;132:474-9.
- Jacobsen SJ, Girman CJ, Lieber MM. Natural history of benign prostatic hyperplasia. *Urology* 2001;58(6 Suppl 1):5-16.
- Madersbacher S, Pycha A, Schatzl G, Mian C, Klingler CH, Marberger M. The aging lower urinary tract: a comparative urodynamic study of men and women. *Urology* 1998;51:206-12.
- Barry MJ, Cockett AT, Holtgrewe HL, McConnell JD, Sihelnik SA, Winfield HN. Relationship of symptoms of prostatism to commonly used physiological and anatomical measures of the severity of benign prostatic hyperplasia. *J Urol* 1993;150(2 Pt 1):351-8.
- Bosch JL, Kranse R, van Mastrigt R, Schroder FH. Reasons for the weak correlation between prostate volume and urethral resistance parameters in patients with prostatism. *J Urol* 1995;153(3 Pt 1):689-93.
- Girman CJ, Jacobsen SJ, Guess HA, Oesterling JE, Chute CG, Panser LA, et al. Natural history of prostatism: relationship among symptoms, prostate volume and peak urinary flow rate. *J Urol* 1995;153:1510-5.
- Diokno AC, Brown MB, Goldstein NG, Herzog AR. Urinary flow rates and voiding pressures in elderly men living in a community. *J Urol* 1994;151:1550-3.
- Eckhardt MD, van Venrooij GE, Boon TA. Symptoms, prostate volume, and urodynamic findings in elderly male volunteers without and with LUTS and in patients with LUTS suggestive of benign prostatic hyperplasia. *Urology* 2001;58:966-71.
- Gup DI, Shapiro E, Baumann M, Lepor H. Contractile properties of human prostate adenomas and the development of infravesical obstruction. *Prostate* 1989;15:105-14.
- Hutchison A, Farmer R, Verhamme K, Berges R, Navarrete RV. The efficacy of drugs for the treatment of LUTS/BPH, a study in 6 European countries. *Eur Urol* 2007;51:207-15.
- Ichiyanagi O, Sasagawa I, Suzuki Y, Ishigooka M, Nakada T. Relation between urethral elasticity and bladder outlet obstruction and histologic composition of the prostate in patients with benign prostatic hyperplasia. *Urology* 1999;53:1149-53.
- Madersbacher S, Marszalek M, Lackner J, Berger P, Schatzl G. The long-term outcome of medical therapy for BPH. *Eur Urol* 2007;51:1522-33.
- McConnell JD, Roehrborn CG, Bautista OM, Andriole GL Jr, Dixon CM, Kusek JW, et al. The long-term effect of doxazosin, finasteride, and combination therapy on the clinical progression of benign prostatic hyperplasia. *N Engl J Med* 2003;349:2387-98.
- Berger AP, Bartsch G, Deibl M, Alber H, Pachinger O, Fritsche G, et al. Atherosclerosis as a risk factor for benign prostatic hyperplasia. *BJU Int* 2006;98:1038-42.
- De EJ, Hou P, Estrera AL, Sdringola S, Kramer LA, Graves DE, et al. Pelvic ischemia is measurable and symptomatic in patients with coronary artery disease: a novel application of dynamic contrast-enhanced magnetic resonance imaging. *J Sex Med* 2008;5:2635-45.
- Tarcan T, Azadzo KM, Siroky MB, Goldstein I, Krane RJ. Age-related erectile and voiding dysfunction: the role of arterial insufficiency. *Br J Urol* 1998;82 Suppl 1:26-33.
- Azadzo KM, Chen BG, Radisavljevic ZM, Siroky MB. Molecular reactions and ultrastructural damage in the chronically ischemic bladder. *J Urol* 2011;186:2115-22.
- Azadzo KM, Radisavljevic ZM, Golabek T, Yalla SV, Siroky MB. Oxidative modification of mitochondrial integrity and nerve fiber density in the ischemic overactive bladder. *J Urol* 2010;183:362-9.
- Azadzo KM, Yalla SV, Siroky MB. Oxidative stress and neurodegeneration in the ischemic overactive bladder. *J Urol* 2007;178:710-5.
- Azadzo KM, Babayan RK, Kozlowski R, Siroky MB. Chronic ischemia increases prostatic smooth muscle contraction in the rabbit. *J Urol* 2003;170(2 Pt 1):659-63.
- Azadzo KM, Yalla SV, Siroky MB. Human bladder smooth muscle cell damage in disturbed oxygen tension. *Urology* 2011;78:967.e9-15.
- Kozlowski R, Kershen RT, Siroky MB, Krane RJ, Azadzo KM. Chronic ischemia alters prostate structure and reactivity in rabbits. *J Urol* 2001;165:1019-26.
- Zarifpour M, Nomiya M, Sawada N, Andersson KE. Protective effect of tadalafil on the functional and structural changes of the rat ventral prostate caused by chronic pelvic ischemia. *Prostate* 2015;75:233-41.
- Azadzo KM, Tarcan T, Kozlowski R, Krane RJ, Siroky MB. Overactivity and structural changes in the chronically ischemic bladder. *J Urol* 1999;162:1768-78.

25. Pinggera GM, Mitterberger M, Steiner E, Pallwein L, Frauscher F, Aigner F, et al. Association of lower urinary tract symptoms and chronic ischaemia of the lower urinary tract in elderly women and men: assessment using colour Doppler ultrasonography. *BJU Int* 2008;102:470-4.
26. Wehrberger C, Temml C, Gutjahr G, Berger I, Rauchenwald M, Ponholzer A, et al. Is there an association between lower urinary tract symptoms and cardiovascular risk in men? A cross sectional and longitudinal analysis. *Urology* 2011;78:1063-7.
27. Kim S, Jeong JY, Choi YJ, Kim DH, Lee WK, Lee SH, et al. Association between lower urinary tract symptoms and vascular risk factors in aging men: The Hallym Aging Study. *Korean J Urol* 2010;51:477-82.
28. Ponholzer A, Temml C, Wehrberger C, Marszalek M, Madersbacher S. The association between vascular risk factors and lower urinary tract symptoms in both sexes. *Eur Urol* 2006;50:581-6.
29. Li N, Ragheb K, Lawler G, Sturgis J, Rajwa B, Melendez JA, et al. Mitochondrial complex I inhibitor rotenone induces apoptosis through enhancing mitochondrial reactive oxygen species production. *J Biol Chem* 2003;278:8516-25.
30. Voss P, Siems W. Clinical oxidation parameters of aging. *Free Radic Res* 2006;40:1339-49.