

Reviews

Familial Cortical Myoclonic Tremor and Epilepsy, an Enigmatic Disorder: From Phenotypes to Pathophysiology and Genetics. A Systematic Review

Tom van den Ende¹, Sarvi Sharifi¹, Sandra M. A. van der Salm^{2,3} & Anne-Fleur van Rootselaar^{1*}

¹ Department of Neurology and Clinical Neurophysiology, Amsterdam Neuroscience, Academic Medical Center, Amsterdam, The Netherlands, ² Brain Center Rudolf Magnus, Department of Neurology and Neurosurgery, University Medical Center, Utrecht, The Netherlands, ³ Stichting Epilepsie Instellingen Nederland (SEIN), Zwolle, The Netherlands

Abstract

Background: Autosomal dominant familial cortical myoclonic tremor and epilepsy (FCMTE) is characterized by distal tremulous myoclonus, generalized seizures, and signs of cortical reflex myoclonus. FCMTE has been described in over 100 pedigrees worldwide, under several different names and acronyms. Pathological changes have been located in the cerebellum. This systematic review discusses the clinical spectrum, treatment, pathophysiology, and genetic findings.

Methods: We carried out a PubMed search, using a combination of the following search terms: cortical tremor, myoclonus, epilepsy, benign course, adult onset, familial, and autosomal dominant; this resulted in a total of 77 studies (761 patients; 126 pedigrees) fulfilling the inclusion and exclusion criteria.

Results: Phenotypic differences across pedigrees exist, possibly related to underlying genetic differences. A “benign” phenotype has been described in several Japanese families and pedigrees linked to 8q (FCMTE1). French patients (5p linkage; FCMTE3) exhibit more severe progression, and in Japanese/Chinese pedigrees (with unknown linkage) anticipation has been suggested. Preferred treatment is with valproate (mind teratogenicity), levetiracetam, and/or clonazepam. Several genes have been identified, which differ in potential pathogenicity.

Discussion: Based on the core features (above), the syndrome can be considered a distinct clinical entity. Clinical features may also include proximal myoclonus and mild progression with aging. Valproate or levetiracetam, with or without clonazepam, reduces symptoms. FCMTE is a heterogeneous disorder, and likely to include a variety of different conditions with mutations of different genes. Distinct phenotypic traits might reflect different genetic mutations. Genes involved in Purkinje cell outgrowth or those encoding for ion channels or neurotransmitters seem good candidate genes.

Keywords: Familial, cortical, myoclonus, tremor, epilepsy, genetics

Citation: van den Ende T, Sharifi S, van der Salm SMA, van Rootselaar AF. Familial cortical myoclonic tremor and epilepsy, an enigmatic disorder: from phenotypes to pathophysiology and genetics. A systematic review. *Tremor Other Hyperkinet Mov.* 2018; 8. doi: 10.7916/D85155WJ

*To whom correspondence should be addressed. E-mail: a.f.vanrootselaar@amc.uva.nl

Editor: Elan D. Louis, Yale University, USA

Received: August 11, 2017 **Accepted:** January 2, 2018 **Published:** January 23, 2018

Copyright: © 2018 van den Ende et al. This is an open-access article distributed under the terms of the Creative Commons Attribution–Noncommercial–No Derivatives License, which permits the user to copy, distribute, and transmit the work provided that the original authors and source are credited; that no commercial use is made of the work; and that the work is not altered or transformed.

Funding: None.

Financial Disclosures: None.

Conflicts of Interest: The authors report no conflicts of interest.

Ethics Statement: Not applicable for this category of article.

Introduction

Autosomal dominant familial cortical myoclonic tremor and epilepsy (FCMTE) has over the years accumulated several names and acronyms including autosomal dominant cortical myoclonus and epilepsy (ADCME), benign adult familial myoclonic epilepsy (BAFME), cortical tremor (Crt Tr), familial adult myoclonic epilepsy (FAME), familial cortical myoclonic tremor (FCMT), familial cortical tremor with epilepsy (FCTE), familial essential myoclonus and epilepsy (FEME), familial benign myoclonus epilepsy of adult onset (FMEA), and hereditary familial tremor and epilepsy

(HTE) (Table 1).¹ FCMTE will in the manuscript serve as the acronym for all abbreviations, as suggested in 2005,² and as currently classified by the HUGO Gene Nomenclature Committee (HGNC).³ The syndrome was first described in the 1990s in Japan, in families with hereditary tremor (distal tremulous myoclonus) and epilepsy.^{4–7} Subsequently, over a hundred pedigrees have been identified in different countries, which have proven to be genetically heterogenic in linkage studies.

Symptoms of FCMTE are tremor-like cortical myoclonus, which can mimic essential tremor (ET), and epileptic seizures. Distal tremulous

Table 1. Familial Cortical Tremor/Myoclonus Syndromes

Acronym	
ADCME	Autosomal dominant cortical myoclonus and epilepsy
BAFME	Benign adult familial myoclonic epilepsy
Crt Tr	Cortical tremor
FAME	Familial adult myoclonic epilepsy
FCMT	Familial cortical myoclonic tremor
FCMTE	Familial cortical myoclonic tremor with epilepsy
FCTE	Familial cortical tremor with epilepsy
FEME	Familial essential myoclonus and epilepsy
FMEA	Familial benign myoclonus epilepsy of adult onset
HTE	Hereditary familial tremor and epilepsy

movements are usually the first symptom, usually with an onset in the second or third decade. Seizures, most often unprovoked generalized tonic-clonic seizures without aura, start later in life, frequently in the third or fourth decade. Diagnosis is based on clinical characteristics and family history, and is supported by electrophysiological investigations, after exclusion of other tremulous disorders and epileptic syndromes. Treatment is symptomatic, usually with anti-epileptic drugs such as valproate and clonazepam.

Additional symptoms have also been described, possibly extending the spectrum of the disease. These include mild cognitive decline^{8–12} but also psychiatric symptoms,¹³ nystagmus,¹⁴ and migraine.^{15–18} Clinical anticipation has been described in Asian pedigrees.^{19–21} It is unknown which of these symptoms are part of FCMTE or are co-incident, and which symptoms might differentiate between underlying genetic mutations.

FCMTE maps to different loci including 8q23.3-q24.13 (Online Mendelian Inheritance in Man [OMIM],²² HGNC,²³ FCMTE1) in Japanese families^{24–26} and a Chinese pedigree;²⁷ 2p11.1-q12.2 (OMIM,²⁸ HGNC,²³ FCMTE2) in multiple Italian pedigrees,^{8,9,17,29–33} a Spanish family,^{29,34} and a family from New Zealand/Australia with ancestors from Austria;¹⁶ 5p15.31-p15 (OMIM,³⁵ HGNC,²³ FCMTE3) in a French family,^{29,36–38} a Dutch pedigree,³⁹ and two Chinese pedigrees;^{40,41} and 3q26.32-3q28 (OMIM,⁴² FCMTE4) in a Thai family.⁴³ Also, an autosomal recessive form of FCMTE (OMIM,⁴⁴ FCMTE5) has been identified in an Egyptian family where a mutation has been localized in the contactin 2 (*CNTN2*) gene, which is associated with potassium channel stability.⁴⁵ In autosomal dominant FCMTE, several possible gene mutations have been proposed as causative on the FCMTE loci.^{27,46–49} Recently, a mutation was found in a Dutch FCMTE3 pedigree in the catenin delta 2 (*CTNND2*) gene, supported by functional tests.³⁹

Neurophysiological, imaging, genetic, and pathology findings have shed some light on the pathophysiology underlying FCMTE. A cortical origin of the myoclonus in FCMTE is proven by electrophysiological investigation consistent with reduced cortical inhibition.¹⁴ Pathology findings in a Dutch FCMTE pedigree indicate Purkinje cell changes, resembling the abnormal neuronal morphology in *Ctnd2* mutant mice.^{1,39,50} Congruent imaging findings include decreased fiber density,⁵¹ functional connectivity alterations⁵² and gray matter loss in the cerebellar motor area.⁵³ It has been hypothesized that, via the cerebello-thalamo-cortical loop, reduced input from the cerebellum can lead to cortical hyperexcitability.⁵⁴ However, the question arises if the cerebellum is the primary generator of cortical hyperexcitability in all FCMTE types. Alternatively, cortical functional changes could underlie the symptoms, with or without coexisting cerebellar pathology.

This review will bring together evidence concerning the clinical spectrum including treatment on the one hand, and, on the other hand, pathophysiological and genetic studies, adding the latest insights.¹ The current review aims to not only summarize studies into FCMTE, but also be of guidance to the clinician encountering a patient with suspected FCMTE. A second aim is to link insights from pathophysiological studies to genetic studies to better understand the underlying disease mechanisms and be a guide for future research and better treatment of these patients.

Methods

We conducted a PubMed search on November 15, 2017, for the period January 1, 2011, to November 15, 2017, using a combination of the following search terms: cortical tremor, myoclonus, epilepsy, benign course, adult onset, familial, autosomal dominant, and the different acronyms for FCMTE fully written; see Appendix A for complete search terms. The search delivered a total of 1,180 articles, and one additional from reference lists, from which 33 fulfilled the selection criteria (flow chart, Figure 1). The search conducted for our previous review in 2011 had already revealed a total of 44 publications published before 2011,¹ which are also included in the current review (Tables 2 and 3).

Included were reports published in English describing pedigrees with the following diagnostic criteria as previously reported:¹ 1) distal action and postural tremor/fine myoclonus; 2) generalized tonic-clonic seizures and/or electrophysiological features of cortical reflex myoclonus including giant somatosensory evoked potentials (SEPs) and/or enhanced long loop reflexes (LLRs/C reflex); and 3) a family history of tremor/epilepsy consistent with autosomal dominant inheritance. Excluded were pedigrees and cases with another cause for tremor and epilepsy (including autosomal recessive FCMTE⁴⁵), structural lesions on magnetic resonance imaging (MRI), and additional symptoms such as clear parkinsonism, dementia, and/or ataxia pointing to a different syndrome.

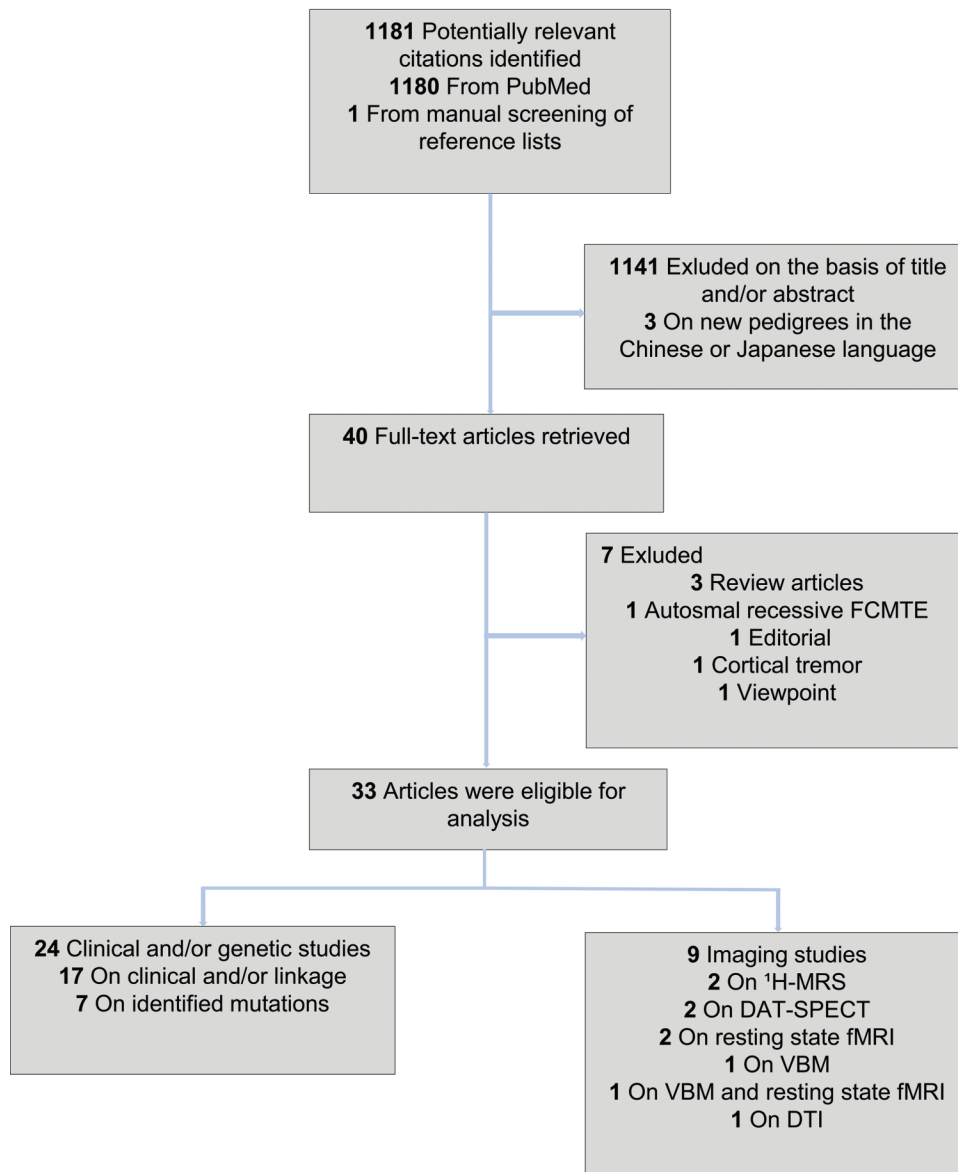


Figure 1. Article Selection Flowchart. Literature search for the identification of new pedigrees, genetic/linkage or imaging studies since our last review.¹ Thirty-three articles were eligible for analysis: 17 reported on clinical and electrophysiology findings with or without linkage analysis, nine reported on neuroimaging, and seven reported on new potential pathogenic mutations. Abbreviations: DAT-SPECT, Dopamine Transporter, Single Photon Emission Computed Tomography; DTI, Diffusion Tensor Imaging; FCMTE, Familial Cortical Myoclonus Tremor And Epilepsy; fMRI, Functional Magnetic Resonance Imaging; ¹H-MRS, Proton Magnetic Resonance Spectroscopy; VBM, Voxel Based Morphometry.

Results

In total 77 publications (126 pedigrees; 761 patients) were retrieved from the combined current PubMed search and the 2011 search.¹ For an overview of additional pedigrees since our last review¹ see Table 2. Table 3 shows the pedigrees previously identified.¹ Since 2011, 70 additional pedigrees in 33 publications, including 48 from India, have been extensively described (providing clinical and electrophysiological data, Table 2).^{16–18,21,27,40,41,43,46–48,55–59} Descriptions of the pedigrees comply with autosomal dominant inheritance. The reports

used uniform criteria for diagnosing FCMTE, and one paper explicitly stated they used the diagnostic criteria from our last review.⁵⁵ The reports vary in detail in their description of the neurological examination, the presence or absence of cerebellar signs, of cognitive assessment, comorbid psychiatric disorders, effect of anti-epileptic drugs on tremor/epileptic seizures, drug dosage, clinical anticipation, structural imaging, and electrophysiological investigation including jerk-locked back averaging (JLA). Owing to insufficient clinical/electrophysiological data, several new families were not included in Table 2.^{13,19,20,29,60}

Table 2. Described Pedigrees (2011–2017) with Core Disease Characteristics

Descent	Genetics	Origin, # Family	Clinical features			Electrophysiology			Imaging (cases)	Additional Symptoms, Other Findings	
			Myoclonus	Seizures	Seizure Type	JLA	Giant SEP	LLR			EEG
Age at Onset mean and (range)											
Asian	8q, <i>SLC30A8</i>	Chinese, 1 ²⁷	26 (13–36)	34 (29–40)	GTC	n.d.	+	+	n.a.	n.a. (1)	No CA; M lower limbs (n:2)
	8q, <i>UBR5</i>	Japanese, 1 ³⁶	?	?	G	n.d.	n.d.	n.d.	n.d.	n.a. (1)	M worse aging
	22q, <i>PLA2G6</i>	Chinese, 1 ⁴⁷	29 (21–38)	39 (36–46)	G, GTC, Ph	n.d.	+	+	PSW, PMR	n.a. (1)	M rest; Head; Lower limbs (n:1)
	5p	Chinese, 2 ^{40,41}	>18	>30	G, GTC, Ph	n.d.	+	n.d.	PSW, PRA	n.d.	Non-progressive; Headache
	3q	Thai, 1 ⁴³	19 (10–33)	25 (19–33)	G, GTC	+	+	+	PSW, SW, PPR, PMR	n.d.	Early-onset seizures
	8q, n.d.	Chinese, 9 ²¹	31 (15–59)	36 (19–64)	GTC, Ph	n.d.	+	+	G-E, Sp, Sw	n.d.	S before M (n:5); Headache; M worse aging
	n.d.	Chinese, 1 ⁵⁵	30 (20–40)	39 (28–48)	GTC	n.d.	n.d.	n.d.	E, Sp, Sw	+ (7)	Night blindness; Mild cognitive decline; CA
	n.d.	Indian, 48 ⁵⁶	25 maj (14–40)		GTC, CP, Ph	n.d.	+	n.d.	PSW, F, PPR	n.a. (48)	Rest fMRI abnormalities
			Seizures possibly first symptom 48%								
European	n.d.	Indian, 1 ⁵⁷	>15	?	GTC	n.d.	n.d.	n.d.	PSW, Sw, PPR	n.a. (3)	Cognitive decline; M axial; M worse aging
	2p	Italian, 1 ¹⁷	28 (19–40)	34 (5–63)	GTC, M, Ph	+	+	+	G-E, PSW, Sw, PPR	n.a. (2)	Psychiatric comorbidity; M worse aging
			Gait disability; Cognitive decline (n:2); Migraine;								
			TMS reduction rest motor threshold								
	2p	New Zealand/Australia, 1 ¹⁶	Median 15 (4–60)	Median 44 (18–76)	GTC, F	+	+	+	PSW, PMR	n.a. (7), + (1)	Migraine; M head, legs, 'drop attacks'; M worse aging
		European ancestors	Severe M before S around sleep onset								
	2p, <i>ACMSD</i>	Spain, 1 ⁴⁸	>17 (17–23)	19 (17–22)	GTC, PSG	n.d.	+	+	PSW, PPR	+ (2)	Parkinsonism (n:1); Cognitive decline (n:1);
	2p, <i>ADR42B</i>	Italian, 1 ⁴⁶	(18–50)	?	GTC, CP, F	+	+	+	G paroxysmal activity	n.a. (3)	Mild ataxia unaffected patient (n:1); Cognitive imparity (n:1); Age-related dementia
	n.d.	South Africa, 1 ⁵⁰	16 (12–20)	39 (30–45)	GTC	n.d.	+	+	G-E, TLE, PSW	n.d.	ADL and MRS affected by M severity;

Table 2. Continued

Descent	Genetics	Origin, # Family	Clinical features			Electrophysiology			Imaging (cases)	Additional Symptoms, Other Findings
			Myoclonus	Seizures	Seizure Type	JLA	Giant SEP	LLR		
		European descent	> 13 (13–16)	> 17 (14–17)	GTC, F, A, M	n.d.	n.d.	n.d.	n.a. (3)	Gait dysfunction; Facial M (n:2); M worse aging; No (ataxia/cognitive decline) after 30 years
	n.d.	Turkish, 1 ¹⁸	> 13 (13–16)	> 17 (14–17)	GTC, F, A, M	n.d.	n.d.	n.d.	n.a. (3)	Frequent M seizures (1 x month); Migraine; Drop attacks; Psychiatric comorbidity

Higher than ET and JME

Abbreviations: A, Absence; ACMSD, Aminocarbonylacetate Semialdehyde Decarboxylase; ADL, Activities of Daily Living; ADRA2B, α 2-Adrenergic Receptor Subtype B; AED, Anti-epileptic Drug; CA, Clinical Anticipation; CP, Complex Partial; EEG, Electroencephalography; ET, Essential Tremor; F, Focal; fMRI, Functional Magnetic Resonance Imaging; G, Generalized; G-E, Generalized Epileptiform; giant SEP, Giant Somatosensory Evoked Potential; GTC, Generalized Tonic-Clonic; HLA, Humane Leukocyte Antigen; JLA, Jerk Locked Back Averaging; LLR, Long Latency Reflex; JME, Juvenile Myoclonic Epilepsy; M, Myoclonic/Myoclonus; maj, Majority; MRS, Myoclonus Rating Scale; n, Number; n.a., No Abnormalities; n.d., Not Done; Ph, Photosensitivity; PLA2G6, Phospholipase A2 Group 6; PMR, Photomyoclonic Response; PPR, Photoparoxysmal Response; PRA, Paroxysmal Rate Abnormalities; PSG, Partial Secondly Generalized; PSW, Polyspike-Wave Complexes; S, Seizures; SIC30A8, Solute Carrier Family 30 (zinc transporter), Member 8; Sp, Spikes; SW, Slow Waves; SW, Spike Wave Complexes; TLE, Temporal Lobe Epileptiform; TMS, Transcranial Magnetic stimulation; UBR5, Ubiquitin Protein Ligase E3 Component n-Recognin 5; +, Abnormal; -, Normal; # family, Number of Described Families; ?, Not Known. Insufficient information on new pedigrees (n: number) and could therefore not be added to Table 2 n:3, France¹⁹; n:7, Japan¹³; n:3, Italy¹³; 19 patients⁶⁰.

The results section covers both the previously identified and novel pedigrees.

The FCMTE phenotype; core characteristics and less common findings

Clinical spectrum. FCMTE usually starts with tremor-like, cortical myoclonus of the distal limbs, with onset in the second or third decade (range 3–70 years). Epileptic seizures usually start in the third or fourth decade (range 5–76 years), for which patients often seek medical attention. However, epileptic seizures can also be the first symptom.^{17,21,43,56}

The tremulous movements are in fact small, high-frequency myoclonic jerks, induced by posture or action. They can be mild, but can also be more incapacitating.^{17,27,47,57,58} When present in the lower limbs, these may lead to gait disorders^{17,36–38,58,61} and even “drop attacks”.^{16,18} These tremor-like movements during action can easily be mistaken for ET. Electrophysiological measures can distinguish FCMTE from ET, showing short irregular electromyography (EMG) bursts during action and a cortical drive. Stimulus-sensitive myoclonus, frequently present in FCMTE, may be triggered or worsened by alcohol, emotional stress, sleep deprivation, tactile stimuli, and photic/ phonic stimulation.^{16,17,21,37,47,56,57,62} Twitching movements can involve facial/axial muscles.^{16,21,57,58} Alcohol responsiveness has been reported in two pedigrees.^{16,58} Myoclonus may remain stable, but long-term follow-up is not always present.^{18,40,41} Also, myoclonus has been reported to worsen with progressing age.^{10,16,17,21,36,57,58,63}

Epileptic seizures are usually generalized tonic-clonic seizures, but can also be complex partial seizures.^{8,37,46,56} Recently the latter were renamed as focal seizures with impaired awareness (International League Against Epilepsy [ILAE] 2017 classification).⁶⁴ Moreover, they can be drug resistant.⁴⁶ Focal seizures with mesiotemporal symptoms or motor symptoms (déjà vu and fear) have been reported in four patients.^{16,46} Generalized seizures mostly start without a warning sign but sometimes are preceded by severe myoclonus.^{16,56} Also, myoclonic seizures have been described.^{11,17,18} Seizures are reported to be induced by sleep deprivation, photic stimulation, stress, excitement,^{16,37,47,62} or snow.²¹ Frequency is usually low. Over five seizures per year is uncommon,^{13,16,17,21,27,43,47,58} but more severe cases (≥ 10 seizures per year) have been described.^{10,18,37}

Additional clinical findings, possibly extending the clinical spectrum, are listed below.

- Cerebellar findings include in French pedigrees mild ataxia and gait instability,^{17,37,38,62} (downbeat) nystagmus increasing with hyperventilation in a Dutch pedigree,¹⁴ and dysarthria in South African/French pedigrees.^{10,38} Ataxia is not a feature of FCMTE^{16,17,27,47,57,58,60,65} but subtle cerebellar signs have not explicitly been ruled out.
- Mild cognitive decline, not including dementia, has been noted in some papers.^{8–12,52,57}
- Psychiatric comorbidity has been noted in seven Italian families (FCMTE2),^{13,17} anxiety in Indian patients,⁵⁶ schizophrenia in a Chinese pedigree,⁶⁶ and psychiatric comorbidity in a Turkish family.¹⁸ State anxiety (measured by a scoring list), depression, and

Table 3. Described Pedigrees (up until 2011) with Core Disease Characteristics¹

Descent	Genetics	Origin, # Family	Clinical features		Electrophysiology			Structural		Additional Symptoms, Other Findings	Summary
			Tremor, Myoclonus	Seizures Type	JLA	giant SEP	LLR	EEG	Imaging (cases)		
Asian	8q	Japanese, 5 ^{24,25}	18-45	? GTC	+	+	+	G-PSW, PPR, PSW, PMR	atr (3) n.a. (>14)	n.d.	Classical phenotype Age at onset at adulthood
n.d.		Japanese, 35 ⁷ , 68,69,83,99-104	16-70	17-54 GTC, Ph	+	+	+	PSW, PPR, SW, Sp	atr (3) n.a. (25)	n.a. (4)	Rare: night blindness, behavioral arrest Electrophysiological abnormalities
Excl 2p, 8q		Chinese, 1 ⁶⁶	5-?	? GTC, M	n.d.	n.d.	n.d.	M, SW, PSW	n.d.	n.d.	Schizophrenia in family Classical phenotype with earlier age of onset in the
			(34)					Slow waves			
								13/?			youngest generations
								Presymptomatic changes			
European	2p	Italian, 7 ^{8,9} , 30-33	11-50	12-59 G, GTC, Ph,	+	+	+	Sp, SW, PPR,	atr (3)	n.d.	Visuospatial impairment; Symptoms appear earlier
			maj >20	maj >25 CP, M	Also in presymptomatic			PMR, GPA, PSW, SW	n.a. (27)		Eyelid twitching; Complex partial seizures tremor; Cognitive impairment
								3/7 ⁹			Mild cognitive impairment
								Absent in 1 pedigree ⁹			impairment; TMS cortical hyperexcitability, normal
											sensorimotor integration
n.d.		Italian, 1 ¹²	12-57	5-18 GTC, Abs	+	+	+	Sp, SW, PPR	atr (2)	n.d.	-
		Turkish, 1 ¹⁵	29-?	30 GTC	n.d.	n.d.	n.d.	G-Sp, SW, PPR	n.a. (1)	n.d.	Migraine
5p		French, 1 ³⁶⁻³⁸	10-47 (30.8)	24-41 GTC, Ph,	+	+	+	Sp, PPR, PS	n.d.	n.d.	Progression in gait symptoms; Sensitivity to exercise; GTC preceding M (5/16);

Table 3. Continued

Descent	Genetics	Origin, # Family	Clinical features		Electrophysiology			Structural		Additional Symptoms, Other Findings	Summary		
			Tremor, Myoclonus	Seizures	Seizure Type	JLA	giant SEP	LLR	EEG			Imaging (cases)	PA (cases)
			(29.1)	CM, PS							No cognitive impairment Gait disorders Indication of progression		
5p, CTNND2		Dutch, 1 ^{2,11,14,30,77}	12–45 (23.5)	13–44 (43)	GTC, M, Ph	-	+	+	SW, PPR	atr (2)	+ (3)	Dysarthria; Ophthalmic migraine; TMS cortical hyperexcitability;	
												n.a. (2)	Frequent seizures; Cognitive impairment; Progression in symptoms
Excl 2p, 8q		Spanish, 1 ⁸¹	30–60 (41)	30–67 (44.6)	GTC	+	+	+	G-PSW	n.a. (5)	n.d.	Childhood onset, Pyramidal signs	
		Italian, 1 ⁶²	3–12	23–34	GTC, CM	+	+	+	SW, FMR, Sp	n.d.	n.d.	Prominent photic induced myoclonus and epilepsy;	
					Ph							Changing symptoms with age; Mild axial ataxia; Behavioral disorder	
		South African, 2 ¹⁰	13–31 (20.9)	?	GTC	+	+	+	Abnormal background, PSW, Sp	atr (8)	+ (1)	Frequent seizures; Cognitive impairment; Signs of	
		Intermarriage with											pyramidal and cerebellar dysfunction; Progression in symptoms
		European settlers											

Abbreviations: Abs, Absence; atr, Atrophy; CM, Cortical Myoclonus; CP, Complex Partial; CTNND2, Catenin Delta 2; EEG, Electroencephalography; excl, Excluded; G, Generalized; GPA, Generalized Paroxysmal Activity; giant SEP, Giant Somatosensory Evoked Potential; GTC, Generalized Tonic-Clonic; inf, Infarct; JLA, Jerk Locked Back Averaging; LLR, Long Latency Reflex; maj, Majority; M, Myoclonic; n.a., No Abnormalities; n.d., Not Done; PA, Pathology; Ph, Photosensitivity; PMR, Photomyoclonic Response; PPR, Photoparoxysmal Response; PSW, Polyspike-Wave Complexes; PS, Partial Seizures; Sp, Spikes; SW, Spike-Wave Complexes; TMS, Transcranial Magnetic Stimulation; +, Abnormal; -, Normal; #, Number Of Described Families; ?, Not Known.

¹The table was originally published in our previous review.¹ We have added the table to the manuscript with minimal changes.

personality disturbances (hypochondriasis and schizophrenia) were more prevalent in Italian FCMTE pedigrees than juvenile myoclonic epilepsy and healthy controls.¹³

- Clinical anticipation has been recognized in Japanese patients with unknown linkage: tremor started at a younger age and seizures newly appeared in the next generation.^{19,20} Possibly, maternal transmission is associated with this phenomenon.²⁰ In Chinese patients paternal transmission was noted in the earlier onset of tremor but not of seizures.²¹
- Other findings include migraine,^{15–18} ophthalmic migraine,³⁷ headaches,⁴⁰ logopenic syndrome,⁶⁷ visual intolerance,⁶¹ frontal dysfunction,⁶¹ night blindness,⁶⁸ motionless state,⁶⁹ absence seizures,¹⁸ parkinsonism,⁴⁸ reduced verbal fluency,⁷⁰ sensitivity to glucose deprivation or vibration as an aggravating factor,^{37,38} and visuospatial impairment.^{9,52}

Electrophysiological findings. Additional investigations in patients suspected of FCMTE to aid the diagnosis include electroencephalography (EEG), EMG, SEP, LLR, JLA, and corticomuscular (EEG-EMG) coherence analysis.

EEG findings may include generalized (poly) spikes and waves, photoparoxysmal response, and photomyogenic responses (Tables 2 and 3). EMG shows arrhythmic/semi-rhythmic high-frequency (≥ 10 per second) burst-like discharges of about 50 ms, which can be synchronous between agonist and antagonist muscles, typical for cortical myoclonus.⁷¹

Often features of cortical reflex myoclonus are present, including giant SEP, enhanced LLR, and/or cortical spikes preceding myoclonus with JLA.⁷¹ EEG-EMG coherence analysis indicated strong corticomuscular coherences around 20 Hz with a cortical drive.⁷² With aging giant SEP and JLA cortical spike amplitude can be enhanced in FCMTE patients.^{16,73} Not all patients have giant SEPs or LLR, possibly due to anti-epileptic drug (AED) use,³³ although giant SEP amplitude can also increase with AED use.²¹

Imaging. Structural imaging with MRI is normal in most cases. Although slight cerebellar atrophy (e.g., vermis)¹⁰ has been described.^{9–11,48} In one patient corticospinal degeneration was present.⁴⁸ In three patients basal ganglia/periventricular white matter changes were observed.¹⁰

Treatment. The treatment of FCMTE consists of the prevention of epileptic seizures and/or reduction of troublesome tremor/myoclonus mainly with AEDs and benzodiazepines. Valproate is the drug most often reported to be effective with or without clonazepam.^{13,16,17,27,43,47,48,56,58,60,65,74} Because of teratogenicity, this should not be prescribed to women of childbearing age. Newer AEDs with a good effect are levetiracetam^{13,17,37,38,43,46,48,58,74,75} and lamotrigine.^{37,58} Other drugs prescribed to prevent seizures in FCMTE are phenobarbital, phenytoin, carbamazepine, clobazam, oxcarbazepine, and primidone.^{1,16,40,43,47,48,58,60,74} One report observed a reduction in tremulous movements from a β -blocker.¹⁶ One to three AEDs usually prevents seizures or reduces them to once a year. Gabapentin has been reported to precipitate myoclonic status.⁷⁶

Pathophysiology

Cortical hyperexcitability can be considered the hallmark of FCMTE. However, cerebellar changes have been described in neuroimaging and pathology studies.

Cortical hyperexcitability. Electrophysiological findings in FCMTE point to cortical hyperactivity and a cortical origin of the tremulous myoclonic movements. Functional (f)MRI-EMG also indicated cortical activity linked to the tremulous movements.⁷⁷ Transcranial magnetic stimulation (TMS) in European pedigrees revealed a reduction in short interval cortical inhibition compared with healthy controls, reflecting hyperexcitability of the cortex.^{9,14} In Japanese FCMTE patients the giant SEP was enhanced, lacking the long-term depression effect seen in healthy controls after quadripulse TMS over the primary motor cortex.⁷⁸ However, post-mortem pathology studies in three Dutch cases revealed limited involvement of the sensorimotor cortex.^{1,14,50}

Cerebellar involvement. Evidence for cerebellar involvement differs between FCMTE types (Table 4, imaging overview). For FCMTE1 and 4 there are no imaging or pathology studies available. In FCMTE2 a proton magnetic resonance spectroscopy (MRS) study indicated cerebellar dysfunction.⁷⁹

In the Dutch FCMTE3 pedigree, with a *CTNND2* gene mutation³⁹ several findings point to cerebellar changes. These include, in certain family members, a downbeat nystagmus upon hyperventilation¹⁴ and in three deceased cases there was Purkinje cell loss in the cerebellar cortex and abnormal morphology of Purkinje cells during pathological examination.^{1,14,50}

In family members of these deceased Dutch patients a mutation was found in the *CTNND2* gene that led to abnormal neuronal sprouting in mice neurons, resembling the aforementioned cerebellar pathology.³⁹ Moreover, imaging findings in the same pedigree showed decreased cerebellar fiber density⁵¹ and gray matter loss in the cerebellar motor area.⁵³ In a Chinese pedigree in which 8q and 2p linkage was excluded, MRS indicated cerebellar dysfunction⁶⁵ and a fMRI study indicated alterations between the cerebellum and supratentorial structures after network analysis.⁵² A South African pathology case, from a pedigree in which 8q and 2p linkage was excluded, revealed focal Purkinje cell loss, neuronal atrophy in the dentate nucleus, and neuronal loss with gliosis in the olives and pallidum.¹⁰

Other findings. A functional MRI/voxel-based morphometry (VBM) study indicated gray matter loss in cortical and subcortical structures with connectivity alterations.⁷⁰ In a resting state fMRI study, compared to ET and healthy controls, the right fusiform gyrus and the posterior cingulate cortex showed decreased amplitude of low-frequency fluctuation (ALFF), and the frontal lobe showed increased ALFF that correlated with disease duration.⁵⁵ In two FCMTE patients with gait difficulties but no benefit from L-dopa in one, MRI showed frontal atrophy and single positron emission computed tomography (SPECT) showed dopamine depletion.⁶¹ In a FCMTE patient with a language disorder and short-term memory problems, MRI showed frontal

Table 4. Imaging Findings across Pedigrees

Reference	Origin, Linkage	Imaging Modality	Design	Cerebellum	Other Findings in FCMTE
Buijink et al. ⁵³	Dutch, 5p	MRI (VBM)	8 FCMTE, 45 ET, 39 HS	Total volume; Crus I; lobules IX, X ↓	n.d.
Total/local cerebellar volume					
Buijink et al. ⁵¹	Dutch, 5p	MRI (DTI)	7 FCMTE, 8 ET, 5 HS	Cerebellum ↓	n.d.
Fractional anisotropy; MDV					
Magnin et al. ⁶⁷	French, 5p	DAT-SPECT, MRI	Case report (n:1)	Atrophy: cerebellum ↓	Atrophy: cortical structures ↓
Magnin et al. ⁶¹			Case report (n:2)		DAT: striatum; cortical perfusion ↓
Sririano et al. ⁷⁹	Italian, 2p	¹ H-MRS	11 FCMTE, 11 HS, Neurochemical ratios	Cho/Cr ratio ↑	n.a.
Long et al. ⁵²	Chinese, excl. 2p, 8q	RS fMRI (BOLD)	11 FCMTE, 15 HS	DN: R crus I with L frontal + R lobule IX ↓ AN: L lobule VIII with temporal, R putamen and L crus I ↑	n.d.
Functional connectivity					
CN: L lobule VIIb and R frontal ↑					
Long et al. ⁶⁵	Chinese, excl. 2p, 8q	¹ H-MRS	12 FCMTE, 12 HS, Neurochemical ratios	NAA/Cho ratio ↓	n.a.
Zeng et al. ⁷⁰	Chinese, excl. 2p, 8q	RS fMRI + VBM	11 FCMTE, 15 HS	n.d.	Gray matter: R hippocampus; R temporal ↓
Gray matter; Functional connectivity					
L orbitofrontal; L prefrontal ↓					
FC: R hippocampus with R parietal ↑					
cingulate, L precuneus, L precentral gyrus ↑					
Wang et al. ⁵⁵	Chinese, n.d.	RS fMRI	7 FCMTE, 7 ET, 10 HS	n.d.	R fusiform gyrus; cingulate ↓
BOLD; ALFF					
Frontal lobe ↑					

Abbreviations: ALFF, Amplitude Of Low Frequency Fluctuation; AN, Attention Network; BOLD, Blood-Oxygen-Level Dependent; Cho, Choline; CN, Control Network; Cr, Creatinine; DAT, Dopamine Transporter; DAT-SPECT, Dopamine Transporter, Single Photon Emission Computed Tomography; DN, Default Network; DTI, Diffusion Tensor Imaging; ET, Essential Tremor; excl, Exclusion; FCMTE, Familial Cortical Myoclonus Tremor And Epilepsy; FC, Functional Connectivity; HS, Healthy Subjects; ¹H-MRS, Proton Magnetic Resonance Spectroscopy; L, Left; MDV, Mean Diffusivity Volume; MRI, Magnetic Resonance Imaging; n, Number; n.a., No Abnormalities; NAA, n-Acetylaspartate; n.d., Not Done; R, Right; RS fMRI, Resting State Functional Magnetic Resonance Imaging; VBM, Voxel Based Morphometry; ↑ Increase; ↓ Decrease.

atrophy and SPECT indicated loss of dopamine transporters in the left striatum.⁶⁷

Genetic linkage, proposed mutations

In several FCMTE pedigrees, causative mutations have been proposed (Table 5). In a Dutch pedigree a mutation in *CTNND2*, supported by functional tests, has recently been discovered.³⁹ However, functional tests have not been performed for every mutation.⁸⁰ Linkage studies indicated several loci: 8q23.3-8q24.13 (FCMTE1)²⁴⁻²⁷; 2p11.1-q12.2 (FCMTE2)^{8,9,16,17,29-34}; 5p15.31-p15 (FCMTE3)^{29,36-41}; and 3q26.32-3q28 (FCMTE4).⁴³ Furthermore, there are several families (Chinese, Spanish, Italian, South African) in which 2p and/or 8q linkage was excluded.^{10,62,66,81} Below we summarize the findings in FCMTE1-4 and FCMTE-like disorders.

Linkage to the FCMTE1 locus on chromosome 8q23.3-8q24.13 was found in several Japanese families²⁴⁻²⁶ and one Chinese family.²⁷ In the Chinese pedigree a single nucleotide variant (SNV) was identified in the *SLC30A8* (solute carrier family 30 [zinc transporter]) gene after whole-exome sequencing (WES).²⁷ However, there is no expression of this gene in the brain, making it irrelevant.²⁷ Besides, sequence and copy number variant analysis of the genes located on the 8q23.3-8q24.13 locus did not reveal any mutation.²⁶

Linkage to the FCMTE2 locus on chromosome 2p11.1-q12.2 was found in Italian,^{8,9,17,29-33} Spanish,^{29,34} and Australian/New Zealand pedigrees (with European ancestors).¹⁶ A founder haplotype was identified in Italian FCMTE2 pedigrees from the same geographical area.^{17,29} A mutation in two Italian family members within the FCMTE2 locus was found on the α2-adrenergic receptor subtype B (*ADRA2B*) gene with next-generation sequencing (NGS).⁴⁶ Identity by descent mapping (IBD), which is able to detect genetic loci with an ancestral segment among pedigree unrelated individuals, refined the FCMTE2 locus to 2p11.1-q11.1 without excluding the *ADRA2B* mutation.²⁹ In a Spanish pedigree, WES indicated an SNV in the aminocarboxymuconate semialdehyde decarboxylase (*ACMSD*) gene encoding for an enzyme that is part of the kynurenine pathway of tryptophan and linked to neurodegenerative diseases and epilepsy.⁴⁸

FCMTE3, with linkage to 5p15.31-p15, has been identified in two Chinese families,^{40,41} a Dutch pedigree,³⁹ and a French family.^{29,36-38} In the Dutch family after WES, a mutation was found in the *CTNND2* gene.³⁹ Knockdown of *Ctnd2* in cortical mouse neurons led to abnormal neuronal sprouting which resembled abnormal Purkinje cell morphology in deceased FCMTE patients.³⁹ However, in the French family a mutation in *SEMA5A* (semaphorin-5A) and *CTNND2* genes was excluded using direct sequencing.³⁶ Carr et al.¹⁰ have named their South African pedigree FAME3; however, only analysis to exclude the linkage areas 2p and 8q was performed.

FCMTE4, with linkage to 3q26.32-3q28, has recently been discovered in a Thai family.⁴³ No causative gene has yet been identified. Two candidate genes have been proposed for FCMTE4: *HTR3D* (5-hydroxytryptamine receptor 3D) and *KCNMB3* (calcium-activated

Table 5. Mutations Found in Different Pedigrees

Reference	FCMTE linkage	Origin	Gene, Chromosome	Patients/ pedigrees	Mutation	Causative?
Cen et al. ²⁷	FCMTE1	Chinese	<i>SLC30A8</i> , 8q24.11	N:2, N1	Missense, p.Y69F, c.206A>T	No expression in the brain
Felix Marri-Masso et al. ⁴⁸	FCMTE2	Spanish	<i>ACMSD</i> , 2q21.3	N:3, N:1	SNV, p.Trp26Stop, c.77G>A	Linked to PD, PME, ULD
De Fusco et al. ⁴⁶	FCMTE2	Italian	<i>ADRA2B</i> , 2q11.2	N:2, N:2	Indel, c.675_686delTTGGTGGGG	H: gain of function, altered cortical rhythmic activity
Rooselaar et al. ³⁹	FCMTE3	Dutch	<i>CTNND2</i> , 5p15	N:3, N:1	Missense, p.Glu1044Lys	Abnormal neuronal sprouting in mice
Gao et al. ⁴⁷	FCMTE#	Chinese	<i>PLA2G6</i> , 22q13.1	N:3, N1	Missense, p.Ala19Thr, c.475C > T	Linked to INAD, KS, EODP
Kato et al. ³⁹	FCMTE#	Japanese	<i>UBR5</i> , 8q22.3	N5, N1	Missense, p.Arg1907His, c.5720G>A	Linked to AS, ARJP
Russel et al. ⁴⁹	FCM#	Canada	<i>VOL3</i> , 16q22.1	N:1, N:1	Missense, c.61G>C	No giant SEP or symptoms in <i>Nov3</i> - mice

Abbreviations: ACMSD, Aminocarboxymuconate Semialdehyde Decarboxylase; ADRA2B, α2-Adrenergic Receptor Subtype B; ARJP, Autosomal Recessive Inherited Juvenile Parkinsonism; AS, Angelman Syndrome; CTNND2, Catenin Delta 2; EODP, Early Onset Dystonia Parkinsonism; FCMTE, Familial Cortical Myoclonic Tremor And Epilepsy; FCM, Familial Cortical Myoclonus; giant SEP, Giant Somatosensory Evoked Potential; H, Hypothesis; INAD, Infantile Neuroaxonal Dystrophy; KS, Karak Syndrome; N, Number; NOL3, Nucleolar Protein 3; PD, Parkinson Disease; PLA2G6, Phospholipase A2 Group 6; PME, Progressive Myoclonus Epilepsy; SLC30A8, Solute Carrier Family 30 (zinc transporter); Member 8; SNV, Single Nucleotide Variant; UBR5, Ubiquitin Protein Ligase E3 Component n-recognin 5; ULD, Unverricht-Lundborg Disease; -, Negative; #, Unknown linkage.

potassium channel subunit beta-3), which encode for ion channel receptors.²⁹

Other proposed mutations include a missense mutation on 8q22.3 in ubiquitin protein ligase E3 component n-recognin 5 (*UBR5*) within a Japanese pedigree, linked to Angelman syndrome and autosomal recessive juvenile parkinsonism.⁵⁹ In a Chinese family, a missense mutation at 22q13.1 in *PLA2G6* (phospholipase A2 Group VI) was found using WES.⁴⁷ Pathogenicity is hypothetical. *PLA2G6* mutations have also been linked to infantile neuroaxonal dystrophy and the enzyme encoded by *PLA2G6* is involved in the synthesis of arachidonic acid; abnormal metabolism of arachidonic acid could lead to neuronal hyperexcitability.⁴⁷

Genetic findings in FCMTE-like disorders. In a family from Canada with familial cortical myoclonus without seizures (a potential new disorder), linkage analysis and WES identified a missense mutation on 16q22.1 in the nucleolar protein 3 (*NOL3*) gene.⁴⁹ Pathogenicity is doubtful because *Nol3* knockout mice did not exhibit myoclonic symptoms and had normal SEPs.⁴⁹ Moreover there is an autosomal recessive form of FCMTE, caused by a single base pair deletion in *CNTN2*, crucial for the stability of potassium channels.⁴⁵

Discussion

In this systematic review we included a total of 126 FCMTE pedigrees (761 patients), including 70 additional FCMTE pedigrees (275 patients) since our 2012 review.¹ Here we discuss the diagnostic criteria, clinical spectrum, and treatment. Also, we suggest features that might relate a phenotype to a specific genotype, and focus on the pathophysiology combining neurophysiological, imaging, and pathophysiology studies, as well as on potential candidate genes.

Diagnostic criteria and clinical spectrum

The pedigrees presented in this review share the core features of FCMTE, including autosomal dominant inheritance, distal myoclonic tremor with signs of cortical reflex myoclonus, and/or generalized tonic-clonic seizures. Myoclonus is typically the first symptom, while seizures, usually occurring later in the disease course, are a common reason for patients to seek medical care. However, seizures might in a number of cases be the first symptom.⁵⁶

EEG findings in FCMTE include generalized spikes/waves and photoparoxysmal or photomyogenic responses. Other possible clinical features include mild progression of symptoms with aging,^{16,17,21,57-59} and proximal myoclonus, potentially leading to gait disorders, across linkage types or European/Asian descent.^{16,17,37,46,56-58,61,65,67} Both are not major inclusion criteria but phenomena that are frequently observed and seem to be part of the disease spectrum.

Focal EEG abnormalities and a slower posterior dominant rhythm might be features of FCMTE.^{56,74} Also, EEG may show generalized spikes and waves preceding later onset of epilepsy.⁵⁸

FCMTE is differentiated from other tremor-like disorders (including ET) with electrophysiological recordings.³² FCMTE can be differentiated from the progressive myoclonus epilepsy syndromes and

juvenile myoclonic epilepsy (JME) in the absence of severe cognitive decline and absence of severe ataxia.⁸² Unlike FCMTE, JME presents with myoclonus in the morning and shows no features of cortical reflex myoclonus.⁸²

Criteria for the diagnosis of FCMTE are the following:

- 1) Distal action and postural tremor/fine myoclonus, accompanied by generalized tonic-clonic seizures in at least one family member. Also, mild progression of symptoms with aging and proximal muscle myoclonus can be present.
- 2) Electrophysiological measures support the diagnosis: giant SEP and LLR point to cortical hyperexcitability; polymyography showing discharges of <50 ms suggest cortical myoclonus; and EEG-EMG coherence analysis or JLA can support a cortical origin of the tremulous movements.
- 3) Autosomal dominant inheritance of epilepsy and “tremor”/myoclonus within the family.
- 4) No other cause for tremor, epilepsy. No other symptoms must be present like ataxia, parkinsonism, dementia, dystonia, spasticity.

Are phenotypical differences related to specific mutations?

Differences in symptomatology have been reported, possibly linked to different mutations.¹ Japanese and Chinese pedigrees, linked to 8q (FCMTE1; also known as BAFME) suffer from a more “benign” form of FCMTE with age of onset in the third decade, infrequent seizures, and no cognitive decline.^{24,25,27} Usually, FCMTE1 patients present with rhythmic distal myoclonus of the upper extremities, but more extensive involvement of the lower extremities and facial muscles has also been reported.^{24,68,83}

Pedigrees with linkage to 2p (FCMTE2) exhibit a more severe form of myoclonus (proximal involvement) that progresses with aging and leads to gait disability.^{16,17,46} Specific for Italian 2p pedigrees, psychiatric comorbidity is frequently present.¹³ Atypical symptoms in pedigrees with a possibly pathogenic mutation were present in Spanish 2p *ACMSD* patients (n:1 parkinsonism and mild ataxia)⁴⁸ and in 2p *ADRA2B* patients (focal seizures and age-related dementia).⁴⁶

Linkage to 5p (FCMTE3) in two Chinese pedigrees is related to a benign course with age of onset in the fourth decade, and, during short-term follow-up, no disease progression.^{40,41} However, in French FCMTE3 pedigrees, progression of symptoms, gait disability, frontal syndrome, cognitive changes, and logopenic syndrome were described.^{61,67} Also, in a Dutch FCMTE3 pedigree subjective cognitive decline was present.³⁹

In a Thai pedigree, with linkage to 3q (FCMTE4), myoclonus presented earlier, in the second decade, and seizures started in the third decade.⁴³ No cognitive decline was present.⁴³

In patients with unknown linkage the following findings were reported: clinical anticipation was present in Asian pedigrees (measured with rating scales).¹⁹⁻²¹ Mild cognitive decline was present in Asian patients.^{21,57} European patients (or with European ancestors) suffered from mild cognitive decline,^{8-12,17,39,47,48} focal seizures,^{16,46} mild ataxia and/or gait instability,^{16,17,37,38,48} nystagmus,¹⁴ dysarthria,^{10,38}

and migraine.^{15–18} Atypical features were also described in a Turkish family, including absence seizures, early onset of seizures (14–17 years), negative LLR (while using AEDs), and frequent myoclonic seizures (once a month).¹⁸

There are a number of possible explanations for the reported phenotypical differences between pedigrees/FCMTE types. Firstly, different mutations, extensively described in a limited number of pedigrees, could lead to clinical diversity.^{39,46–48,59} For instance, more severe disease course,^{17,36} cognitive decline,⁶⁷ and/or the pathological/neuroimaging changes in the cerebellum^{1,51,53} might be related to specific FCMTE mutations. Secondly, the clinical differences could be co-incident or based on comorbidity, either related or unrelated to FCMTE. Other possible explanations might be differences in genetic trait other than FCMTE; heterogenic prescription regimes, including AED use per country, or environmental factors. A third explanation is reporting bias. Documentation, investigations, and follow-up differ substantially between pedigrees.

Pathophysiology

The primary symptoms of FCMTE, cortical myoclonus, and epilepsy seem to have their origin in the sensorimotor cortex. Electrophysiology findings indicate cortical hyperexcitability with generalized spikes and waves on EEG, giant SEP, LLR, and reduced cortical inhibition in TMS studies^{9,14,78} and cortical activity preceding the onset of movement (EEG-EMG back averaging and coherence analysis), confirmed with combined EMG/fMRI.^{72,77,84}

Cerebellar changes might be a key feature of FCMTE. Pathology findings in three Dutch patients^{1,14,50} and one South African patient¹⁰ report severe loss of Purkinje cells with dendritic sprouts, neuronal loss in the dentate nucleus and microglia activation with limited changes in the sensorimotor cortex. Use of AEDs might result in loss of Purkinje cells. Notwithstanding, cerebellar pathology findings in FCMTE patients differ from changes seen in patients with chronic idiopathic epilepsy who used phenytoin⁸⁵ and rats chronically exposed to valproic acid.⁸⁶ Also, Dutch patients who did not use AEDs had a downbeat nystagmus upon hyperventilation, indicating cerebellar dysfunction.¹⁴ Moreover, a mutation in *CTNND2* was found in the same Dutch pedigree, probably related to FCMTE3, as the gene *CTNND2* is located on the same linkage area.³⁹ A mutant version of this gene was responsible for abnormal neuronal sprouting in mouse neurons, resembling cerebellar pathology findings in the same Dutch pedigree.³⁹ In a French FCMTE3 pedigree a mutation in *CTNND2* was excluded using direct sequencing.³⁷ It could be there are several mutations located on the same linkage area or the mutation was undetectable due to the technique used.

Pathological cerebellar involvement is in line with cerebellar signs in European FCMTE pedigrees; these include downbeat nystagmus,¹⁴ mild ataxia (although possibly difficult to judge in the presence of tremulous myoclonus),^{37,38} dysarthria,^{10,38} and imaging findings revealing cerebellar involvement.^{51,53,79}

Further evidence for cerebellar involvement in FCMTE arises from imaging studies in FCMTE, indicating functional connectivity changes

between the cerebellum and cortical/subcortical structures.⁵² Supratentorial gray matter loss outside the motor circuit might be secondary.⁷⁰ Also, cerebellar atrophy and ataxia have frequently been noted in patients with epilepsy.⁸⁷ Repetitive TMS over the cerebellar cortex was able to reduce seizure frequency in drug-resistant epilepsy.^{87,88} The cerebellum might be involved in psychiatric disorders.⁸⁹ In several FCMTE pedigrees anxiety and depressive comorbidity was reported.^{13,56} With aging, Purkinje cells become atrophic in healthy adults and the amount of white matter is reduced in the cerebellum.⁹⁰ The degeneration of Purkinje cells might be enhanced in FCMTE patients leading to defective compensatory input to cortical structures. Clinically, this could explain the later onset of seizures and the worsening of symptoms with aging.¹⁶ Moreover, cortical hyperexcitability seems to increase with aging in Japanese patients, reflected by higher giant SEP amplitude.⁷³

Pathology, imaging, genetic, and clinical findings indicate cerebellar changes. This offers a possible explanation for the decreased cortical inhibition. Deficient stimulation of the dentate nucleus by Purkinje cells in the cerebellum may lead to increased cortical facilitation via the cerebello-thalamo-cortical loop, a hypothesis already raised for cortical myoclonus and epilepsy.^{54,87,91} Purkinje cell changes might however not be the (sole) explanation for the symptoms observed in FCMTE.

The cerebellar changes might be specific for certain FCMTE types, with the strongest evidence for FCMTE3. Future research is needed to indicate whether cerebellar involvement, including pathological cerebellar changes, is a general finding in FCMTE. In some FCMTE types it might be co-existent, secondary due to primary cortical pathology, or even absent.

Possible candidate genes

Possible candidate causative genes include a trinucleotide repeat expansion or channelopathy.⁸⁰ Purkinje cell changes in deceased Dutch FCMTE patients show striking similarities with those found in spinocerebellar ataxia (SCA) type 6, characterized by ataxia and downbeat nystagmus.^{1,50} Patients from the same Dutch FCMTE pedigree also have a downbeat nystagmus.¹⁴ SCA type 6 is caused by a CAG repeat in a calcium channel *CACNA1A* heavily expressed in the cerebellum.⁹² Other observations that might also point to a trinucleotide repeat expansion or channelopathy underlying FCMTE include in Asian FCMTE pedigrees, progressively earlier onset of the disease with increasing severity in successive generations^{19–21}; presence of migraine^{15–18} analogues to hemiplegic migraine with mutations in calcium channels⁹³; and the recognition that certain epilepsy syndromes are channelopathies.^{45,94} Recently, an autosomal recessive form of FCMTE has been recognized with a single base pair deletion in *CNTN2*, crucial for the stability of potassium channels.⁴⁵ A channelopathy could involve cerebellar cells and/or induce functional cortical changes.^{50,92}

Several genes have been identified as potentially causative in FCMTE. A gain of function mutation in the *ADRA2B* gene has been found in Italian FCMTE2 pedigrees that could potentially alter the neuronal firing pattern and even reduce gamma-aminobutyric acid

(GABA) neurotransmission.⁴⁶ A reduction in cortical GABA neurotransmission has been associated with cortical myoclonus in rats, progressive myoclonus epilepsy and Unverricht–Lundborg disease characterized by cortical myoclonus and ataxia along with seizures.⁹¹ Treatment with AEDs increasing GABA neurotransmitter levels can relieve the symptoms of FCMTE.

Another neurotransmitter implied in the pathophysiology of FCMTE2 is serotonin.⁴⁸ A mutation in the *ACMSD* gene, encoding for an enzyme that is part of the kynurenine pathway, might lead to the accumulation of waste products.⁴⁸ In mice, seizures could be induced when injecting these kynurenines in the brain ventricles.⁹⁵

In Dutch FCMTE3 patients, a mutation in *CTNND2*, supported by functional tests in mice, seems to be responsible for abnormal neuronal sprouting.³⁹ Hypothetically, the pathology findings in the cerebellum and the disease itself are caused by the *CTNND2* mutation.³⁹

Other proposed mutations/linkage studies have not yet elucidated the pathophysiology of FCMTE and have provided conflicting results, including proposed mutations outside the known linkage areas (*UBR5*, *PLA2G6*)^{47,59} and a pedigree from Canada (*NOL3* mutation)⁴⁹ without seizures, possibly reflecting another illness. The lack of progress might be due to the inability of next-generation sequencing techniques to detect exon rearrangements, trinucleotide repeat expansion, and copy number variants.⁸⁰ Even a deletion in an intron might lead to defective splicing of a gene as in Unverricht–Lundborg disease.⁹⁶ New algorithms and WGS might lead to a breakthrough.^{97,98}

Future genetic studies should focus on mutations in proteins expressed in the cerebellum, involved in neuronal outgrowth, calcium, sodium, or potassium signaling, GABA neurotransmission, and genes which interact with the SCAs or other diseases with cortical myoclonic symptoms.⁸⁰

Limitations

Reporting bias may have influenced our results. The number of patients and follow-up differ between pedigrees. Across studies, rating scales for motor symptoms and cognitive functioning differ or have not been reported. Therefore, symptoms might have been underreported, for instance cerebellar dysfunction and cognitive deterioration in certain pedigrees.¹⁴ Additional investigations (MRI, electrophysiology, pathology) have not always been performed, in some cases leading to diagnostic uncertainty, but more often raising questions with respect to generalizability of findings across pedigrees. For instance, both the imaging and the pathology findings involving cerebellar changes have largely been confined to a South African patient (linkage exclusion 2p, 8q), a Dutch pedigree (FCMTE3), and Chinese patients (linkage exclusion 2p, 8q) making the generalizability of the findings problematic.^{10,39,51–53,65,70} Several mutations (*ACMSD*, *ADRA2B*, *UBR5*, *PLA2G6*) have been proposed but pathogenicity has still to be proven.^{46–48,59}

Conclusion

FCMTE, also known under different names and acronyms, is a clinical entity not (yet) listed by the ILAE. It is characterized by cortical tremor/fine myoclonus and generalized tonic–clonic seizures

with autosomal dominant inheritance. Proximal myoclonus and mild progression with aging are part of the spectrum. Electrophysiology recordings show features of cortical reflex myoclonus. Valproate (not recommended in women of childbearing age) or levetiracetam, with or without clonazepam reduce symptoms. Gabapentin should be prescribed cautiously.

FCMTE is a heterogeneous disorder, and is likely to include a variety of different conditions with mutations of different genes. Additional symptoms have frequently been reported and can be co-incident or based on genetic differences. Pathophysiological mechanisms remain to be elucidated, but pathology, genetic, and imaging studies have given clues that indicate cerebellar involvement. The cerebellar changes might lead to reduced cortical inhibition. Alternatively, underlying genetic changes induce both cerebellar and cortical changes. Genetic heterogeneity is present in linkage studies. Several causative genes have been suggested. However, functional tests have not always been performed.

Pathophysiology and genetic studies indicate that future genetic studies should focus on mutations involving Purkinje cell outgrowth, channelopathies, or genes responsible for neurotransmitter synthesis.

Appendix A

PubMed search

Conducted on 15-11-2017, articles were sought from 01-01-2011 to 15-11-2017.

(((((cortical tremor myoclonus) OR cortical tremor epilepsy) OR (((("Tremor"[Mesh]) AND "Myoclonus"[Mesh]) AND "Epilepsy"[Mesh])) OR ((cortical tremor [tiab] AND epilepsy [tiab] AND myoclonus [tiab]))) OR (((((((("Epilepsy, Myoclonic, Benign Adult Familial, Type 1"[Supplementary Concept]) OR ("Tremor"[Mesh] AND "Epilepsy"[Mesh]) OR ("Tremor"[Mesh] AND "Myoclonus"[Mesh]) OR ("Epilepsy"[Mesh] AND "Myoclonus"[Mesh]) OR (autosomal dominant [tiab] AND "Epilepsy"[Mesh]) AND "Myoclonus"[Mesh])) OR (autosomal dominant [tiab] AND "Tremor"[Mesh] AND "Myoclonus"[Mesh])) OR (familial [tiab] AND "Epilepsy"[Mesh] AND "Myoclonus"[Mesh])) OR (familial [tiab] AND "Tremor"[Mesh] AND "Myoclonus"[Mesh])) OR (benign course [tiab] AND "Epilepsy"[Mesh] OR benign course [tiab] AND epilepsy [tiab])) OR ("Tremor"[Mesh] AND "Myoclonus"[Mesh] OR tremor [tiab] AND myoclonus [tiab] OR epilepsy [tiab] AND myoclonus [tiab]))) OR (Autosomal dominant cortical myoclonus and epilepsy OR Benign adult familial myoclonic epilepsy OR Cortical tremor OR Familial adult myoclonic epilepsy OR Familial cortical myoclonic tremor OR Familial cortical myoclonic tremor with epilepsy OR Familial cortical tremor with epilepsy OR Familial essential myoclonus and epilepsy OR Familial benign myoclonus epilepsy of adult onset OR Heredo-familial tremor and epilepsy).

References

- Sharifi S, Aronica E, Koelman JH, Tijssen MA, Van Rootselaar AF. Familial cortical myoclonic tremor with epilepsy and cerebellar changes:

description of a new pathology case and review of the literature. *Tremor Other Hyperkinet Mov* 2012;2. doi: 10.7916/D8ST7NKK

2. van Rootselaar AF, van Schaik IN, van den Maagdenberg AM, Koelman JH, Callenbach PM, Tijssen MA. Familial cortical myoclonic tremor with epilepsy: a single syndromic classification for a group of pedigrees bearing common features. *Mov Disord* 2005;20:665–673. doi: 10.1002/mds.20413

3. HGNC Database, HUGO Gene Nomenclature Committee (HGNC), EMBL Outstation - Hinxton, European Bioinformatics Institute, Wellcome Trust Genome Campus. www.genenames.org. Accessed December 12, 2017.

4. Yasuda T, Benign adult familial myoclonic epilepsy (BAFME). *Kawasaki Med J* 1991;17:1–13. doi: 10.11482/KMJ-E17

5. Inazuki G, Naito H, Ohama E, Kawase Y, Honma Y, Tokiguchi S, et al. [A clinical study and neuropathological findings of a familial disease with myoclonus and epilepsy—the nosological place of familial essential myoclonus and epilepsy (FEME)]. *Seishin Shinkeigaku Zasshi* 1990;92:1–21.

6. Ikeda A, Kakigi R, Funai N, Neshige R, Kuroda Y, Shibasaki H. Cortical tremor: a variant of cortical reflex myoclonus. *Neurology* 1990;40:1561–1565. doi: 10.1212/WNL.40.10.1561

7. Kudo J, Kudo T, Yamauchi T. [Seven families with hereditary tremor and epilepsy]. *Rinsho Shinkeigaku* 1984;24:1–8.

8. Guerrini R, Bonanni P, Patrignani A, Brown P, Parmeggiani L, Grosse P, et al. Autosomal dominant cortical myoclonus and epilepsy (ADCME) with complex partial and generalized seizures: A newly recognized epilepsy syndrome with linkage to chromosome 2p11.1-q12.2. *Brain* 2001;124(Pt 12): 2459–2475. doi: 10.1093/brain/124.12.2459

9. Suppa A, Berardelli A, Brancati F, Marianetti M, Barrano G, Mina C, et al. Clinical, neuropsychological, neurophysiologic, and genetic features of a new Italian pedigree with familial cortical myoclonic tremor with epilepsy. *Epilepsia* 2009;50:1284–1288. doi: 10.1111/j.1528-1167.2008.01976.x

10. Carr JA, van der Walt PE, Nakayama J, Fu YH, Corfield V, Brink P, et al. FAME 3: a novel form of progressive myoclonus and epilepsy. *Neurology* 2007;68:1382–1389. doi: 10.1212/01.wnl.0000260063.46425.7e

11. van Rootselaar F, Callenbach PM, Hottenga JJ, VermeulenHans FLM, SpeelmanOebele HD, Brouwer OF, et al. A Dutch family with ‘familial cortical tremor with epilepsy’. Clinical characteristics and exclusion of linkage to chromosome 8q23.3-q24.1. *J Neurol* 2002;249:829–834. doi: 10.1007/s00415-002-0729-x

12. Elia M, Musumeci SA, Ferri R, Scuderi C, Gracco SD, Bottitta M, et al. Familial cortical tremor, epilepsy, and mental retardation: a distinct clinical entity? *Arch Neurol* 1998;55:1569–1573. doi: 10.1001/archneur.55.12.1569

13. Coppola A, Caccavale C, Santulli L, Balestrini S, Cagnetti C, Licchetta L, et al. Psychiatric comorbidities in patients from seven families with autosomal dominant cortical tremor, myoclonus, and epilepsy. *Epilepsy Behav* 2016;56: 38–43. doi: 10.1016/j.yebeh.2015.12.038

14. van Rootselaar AF, van der Salm SM, Bour LJ, Edwards MJ, Brown P, Aronica E, et al. Decreased cortical inhibition and yet cerebellar pathology in ‘familial cortical myoclonic tremor with epilepsy’. *Mov Disord* 2007;22:2378–2385. doi: 10.1002/mds.21738

15. Saka E, Saygi S. Familial adult onset myoclonic epilepsy associated with migraine. *Seizure* 2000;9:344–346. doi: 10.1053/seiz.2000.0402

16. Crompton DE, Sadleir LG, Bromhead CJ, Bahlo M, Bellows ST, Arsov T, et al. Familial adult myoclonic epilepsy: recognition of mild phenotypes and

refinement of the 2q locus. *Arch Neurol* 2012;69:474–481. doi: 10.1001/archneurol.2011.584

17. Licchetta L, Pippucci T, Bisulli F, Cantalupo G, Magini P, Alvisi L, et al. A novel pedigree with familial cortical myoclonic tremor and epilepsy (FCMTE): clinical characterization, refinement of the FCMTE2 locus, and confirmation of a founder haplotype. *Epilepsia* 2013;54:1298–1306. doi: 10.1111/epi.12216

18. Aydin Ozemir Z, Oguz Akarsu E, Matur Z, Oge AE, Baykan B. Autosomal dominant cortical tremor, myoclonus, and epilepsy syndrome mimicking juvenile myoclonic epilepsy. *Noro Psikiyatrs Ars* 2016;53:272–275. doi: 10.5152/npa.2016.14841

19. Hitomi T, Kondo T, Kobayashi K, Matsumoto R, Takahashi R, Ikeda A. Clinical anticipation in Japanese families of benign adult familial myoclonus epilepsy. *Epilepsia* 2012;53:e33–36. doi: 10.1111/j.1528-1167.2011.03349.x

20. Hitomi T, Kobayashi K, Jingami N, Nakagawa T, Imamura H, Matsumoto R, et al. Increased clinical anticipation with maternal transmission in benign adult familial myoclonus epilepsy in Japan. *Epileptic Disord* 2013;15: 428–432. doi: 10.1684/epd.2013.0608

21. Cen Z, Huang C, Yin H, Ding X, Xie F, Lu X, et al. Clinical and neurophysiological features of familial cortical myoclonic tremor with epilepsy. *Mov Disord* 2016;31:1704–1710. doi: 10.1002/mds.26756

22. Online Mendelian Inheritance in Man, OMIM®. Johns Hopkins University, Baltimore, MD. MIM number {601068}: {08/03/2017}. https://omim.org/

23. HGNC Database, HUGO Gene Nomenclature Committee (HGNC), EMBL Outstation - Hinxton, European Bioinformatics Institute, Wellcome Trust Genome Campus. www.genenames.org. Accessed May 13, 2017.

24. Mikami M, Yasuda T, Terao A, Nakamura M, Ueno S, Tanabe H, et al. Localization of a gene for benign adult familial myoclonic epilepsy to chromosome 8q23.3-q24.1. *Am J Hum Genet* 1999;65:745–751. doi: 10.1086/302535

25. Plaster NM, Uyama E, Uchino M, Ikeda T, Flanigan KM, Kondo I, et al. Genetic localization of the familial adult myoclonic epilepsy (FAME) gene to chromosome 8q24. *Neurology* 1999;53:1180–1183. doi: 10.1212/WNL.53.6.1180

26. Mori S, Nakamura M, Yasuda T, Ueno S, Kaneko S, Sano A. Remapping and mutation analysis of benign adult familial myoclonic epilepsy in a Japanese pedigree. *J Hum Genet* 2011;56:742–747. doi: 10.1038/jhg.2011.93

27. Cen ZD, Xie F, Lou DN, Lu XJ, Ouyang ZY, Liu L, et al. Fine mapping and whole-exome sequencing of a familial cortical myoclonic tremor with epilepsy family. *Am J Med Genet B Neuropsychiatr Genet* 2015;168:595–599. doi: 10.1002/ajmg.b.32337

28. Online Mendelian Inheritance in Man, OMIM®. Johns Hopkins University, Baltimore, MD. MIM number: {607876}: {07/03/2017}. https://omim.org/

29. Henden L, Freytag S, Afawi Z, Baldassari S, Berkovic SF, Bisulli F, et al. Identity by descent fine mapping of familial adult myoclonus epilepsy (FAME) to 2p11.2-2q11.2. *Hum Genet* 2016;135:1117–1125. doi: 10.1007/s00439-016-1700-8

30. de Falco FA, Striano P, de Falco A, Striano S, Santangelo R, Perretti A, et al. Benign adult familial myoclonic epilepsy: genetic heterogeneity and

allelism with ADCME. *Neurology* 2003;60:1381–1385. doi: 10.1212/01.WNL.0000055874.24000.4A

31. Madia F, Striano P, Di Bonaventura C, de Falco A, de Falco FA, Manfredi M, et al. Benign adult familial myoclonic epilepsy (BAFME): evidence of an extended founder haplotype on chromosome 2p11.1-q12.2 in five Italian families. *Neurogenetics* 2008;9:139–142. doi: 10.1007/s10048-008-0118-4

32. Striano P, Chifari R, Striano S, De Fusco M, Elia M, Guerrini R, et al. A new benign adult familial myoclonic epilepsy (BAFME) pedigree suggesting linkage to chromosome 2p11.1-q12.2. *Epilepsia* 2004;45:190–192. doi: 10.1111/j.0013-9580.2004.39903.x

33. Striano P, Madia F, Minetti C, Striano S, Zara F. Electroclinical and genetic findings in a family with cortical tremor, myoclonus, and epilepsy. *Epilepsia* 2005;46:1993–1995. doi: 10.1111/j.1528-1167.2005.00346.x

34. Saint-Martin C, Bouteiller D, Stevanin G, Popescu C, Charon C, Ruberg M, et al. Refinement of the 2p11.1-q12.2 locus responsible for cortical tremor associated with epilepsy and exclusion of candidate genes. *Neurogenetics* 2008;9:69–71. doi: 10.1007/s10048-007-0107-z

35. Online Mendelian Inheritance in Man, OMIM®. Johns Hopkins University, Baltimore, MD. MIM number: {613608}: {10/26/2010}. <https://omim.org/>

36. Depienne C, Magnin E, Bouteiller D, Stevanin G, Saint-Martin C, Vidailhet M, et al. Familial cortical myoclonic tremor with epilepsy: the third locus (FCMTE3) maps to 5p. *Neurology* 2010;74:2000–2003. doi: 10.1212/WNL.0b013e3181e396a8

37. Magnin E, Vidailhet M, Depienne C, Saint-Martin C, Bouteiller D, LeGuern E, et al. Familial cortical myoclonic tremor with epilepsy (FCMTE): Clinical characteristics and exclusion of linkages to 8q and 2p in a large French family. *Rev Neurol (Paris)* 2009;165:812–820. doi: 10.1016/j.neurol.2009.05.014

38. Bourdain F, Apartis E, Trocello JM, Vidal JS, Masnou P, Vercueil L, et al. Clinical analysis in familial cortical myoclonic tremor allows differential diagnosis with essential tremor. *Mov Disord* 2006;21:599–608. doi: 10.1002/mds.20725

39. van Rootselaar AF, Groffen AJ, de Vries B, Callenbach PMC, Santen GWE, Koelewijn S, et al. delta-Catenin (CTNND2) missense mutation in familial cortical myoclonic tremor and epilepsy. *Neurology* 2017;89:2341–2350. doi: 10.1212/WNL.0000000000004709

40. Liu C, Sun W, Chen Q, Li J, Hu G. Genetic analysis of a Chinese family provides further evidence for linkage of familial cortical myoclonic tremor with epilepsy to 5p15.31-p15. *Neurol India* 2015;63:215–219. doi: 10.4103/0028-3886.156283

41. Li J, Hu X, Chen Q, Zhang Y, Zhang Y, Hu G. A Chinese benign adult familial myoclonic epilepsy pedigree suggesting linkage to chromosome 5p15.31-p15.1. *Cell Biochem Biophys* 2014;69:627–631. doi: 10.1007/s12013-014-9843-5

42. Online Mendelian Inheritance in Man, OMIM®. Johns Hopkins University, Baltimore, MD. MIM number: {615127}: {08/02/2017}. <https://omim.org/>

43. Yeetong P, Ausavarat S, Bhidayasiri R, Piravej K, Pasutharnchat N, Desudchit T, et al. A newly identified locus for benign adult familial myoclonic epilepsy on chromosome 3q26.32-3q28. *Eur J Hum Genet* 2013;21:225–228. doi: 10.1038/ejhg.2012.133

44. Online Mendelian Inheritance in Man, OMIM®. Johns Hopkins University, Baltimore, MD. MIM number: {615400}: {08/14/2017}. <https://omim.org/>

45. Stogmann E, Reinthaler E, Eltawil S, Etribi MAE, Hemeda M, Nahhas NE, et al. Autosomal recessive cortical myoclonic tremor and epilepsy: association with a mutation in the potassium channel associated gene CNTN2. *Brain* 2013;136:1155–1160. doi: 10.1093/brain/awt068

46. De Fusco M, Vago R, Striano P, Di Bonaventura C, Zara F, Mei D, et al. The alpha2B-adrenergic receptor is mutant in cortical myoclonus and epilepsy. *Ann Neurol* 2014;75:77–87. doi: 10.1002/ana.24028

47. Gao L, Li L, Ye J, Zhu X, Shen N, Zhang X, et al. Identification of a novel mutation in PLA2G6 gene in a Chinese pedigree with familial cortical myoclonic tremor with epilepsy. *Seizure* 2016;41:81–85. doi: 10.1016/j.seizure.2016.07.013

48. Marti-Masso JF, Bergareche A, Makarov V, Ruiz-Martinez J, Gorostidi A, de Munain AL, et al. The ACMSD gene, involved in tryptophan metabolism, is mutated in a family with cortical myoclonus, epilepsy, and parkinsonism. *J Mol Med (Berl)* 2013;91:1399–1406.

49. Russell JF, Steckley JL, Coppola G, Hahn AFG, Howard MA, Kornberg Z, et al. Familial cortical myoclonus with a mutation in NOL3. *Ann Neurol* 2012;72:175–183. doi: 10.1002/ana.23666

50. van Rootselaar AF, Aronica E, Jansen Steur EN, Rozemuller-Kwakkel JM, de Vos RA, Tijssen MA. Familial cortical tremor with epilepsy and cerebellar pathological findings. *Mov Disord* 2004;19:213–217. doi: 10.1002/mds.10662

51. Buijink AW, Caan MW, Tijssen MA, Hoogduin JM, Maurits NM, van Rootselaar AF. Decreased cerebellar fiber density in cortical myoclonic tremor but not in essential tremor. *Cerebellum*. 2013;12:199–204.

52. Long L, Zeng LL, Song Y, Shen H, Fang P, Zhang L, et al. Altered cerebellar-cerebral functional connectivity in benign adult familial myoclonic epilepsy. *Epilepsia* 2016;57:941–948. doi: 10.1111/epi.13372

53. Buijink AW, Broersma M, van der Stouwe AM, Sharifi S, Tijssen MAJ, Speelman JD, et al. Cerebellar atrophy in cortical myoclonic tremor and not in hereditary essential tremor—a voxel-based morphometry study. *Cerebellum* 2016;15:696–704. doi: 10.1007/s12311-015-0734-0

54. Striano P, Louis ED, Manto M. Autosomal dominant cortical tremor, myoclonus, and epilepsy: is the origin in the cerebellum? Editorial. *Cerebellum* 2013;12:145–146. doi: 10.1007/s12311-012-0419-x

55. Wang P, Luo C, Dong L, Bin Y, Ma S, Yao D, et al. Altered intrinsic brain activity in patients with familial cortical myoclonic tremor and epilepsy: an amplitude of low-frequency fluctuation study. *J Neurol Sci* 2015;351:133–139. doi: 10.1016/j.jns.2015.03.005

56. Mahadevan R, Viswanathan N, Shanmugam G, Sankaralingam S, Essaki B, Chelladurai RP. Autosomal dominant cortical tremor, myoclonus, and epilepsy (ADCME) in a unique south Indian community. *Epilepsia* 2016;57:e56–59. doi: 10.1111/epi.13303

57. Sharma CM, Nath K, Kumawat BL, Khandelwal D. Autosomal dominant cortical tremor, myoclonus, and epilepsy (ADCME): Probable first family from India. *Ann Indian Acad Neurol* 2014;17:433–436. doi: 10.4103/0972-2327.144025

58. van Coller R, van Rootselaar AF, Schutte C, van der Meyden CH. Familial cortical myoclonic tremor and epilepsy: description of a new South

- African pedigree with 30 year follow up. *Parkinsonism Relat Disord* 2017;38:35–40. doi: 10.1016/j.parkreldis.2017.02.016
59. Kato T, Tamiya G, Koyama S, Nakamura T, Makino S, Arawaka S, et al. UBR5 Gene mutation is associated with familial adult myoclonic epilepsy in a Japanese family. *ISRN Neurol* 2012;2012:508308. doi: 10.5402/2012/508308
60. Toyota T, Akamatsu N, Tanaka A, Tsuji S, Uozumi T. Electroencephalographic features of benign adult familial myoclonic epilepsy. *Clin Neurophysiol* 2014;125:250–254. doi: 10.1016/j.clinph.2013.08.002
61. Magnin E, Vidailhet M, Ryff I, Ferreira S, Labauge P, Rumbach L. Fronto-striatal dysfunction in type 3 familial cortical myoclonic tremor epilepsy occurring during aging. *J Neurol* 2012;259:2714–2719. doi: 10.1007/s00415-012-6575-6
62. Gardella E, Tinuper P, Marini C, Guerrini R, Parrini E, Bisulli F, et al. Autosomal dominant early-onset cortical myoclonus, photic-induced myoclonus, and epilepsy in a large pedigree. *Epilepsia* 2006;47:1643–1649. doi: 10.1111/j.1528-1167.2006.00636.x
63. Coppola A, Santulli L, Del Gaudio L, Minetti C, Striano S, Zara F, et al. Natural history and long-term evolution in families with autosomal dominant cortical tremor, myoclonus, and epilepsy. *Epilepsia* 2011;52:1245–1250. doi: 10.1111/j.1528-1167.2011.03017.x
64. Fisher RS, Cross JH, French JA, Higurashi N, Hirsch E, Jansen FE, et al. Operational classification of seizure types by the International League Against Epilepsy: position paper of the ILAE Commission for Classification and Terminology. *Epilepsia* 2017;58:522–530. doi: 10.1111/epi.13670
65. Long L, Song Y, Zhang L, Hu C, Gong J, Xu L, et al. A case-control proton magnetic resonance spectroscopy study confirms cerebellar dysfunction in benign adult familial myoclonic epilepsy. *Neuropsychiatr Dis Treat* 2015;11:485–491. doi: 10.2147/NDT.S77910
66. Deng FY, Gong J, Zhang YC, Wang K, Xiao SM, Lia YN, et al. Absence of linkage to 8q23.3-q24.1 and 2p11.1-q12.2 in a new BAFME pedigree in China: indication of a third locus for BAFME. *Epilepsy Res* 2005;65:147–152. doi: 10.1016/j.eplepsyres.2005.05.006
67. Magnin E. Logopenic syndrome and corticobasal dysfunction in a “benign” type 3 familial cortical myoclonic tremor with epilepsy. *Seizure* 2015; 25:84–86. doi: 10.1016/j.seizure.2015.01.004
68. Manabe Y, Narai H, Warita H, Hayashi T, Shiro Y, Sakai K, et al. Benign adult familial myoclonic epilepsy (BAFME) with night blindness. *Seizure* 2002;11:266–268. doi: 10.1053/seiz.2001.0606
69. Morita S, Miwa H, Kondo T. [A case of the familial essential myoclonus and epilepsy presenting behavioral arrest]. *No To Shinkei* 2003;55:345–348.
70. Zeng LL, Long L, Shen H, Fang P, Song Y, Zhang L, et al. Gray matter loss and related functional connectivity alterations in a Chinese family with benign adult familial myoclonic epilepsy. *Medicine (Baltimore)* 2015;94:e1767. doi: 10.1097/MD.0000000000001767
71. Kojovic M, Cordivari C, Bhatia K. Myoclonic disorders: a practical approach for diagnosis and treatment. *Ther Adv Neurol Disord* 2011;4:47–62. doi: 10.1177/1756285610395653
72. van Rootselaar AF, Maurits NM, Koelman JH, van der Hoeven JH, Bour LJ, Leenders KL, et al. Coherence analysis differentiates between cortical myoclonic tremor and essential tremor. *Mov Disord* 2006;21:215–222. doi: 10.1002/mds.20703
73. Hitomi T, Ikeda A, Kondo T, Imamura H, Inouchi M, Matsumoto R, et al. Increased cortical hyperexcitability and exaggerated myoclonus with aging in benign adult familial myoclonus epilepsy. *Mov Disord* 2011;26:1509–1514. doi: 10.1002/mds.23653
74. Hitomi T, Kobayashi K, Sakurai T, Ueda S, Jingami N, Kanazawa K, et al. Benign adult familial myoclonus epilepsy is a progressive disorder: no longer idiopathic generalized epilepsy. *Epileptic Disord* 2016;18:67–72. doi: 10.1684/epd.2016.0807
75. Striano P, Manganelli F, Boccella P, Perretti A, Striano S. Levitiracetam in patients with cortical myoclonus: a clinical and electrophysiological study. *Mov Disord* 2005;20:1610–1614. doi: 10.1002/mds.20530
76. Striano P, Coppola A, Madia F, Pezzella M, Zara F, Striano S. Life-threatening status epilepticus following gabapentin administration in a patient with benign adult familial myoclonic epilepsy. *Epilepsia* 2007;48:1995–1998. doi: 10.1111/j.1528-1167.2007.01198.x
77. van Rootselaar AF, Maurits NM, Renken R, Koelman JHTM, Hoogduin JM, Leenders KL, et al. Simultaneous EMG-functional MRI recordings can directly relate hyperkinetic movements to brain activity. *Hum Brain Mapp* 2008;29:1430–1441. doi: 10.1002/hbm.20477
78. Nakatani-Enomoto S, Hanajima R, Hamada M, Terao Y, Matsumoto H, Shirota Y, et al. Somatosensory-evoked potential modulation by quadri-pulse transcranial magnetic stimulation in patients with benign myoclonus epilepsy. *Clin Neurophysiol* 2016;127:1560–1567. doi: 10.1016/j.clinph.2015.07.029
79. Striano P, Caranci F, Di Benedetto R, Tortora F, Zara F, Striano S. (1)H-MR spectroscopy indicates prominent cerebellar dysfunction in benign adult familial myoclonic epilepsy. *Epilepsia* 2009;50:1491–1497. doi: 10.1111/j.1528-1167.2008.01900.x
80. Cen ZD, Xie F, Xiao JF, Luo W. Rational search for genes in familial cortical myoclonic tremor with epilepsy, clues from recent advances. *Seizure* 2016;34:83–89. doi: 10.1016/j.seizure.2015.12.004
81. Labauge P, Amer LO, Simonetta-Moreau M, Attané F, Tannier C, Clanet M, et al. Absence of linkage to 8q24 in a European family with familial adult myoclonic epilepsy (FAME). *Neurology* 2002;58:941–944. doi: 10.1212/WNL.58.6.941
82. Striano P, Zara F. Autosomal dominant cortical tremor, myoclonus and epilepsy. *Epileptic Disord* 2016;18(S2):139–144. doi: 10.1684/epd.2016.0860
83. Okino S. Familial benign myoclonus epilepsy of adult onset: a previously unrecognized myoclonic disorder. *J Neurol Sci* 1997;145:113–118. doi: 10.1016/S0022-510X(96)00245-6
84. van Rootselaar AF, Renken R, de Jong BM, Hoogduin JM, Tijssen MA, Maurits NM. fMRI analysis for motor paradigms using EMG-based designs: a validation study. *Hum Brain Mapp* 2007;28:1117–1127. doi: 10.1002/hbm.20336
85. Crooks R, Mitchell T, Thom M. Patterns of cerebellar atrophy in patients with chronic epilepsy: a quantitative neuropathological study. *Epilepsy Res* 2000;41:63–73. doi: 10.1016/S0920-1211(00)00133-9
86. Sobaniec-Lotowska ME. Ultrastructure of Purkinje cell perikarya and their dendritic processes in the rat cerebellar cortex in experimental encephalopathy induced by chronic application of valproate. *Int J Exp Pathol* 2001;82:337–348. doi: 10.1046/j.1365-2613.2001.00206.x

87. Marcian V, Filip P, Bares M, Brazdil M. cerebellar dysfunction and ataxia in patients with epilepsy: coincidence, consequence, or cause? *Tremor Other Hyperkinet Mov* 2016;6. doi: 10.7916/D8KH0NBT
88. Brighina F, Daniele O, Piazza A, Giglia G, Fierro B. Hemispheric cerebellar rTMS to treat drug-resistant epilepsy: case reports. *Neurosci Lett* 2006; 397:229–233. doi: 10.1016/j.neulet.2005.12.050
89. Phillips JR, Hewedi DH, Eissa AM, Moustafa AA. The cerebellum and psychiatric disorders. *Front Public Health* 2015;3:66. doi: 10.3389/fpubh.2015.00066
90. Andersen BB, Gundersen HJ, Pakkenberg B. Aging of the human cerebellum: a stereological study. *J Comp Neurol* 2003;466:356–365. doi: 10.1002/ene.10884
91. Ganos C, Kassavetis P, Erro R, Edwards MJ, Rothwell J, Bhatia KP. The role of the cerebellum in the pathogenesis of cortical myoclonus. *Mov Disord* 2014;29:437–443. doi: 10.1002/mds.25867
92. Zhuchenko O, Bailey J, Bonnen P, Ashizawa T, Stockton DW, Amos C, et al. Autosomal dominant cerebellar ataxia (SCA6) associated with small polyglutamine expansions in the alpha 1A-voltage-dependent calcium channel. *Nat Genet* 1997;15:62–69. doi: 10.1038/ng0197-62
93. Huang Y, Xiao H, Qin X, Nong Y, Zou D, Wu Y. The genetic relationship between epilepsy and hemiplegic migraine. *Neuropsychiatr Dis Treat* 2017;13:1175–1179. doi: 10.2147/NDT.S132451
94. Lascano AM, Korff CM, Picard F. Seizures and epilepsies due to channelopathies and neurotransmitter receptor dysfunction: a parallel between genetic and immune aspects. *Mol Syndromol* 2016;7:197–209. doi: 10.1159/000447707
95. Lapin IP. Stimulant and convulsive effects of kynurenines injected into brain ventricles in mice. *J Neural Transm* 1978;42:37–43. doi: 10.1007/BF01262727
96. Joensuu T, Kuronen M, Alakurtti K, Tegelberg S, Hakala P, Aalto A, et al. Cystatin B: mutation detection, alternative splicing and expression in progressive myoclonus epilepsy of Unverricht-Lundborg type (EPM1) patients. *Eur J Hum Genet* 2007;15:185–193. doi: 10.1038/sj.ejhg.5201723
97. Abel HJ, Duncavage EJ. Detection of structural DNA variation from next generation sequencing data: a review of informatic approaches. *Cancer Genet* 2013;206:432–440. doi: 10.1016/j.cancergen.2013.11.002
98. Zhao W, Chen JJ, Perkins R, Wang Y, Liu Z, Hong H, et al. A novel procedure on next generation sequencing data analysis using text mining algorithm. *BMC Bioinformatics* 2016;17:213. doi: 10.1186/s12859-016-1075-9
99. Okuma Y, Shimo Y, Shimura H, Hattori K, Hattori T, Tanaka S, et al. Familial cortical tremor with epilepsy: an under-recognized familial tremor. *Clin Neurol Neurosurg* 1998;100:75–78. doi: 10.1016/S0303-8467(98)00003-1
100. Terada K, Ikeda A, Mima T, Kimura K, Nagahama Y, Kamioka Y, et al. Familial cortical myoclonic tremor as a unique form of cortical reflex myoclonus. *Mov Disord* 1997;12:370–377. doi: 10.1002/mds.870120316
101. Yokochi M, Takaoka S, Kawano H, Mori H, Shirai T, Imai H, et al. [A 77-year-old woman with myoclonus and epilepsy]. *No To Shinkei* 1993; 45:1173–1185.
102. Okuma Y, Shimo Y, Hattori K, Hattori T, Tanaka S, Mizuno Y. Familial cortical tremor with epilepsy. *Parkinsonism Relat Disord* 1997;3:83–87. doi: 10.1016/S1353-8020(97)00001-1
103. Oguni E, Hayashi A, Ishii A, Mizusawa H, Shoji S. A case of cortical tremor as a variant of cortical reflex myoclonus. *Eur Neurol* 1995;35:63–64. doi: 10.1159/000117093
104. Nagayama S, Kishikawa H, Yukitake M, Matsui M, Kuroda Y. [A case of familial myoclonus showing extremely benign clinical course]. *Rinsho Shinkeigaku* 1998;38:430–434.