

# Novel compound heterozygous mutations in *ABCA4* in a Chinese pedigree with Stargardt disease

Jianping Zhang,<sup>1</sup> Anhui Qi,<sup>2,3</sup> Xi Wang,<sup>3</sup> Hong Pan,<sup>2,3</sup> Haiming Mo,<sup>1</sup> Jiwei Huang,<sup>1</sup> Honghui Li,<sup>1</sup> Zhenwen Chen,<sup>1</sup> Meirong Wei,<sup>1</sup> Binbin Wang<sup>3</sup>

(The first two authors contributed equally to this work.)

<sup>1</sup>Department of Ophthalmology, Liuzhou Maternal and Child Healthcare Hospital, Liuzhou, Guangxi, China; <sup>2</sup>Graduate School of Peking Union Medical College, Beijing, China; <sup>3</sup>National Research Institute of Family Planning, Beijing, China

**Purpose:** Stargardt disease (STGD) is a common macular dystrophy in juveniles that is commonly inherited as an autosomal recessive trait. Mutations in five genes (*ABCA4*, *PROM1*, *ELOVL4*, *BEST1*, and *PRPH2*) have been reported to be associated with STGD. In the present study, we aimed to identify the pathogenic mutations in affected members in a Chinese STGD pedigree.

**Methods:** One patient was selected for whole-exome sequencing. Variants in five candidate genes were identified initially, followed by several filtering steps against public and private variation databases (1000Genomes, ESP6500si, ExAC, and in-house database), as well as bioinformatic analysis of the putative pathogenic roles. Sanger sequencing was used for cosegregation analysis among all members with available DNA.

**Results:** Two mutations in *ABCA4* (NM\_000350.2; c.5646G>A; p.Met1882Ile and NM\_000350.2; c.3523-2A>G) were found using whole-exome sequencing. Cosegregation analysis confirmed all the affected members carried the compound heterozygous mutations while the other healthy members had at most one. The missense mutation was extremely rare in public databases and predicted to be deleterious. The splice-site mutation was absent from all public and private databases and was predicted to alter the splice pattern, resulting in an exon skip and a frameshift.

**Conclusions:** Using whole-exome sequencing, we found novel compound heterozygous mutations in *ABCA4* in a Chinese STGD pedigree. These mutations are reported for the first time, therefore widening the mutation spectrum of Stargardt disease. The present study also illustrates the potential of whole-exome sequencing in determining the genetic cause of STGD.

Stargardt disease (STGD) is a common juvenile hereditary macular dystrophy that was first proposed by Karl Stargardt in 1909 [1]. It is characterized by progressive loss of central vision, a beaten-bronze appearance, atrophy of the RPE, and flecks around the macula and/or retinal periphery with a prevalence of about 1 in 10,000 [2,3]. Most cases are inherited in an autosomal recessive pattern while in some families the disorder is transmitted in an autosomal dominant form [2,4,5]. This disorder is clinically and genetically heterogeneous. The clinical features, including disease manifestation, progression, prognosis and imaging results, may vary with the disease-causing mutations in various genes. Until now, mutations in five genes (*ABCA4*-Gene ID: 24, OMIM 601691, *PROM1*-Gene ID: 8842, OMIM 604365, *ELOVL4*-Gene ID: 6785, OMIM 605512, *BEST1*-Gene ID: 7439, OMIM 607854, and *PRPH2*-Gene ID: 5961, OMIM 179605) have been reported to be associated with STGD [6-10].

STGD1 is the most frequent form of all STGD cases, which is caused by compound heterozygous or homozygous mutations in the *ATP binding cassette subfamily A member 4* (*ABCA4*) gene [11]. The onset of STGD occurs in childhood most commonly, followed by early adulthood and later adulthood. Generally speaking, the earlier the onset of STGD, the worse the prognosis, resulting in more serious vision loss in the children compared with adults [12]. To date, more than 900 sequence variants in *ABCA4* have been identified [13]. Increasing evidence suggests that onset is related to the deleterious effect of the identified variants. Early onset STGD1 is more frequently associated with more deleterious variants, including nonsense, splice-site, and frameshift mutations, compared with later onset [12].

Here, we report a Chinese STGD pedigree with three affected members in an autosomal recessive inherited pattern. Whole-exome sequencing (WES) revealed compound heterozygous mutations in *ABCA4* completely cosegregated with this disorder. These two mutations were identified for the first time in STGD.

Correspondence to: Binbin Wang, Center for Genetics, National Research Institute for Family Planning, 12 Dahuisi Road, Haidian, Beijing 100081 China; Phone: +86 10 62173443; FAX: +86 10 62179086; email: wbbahu@163.com

**METHODS**

**Ethics statement:** This research project was approved by the ethical committee of the National Research Institute of Family Planning. Written informed consent was obtained from all participants. The methods and experiments were performed in accordance with approved guidelines. The study adhered to the tenets of the Declaration of Helsinki and the ARVO statement on human subjects.

**Clinical examinations:** Eight members of a STGD pedigree were enrolled for clinical and genetic analysis (Figure 1A). The medical history of each participant was recorded, and ophthalmic examinations, including measurement of visual acuity, fundus examination, optical coherence tomography (OCT), full field electroretinography (ERG), and electrooculogram (EOG), were performed at the Maternal and Children Healthcare Hospital, Liuzhou, Guangxi, China for the diagnosis of STGD disease.

**WES and validation:** Peripheral venous blood was collected from all participants, and genomic DNA was extracted using the QIAamp DNA Blood Mini Kit (QIAGEN, Hilden, Germany). All exons were captured with the SureSelect Human All Exon V5 (Agilent, Santa Clara, CA) and then sequenced on the Illumina HiSeq4000 sequencer (Illumina, Saint Diego, CA). The reads were aligned against the human reference genome (hg19) by using BWA -0.7.10 (the Burrows-Wheeler Alignment Tool). The GATK 3.v4 (Genome Analysis Toolkit) was used to call variants that include single nucleotide polymorphisms (SNPs) and indels. Then the variants were annotated with SnpEff\_v4.1.

The impact of missense mutations on the proteins was predicted with online programs, including MutationTaster, SIFT, PolyPhen2, and SNP&GO. Conservation analysis was predicted with CLC Workbench software. Whether the splice site mutation altered the splice pattern was assessed with

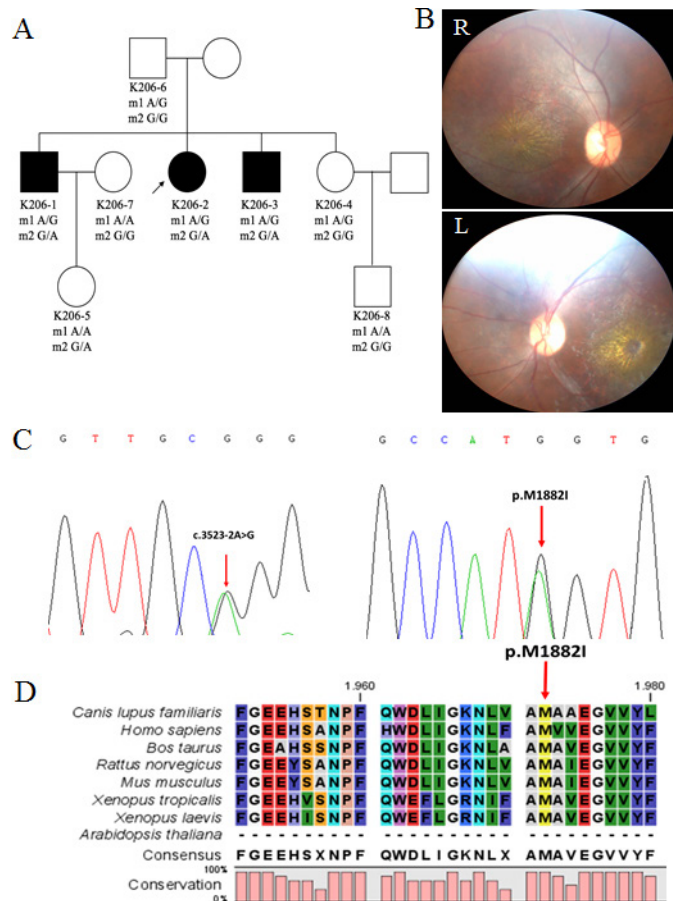


Figure 1. Compound heterozygous mutations in *ABCA4* identified in the STGD family. **A:** The Chinese Stargardt disease pedigree and the complete cosegregation pattern of the compound heterozygous mutations in *ABCA4*. **B:** The fundus images of both of the proband’s eyes showed yellow flecks on the retina and macular atrophy. **C:** Sanger sequencing results for the two mutations. **D:** Multiple alignment of *ABCA4* indicated p.M1882 is highly conserved. m1: c.3523-2A>G; m2: c.5646G>A, p.M1882I; square: male; circle: female; filled symbol: patient; unfilled symbol: unaffected member; black arrow: the proband; R: right eye; L: left eye.

MaxEntScan (MaxEnt), Human Splicing Finder 3 (HSF3), and NetGene2. Cosegregation analysis of the two mutations in *ABCA4* was performed with Sanger sequencing among pedigree members with available DNA. The primers used for Sanger sequencing were as follows: forward, 5'-GGC TCT TGC TCA GTT CCC-3'; reverse, 5'-TTT AAC CCG ATC CTC TAC TTG-3' (*ABCA4* c.5646G>A); and forward, 5'-GCT GCG AAG TGA ACA AAC-3'; reverse, 5'-CCA GAC GGA ACC CAA GTA-3' (*ABCA4* c.3523-2A>G).

## RESULTS

**Clinical manifestations and examination results:** The proband (K206-2) was 25-years-old and admitted to the hospital for evaluation of his eyesight. The uncorrected visual acuity of each eye was 20/400, which has progressively decreased for 13 years. Ophthalmoscopy showed atrophic and pigmentary changes in the macular area and some evident yellow flecks (Figure 1B). The retinal vessels were normal. OCT displayed thinning of the nerve fiber layer the outer nuclear layer (ONL), and the inner segment-outer segment junction (IS-OS), as well as various degrees of atrophy of the RPE (Appendix 1). Therefore, he was diagnosed with Stargardt disease 1. His two siblings, K206-1 and K206-3, had had progressive vision loss for 14 and 17 years, respectively. Fundus examinations showed the typical yellow flecks and macular atrophy while OCT indicated results similar to the proband's (Appendix 1 and Appendix 2). The other family members did not have obvious ocular abnormalities after undergoing medical examinations. The clinical characteristics and examination results are shown in Table 1, Appendix 3, and Appendix 4.

**Whole-exome sequencing in one patient in the STGD pedigree:** The proband was selected for WES. Using WES, we identified 78,715 SNPs and 9,428 indels. Initially, we focused on the non-synonymous mutations, including the missense, nonsense, splice-site, and frameshift mutations of five known candidate genes (*ABCA4*, *PROM1*, *ELOVL4*, *BEST1*, and *PRPH2*) and found seven missense mutations and one splice-site mutation in *ABCA4*, *ELOVL4*, and *PRPH2* (Table 2). Subsequent searching for the minor allele frequency of each variant in public databases (1000Genomes, ESP6500si, and ExAC) excluded five variants as they are common in various populations. In addition, another variant (*ABCA4* p.G1183C) was predicted to be benign by all four online programs and therefore was discarded. Finally, one rare mutation (c.5646G>A; p.M1882I in exon 40) and a novel splice-site mutation (c.3523-2A>G at the 3' splice site in intron 24 in *ABCA4*) remained. Both variations were highly conserved according to online predictions.

**Cosegregation analysis:** Cosegregation analysis was performed among the family members who had available DNA. All affected members carried these two mutations. The proband's unaffected father and healthy sister both harbored the splice-site mutation only, while the unaffected daughter of K206-1 had only the missense mutation, demonstrating that these two mutations were compound heterozygous and completely segregated with the disorder (Figure 1A,C).

**Online predictions:** The missense mutation (c.5646G>A), resulting in an amino acid substitution from Met to Ile at the 1882th residue, was not found in 1000 Genomes, ESP6500si, or an in-house database (about 400 exomes), and was rare in ExAC (carried by three individuals in an East Asian population comprising more than 4,300 sequenced samples). The mutation was predicted to damage the protein function by online programs including MutationTaster, SIFT, PolyPhen2, and SNP&GO, and was highly conserved among various species (Figure 1D, Table 2).

The splice-site mutation (c.3523-2A>G) was absent from all public databases and our internal database. We applied MaxEnt and HSF to predict whether the mutation could alter the splice pattern. When it was mutated, the score given by MaxEnt decreased remarkably from 8.69 to 0.73 with a reduction of 91.6% exceeding the threshold of 30% [14]. Meanwhile, the HSF score decreased from 88.54 to 59.59 with an alteration over the threshold of 10% [15]. Both programs predicted this splice site might be abandoned in the mutant. Additionally, the NetGene2 program predicted the acceptor site mutation that led to the skipping of exon 25, a frameshift change, and a premature termination.

## DISCUSSION

The *ABCA4* gene, located on human chromosome 1p, is a member of the subfamily A of ATP-binding cassette (ABC) transporter family [16]. The gene is expressed in the outer segments of the photoreceptor cells of the vertebrate retina and encodes a retina-specific ABC transporter protein called ABCR [4,17]. Previous studies have shown that ABCR is involved in the transport of N-retinylidene-PE (a precursor of potentially toxic substances) and then prevents the accumulation of precursor inside the disks. The mutation in *ABCA4* can ultimately lead to the accumulation of lipofuscin content in the RPE cells and influence retinoid cycle kinetics [4,18].

*ABCA4* is a large gene comprising 50 exons and spanning 130 kbp with more than 900 mutations identified in patients with STGD or cone-rod dystrophy. The numerous sequence variants make the establishment of a genotype-phenotype relation problematic and genetic testing of *ABCA4*-related disorders challenging. Direct sequencing of all exons or

TABLE 1. CLINICAL FEATURES OF A CHINESE PEDIGREE WITH SIGD.

Patients	Age	Gender	Vision acuity	Fundus manifestations	OCT	ERG	EOG
K206-2	26	F	20/400 20/400	macular atrophy, yellow flecks on RPE	thin nerve epithelium; become thin; RPE atrophy	a, b-wave amplitude declined moderately	light peak/dark trough ratio (Lp/Dt) declined heavily
K206-1	28	M	20/400 20/400	macular atrophy, yellow flecks on RPE	thin nerve epithelium; become thin; RPE atrophy	a, b-wave amplitude declined moderately	N.D.
K206-3	24	M	20/500 20/500	macular atrophy, yellow flecks on RPE	thin nerve epithelium; become thin; RPE atrophy	a, b-wave amplitude declined moderately	light peak/dark trough ratio (Lp/Dt) declined moderately

F: female; M: male; RPE: retinal pigment epithelium; OCT: optical coherence tomography; ONL: outer nuclear layer; IS/OS: inner segment/outer segment; F-ERG: flash electroretinogram; EOG: electro-oculogram; N.D.: not detected

TABLE 2. MUTATIONS IN KNOWN CANDIDATE GENES OF STARGARDT DISEASE IDENTIFIED BY WHOLE-EXOME SEQUENCING.

Gene	Chromosome Position	Mutation	1000G (%)	ESP6500si (%)	ExAC# (%)	Online Prediction			SNPs&GO
						PolyPhen2	SIFT	MutationTaster	
	chr1:94,476,424	NM_000350.2:c.G5646A:p.M1882I	0	0	0.035	+	+	+	+
ABCA4	chr1:94,505,685	NM_000350.2:c.3523-2A>G:	0	0	0	NA	NA	NA	NA
	chr1:94,505,659	NM_000350.2:c.G3547T:p.G1183C	0.34	0	1.34	-	-	-	-
ELOVL4	chr1:94,544,234	NM_000350.2:c.A1268G:p.H423R	30.26	30.94	24.77	-	-	-	-
	chr6:80,626,375	NM_022726.3:c.A895G:p.M299V	24.16	10.92	21.16	-	-	-	-
	chr6:42,666,061	NM_000322.4:c.A1013G:p.D338G	75.74	19.88	86.02	Unknown	-	-	-
PRPH2	chr6:42,666,145	NM_000322.4:c.G929A:p.R310L	94.13	9.46	99.82	-	-	-	-
	chr6:42,666,164	NM_000322.4:c.C910G:p.Q304E	75.66	19.90	85.85	+	-	-	-

#refer to the frequency in ExAC East Asian population comprising over 8600 chromosomes. “+”: predicted to be deleterious; “-”: predicted to be benign; NA: not applicable

screening with microarrays for all known disease-causing mutations in *ABCA4* can detect the majority of pathogenic variants [19,20]. However, they are either low cost-effective or unable to detect novel variants. With the rapid development of sequencing technology, massively parallel sequencing or next-generation sequencing (NGS) has been frequently used for genome-wide or region-wide identification of disease-related variants, which includes whole-genome, whole-exome, and target-region sequencing. Exome sequencing projects in Stargardt disease cohorts have shown the enormous potential and good performance of NGS in STGD genetic research and diagnosis [21-24].

Here, we employed WES to identify the genetic pathogenic cause of a Chinese STGD family. We identified compound heterozygous mutations in *ABCA4* that was cosegregated with the phenotype among all members. In general, STGD disease is caused by mutations in the *ABCA4* gene in an autosomal recessive pattern. That is to say, only when the *ABCA4* gene is abnormal on both chromosomes and the structure or function of the ABCR protein is almost completely disrupted is the mutation pathogenic because the protein cannot participate in the transport of N-retinylidene-PE. In the present study, the family members who carry only one mutation exhibit no symptom of vision loss, because nearly half of the ABCR protein can work normally, which is sufficient for the normal transportation of N-retinylidene-PE. Members who carry only one mutation are healthy while the members who carry the two mutations are affected, demonstrating that these two mutations are pathogenic in a recessive pattern.

The impact of the missense mutation (c.5646G>A; p.M1882I) on protein function was predicted to be deleterious by four online prediction programs. This missense mutation has been previously reported in a patient with STGD with screening three exons (17, 40, and 47) of the *ABCA4* gene [25]. A splice-site mutation is another common type of disease-causing mutation that disrupts the protein function through altering mRNA splice patterns. Several splice-site mutations (c.5461-10T>C and c.5312+3A>T, for instance) have been reported to cause exon skipping, intron retaining, and frame shifting that result in premature protein products [26,27]. In the present study, a novel mutation (c.3523-2A>G) in a canonical splice acceptor site was identified for the first time. The acceptor site was abandoned, and the 25<sup>th</sup> exon was skipped, as predicted by HSF3, MaxEnt, and NetGene2. These caused the frameshift of the open reading frame (ORF) and led to premature termination of protein translation.

In summary, we identified novel compound heterozygous mutations in *ABCA4*, by using WES, in a Chinese STGD

pedigree. These results make the genetic studies of STGD more comprehensive and may help in genetic counseling for patients with STGD. In addition, the results indicate that WES is a useful tool for genomic analysis that can help us better understand the genetic mechanism of STGD.

#### **APPENDIX 1. OPTICAL COHERENCE TOMOGRAPHY (OCT) OF THE AFFECTED MEMBERS SHOWED THE CENTRAL LOSS OF OUTER RETINA STRUCTURE.**

OCT was not performed on the proband's right eye due to its poor condition. It is difficult to see the IS/OS layer clearly because it atrophied severely. Red arrow: RPE layer. To access the table, click or select the words "[Appendix 1.](#)"

#### **APPENDIX 2. THE FUNDUS IMAGES OF K206-1 AND K206-2 SHOWED YELLOW FLECKS ON RETINA AND MACULAR ATROPHY.**

To access the table, click or select the words "[Appendix 2.](#)"

#### **APPENDIX 3. THE RESULTS OF EOG OF ALL AFFECTED MEMBERS IN THE STGD FAMILY**

EOG: electro-oculogram; K206-1 did not receive EOG examination. To access the table, click or select the words "[Appendix 3.](#)"

#### **APPENDIX 4. THE RESULTS OF ERG OF ALL AFFECTED MEMBERS IN THE STGD FAMILY**

ERG: electroretinogram. To access the table, click or select the words "[Appendix 4.](#)"

#### **ACKNOWLEDGMENTS**

The authors thank all the participants in this study, without whom the research couldn't have been performed. This study was supported by national science and technology basic work (2014FY130100). Meirong Wei (wmr6512@126.com) and Binbin Wang contributed equally to the research project and can be considered co-corresponding authors. None of the authors disclosed any conflict of interest.

#### **REFERENCES**

1. Riveiro-Alvarez R, Aguirre-Lamban J, Lopez-Martinez MA, Trujillo-Tiebas MJ, Cantalapiedra D, Vallespin E, Avila-Fernandez A, Ramos C, Ayuso C. Frequency of *ABCA4* mutations in 278 Spanish controls: an insight into the prevalence of autosomal recessive Stargardt disease. *Br J Ophthalmol* 2009; 93:1359-64. [PMID: 18977788].

2. Anderson KL, Baird L, Lewis RA, Chinault AC, Otterud B, Leppert M, Lupski JR. A YAC contig encompassing the recessive Stargardt disease gene (STGD) on chromosome 1p. *Am J Hum Genet* 1995; 57:1351-63. [PMID: 8533764].
3. Michaelides M, Hunt DM, Moore AT. The genetics of inherited macular dystrophies. *J Med Genet* 2003; 40:641-50. [PMID: 12960208].
4. Battu R, Verma A, Hariharan R, Krishna S, Kiran R, Jacob J, Ganapathy A, Ramprasad VL, Kumaramanickavel G, Jeyabalan N, Ghosh A. Identification of Novel Mutations in ABCA4 Gene: Clinical and Genetic Analysis of Indian Patients with Stargardt Disease. *BioMed Res Int* 2015; xxx:940864-.
5. Kniazeva M, Chiang MF, Morgan B, Anduze AL, Zack DJ, Han M, Zhang K. A new locus for autosomal dominant stargardt-like disease maps to chromosome 4. *Am J Hum Genet* 1999; 64:1394-9. [PMID: 10205271].
6. Allikmets R, Shroyer NF, Singh N, Seddon JM, Lewis RA, Bernstein PS, Peiffer A, Zabriskie NA, Li Y, Hutchinson A, Dean M, Lupski JR, Leppert M. Mutation of the Stargardt disease gene (ABCR) in age-related macular degeneration. *Science* 1997; 277:1805-7. [PMID: 9295268].
7. Yang Z, Chen Y, Lillo C, Chien J, Yu Z, Michaelides M, Klein M, Howes KA, Li Y, Kaminoh Y, Chen H, Zhao C, Chen Y, Al-Sheikh YT, Karan G, Corbeil D, Escher P, Kamaya S, Li C, Johnson S, Frederick JM, Zhao Y, Wang C, Cameron DJ, Huttner WB, Schorderet DF, Munier FL, Moore AT, Birch DG, Baehr W, Hunt DM, Williams DS, Zhang K. Mutant prominin 1 found in patients with macular degeneration disrupts photoreceptor disk morphogenesis in mice. *J Clin Invest* 2008; 118:2908-16. [PMID: 18654668].
8. Edwards AO, Donoso LA, Ritter R 3rd. A novel gene for autosomal dominant Stargardt-like macular dystrophy with homology to the SUR4 protein family. *Invest Ophthalmol Vis Sci* 2001; 42:2652-63. [PMID: 11581213].
9. Petrukhin K, Koisti MJ, Bakall B, Li W, Xie G, Marknell T, Sandgren O, Forsman K, Holmgren G, Andreasson S, Vujic M, Bergen AA, McGarty-Dugan V, Figueroa D, Austin CP, Metzker ML, Caskey CT, Wadelius C. Identification of the gene responsible for Best macular dystrophy. *Nat Genet* 1998; 19:241-7. [PMID: 9662395].
10. Poloschek CM, Bach M, Lagreze WA, Glaus E, Lemke JR, Berger W, Neidhardt J. ABCA4 and ROM1: implications for modification of the PRPH2-associated macular dystrophy phenotype. *Invest Ophthalmol Vis Sci* 2010; 51:4253-65. [PMID: 20335603].
11. Allikmets R, Singh N, Sun H, Shroyer NF, Hutchinson A, Chidambaram A, Gerrard B, Baird L, Stauffer D, Peiffer A, Rattner A, Smallwood P, Li Y, Anderson KL, Lewis RA, Nathans J, Leppert M, Dean M, Lupski JR. A photoreceptor cell-specific ATP-binding transporter gene (ABCR) is mutated in recessive Stargardt macular dystrophy. *Nat Genet* 1997; 15:236-46. [PMID: 9054934].
12. Tanna P, Strauss RW, Fujinami K, Michaelides M. Stargardt disease: clinical features, molecular genetics, animal models and therapeutic options. *Br J Ophthalmol* 2016; [PMID: 27491360].
13. Zernant J, Xie YA, Ayuso C, Riveiro-Alvarez R, Lopez-Martinez MA, Simonelli F, Testa F, Gorin MB, Strom SP, Bertelsen M, Rosenberg T, Boone PM, Yuan B, Ayyagari R, Nagy PL, Tsang SH, Gouras P, Collison FT, Lupski JR, Fishman GA, Allikmets R. Analysis of the ABCA4 genomic locus in Stargardt disease. *Hum Mol Genet* 2014; 23:6797-806. [PMID: 25082829].
14. Yeo G, Burge CB. Maximum entropy modeling of short sequence motifs with applications to RNA splicing signals. *J Comput Biol* 2004; 11:377-94. [PMID: 15285897].
15. Desmet FO, Hamroun D, Lalande M, Collod-Beroud G, Claustres M, Beroud C. Human Splicing Finder: an online bioinformatics tool to predict splicing signals. *Nucleic Acids Res* 2009; 37:e67-[PMID: 19339519].
16. Allikmets R. A photoreceptor cell-specific ATP-binding transporter gene (ABCR) is mutated in recessive Stargardt macular dystrophy. *Nat Genet* 1997; 17:122-[PMID: 9288113].
17. Molday RS, Zhong M, Quazi F. The role of the photoreceptor ABC transporter ABCA4 in lipid transport and Stargardt macular degeneration. *Biochim Biophys Acta* 2009; 1791:573-83. [PMID: 19230850].
18. Tsipi M, Tzetis M, Kosma K, Moschos M, Braoudaki M, Poulou M, Kanavakis E, Kitsiou-Tzeli S. Genomic screening of ABCA4 and array CGH analysis underline the genetic variability of Greek patients with inherited retinal diseases. *Meta Gene* 2016; 8:37-43. [PMID: 27014590].
19. Shroyer NF, Lewis RA, Yatsenko AN, Wensel TG, Lupski JR. Cosegregation and functional analysis of mutant ABCR (ABCA4) alleles in families that manifest both Stargardt disease and age-related macular degeneration. *Hum Mol Genet* 2001; 10:2671-8. [PMID: 11726554].
20. Ernest PJ, Boon CJ, Klevering BJ, Hoefsloot LH, Hoyng CB. Outcome of ABCA4 microarray screening in routine clinical practice. *Mol Vis* 2009; 15:2841-7. [PMID: 20029649].
21. Scieczynska A, Ozieblo D, Ambroziak AM, Korwin M, Szulborski K, Krawczynski M, Stawinski P, Szaflik J, Szaflik JP, Ploski R, Oldak M. Next-generation sequencing of ABCA4: High frequency of complex alleles and novel mutations in patients with retinal dystrophies from Central Europe. *Exp Eye Res* 2016; 145:93-9. [PMID: 26593885].
22. Xin W, Xiao X, Li S, Jia X, Guo X, Zhang Q. Identification of Genetic Defects in 33 Proband with Stargardt Disease by WES-Based Bioinformatics Gene Panel Analysis. *PLoS One* 2015; 10:e0132635-[PMID: 26161775].
23. Strom SP, Gao YQ, Martinez A, Ortube C, Chen Z, Nelson SF, Nusinowitz S, Farber DB, Gorin MB. Molecular diagnosis of putative Stargardt Disease probands by exome sequencing. *BMC Med Genet* 2012; 13:67-[PMID: 22863181].
24. Zhou Y, Tao S, Chen H, Huang L, Zhu X, Li Y, Wang Z, Lin H, Hao F, Yang Z, Wang L, Zhu X. Exome sequencing analysis identifies compound heterozygous mutation in ABCA4 in

- a Chinese family with Stargardt disease. *PLoS One* 2014; 9:e91962-[\[PMID: 24632595\]](#).
25. Yi J, Li S, Jia X, Xiao X, Wang P, Guo X, Zhang Q. Evaluation of the ELOVL4, PRPH2 and ABCA4 genes in patients with Stargardt macular degeneration. *Mol Med Rep* 2012; 6:1045-9. [\[PMID: 22948568\]](#).
  26. Sangermano R, Bax NM, Bauwens M, van den Born LI, De Baere E, Garanto A, Collin RW, Goercharn-Ramlal AS, den Engelsman-van Dijk AH, Rohrschneider K, Hoyng CB, Cremers FP, Albert S. Photoreceptor Progenitor mRNA Analysis Reveals Exon Skipping Resulting from the ABCA4 c.5461-10T→C Mutation in Stargardt Disease. *Ophthalmology* 2016; 123:1375-85. [\[PMID: 26976702\]](#).
  27. Xi Q, Li L, Traboulsi EI, Wang QK. Novel ABCA4 compound heterozygous mutations cause severe progressive autosomal recessive cone-rod dystrophy presenting as Stargardt disease. *Mol Vis* 2009; 15:638-45. [\[PMID: 19352439\]](#).

Articles are provided courtesy of Emory University and the Zhongshan Ophthalmic Center, Sun Yat-sen University, P.R. China. The print version of this article was created on 30 December 2016. This reflects all typographical corrections and errata to the article through that date. Details of any changes may be found in the online version of the article.