

Safe fronto-orbito-zygomatic osteotomy using a diamond-coated threadwire saw in orbito-zygomatic craniotomy

Kojiro Wada, Kentaro Mori, Terushige Toyooka, Naoki Otani, Kazuya Fujii, Hideaki Ueno, Satoshi Tomura, Arata Tomiyama

Department of Neurosurgery, National Defense Medical College, Tokorozawa, Saitama, Japan

ABSTRACT

Orbito-zygomatic craniotomy is a widely accepted skull-based technique, but osteotomy at the malar eminence (ME) is complicated. We have developed a safe fronto-orbito-zygomatic (FOZ) osteotomy by creating small guide burr holes in the superior and lateral parts of the orbital wall and cutting the bone using a diamond-coated threadwire saw. This method involves standard two-piece osteotomy by creating small superior and lateral guide orbital burr holes instead of sectioning into the superior and inferior orbital fissures. The guide burr holes are connected using a diamond-coated threadwire saw to create the FOZ bar. This method was applied to the treatment of four patients with skull-based tumors or internal carotid and basilar artery aneurysms. Postoperative three-dimensional bone density computed tomography showed minimum bone gap in the ME. No craniotomy-related complication has occurred. FOZ osteotomy by creating guide burr holes in the orbital wall and cutting the bone using a diamond-coated threadwire saw is safe and results in minimum bone gap in the ME.

Key words: Diamond-coated threadwire saw, orbital guide burr holes, orbito-zygomatic approach, skull-based surgery

Introduction

The orbito-zygomatic approach is one of the standard anterolateral skull-based techniques, which is widely accepted as a strategy to treat tumors and vascular lesions deeply located in the central skull-based including the cavernous sinus and upper clival region because of the wide operative field and angles without requiring excessive brain retraction.^[1] However, extensive bone cutting to create the fronto-orbito-zygomatic (FOZ) bar including sectioning of the superior orbital fissure (SOF) and inferior orbital fissure (IOF) is often time-consuming and sometimes difficult. In particular, the part of the malar eminence (ME) at the junction of the

orbital limb and zygomatic arch is three-dimensionally complex and is the most difficult part to section correctly.

Here we describe and recommend a technique to create small guide burr holes in the superior and lateral parts of the orbital wall to avoid sectioning into the SOF and IOF to achieve safer and faster FOZ bar removal during orbito-zygomatic craniotomy using a diamond-coated threadwire saw (diamond T-saw; Mani, Inc., Utsunomiya, Tochigi, Japan).

Surgical Technique

The procedure to perform orbito-zygomatic bar osteotomy using a diamond T-saw was demonstrated using a modified dissectable skull-based model (KEZLEX; Ono and Co., Ltd., Tokyo, Japan) with artificial dura mater, periorbita, cranial nerves, dural sinus, and cavernous sinus.^[2] After semicoronal skin incision, and interfascial dissection of the temporal muscle fascia, the temporal muscle is dissected and reflected postero-inferiorly. The orbital limb and zygomatic arch and the ME are exposed subperiosteally up to the zygomaticofacial foramen. A standard fronto-temporal craniotomy is made, and both the frontal and middle fossae are flushed with their bases. The supraorbital notch can be chiseled out if necessary. The frontal base dura mater is dissected from the orbital roof, and the periorbita is also detached from the orbit. The tip of the temporal dura mater is also detached until the SOF is exposed. Exposure of the IOF is not necessary, but the infratemporal

Access this article online

Quick Response Code:



Website:

www.asianjns.org

DOI:

10.4103/1793-5482.161190

Address for correspondence:

Dr. Kojiro Wada, Department of Neurosurgery, National Defense Medical College, 3-2 Namiki, Tokorozawa, Saitama - 359-8513, Japan.
E-mail: stingray@ndmc.ac.jp

crest, which is situated just above the IOF, should be located with the finger tip. The small guide burr holes about 3 mm diameter are made using a high speed drill in the orbital roof at 5 mm anterior from the lateral edge of the SOF (superior orbital guide burr hole) and the lateral orbital wall at 5 mm superior from the IOF on the sphenozygomatic suture (lateral orbital guide burr hole). Before cutting the FOZ bone, the titanium mini-plates are placed and removed for later precise fixation.

Figure 1 illustrates the difference in the bone cutting lines between the standard FOZ osteotomy sectioning into the SOF to IOF, and FOZ bone cutting with superior and lateral orbital small guide burr holes. The diamond T-saw (0.64 mm diameter) within the outer sheath is passed from the medial orbit to the superior orbital burr hole [Figure 2a]. A tapered brain spatula is placed between the periorbita and the orbit to protect the periorbita. The outer sheath is then removed, both ends of the wire are grasped with Péan forceps, and reciprocal movement of the saw is made to cut the orbital roof. The wire saw is then passed from the superior orbital burr hole to the inferior burr hole, and the lateral wall of the orbit is cut, in the same way. The wire saw is then passed from the lateral part of the orbit to the lateral orbital burr hole, and under the zygomatic arch near the ME. The reciprocal wire saw movement automatically cuts the ME [Figure 2b]. Finally, the zygomatic arch near the root of the zygoma is cut. Consequently, the FOZ bar is created without fracture and with minimum bone loss. Additional removal of the orbital roof and opening of the SOF and optic canal can be added according to the pathology if necessary.

We applied this method to the treatment of four patients with skull-based tumors or internal carotid, and basilar artery aneurysms [Figure 3a].

Results

Figure 3b shows a representative postoperative three-dimensional bone density computed tomography image, which depicts the minimum bone gap at the ME. No craniotomy-related complications including enophthalmos have occurred.

Discussion

Since the orbito-zygomatic approach was introduced, many operative techniques and modifications have been advocated. The two main techniques involve one-piece or two-piece bone flap methods.^[3-5] The one-piece method requires a simpler reconstruction of the bone flap, whereas the two-piece method allows for more extensive removal of the superior and lateral parts of the orbit.^[5] The two-piece method of orbito-zygomatic craniotomy requires FOZ osteotomy in addition to the standard fronto-temporal craniotomy. The original procedures used sectioning into the SOF and IOF to create the FOZ bar in order to reduce bony loss.^[6] However, sectioning into the SOF carries the potential risk of injury to the cranial nerves passing through the foramen. The necessary extent of bony

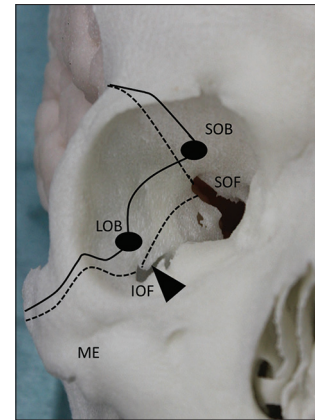


Figure 1: Photograph of the three-dimensional skull model showing the two different bone cutting lines of fronto-orbito-zygomatic (FOZ) bar formation. Broken line: Bone cutting line for standard FOZ bar sectioning into the superior orbital fissure (SOF) and inferior orbital fissure (IOF). Solid line: Bone cutting line of the FOZ bar using the superior orbital guide burr hole and lateral orbital guide burr hole without sectioning the SOF and IOF. Arrowhead indicates the infratemporal crest. ME: Malar eminence

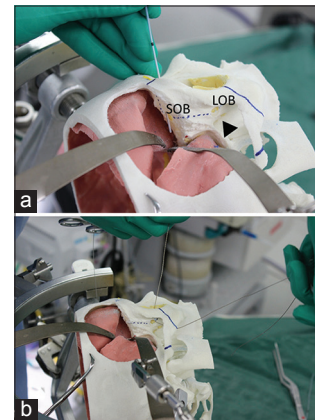


Figure 2: Photographs of the three-dimensional skull model showing the process of fronto-orbito-zygomatic bar formation using a diamond-coated threadwire saw. (a) Outer sheath is passed between the periorbita and superior orbital burr hole. (b) Bone cutting using a diamond-coated threadwire saw passing from the lateral orbital burr hole to the zygoma to cut the malar eminence. Arrowhead: Infratemporal crest

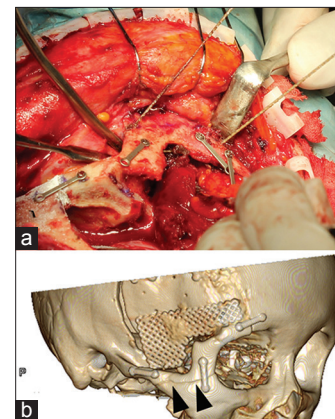


Figure 3: Intraoperative photograph showing cutting of the malar eminence (ME) using a diamond-coated threadwire saw (a), and postoperative three-dimensional bone density computed tomography image. (b) Note the minimal bone gap in the ME (arrowheads)

removal depends on the pathology. To avoid nerve injury, we recommend to create small superior and lateral orbital guide keyholes instead of sectioning of the SOF, and IOF, for a safe and easy way to remove the FOZ bar.

The ME is located between the lateral orbital limb and the zygomatic arch, and forms a tetrapod-like bony mass. Sectioning this part with the oscillation bar is the most difficult maneuver in orbito-zygomatic craniotomy. After incomplete bony cutting, empirical fracturing using a chisel is usually performed but sometimes causes formidable fragmentation of the zygomatic arch. The diamond T-saw was originally introduced in cervical laminoplasty to split the spinous process and then was used in craniotomy to reduce the bone gap for fitted bone flap fixation.^[7-10]

The diamond T-saw includes a 20 cm section in the midpoint of the wire that is coated with diamond particles to act as the cutting edge. A standard wire saw (Gigli saw) is also used in some cases of FOZ craniotomy.^[4] However, the bone gap is thinner, and the procedure is faster using the diamond T-saw cutting compared with the Gigli saw. Cutting this part of the ME using a diamond T-saw with a simple reciprocating movement automatically creates the appropriate cutting line in this complicated shaped bony part, avoids bone fracture, and is more time efficient. The thin cutting line created by a diamond T-saw also reduces bony loss and is cosmetically beneficial. We have not experienced any craniotomy-related complications including enophthalmos.

Conclusions

The present technique for FOZ bar craniotomy in the orbito-zygomatic approach using a diamond T-saw with small

guide burr holes in the orbital wall is safe and easy and results in minimum bone gap, especially in the ME.

References

1. Campero A, Martins C, Socolovsky M, Torino R, Yasuda A, Domitrovic L, *et al.* Three-piece orbitozygomatic approach. *Neurosurgery* 2010;66:E119-20.
2. Hakuba A, Liu S, Nishimura S. The orbitozygomatic infratemporal approach: A new surgical technique. *Surg Neurol* 1986;26:271-6.
3. Hayashi N, Hirashima Y, Kurimoto M, Asahi T, Tomita T, Endo S. One-piece pedunculated frontotemporal orbitozygomatic craniotomy by creation of a subperiosteal tunnel beneath the temporal muscle: Technical note. *Neurosurgery* 2002;51:1520-3.
4. Mori K, Yamamoto T, Nakao Y, Esaki T. Development of artificial cranial base model with soft tissues for practical education: Technical note. *Neurosurgery* 2010;66:339-41.
5. Shimizu S, Kondo K, Yamazaki T, Nakayama K, Yamamoto I, Fujii K. Repositioning of cranial bone flaps cut with a diamond-coated threadwire saw: 5-year experience with cosmetic cranioplasty without fixation devices. *Skull Base* 2011;21:323-8.
6. Shimizu S, Miyazaki T, Suzuki S, Yamada M, Utsuki S, Oka H, *et al.* Supratentorial craniotomy using a threadwire saw. Technical note. *Neurol Med Chir (Tokyo)* 2008;48:191-4.
7. Tanriover N, Ulm AJ, Rhoton AL Jr, Kawashima M, Yoshioka N, Lewis SB. One-piece versus two-piece orbitozygomatic craniotomy: Quantitative and qualitative considerations. *Neurosurgery* 2006;58:ONS-229.
8. Tomita K, Kawahara N. The threadwire saw: A new device for cutting bone. *J Bone Joint Surg Am* 1996;78:1915-7.
9. Tomita K, Kawahara N, Toribatake Y, Heller JG. Expansive midline T-saw laminoplasty (modified spinous process-splitting) for the management of cervical myelopathy. *Spine (Phila Pa 1976)* 1998;23:32-7.
10. Zabramski JM, Kiris T, Sankhla SK, Cabiol J, Spetzler RF. Orbitozygomatic craniotomy. Technical note. *J Neurosurg* 1998;89:336-41.

How to cite this article: Wada K, Mori K, Toyooka T, Otani N, Fujii K, Ueno H, *et al.* Safe fronto-orbito-zygomatic osteotomy using a diamond-coated threadwire saw in orbito-zygomatic craniotomy. *Asian J Neurosurg* 2015;10:250-2.

Source of Support: Nil, **Conflict of Interest:** None declared.